

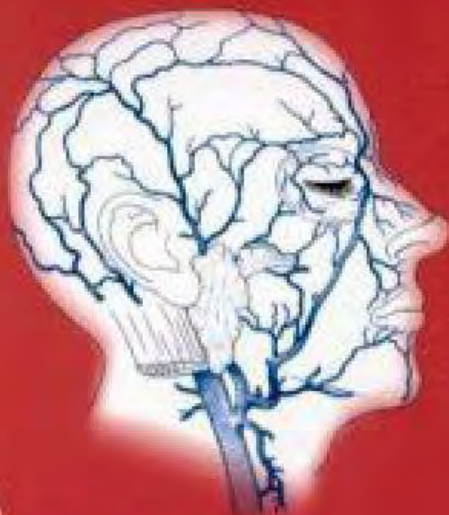
THIEME FLEXIBOOK

Heinz Feneis
Wolfgang Dauber

Pocket Atlas of
Human Anatomy

Based on the International Nomenclature

Fourth edition, fully revised



Thieme

Pocket Atlas of Human Anatomy
4th edition

Pocket Atlas of Human Anatomy

Based on the International Nomenclature

Heinz Feneis

Professor
Formerly Institute of Anatomy
University of Tübingen
Tübingen, Germany

Wolfgang Dauber

Professor
Institute of Anatomy
University of Tübingen
Tübingen, Germany

Fourth edition, fully revised
800 illustrations by Gerhard Spitzer



Thieme
Stuttgart · New York 2000

Feneis, Pocket Atlas of Human Anatomy © 2000 Thieme

All rights reserved. Usage subject to terms and conditions of license.

Library of Congress Cataloging-in-Publication Data

is available from the publisher.

1st German edition 1967	2nd Japanese edition 1983	7th German edition 1993
2nd German edition 1970	1st Dutch edition 1984	2nd Dutch edition 1993
1st Italian edition 1970	2nd Swedish edition 1984	2nd Greek edition 1994
3rd German edition 1972	2nd English edition 1985	3rd English edition 1994
1st Polish edition 1973	2nd Polish edition 1986	3rd Spanish edition 1994
4th German edition 1974	1st French edition 1986	3rd Danish edition 1995
1st Spanish edition 1974	2nd Polish edition 1986	1st Russian edition 1996
1st Japanese edition 1974	6th German edition 1988	2nd Czech edition 1996
1st Portuguese edition 1976	2nd Italian edition 1989	3rd Swedish edition 1996
1st English edition 1976	2nd Spanish edition 1989	2nd Turkish edition 1997
1st Danish edition 1977	1st Turkish edition 1990	8th German edition 1998
1st Swedish edition 1979	1st Greek edition 1991	1st Indonesian edition 1998
1st Czech edition 1981	1st Chinese edition 1991	1st Basque edition 1998
5th German edition 1982	1st Icelandic edition 1992	3rd Dutch edition 1999
2nd Danish edition 1983	3rd Polish edition 1992	4th Spanish edition 2000

This book is an authorized and revised translation of the 8th German edition published and copyrighted 1998 by Georg Thieme Verlag, Stuttgart, Germany.

Translated by David B Meyer, Detroit, Michigan, USA.

Translation revised by Suzyon O'Neal Wandrey, Berlin, Germany.

Important Note: Medicine is an ever-changing science undergoing continual development. Research and clinical experience are continually expanding our knowledge, in particular our knowledge of proper treatment and drug therapy. Insofar as this book mentions any dosage or application, readers may rest assured that the authors, editors, and publishers have made every effort to ensure that such references are in accordance with **the state of knowledge at the time of production of the book.**

Nevertheless, this does not involve, imply, or express any guarantee or responsibility on the part of the publishers in respect of any dosage instructions and forms of application stated in the book. **Every user is requested to examine carefully** the manufacturers' leaflets accompanying each drug and to check, if necessary in consultation with a physician or specialist, whether the dosage schedules mentioned therein or the contraindications stated by the manufacturers differ from the statements made in the present book. Such examination is particularly important with drugs that are either rarely used or have been newly released on the market. **Every dosage schedule or every form of application used is entirely at the user's own risk and responsibility.** The authors and publishers request every user to report to the publishers any discrepancies or inaccuracies noticed.

Some of the product names, patents, and registered designs referred to in this book are in fact registered trademarks or proprietary names even though specific reference to this fact is not always made in the text. Therefore, the appearance of a name without designation as proprietary is not to be construed as a representation by the publisher that it is in the public domain.

This book, including all parts thereof, is legally protected by copyright. Any use, exploitation, or commercialization outside the narrow limits set by copyright legislation, without the publisher's consent, is illegal and liable to prosecution. This applies in particular to photostat reproduction, copying, mimeographing or duplication of any kind, translating, preparation of microfilms, and electronic data processing and storage.

© 1976, 2000 Georg Thieme Verlag, Rüdigerstraße 14, D-70469 Stuttgart, Germany
Thieme New York, 333 Seventh Avenue, New York, NY 10001, USA

Typesetting by primustype R. Hurler GmbH, D-73274 Notzingen, Typeset on Textline/HerculesPro
Printed in Germany by Offizin Andersen Nexö, Leipzig

ISBN 3-13-511204-7 (GTV)

ISBN 0-86577-928-7 (TNY)

1 2 3 4 5 6

Feneis, Pocket Atlas of Human Anatomy © 2000 Thieme

All rights reserved. Usage subject to terms and conditions of license.

Foreword

The success of Dr. Feneis's "Bildwörterbuch" has been phenomenal. I remember seeing the first edition of it most vividly and wondering why no one else had thought of producing such a useful book. And now it is in its eighth German edition, and has also been translated into many languages. I have several such versions of it on the shelf above my desk, and I refer to it frequently. It is, of course, much more than a dictionary of the official "Nomina Anatomica," for it is also a most valuable working pocket book for anyone in the field of anatomy and medicine. It is its illustrations which make it so useful and, indeed, unique; I know of no other similar dictionary in any language in which the terms are not only defined but also shown in clear, simple pictures. Among the large number of books on anatomy appearing year after year, few have the originality and perennial usefulness to become of permanent value. This volume is undoubtedly of this elite quality. It will serve students, academics, and clinicians throughout their working years.

Roger Warwick
Professor Emeritus
University of London
(Guy's Hospital Medical School)

Preface to the Fourth Edition

Professor Feneis designed the anatomic picture dictionary as a reference book that provides illustrated short descriptions of anatomic terms in accordance with the valid international nomenclature. The brief and clearly written text segments were set opposite concise figures of equal educational value—a graphic task that Professor Spitzer managed to solve brilliantly.

Since its initial publication in 1967, the Feneis work has been published in seven editions and has been translated into numerous languages. The acceptance of the pocket book format by our readers is proof of its successful didactic concept. Hence, it is only logical that the eighth edition should remain dedicated to this effective concept.

The text and figures were revised and adapted to reflect the current state of knowledge. Our colleagues and students also contributed significantly with their numerous suggestions. We would like to thank all of you for your efforts, especially Dr. C. Walther, who with great commitment provided a continuous supply of expert suggestions.

Proposals to add color to the illustrations of the present edition were rejected after extensive debate, because the masterful pen-and-ink drawings by Professor Spitzer already capture the essential elements of the structures. Furthermore, his drawings are plastic and easy to remember. The extensive addition of color would increase neither the informative value of the book nor the aesthetic appeal of the figures.

Instead, we selectively added color to the text when it served to make the individual chapters and terms easier to find, also when quickly leafing through the book. The combined use of color and different typefaces makes it easier to maintain an overview of the different terms. Highlighting in color the alphabetic characters of the figures facilitates the identification of text and graphic elements that belong together.

We would like to thank Georg Thieme Verlag and its employees for their patience, understanding, and collaboration in the production of this edition.

Tübingen, spring of 2000

Wolfgang Dauber

Contents

Bones	2
Sutures, joints and ligaments	54
Muscles	74
Muscles, synovial bursae and sheaths	100
Digestive system	108
Digestive and respiratory system	134
Urogenital system	154
Peritoneum	176
Endocrine glands	182
Heart	184
Arteries	190
Veins	230
Lymphatic system	254
Spleen, meninges	268
Meninges	268
Spinal cord	272
Brain	278
Cranial nerves	320
Spinal nerves	334
Autonomic nervous system	348
Sense organs	354
Skin and its appendages	390
General terms	396
References	409
Index	412

1

2

3

4

5

6

7

8

9

10

11

12

13

14

15

16

17

18

19

20

21

22

23

24

25

Instructions for Use

- ▶ The organization of the terms in accordance with the current Nomina Anatomica is exemplified by the typefaces shown on the right.
- ▶ Terms not organized hierarchically are printed in normal red lettering.
- ▶ The letters printed after a text segment refer to the figures on the opposite page. The numbers in the figures correspond to the key word mentioned behind the corresponding number listed in the text.
- ▶ Higher-ranking terms frequently are not represented by a number in the figures.
- ▶ Fully valid alternative expressions are listed in parentheses.
- ▶ The following are listed in single square brackets:
 - inconstant structures,
 - terms that are unofficial but listed in the Nomina Anatomica,
 - explanatory supplements.
- ▶ Terms not mentioned in the Nomina Anatomica are printed in double square brackets.
- ▶ Terms representing a supplement to the older editions are marked by lower case letters.
- ▶ Circled numeric marks refer to a more extensive region.

Examples

CARDIOVASCULAR SYSTEM

ARTERIES

AORTA

ABDOMINAL AORTA

Celiac trunk

Common hepatic artery

Proper hepatic artery

Right branch

Cystic artery

BONES OF SKULL

Neurocranium

Viscerocranium

Chondrocranium

Carpal bones (carpi)

[Sutural bones]

[Pyramidal tract]

Splenium [of corpus callosum]

[[Pouch of Douglas]]

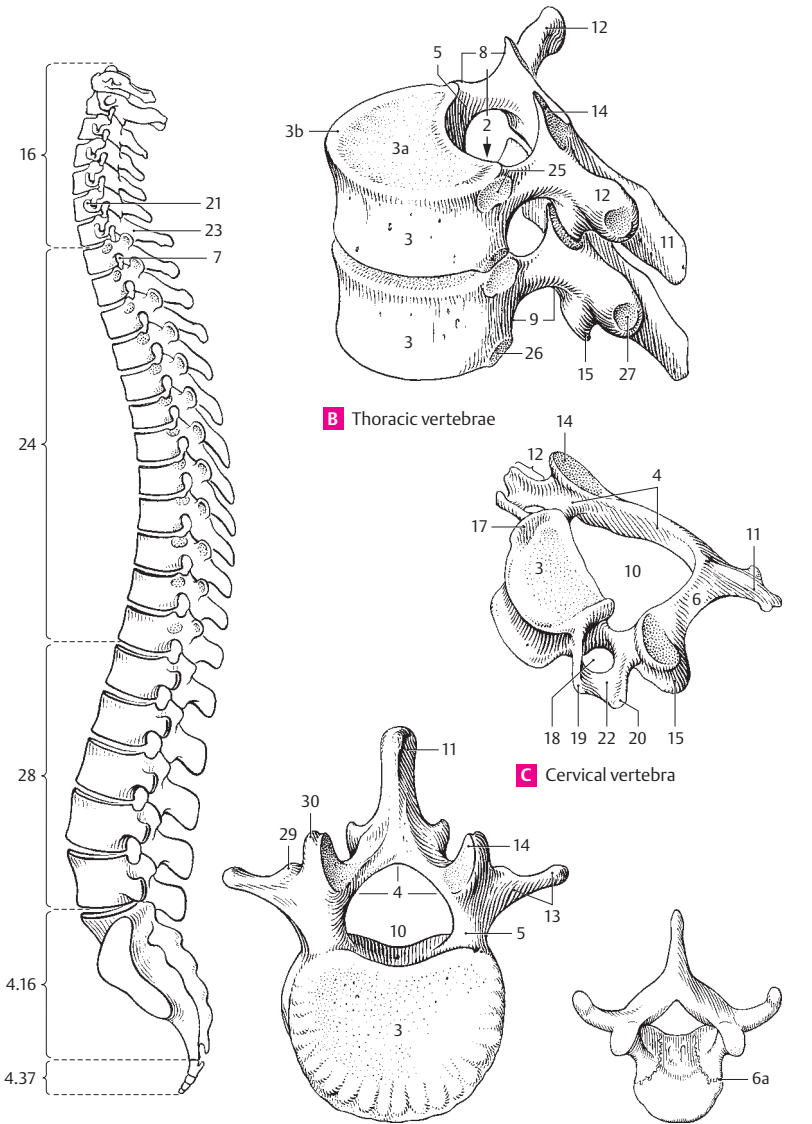
3 a intervertebral surface of vertebra

Pocket Atlas of Human Anatomy

SKELETON

Axial skeleton. Skeleton axiale.

- 1 **VERTEBRAL COLUMN.** Columna vertebralis. A
- 1a **Vertebra.**
- 2 **VERTEBRAL CANAL.** Canalis vertebralis. Canal formed by the successive vertebral foramina. It contains the spinal cord. B
- 3 **Body of vertebra.** Corpus vertebrae (vertebrale). B C D
- 3a **Facies intervertebralis.** The surface of a vertebra facing the adjacent vertebra. B
- 3b **Ring apophysis (epiphysis).** Apophysis anularis. Ring of bone around the upper and lower surfaces of the vertebral body. It represents a secondary center of ossification. B
- 4 **Vertebral arch.** Arcus vertebrae (vertebralis). It forms the posterior and lateral boundaries of the vertebral foramen. C D
- 5 **Pedicle.** Pediculus arcus vertebrae. The portion of the vertebral arch situated anteriorly between the body and transverse process as well as between the superior and inferior vertebral notches. B D
- 6 **Lamina.** Lamina arcus vertebrae (vertebralis). The portion of the vertebral arch situated posteriorly between the transverse process and the spinous process. C
- 6a **Neurocentral junction (synchondrosis).** Junctio neurocentralis. Cartilaginous joint between the left and right fetal neural arches and the centrum. E
- 7 **Intervertebral foramen.** Foramen intervertebrale. Opening for the passage of the spinal nerve and small vessels. It is bordered by the two adjacent vertebral notches, the vertebral body and the intervertebral disc. A B
- 8 **Superior vertebral notch.** Incisura vertebralis superior. Notch on the superior aspect of the pedicle. B
- 9 **Inferior vertebral notch.** Incisura vertebralis inferior. Notch on the inferior aspect of the pedicle. B
- 10 **Vertebral foramen.** Foramen vertebrale. Space surrounded by the vertebral arch and body. Together, the series of foramina form the vertebral canal. C D
- 11 **Spinous process.** Processus spinosus. It is bifid in the upper four cervical vertebrae. B C D
- 12 **Transverse process.** Processus transversus. B C
- 13 **Costal process.** Processus costalis. The transverse process of a lumbar vertebra. It corresponds to a rudimentary rib formed by the embryonic costal element. D
- 14 **Superior articular process (zygapophysis).** Processus articularis (zygapophysis) superior. Articular process on the superior aspect of the vertebral arch. B C D
- 15 **Inferior articular process (zygapophysis).** Processus articularis (zygapophysis) inferior. Articular process on the inferior aspect of the vertebral arch. B C
- 16 **CERVICAL VERTEBRAE.** Vertebrae cervicales. The seven uppermost vertebrae (C1–7). A
- 17 **Uncal process or uncus.** Uncus corporis. Upwardly projecting, hook-like process on either side of the cervical vertebrae. It occasionally gives rise to bony proliferations which can exert pressure on the spinal nerve. C
- 18 **Foramen transversarium.** Hole in the transverse process of cervical vertebrae for the passage of the vertebral artery and vein. C
- 19 **Anterior tubercle.** Tuberculum anterius. Anterior projection on the transverse processes of cervical vertebrae 2–7 for muscle attachment. C
- 20 **Posterior tubercle.** Tuberculum posterius. Posterior projection on the transverse processes of cervical vertebrae 2–7 for muscle attachment. C
- 21 **Carotid tubercle.** Tuberculum caroticum. Well developed anterior tubercle of C6. So named because the common carotid artery can be compressed against it anteriorly. A
- 22 **Groove for spinal nerve.** Sulcus n. spinalis. Groove on the transverse processes of C3–7 for the spinal nerves exiting from the intervertebral foramina. C
- 23 **Vertebra prominens (C7).** The seventh cervical vertebra. It is so named because of its especially well-developed spinous process (in 70% of cases). A
- 24 **THORACIC VERTEBRAE.** Vertebrae thoracicae. The twelve vertebrae of the thorax (T1–12). A
- 25 **Superior costal facet.** Fovea costalis superior. Fossa for articulation with the head of a rib. It is located near the root of the arch on the upper edge of the body of a vertebra. B
- 26 **Inferior costal facet.** Fovea costalis inferior. Fossa for articulation with the head of a rib. It is located below the root of the arch on the lower edge of the body of a vertebra. B
- 27 **Costal facet of transverse process.** Fovea costalis processus transversi. Facet for articulation with the tubercle of a rib. B
- 28 **LUMBAR VERTEBRAE.** Vertebrae lumbales (lumbares). The five vertebrae of the lumbar region (L1–5). A
- 29 **Accessory process.** Processus accessorius. Rudiment of the original lumbar transverse process. It projects posteriorly from the base of the costal process. D
- 30 **Mamillary process.** Processus mamillaris. A blunt process projecting from the superior articular process of the lumbar vertebra. D



A Vertebral column

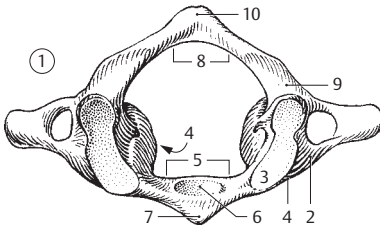
D Lumbar vertebra, superior view

E Infantile thoracic vertebra

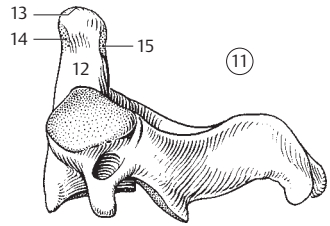
B Thoracic vertebrae

C Cervical vertebra

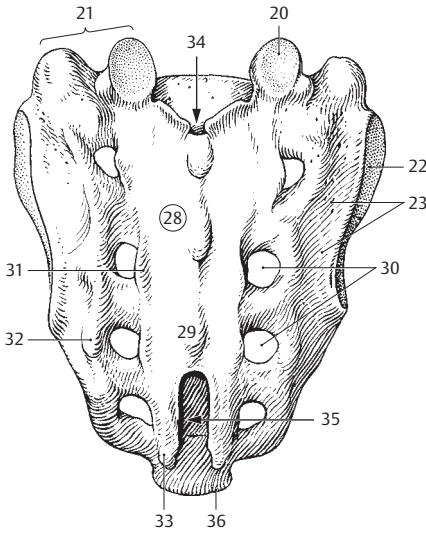
- 1 **Atlas (C1).** First cervical vertebra. It lacks a body. A
- 2 **Lateral mass of atlas.** *Massa lateralis atlantis.* The thickened lateral part of the atlas which bears the skull for the lacking vertebra. A
- 3 **Superior articular facet.** *Facies articularis superior.* Elliptical and concave facet. A
- 4 **Inferior articular facet.** *Facies articularis inferior.* Roundish and slightly concave surface lined with cartilage.
- 5 **Anterior arch of atlas.** *Arcus anterior atlantis.* A
- 6 **Dental fovea of atlas.** *Fovea dentis atlantis.* Facet for articulation with the dens of the axis on the inner surface of the anterior arch. A
- 7 **Anterior tubercle of atlas.** *Tuberculum anterius atlantis.* A
- 8 **Posterior arch of atlas.** *Arcus posterior atlantis.* A
- 9 **Groove for vertebral artery.** *Sulcus arteriae vertebralis.* Groove for the vertebral artery located on the posterior arch of the atlas behind the articular surfaces. A
- 10 **Posterior tubercle.** *Tuberculum posterius.* It is a rudiment of the spinous process. A
- 11 **Axis (C2) [[Epistropheus]]** The second cervical vertebra. B
- 12 **Dens [[odontoid process]] of axis.** *Dens axis.* B
- 13 **Apex of dens.** *Apex dentis.* Attachment site of the apical ligament of the dens. B
- 14 **Anterior articular surface of dens.** *Facies articularis anterior.* B
- 15 **Posterior articular surface of dens.** *Facies articularis posterior.* B
- 16 **OS SACRUM (SACRALE) / VERTEBRAE SACRALES I-V.** Sacral bone [[sacrum]] formed by five fused vertebrae. C D F
- 17 **Base of sacrum.** *Basis ossis sacri.* Broad upper end of sacrum. F
- 18 **Promontory of sacrum.** *Promontorium ossis sacri.* Prominent anterior margin of the body of the first sacral vertebra. It projects quite far into the pelvic inlet. F
- 19 **Ala of sacrum.** *Ala sacralis.* Part of the base of the sacrum situated lateral to the first sacral vertebra.
- 20 **Superior articular process.** *Processus articularis superior.* C F
- 21 **Lateral part or mass of sacrum.** *Pars lateralis ossis sacri.* The lateral part of the sacrum derived from the transverse processes and rudimentary ribs. C F
- 22 **Auricular surface.** *Facies auricularis.* Ear-shaped articular surface for the ilium. C
- 23 **Sacral tuberosity.** *Tuberositas sacralis.* Rough area behind the auricular surface for the attachment of the sacroiliac ligaments. C
- 24 **Pelvic surface.** *Facies pelvica.* Anterior surface of the sacrum facing the pelvis. F
- 25 **Transverse lines.** *Lineae transversae.* Four anteriorly situated fusion lines of the five sacral vertebral bodies. F
- 26 **Intervertebral foramina.** *Foramina intervertebralia.* Openings for passage of the sacral spinal nerves. They develop from the original superior and inferior notches. D
- 27 **Anterior sacral foramina.** *Foramina sacralia anteriora (pelvica).* Anterior openings for nerves and vessels. D F
- 28 **Dorsal surface of sacrum.** *Facies dorsalis ossis sacri.* C
- 29 **Median sacral crest.** *Crista sacralis mediana.* Median ridge formed by the remnants of the spinous processes of the sacral vertebrae. C
- 30 **Posterior sacral foramina.** *Foramina sacralia posteriora.* Posterior openings for nerves and vessels. C D
- 31 **Intermediate sacral crests.** *Cristae sacralis intermedia.* Remnants of the articular processes located on either side the median sacral crest. C
- 32 **Lateral sacral crest.** *Crista sacralis lateralis.* Posterior bilateral series of rudimentary transverse processes. C
- 33 **Sacral cornu (horn).** *Cornu sacrale.* Hook-shaped processes that extend downward on either side of the sacral hiatus. C
- 34 **Sacral canal.** *Canalis sacralis.* Inferior end of the vertebral canal. C D
- 35 **Sacral hiatus.** *Hiatus sacralis.* Opening at the inferior end of the vertebral canal located usually at the level of vertebrae S3–4. Emergence site of filum terminale and injection site for lower epidural anesthesia (caudal analgesia). C
- 36 **Apex of sacrum.** *Apex ossis sacri.* Inferior tip of sacrum which gives attachment to the coccyx. C F
- 37 **COCYGEAL VERTEBRAE I-IV.** *Os coccygis.* Bone that usually consists of four rudimentary vertebrae. E
- 38 **Coccygeal cornu (horn).** *Cornu coccygeus.* Upwardly projecting process formed by the articular process. E



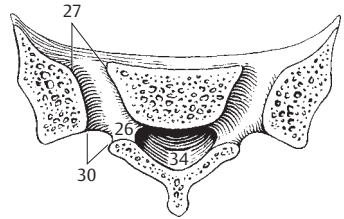
A Atlas, superior view



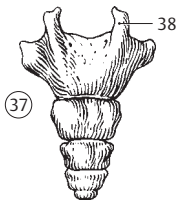
B Axis from left



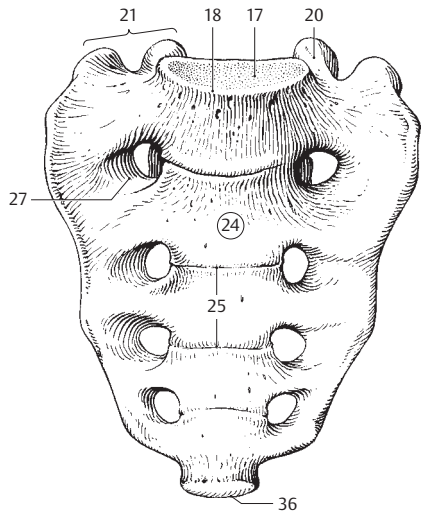
C Sacral bone, dorsal view



D Sacral bone, cross-section

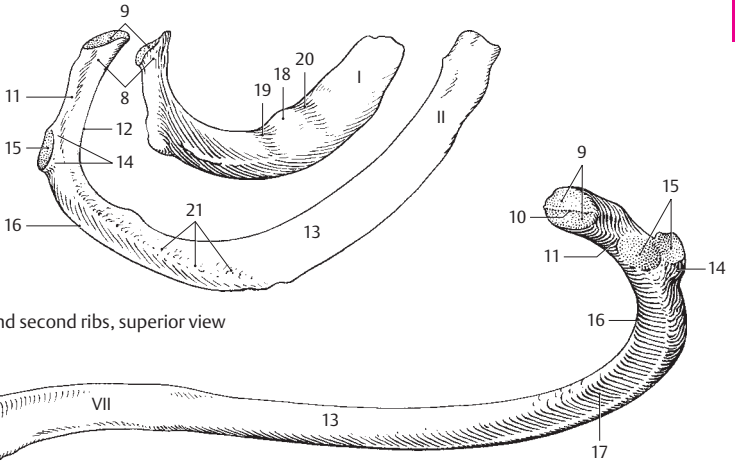


E Coccyx, dorsal view



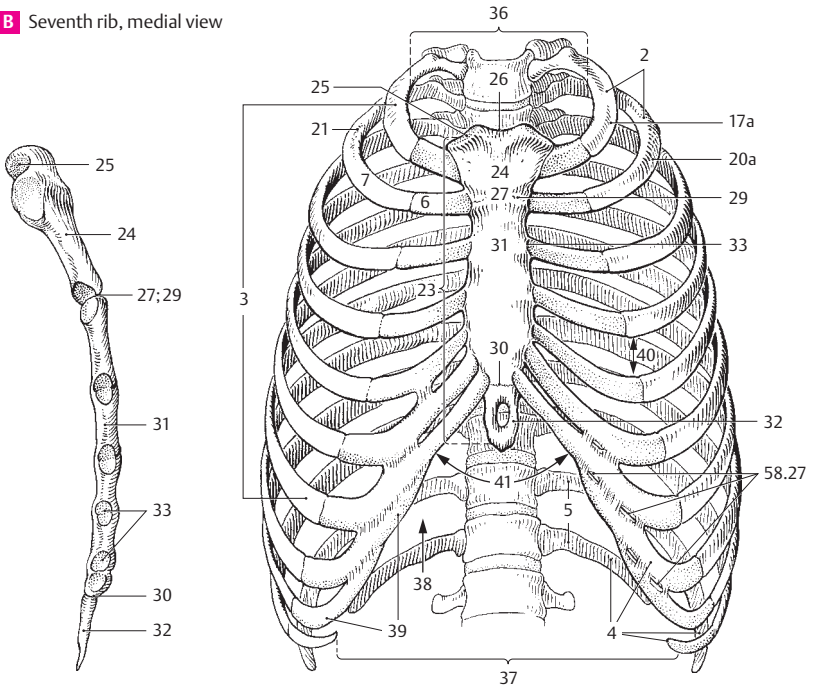
F Sacral bone, anterior view

- 1 **[THORAX]** Used to denote the chest and wall consisting of ribs, cartilage and soft tissue that encases the chest cavity.
- 1 **THORACIC BONES.** Ossa thoracis.
- 2 **RIBS.** Costae (I–XII). D
- 3 **True ribs (1–7).** Costae verae (I–VII). The first seven ribs with individual cartilaginous connections to the sternum thereby distinguishing them from the last five ribs. D
- 4 **False ribs (8–12).** Costae spuriae (VIII–XII). The last five ribs which have no direct cartilaginous union with the sternum. D
- 5 **Floating ribs (11–12).** Costae fluitantes (XI–XII). They have no connection with the costal arch (arch of ribs). D
- 6 **Costal cartilage.** Cartilago costalis. Cartilage at the anterior ends of the ribs. D
- 7 **Bony rib.** Os costale (costa). It is contrasted with the cartilaginous segment of the rib. D
- 8 **Head of rib.** Caput costae. It articulates with the vertebral column. A
- 9 **Articular surface on head of rib.** Facies articulares capitis costae. A B
- 10 **Interarticular crest on head of rib.** Crista capitis costae. Small ridge which separates the two articular facets. B
- 11 **Neck of rib.** Collum costae. It lies lateral to the head of the rib. A B
- 12 **Crest of neck of rib.** Crista colli costae. Sharp ridge on the upper border of the neck of a rib. A
- 13 **Shaft (body) of rib.** Corpus costae. Main part of rib adjacent to the neck. A B
- 14 **Costal tubercle.** Tuberculum costae. Posterior elevation between the neck and the shaft of the rib. A B
- 15 **Articular facet of costal tubercle.** Facies articularis tuberculi costae. Surface for articulation with the transverse process of the thoracic vertebrae. A B
- 16 **Angle of rib.** Angulus costae. Posteriorly situated bend in the axis of the rib. A B
- 17 **Costal groove.** Sulcus costae. Groove for the intercostal artery, vein and nerve on the lower margin of the internal surface of the rib. B
- 17a **First rib.** Costa prima. It is the only rib bent only along the edge. A D
- 18 **Tubercle for anterior scalene muscle.** Tuberculum musculi scaleni anterioris. Small prominence on the upper surface of the first rib for the attachment of the anterior scalene muscle. A
- 19 **Groove for subclavian artery.** Sulcus arteriae subclaviae. Groove on the first rib, just posterior to the anterior scalene tubercle. A
- 20 **Groove for subclavian vein.** Sulcus venae subclaviae. Groove on the first rib, just anterior to the anterior scalene tubercle. A
- 20a **Second rib.** Costa secunda. It attaches to the sternal angle and can easily be identified in patients. A D
- 21 **Tuberositas musculi serrati anterioris.** Roughened area on the outer surface of the shaft of the second rib that gives attachment to the serratus anterior muscle. A D
- 22 **Cervical rib.** [Costa cervicalis]. Accessory rib at C7. It can irritate the nerves to the arm.
- 23 **Sternum.** C D
- 24 **Manubrium sterni.** The portion of the sternum situated above the sternal angle. C D
- 25 **Clavicular notch.** Incisura clavicularis. Indentation for the sternoclavicular joint. C D
- 26 **Jugular notch.** Incisura jugularis. Concavity at the upper border of the manubrium. D
- 27 **Sternal angle.** Angulus sterni (sternalis) [Ludovici]. Angle between the body and manubrium of the sternum. It is palpable through the skin. C D
- 28 **Sternal synchondroses.** Synchondroses sternales. The two synchondroses of the sternum are as follows:
- 29 **Manubriosternal synchondrosis.** [Synchondrosis manubriosternalis]. Cartilaginous joint between the manubrium and the body of the sternum. C D
- 30 **Xiphisternal synchondrosis.** Synchondrosis xiphisternalis. Cartilaginous joint between the body of the sternum and the xiphoid process. C D
- 31 **Body of sternum.** Corpus sterni. Situated between the manubrium and xiphoid process. C D
- 32 **Xiphoid process.** Processus xiphoideus. Stout process at the lower end of the sternum. C D
- 33 **Costal notches.** Incisurae costales. Indentations for the costal cartilages. C D
- 34 **Suprasternal bones.** [Ossa suprasternalia]. Small osseous remnants of the earlier episternum occurring in the ligaments of the sternoclavicular joint.
- 35 **Thoracic skeleton.** Compages thoracis.
- 35a **Thoracic cavity.** Cavitas thoracis. Used to denote the chest and chest cavity.
- 36 **Superior thoracic aperture (thoracic inlet).** Apertura thoracis superior. Upper thoracic opening. D
- 37 **Inferior thoracic aperture (thoracic outlet).** Apertura thoracis inferior. Lower opening of thorax. D
- 38 **Pulmonary sulcus of thorax.** Sulcus pulmonalis thoracis. Either of two large, vertical grooves on either side of the vertebral column that are occupied by the lungs. D
- 39 **Costal arch.** Arcus costalis. Arch of ribs formed by the cartilages of ribs 7–10. D
- 40 **Intercostal space.** Spatium intercostale. Space between the ribs. D
- 41 **Infrasternal angle.** Angulus infrasternalis. Angle between the right and left costal arch. D



A First and second ribs, superior view

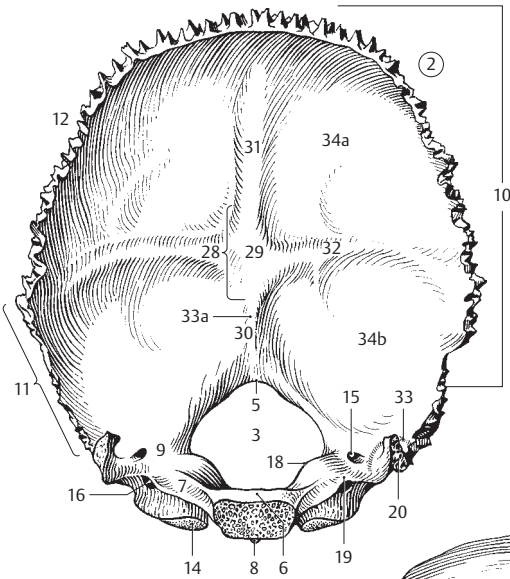
B Seventh rib, medial view



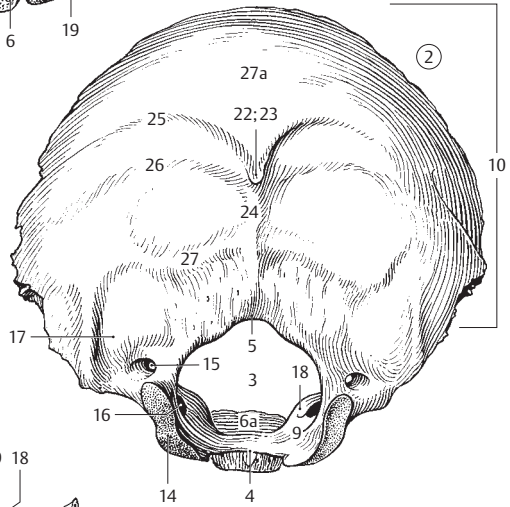
C Sternum from right

D Thoracic skeleton, anterior view

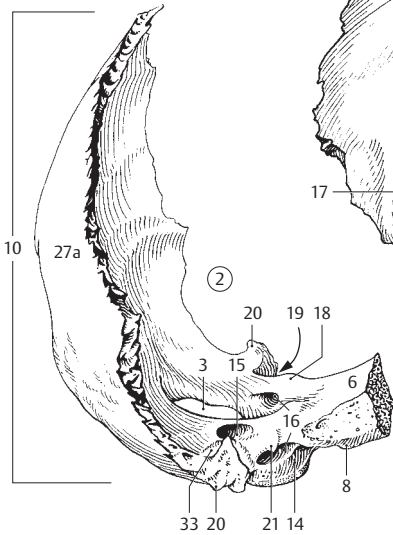
- 1 **Cranial bones.** Ossa cranii. Bones of the skull.
- 1a **Neurocranium.** Portion of the cranium that encloses the brain.
- Viscerocranium.** Portion of the cranium that forms the face.
- Chondrocranium.** Cartilaginous part of embryological skull that later forms base of skull.
- 2 **Occipital bone.** Os occipitale. It lies between the sphenoid, temporal and parietal bones. A B C
- 3 **Foramen magnum.** Large opening in the occipital bone for passage of the medulla oblongata, vessels and nerves. A B C
- 4 **Basion.** Midpoint of the anterior border of the foramen magnum. B
- 5 **Opisthion.** Midpoint of the posterior border of the foramen magnum. A B
- 6 **Basilar part of occipital bone (basioccipital bone).** Pars basilaris ossis occipitalis. Portion of occipital bone that projects superiorly from foramen magnum to sphenoid bone. A C
- 6a **Clivus.** Part of the basioccipital bone that slopes upwardly from the foramen magnum to the dorsum sellae. B
- 7 **Groove for inferior petrosal sinus of occipital bone.** Sulcus sinus petrosi inferioris ossis occipitalis. A
- 8 **Pharyngeal tubercle.** Tuberculum pharyngeum. Prominence on the inferior surface of the basioccipital bone, for attachment of the pharyngeal raphe. A C
- 9 **Lateral (condylar) part of occipital bone.** Pars lateralis ossis occipitalis. It lies lateral to the foramen magnum. A B
- 10 **Squamous part of occipital bone.** Squama occipitalis. Area extending from the posterior edge of the foramen magnum. A B C
- 11 **Mastoid margin.** Margo mastoideus. The border of the occipital bone united with the temporal bone. A
- 12 **Lambdoid margin.** Margo lambdoideus. The border of the occipital bone that articulates with the parietal bone. A
- 13 **Interparietal bone.** [Os interparietale]. Anatomic variant that forms when the upper half of the squama occipitalis is separated by a transverse suture.
- 14 **Occipital condyle.** Condylus occipitalis. Process on the occipital bone, for articulation with the atlas. A B C
- 15 **Condylar canal.** Canalis condylaris. Passage located posterior to the occipital condyle, for transmission of a vein from the sigmoid sinus. A B C
- 16 **Hypoglossal canal.** Canalis hypoglossalis. Passage that originates from the lateral part of the occipital bone anterior to the foramen magnum and ends outside, anterior to the occipital condyle. It transmits the twelfth cranial nerve and the venous plexus. A B C
- 17 **Condylar fossa.** Fossa condylaris. Depression posterior to the occipital condyle. B
- 18 **Jugular tubercle.** Tuberculum jugulare. Small eminence above the hypoglossal canal. A B C
- 19 **Jugular notch.** Incisura jugularis. Indentation for the jugular foramen. A C
- 20 **Jugular process.** Processus jugularis. Externally and internally visible process that projects laterally from the jugular foramen. It corresponds to the transverse process of a vertebra. A C
- 21 **Intrajugular process of occipital bone.** Processus intrajugularis ossis occipitalis. It occasionally divides the jugular foramen into a lateral portion for the internal jugular vein and a medial segment for nerves. C
- 22 **External occipital protuberance.** Protuberantia occipitalis externa. Readily palpable bony projection in the middle of the occipital bone. B
- 23 **Inion.** Anthropometric landmark indicating the most prominent point on the external occipital protuberance. B
- 24 **External occipital crest.** Crista occipitalis externa. Bony ridge occasionally present between the external occipital protuberance and the foramen magnum. B
- 25 **Highest (supreme) nuchal line.** Linea nuchalis suprema. Line arching externally from the upper margin of the external occipital protuberance. It gives attachment to the occipital belly of the epicranium muscle. B
- 26 **Superior nuchal line.** Linea nuchalis superior. Transverse ridge at the level of the external occipital protuberance. The trapezius muscle attaches between it and the highest nuchal line. B
- 27 **Inferior nuchal line.** Linea nuchalis inferior. Transverse ridge between the superior nuchal line and the foramen magnum. The semispinalis capitis muscle attaches between it and the superior nuchal line. B
- 27a **Occipital plane.** Planum occipitale. Outer surface of the occipital bone located superior to the external occipital protuberance. B C
- 28 **Cruciform eminence.** Eminentia cruciformis. Cross-shaped bony prominence with the internal occipital protuberance at its center. A
- 29 **Internal occipital protuberance.** Protuberantia occipitalis interna. Midpoint of the cruciform eminence. A
- 30 **Internal occipital crest.** [Crista occipitalis interna]. Thick bony ridge that occasionally extends from the internal occipital protuberance to the foramen magnum. A
- 31 **Groove for superior sagittal sinus.** Sulcus sinus sagittalis superioris. A
- 32 **Groove for transverse sinus.** Sulcus sinus transversi. A
- 33 **Groove for the sigmoid sinus.** Sulcus sinus sigmoidei. Groove that begins before the sigmoid sinus enters the jugular foramen. A C
- 33a **Groove for occipital sinus.** Sulcus sinus occipitalis. A
- 34 **Paramastoid process.** [Processus paramastoideus]. Prominence that occasionally projects from the jugular process in the direction of the transverse process of the atlas.
- 34a **Cerebral fossa.** Fossa cerebialis. Depression for the occipital lobes of the cerebrum. A
- 34b **Cerebellar fossa.** Fossa cerebellaris. Depression for the cerebellum. A



A Occipital bone, internal surface

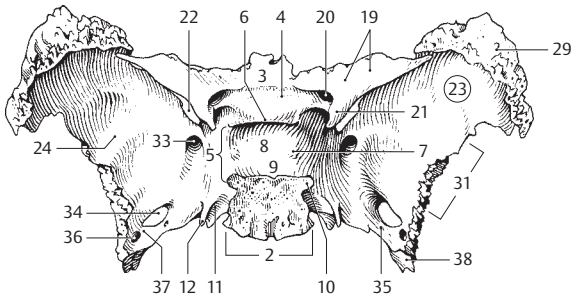


B Occipital bone, inferoposterior view

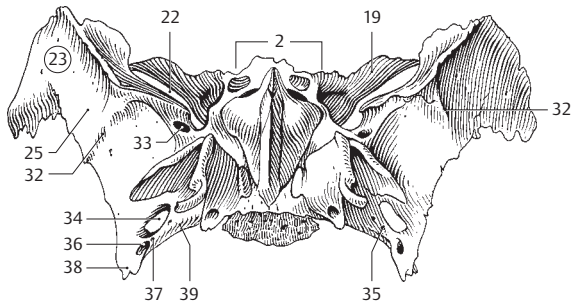


C Occipital bone, dextralateral and partly anterior view

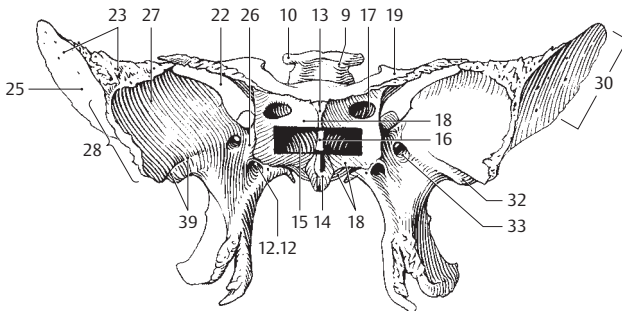
- 1 **Sphenoid bone.** Os sphenoidale. Bone located between the frontal, occipital and temporal bones. A B C
- 2 **Body of sphenoid bone.** Corpus ossis sphenoidalis. Part located between the winged processes of the sphenoid bone. A B
- 3 **Jugum sphenoidale.** Connects the lesser wings of the sphenoid. A
- 4 **(Pre)chiasmatic groove.** Sulcus prechiasmaticus. Groove between the right and left optic canals. A
- 5 **Turkish saddle.** Sella turcica. It lies above the sphenoidal sinus and contains the hypophysis. A
- 6 **Tuberculum sellae.** Small process in front of the hypophysial fossa. A
- 7 **Middle clinoid process.** [Processus clinoides medius]. Either of two small protuberances occasionally present, one on either side of the floor of the hypophysial fossa. A
- 8 **Hypophysial fossa.** Fossa hypophysialis. Fossa occupied by the hypophysis. A
- 9 **Dorsum sellae.** Posterior wall of the hypophysial fossa. A C
- 10 **Posterior clinoid process.** Processus clinoides posterior. Either of two processes that extend from either side of the dorsum sellae. A C
- 11 **Carotid groove.** Sulcus caroticus. Longitudinal groove lateral to the body of the sphenoid bone that lodges the internal carotid artery. A
- 12 **Lingula sphenoidalis.** Pointed process lateral to the entrance of the internal carotid artery into the cranial fossa. A
- 13 **Sphenoidal crest.** Crista sphenoidalis. Median bony ridge on the anterior surface of the body of the sphenoid bone that articulates with the perpendicular plate of the ethmoid. C
- 14 **Sphenoidal rostrum.** Rostrum sphenoidale. Downward continuation of the sphenoidal crest that articulates with the vomer. C
- 15 **Sphenoidal sinus.** Sinus sphenoidalis. Either of the paired paranasal sphenoidal sinuses. C
- 16 **Septum of sphenoidal sinus.** Septum intersinuale sphenoidale. Partition separating the sinus into right and left parts. C
- 17 **Aperture of sphenoidal sinus.** Apertura sinus sphenoidalis. Orifice that opens anteriorly into the speno-ethmoidal recess. C
- 18 **Sphenoidal concha.** Concha sphenoidalis. Originally paired, concave bony plate which fuses with the body of the sphenoid and forms part of the anterior and inferior wall of the sphenoidal sinus and other structures. C
- 19 **Lesser wing of sphenoid.** Ala minor ossis sphenoidalis. A B C
- 20 **Optic canal.** Canalis opticus. Canal for the optic nerve and the ophthalmic artery. A
- 21 **Anterior clinoid process.** Processus clinoides anterior. Cone-like process on either side of the anterior part of the hypophysial fossa. A
- 22 **Superior orbital fissure.** Fissura orbitalis superior. Cleft between the greater and lesser wings of the sphenoid for the passage of nerves and veins. A B C
- 23 **Greater wing of sphenoid.** Ala major ossis sphenoidalis. A B C
- 24 **Cerebral surface.** Facies cerebrialis. Surface of the greater wing facing the brain. A
- 25 **Temporal surface.** Facies temporalis. Outward surface of the greater wing. B C
- 26 **Maxillary surface.** Facies maxillaris. Surface of the greater wing facing the maxilla. The foramen rotundum opens here. C
- 27 **Orbital surface.** Facies orbitalis. Surface of the greater wing facing the orbit. C
- 28 **Zygomatic border.** Margo zygomaticus. Margin of the greater wing articulating with the zygomatic bone. C
- 29 **Frontal border.** Margo frontalis. Margin of the greater wing fused with the frontal bone. A
- 30 **Parietal border.** Margo parietalis. Margin of the greater wing fused with the parietal bone. C
- 31 **Squamous border.** Margo squamosus. Squamous margin of the greater wing that articulates with the temporal bone. A
- 32 **Infratemporal crest.** Crista infratemporalis. Bony ridge between the vertical temporal surface and the horizontally-oriented inferior surface of the greater wing of the sphenoid. B C
- 33 **Foramen rotundum.** Round opening in the great wing that extends anteriorly into the pterygopalatine fossa. It transmits the maxillary nerve. A B C
- 34 **Foramen ovale.** Opening for passage of the mandibular nerve in the medial part of the great wing, located in front of the foramen spinosum. A B
- 35 **[Foramen venosum].** Opening occasionally present medial to the foramen ovale for passage of an emissary vein from the cavernous sinus. A B
- 36 **Foramen spinosum.** Opening situated lateral to and behind the foramen ovale for passage of the middle meningeal artery. A B
- 37 **[Foramen petrosum].** [Canaliculus innominatus.] Opening occasionally present between the foramen ovale and the foramen spinosum for transmission of the lesser petrosal nerve. A B
- 38 **Angular spine of sphenoid.** Spina ossis sphenoidalis. Sharp, bony spur that extends downward from the greater wing. A B
- 39 **Groove for the cartilaginous part of the auditory tube.** Sulcus tubae auditoriae (auditi-vae). Shallow groove on the underside of the greater wing lateral to the root of the pterygoid process. B



A Sphenoid bone, superior view

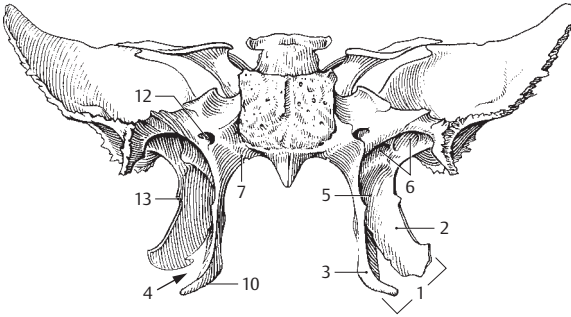


B Sphenoid bone, anteroinferior view

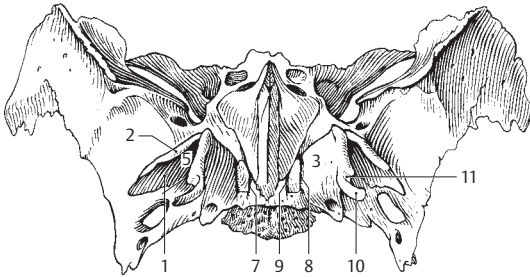


C Sphenoid bone, frontal view.
Sphenoidal sinus, fenestrated

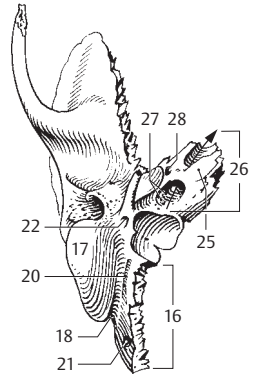
- 1 **Pterygoid process of the sphenoid bone.** Processus pterygoideus. A B
- 2 **Lateral pterygoid plate.** Lamina lateralis [processus pterygoidei]. A B
- 3 **Medial pterygoid plate.** Lamina medialis [processus pterygoidei]. A B
- 4 **Pterygoid notch (fissure).** Incisura pterygoidea. Fissure formed inferiorly by the diverging medial and lateral pterygoid plates. It is occupied by the pyramidal process of the palatine bone. A
- 5 **Pterygoid fossa.** Fossa pterygoidea. Space between the lateral and medial pterygoid plates for the medial pterygoid muscle. A B
- 6 **Scaphoid fossa.** Fossa scaphoidea. Oblong depression at the root of the medial pterygoid plate, where the end of the cartilage of the pharyngotympanic tube is located. The tensor veli palatini muscle originates at its lateral end. A
- 7 **Vaginal process.** Processus vaginalis. Small bony ridge medial to the root of the medial pterygoid plate. It borders a small furrow laterally. A B
- 8 **Palatovaginal groove.** Sulcus palatovaginalis. Groove which joins the palatine bone to form the palatovaginal canal. B
- 9 **Vomerovaginal groove.** Sulcus vomerovaginalis. Groove at the base of the pterygoid process. Together with the vomer, it forms the vomerovaginal canal. B
- 10 **Pterygoid hamulus.** Hamulus pterygoideus. Hook-like process at the inferior end of the medial pterygoid plate. A B
- 11 **Sulcus of pterygoid hamulus.** Sulcus hamuli pterygoidei. Groove produced by a sharp bend in the hamulus. B
- 12 **Pterygoid (vidian) canal.** Canalis pterygoideus [[canalis Vidii]]. Passage that extends anteriorly in the base of the pterygoid process for transmission of the greater and deep petrosal nerves to the pterygopalatine ganglion in the pterygopalatine fossa. A see 11 C
- 13 **Pterygospinous process.** Processus pterygospinosus. Sharp spine on the posterior edge of the lateral pterygoid plate. A
- 14 **Temporal bone.** Os temporale. Bone that lies between the occipital, sphenoid and parietal bones and consists of three parts: petrous, tympanic and squamous. C D E
- 15 **Petrous part (pyramid) of temporal bone.** Pars petrosa ossis temporalis. It houses the inner ear. D
- 16 **Occipital border.** Margo occipitalis. Margin articulating with the occipital bone. C D
- 17 **Mastoid process.** Processus mastoideus. Process located just posterior to the external acoustic meatus. C E
- 18 **Mastoid notch.** Incisura mastoidea. Medial notch on the inferior surface of the mastoid process. It gives origin to the posterior belly of the digastric muscle. C
- 19 **Groove for sigmoid sinus.** Sulcus sinus sigmoidei. Sulcus on the internal, posterior surface. D
- 20 **Groove for occipital artery.** Sulcus a. occipitalis. It lies medial to the mastoid notch and proximal to the occipital margin. C
- 21 **Mastoid foramen.** Foramen mastoideum. Opening behind the mastoid process for additional venous drainage from the cranial cavity. C D
- 22 **Facial canal.** Canalis facialis. Canal for the facial nerve. It begins at the opening of the internal acoustic meatus and ends at the stylomastoid foramen. C D E
- 23 **Genu of facial canal.** Geniculum canalis facialis. Sharp bend in the facial canal just below the anterior wall of the petrous part of the temporal bone, near the hiatus of the canal for the greater petrosal nerve. D
- 24 **Canaliculus of chorda tympani nerve.** Canaliculus chordae tympani. Narrow passageway for the chorda tympani nerve between the facial canal and the tympanic cavity. D E. Cf. page 381 D
- 25 **Apex of petrous temporal bone.** Apex partis petrosae. It is directed anteromedially. C D
- 26 **Carotid canal.** Canalis caroticus. Canal for the internal carotid artery. It begins inferiorly and externally between the jugular foramen and the musculotubal canal. C
- 27 **Caroticotympanic canaliculi.** Canaliculi caroticotympanici. Small channels in the wall of the carotid canal for arterial and nerve branches to the middle ear from the internal carotid artery and the carotid plexus. C
- 28 **Musculotubal canal.** Canalis musculotubarius. Double canal for the auditory tube and tensor tympani muscle. It lies in front of the carotid canal and leads into the tympanic cavity. C E
- 29 **Semicanal for tensor tympani muscle.** Semicanalis m. tensoris tympani. E
- 30 **Semicanal for the auditory tube.** Semicanalis tubae auditoriae (auditivae). E
- 31 **Septum of musculotubal canal.** Septum canalis musculotubarii. Bony partition between the above-mentioned semicanals. E



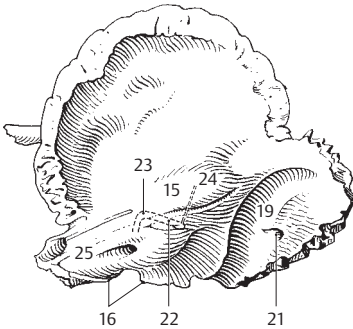
A Sphenoid bone, posterior view



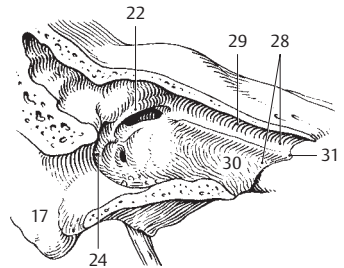
B Sphenoid bone, inferior view



C Right temporal bone, inferior view



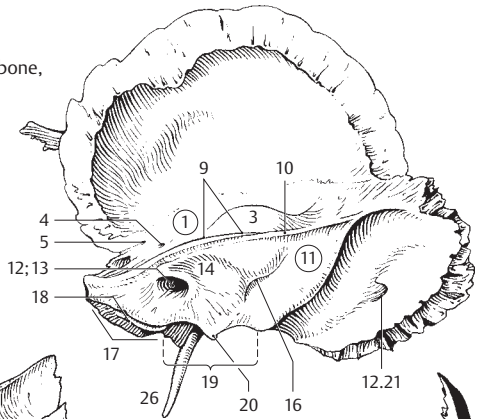
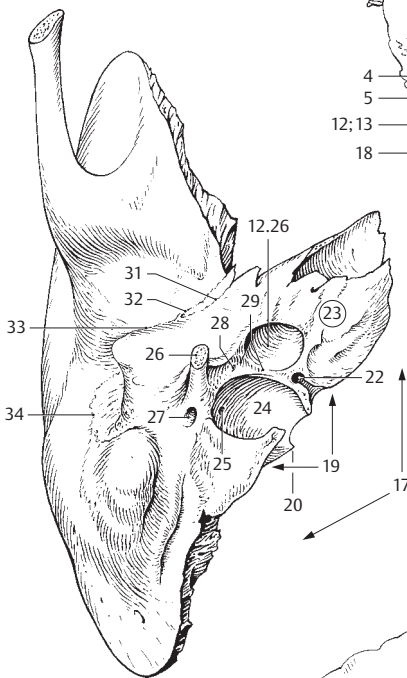
D Right temporal bone, internal surface



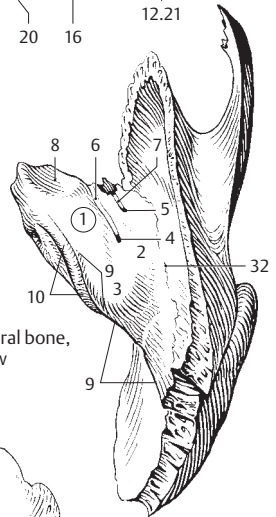
E Right temporal bone, opened. Anterolateral view

- 1 **Anterior surface of petrous part of temporal bone.** *Facies anterior partis petrosae.* A C
- 2 **Roof of tympanic cavity.** *Tegmen tympani.* Thin bony plate anterolateral to the arcuate eminence. C
- 3 **Arcuate eminence.** *Eminentia arcuata.* Elevation on the anterior surface of the petrous part of the temporal bone produced by the underlying anterior semicircular canal. A C
- 4 **Hiatus of canal for greater petrosal nerve.** *Hiatus canalis n. petrosi majoris.* Opening in the anterior wall of the petrous part of the temporal bone for passage of the greater petrosal nerve. A C
- 5 **Hiatus of canal for lesser petrosal nerve.** *Hiatus canalis n. petrosi minoris.* Opening in the anterior wall of the petrous temporal below the greater petrosal nerve. A C
- 6 **Groove for greater petrosal nerve.** *Sulcus n. petrosi majoris.* It runs anteromedially from the hiatus to the foramen lacerum. C
- 7 **Groove for lesser petrosal nerve.** *Sulcus n. petrosi minoris.* Groove for the lesser petrosal nerve, running from the respective hiatus to the foramen lacerum. C
- 8 **Trigeminal impression.** *Impressio trigeminalis.* Shallow depression in the anterior wall of the apex of the petrous part of the temporal bone. It lodges the trigeminal [semilunar] ganglion. C
- 9 **Superior border of petrous temporal bone.** *Margo superior partis petrosae.* A C
- 10 **Groove for superior petrosal sinus.** *Sulcus sinus petrosi superioris.* Its course is on the upper margin of the petrous part of the temporal bone. A C
- 11 **Posterior surface of petrous part of temporal bone.** *Facies posterior partis petrosae.* A
- 12 **Porus acusticus internus.** Opening of internal acoustic meatus on the posterior wall of the petrous part of the temporal bone. A
- 13 **Internal acoustic (auditory) meatus.** *Meatus acusticus internus.* It transmits cranial nerves VII and VIII and vessels. A
- 14 **Subarcuate fossa.** *Fossa subarcuata.* Depression lateral and superior to the internal acoustic meatus. In the fetus, it lodges the flocculus of the cerebellum. A
- 15 **Aqueduct of vestibule.** *Aqueductus vestibuli.* Narrow canal extending from the endolymphatic space of the inner ear to the posterior wall of the petrous part of the temporal bone.
- 16 **External opening of vestibular aqueduct.** *Apertura externa aqueductus vestibuli.* A
- 17 **Posterior border of petrous part of the temporal bone.** *Margo posterior partis petrosae.* A B
- 18 **Groove for inferior petrosal sinus.** *Sulcus sinus petrosi inferioris.* A
- 19 **Jugular notch.** *Incisura jugularis.* Indentation forming the anterior margin of the jugular foramen. A B
- 20 **Intrajugular process.** *Processus intrajugularis.* It divides the jugular foramen into a posterolateral part for the internal jugular vein and an anteromedial part for cranial nerves IX, X and XI. A B
- 21 **Cochlear canaliculus.** *Canaliculus cochleae.* Bony canal for the cochlear aqueduct.
- 22 **External opening of cochlear canaliculus.** *Apertura externa canaliculi cochleae.* It lies medially in front of the jugular fossa. B
- 23 **Inferior surface of petrous temporal bone.** *Facies inferior partis petrosae.* B
- 24 **Jugular fossa.** *Fossa jugularis.* Enlargement of the jugular foramen for the superior bulb of the internal jugular vein. B
- 25 **Mastoid canaliculus.** *Canaliculus mastoideus.* Narrow canal for the auricular branch of the vagus nerve. It begins in the jugular fossa. B
- 26 **Styloid process.** *Processus styloideus.* Long process located laterally in front of the jugular fossa. It is a vestige of the second branchial arch. A B D
- 27 **Stylomastoid foramen.** *Foramen stylomastoideum.* External opening of the facial canal located behind the styloid process and between the mastoid process and the jugular fossa. B
- 28 **Tympanic canaliculus.** *Canaliculus tympanicus.* Minute canal in the petrosal fossula traversed by the tympanic nerve and inferior tympanic artery. B
- 29 **Petrosal fossula.** *Fossula petrosa.* Slight depression in the bony ridge between the carotid canal and the jugular fossa. It is occupied by the tympanic ganglion of the glossopharyngeal nerve. B
- 30 **Tympanic (middle ear) cavity.** *Cavitas tympanica.* Narrow, air-filled space between the osseous labyrinth and the tympanic membrane.
- 31 **Petrotympanic fissure [glaserian fissure].** *Fissura petrotympanica.* Fissure situated dorsomedial to the fossa of the temporomandibular joint, between the tympanic part of the temporal bone and the visible petrous strip. The medial part lodges the chorda tympani nerve. B D
- 32 **Petrosquamous fissure.** *Fissura petrosquamosa.* It lies on the skull base in front of the petrotympanic fissure between the visible petrous strip and the squamous part of the temporal bone. B C
- 33 **Squamotympanic fissure.** *Fissura tympanosquamosa.* Lateral continuation of the two above mentioned fissures after they unite. B D
- 34 **Tympanomastoid fissure.** *Fissura tympanomastoidea.* Suture between the tympanic part of the temporal bone and the mastoid process. Exit site of the auricular branch of the vagus nerve. B D

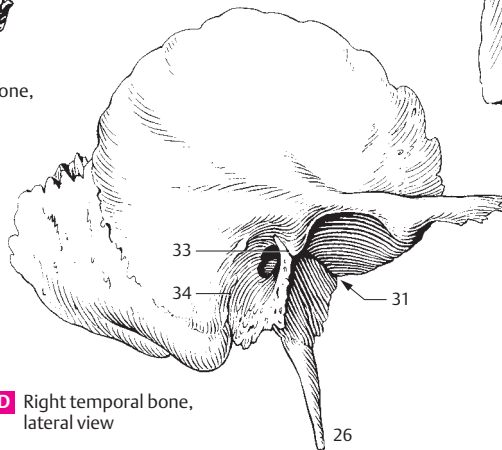
A Right temporal bone, medial view



C Right temporal bone, superior view

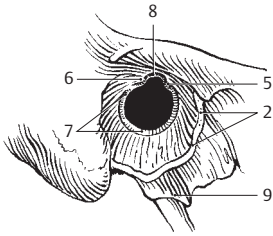


B Right temporal bone, posterior view

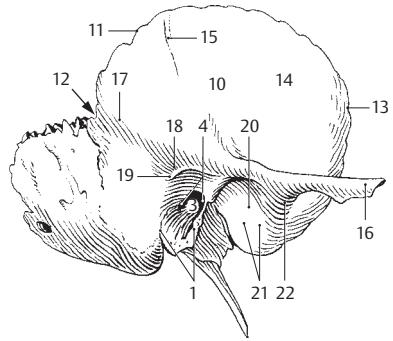


D Right temporal bone, lateral view

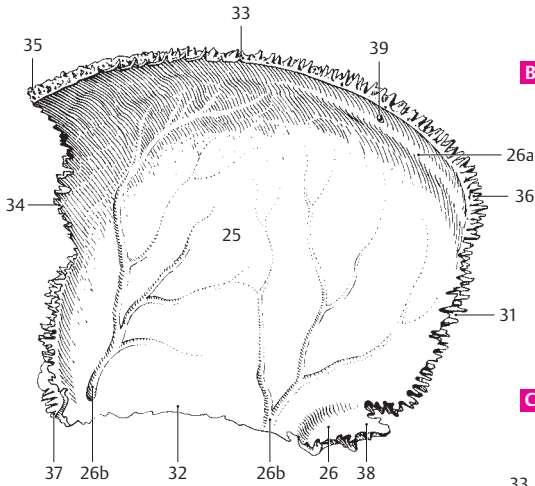
- 1 **Tympanic part of temporal bone.** Pars tympanica. Wall of the bony external acoustic meatus with the exception of the posterior, upper wall (tympanic notch). B
- 2 **Tympanic ring.** Anulus tympanicus. Bony ring which is the developmental precursor of the tympanic part of the temporal bone. The superior part is still open at birth. A
- 3 **External acoustic (auditory) meatus.** Meatus acusticus externus. B
- 4 **Opening of external acoustic meatus.** Porus acusticus externus. B
- 5 **Greater tympanic spine.** Spina tympanica major. Anterior end of the tympanic ring formed by the tympanic part of the temporal bone. A
- 6 **Lesser tympanic spine.** Spina tympanica minor. Posterior end of the ring formed by the tympanic part of the temporal bone. A
- 7 **Tympanic groove.** Sulcus tympanicus. Groove for attachment of the tympanic membrane. A
- 8 **Tympanic notch.** Incisura tympanica. Notch between the greater and lesser tympanic spines. In the newborn, it is situated superiorly in the tympanic part of the temporal bone between the free ends of the still open tympanic ring. A
- 9 **Sheath of styloid process.** Vagina processus styloidei. Ridge formed by the tympanic part of the temporal bone and partially enclosing the root of the styloid process. A
- 10 **Squamous part.** Pars squamosa. Part of the temporal bone located between the sphenoid, parietal and occipital bones. B
- 11 **Parietal border.** Margo parietalis. Upper margin articulating with the parietal bone. B
- 12 **Parietal notch.** Incisura parietalis. Indentation posteroinferior to the temporal line. B
- 13 **Sphenoidal border.** Margo sphenoidal. Anterior margin articulating with the sphenoid bone. B
- 14 **Temporal surface.** Facies temporalis. External surface covered primarily by the temporalis muscle. B
- 15 **Groove for the middle temporal artery.** Sulcus arteriae temporalis mediae. B
- 16 **Zygomatic process of temporal bone.** Processus zygomaticus. It contributes to the formation of the zygomatic arch. B
- 17 **Supramastoid crest.** Crista supramastoidea. Ridge forming the posterior boundary of the field of attachment of the temporalis muscle. B
- 18 **Suprameatal pit.** Foveola suprameatica (suprameatalis). Small pit superior to the suprameatal spine and lateral to the mastoid antrum. B
- 19 **Suprameatal spine.** [Spina suprameatica]. Projection for attachment of the auricular cartilage. B
- 20 **Mandibular fossa.** Fossa mandibularis. Depression for the head of the mandible. B
- 21 **Facies articularis.** Surface for articulation with the temporomandibular joint. B
- 22 **Articular tubercle.** Tuberculum articulare. Cylindrical elevation in front of the mandibular fossa. B
- 23 **Cerebral surface.** Facies cerebri. Inner surface of squamous part of the temporal bone facing the brain.
- 24 **Parietal bone.** Os parietale. It is located between the frontal, sphenoid and temporal bones. C D
- 25 **Internal surface.** Facies interna. The internal or cerebral surface of the parietal bone. C
- 26 **Groove for sigmoid sinus.** Sulcus sinus sigmoidei. It lies in the vicinity of the mastoid angle. C
- 26a **Groove for superior sagittal sinus.** Sulcus sinus sagittalis superioris. C
- 26b **Groove for middle meningeal artery.** Sulcus arteriae meningae mediae. C
- 27 **External surface.** Facies externa. The external surface of the parietal bone facing the scalp. D
- 28 **Superior temporal line.** Linea temporalis superior. Curved line for attachment of the temporal fascia. It forms the upper margins of the [[planum temporale]]. D
- 29 **Inferior temporal line.** Linea temporalis inferior. Curved line for attachment of the temporalis muscle. D
- 30 **Parietal tuber.** Tuber parietale. Prominence located near the middle of the external surface of the parietal bone. D
- 31 **Occipital border.** Margo occipitalis. Margin facing the occiput. C D
- 32 **Squamous border.** Margo squamosus. Inferior edge of the parietal bone. C D
- 33 **Sagittal border.** Margo sagittalis. Upper edge of parietal bone that lies in the midsagittal plane. C D
- 34 **Frontal border.** Margo frontalis. Anterior margin articulating with the frontal bone. C D
- 35 **Frontal angle.** Angulus frontalis. Anterosuperior angle of the parietal bone. C D
- 36 **Occipital angle.** Angulus occipitalis. Posterosuperior angle of the parietal bone. C D
- 37 **Sphenoidal angle.** Angulus sphenoidal. Anteroinferior angle of the parietal bone. C D
- 38 **Mastoid angle.** Angulus mastoideus. Posteroinferior angle of the parietal bone. C D
- 39 **Parietal foramen.** Foramen parietale. Opening for an emissary vein through the cranial cavity, usually located in the posterosuperior part of the parietal bone. C D



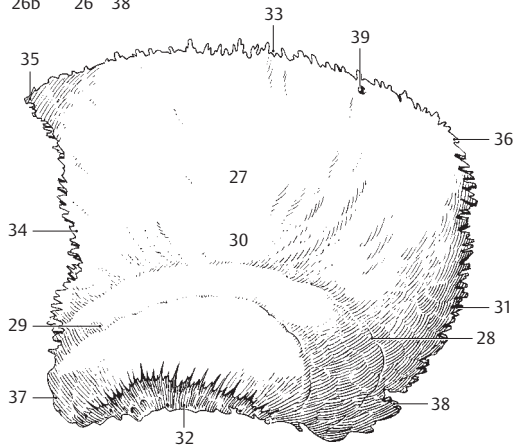
A Tympanic ring



B Right temporal bone, lateral view

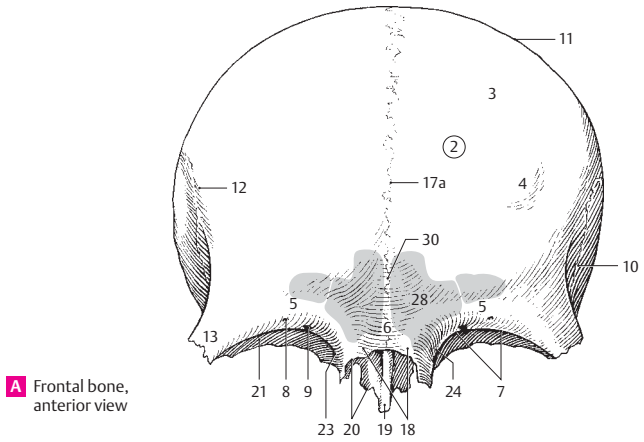


C Right parietal bone, medial view

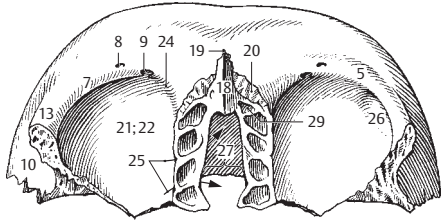


D Left parietal bone, lateral view

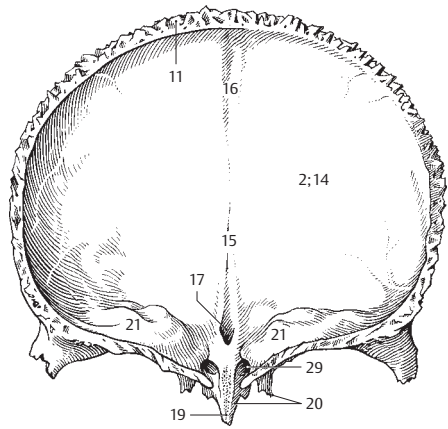
- 1 **Frontal bone.** Os frontale. A B C
- 2 **Squama of frontal bone.** Squama frontalis. A C
- 3 **External surface of frontal bone.** Facies externa. A
- 4 **Frontal tuber (tuberosity).** Tuber frontale (eminentia frontalis). A
- 5 **Superciliary arch.** Arcus superciliaris. Bony elevation above the upper margin of the orbit. A B
- 6 **Glabella.** Landmark between the two superciliary arches. A
- 6a **Frontal (metopic) suture.** [Sutura frontalis]. Cf. page 54.11
- 7 **Supraorbital border.** Margo supraorbitalis. Upper orbital margin of frontal bone. A B
- 8 **Supraorbital notch or foramen.** Incisura supraorbitalis/foramen supraorbitale. Notch or hole in the supraorbital margin for the supraorbital artery and lateral branch of the supraorbital nerve. Pressure point for the first branch of the trigeminal nerve. A B
- 9 **Frontal notch or foramen.** Incisura frontalis/foramen frontale. Notch or foramen medial to the supraorbital foramen for the supratrochlear artery and the medial branch of the supraorbital nerve. A B
- 10 **Temporal surface.** Facies temporalis. External, lateral surface of the frontal bone. A B
- 11 **Parietal border.** Margo parietalis. Posterior margin of frontal bone which articulates with the parietal bone. A C
- 12 **Temporal line of frontal bone.** Linea temporalis ossis frontalis. Continuation of the line formed by the union of the superior and inferior temporal lines of the parietal bone. A
- 13 **Zygomatic process of frontal bone.** Processus zygomaticus ossis frontalis. Process situated lateral to the orbit for articulation with the zygomatic bone. A B C
- 14 **Internal surface.** Facies interna. The internal or cerebral surface of the frontal bone. C
- 15 **Frontal crest.** Crista frontalis. A median ridge on the anterior internal surface of the frontal bone for attachment of the falx cerebri. C
- 16 **Groove for superior sagittal sinus.** Sulcus sinus sagittalis superioris. Its margins come together as it passes downward and become continuous with the frontal crest. C
- 17 **Foramen cecum.** Foramen caecum. Canal behind the frontal crest. It usually ends blindly but contains an emissary vein when patent. C
- 17a **Sutura frontalis metopica.** Persistent frontal suture in the adult. A
- 18 **Nasal part of frontal bone.** Pars nasalis ossis frontalis. Middle segment between the two orbital parts of the frontal bone. A B
- 19 **Nasal spine.** Spina nasalis. Pointed median structure projecting from the pars nasalis. A B C
- 20 **Nasal border.** Margo nasalis. Serrated lower margin of the nasal part of the frontal bone. It articulates with the right and left nasal bones. A B C
- 21 **Orbital part.** Pars orbitalis. The part of the frontal bone forming the roof of the orbit. A B C
- 22 **Orbital surface.** Facies orbitalis. The surface of the frontal bone facing the orbit. B
- 23 **Trochlear spine.** [Spina trochlearis]. Small bony spicule occasionally present on the anterosuperior part of the medial angle of the orbit for the attachment of the trochlea of the superior oblique muscle. A
- 24 **Trochlear fovea.** Fovea trochlearis. Small depression for attachment of a cartilaginous sling (trochlea or pulley) and passage of the tendon of the superior oblique muscle. A B
- 25 **Ethmoidal foramina.** Foramina ethmoidalia. Openings for the ethmoidal vessels and nerves. B Cf. page 20.12
- 26 **Fossa for lacrimal gland.** Fossa glandulae lacrimalis. Depression for the lacrimal gland in the lateral angle of the orbit. B
- 27 **Ethmoid notch.** Incisura ethmoidalis. Space between the right and left orbital parts of the frontal bone in which the ethmoid bone is lodged. B
- 28 **Frontal sinus.** Sinus frontalis. It averages 3 cm high and 2.5 cm wide and often extends 1.8 cm posteriorly, thereby forming a part of the orbital roof. A
- 29 **Opening of frontal sinus.** Apertura sinus frontalis. Medial opening on the floor of the frontal sinus for discharge of secretions into the nasal cavity. Located at the ethmoidal infundibulum below the middle nasal concha. B C
- 30 **Septum of frontal sinus.** Septum intersinuale frontale. Partition between the right and left frontal sinuses. A



A Frontal bone, anterior view

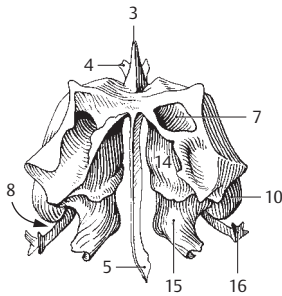


B Frontal bone, inferior view

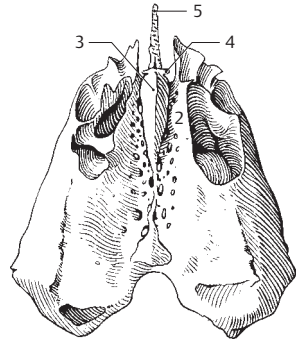


C Frontal bone, posterior view

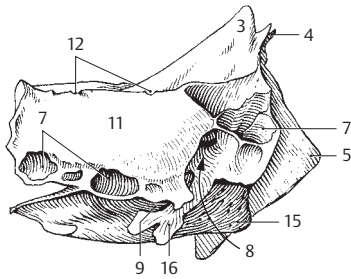
- 1 **Ethmoid bone.** Os ethmoidale. Unpaired bone in the ethmoid notch of the frontal bone. A B C D
- 2 **Cribriform plate and foramina.** Lamina et foramina cribrosa. Elongated horizontal plate occupying the median plane between the nasal cavity and the anterior cranial fossa. Its numerous foramina transmit the olfactory nerve fibers. B
- 3 **Crista galli.** Small bony process that projects upward from the anterior cranial fossa and gives attachment to the falx cerebri. A B C D
- 4 **Ala of crista galli.** Ala cristae galli. Winglike, paired process for connection of the crista galli to the frontal crest. A B C D
- 5 **Perpendicular plate.** Lamina perpendicularis. It extends downward from the ethmoid bone and forms the upper part of the nasal septum. A B C
- 6 **Ethmoidal labyrinth.** Labyrinthus ethmoidalis. Collective term for the ethmoidal air cells situated between the orbital and nasal cavities.
- 7 **Ethmoidal air cells.** Cellulae ethmoidales. A C
- 8 **Ethmoidal infundibulum.** Infundibulum ethmoidale. Narrow, oblong canal below the middle nasal concha and between the uncinat process and ethmoidal bulla. It receives the openings of the frontal and maxillary sinuses as well as the anterior ethmoidal air cells. A C
- 9 **Hiatus semilunaris.** Opening of the infundibulum that faces the nose. C
- 10 **Bulla ethmoidalis.** An anterior elevation formed by an especially large and wide ethmoidal air cell which compresses the ethmoidal infundibulum. A
- 11 **Orbital plate.** Lamina orbitalis. A very thin bony plate which forms part of the medial wall of the orbit. [[Lamina papyracea]]. C
- 12 **Ethmoidal foramina.** Foramina ethmoidalia. Holes or grooves at the border to the frontal bone for the passage of ethmoidal nerves, arteries and veins to and from the orbit. C Cf. page 18.25
- 13 **[Concha nasalis suprema].** Highest, rudimentary nasal concha. D
- 14 **Superior nasal concha.** Concha nasalis superior. A D
- 15 **Middle nasal concha.** Concha nasalis media. A C D
- 16 **Uncinate process.** Processus uncinatus. Hook-like process that extends posteriorly and inferiorly from the ethmoid bone. It is almost entirely concealed by the middle nasal concha and partially closes the semilunar hiatus. A C
- 17 **Inferior nasal concha.** Concha nasalis inferior. Independent lower nasal concha attached to the lateral nasal wall. E
- 18 **Lacrimal process.** Processus lacrimalis. Process that projects anterosuperiorly from the inferior nasal concha. E
- 19 **Maxillary process.** Processus maxillaris. Lateral process which forms a part of the medial wall of the maxillary sinus. E
- 20 **Ethmoidal process.** Processus ethmoidalis. It is united with the uncinat process of the ethmoid bone. E
- 21 **Lacrimal bone.** Os lacrimale. Bone in front of the orbital plate of the ethmoid bone. F
- 22 **Posterior lacrimal crest.** Crista lacrimalis posterior. Ridge forming the posterior border of the entrance into the nasolacrimal canal. F
- 23 **Lacrimal sulcus of lacrimal bone.** Sulcus lacrimalis. Groove-like beginning of the nasolacrimal canal. F
- 24 **Lacrimal hamulus.** Hamulus lacrimalis. Hook-like lower margin of the entrance into the nasolacrimal canal. F
- 25 **Fossa for lacrimal sac.** [[Fossa sacci lacrimalis]]. Enlarged area for the nasolacrimal sac located at the beginning of the nasolacrimal canal. F
- 26 **Nasal bone.** Os nasale. Bone between the right and left halves of the maxilla. The superior part articulates with the frontal bone. G
- 27 **Ethmoidal sulcus.** Sulcus ethmoidalis. Groove on the undersurface of the nasal bone for the external nasal branch of the anterior ethmoidal nerve. G
- 27a **Nasal foramina.** Foramina nasalia. Inconstant opening for branches of the external nasal and anterior ethmoidal nerves and vessels.
- 28 **Vomer.** Unpaired bone forming a part of the nasal septum and lying between the sphenoid, maxillary and palatine bones as well as the perpendicular plate of the ethmoid. H
- 29 **Ala of vomer.** Ala vomeris. Wing-like process for articulation with the sphenoid and palatine bones. H
- 30 **Sulcus vomeris.** Oblique groove for the nasopalatine nerve and its accompanying vessels. H
- 30a **Choanal crest of vomer.** Crista choanalis vomeris. Posterior edge of vomer separating the two choanae. H
- 30b **Cuneiform part of vomer.** Pars cuneiformis vomeris. Wedge-shaped part of vomer. H



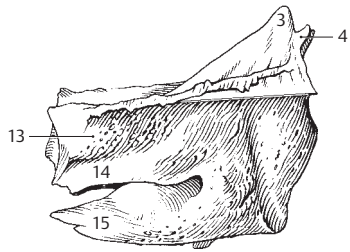
A Ethmoid bone, posterior view



B Ethmoid bone, superior view



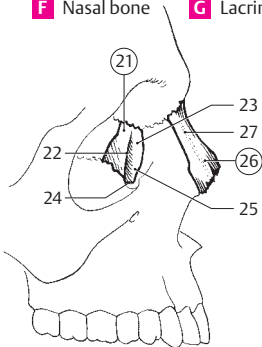
C Ethmoid bone, dextral view



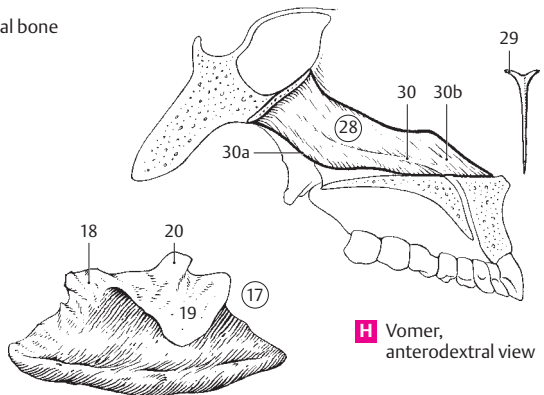
D Ethmoid bone, left half without perpendicular plate, medial view

F Nasal bone

G Lacrimal bone

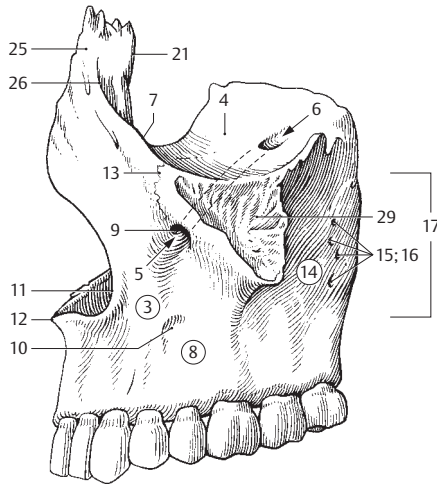


E Sinistral inferior nasal concha, lateral view

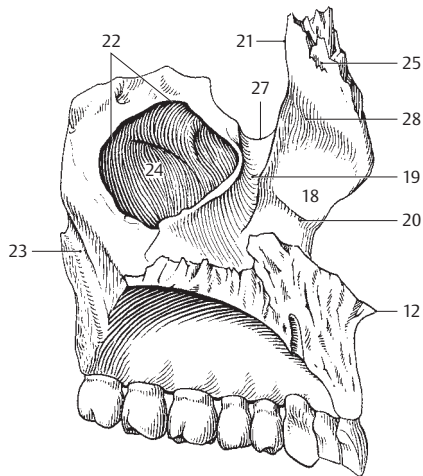


H Vomer, anterodextral view

- 1 **[[FACIAL BONES]].** [[Ossa faciei]].
- 2 **Maxilla.** Upper jaw. A B
- 3 **Body of maxilla.** Corpus maxillae. Central part of the maxilla enclosing the maxillary sinus. A
- 4 **Orbital surface.** Facies orbitalis. Surface of the maxilla forming a portion of the floor of the orbit. A
- 5 **Infraorbital canal.** Canalis infraorbitalis. Canal for the infraorbital artery and nerve. A
- 6 **Infraorbital groove.** Sulcus infraorbitalis. Groove at the beginning of the infraorbital canal. A
- 7 **Infraorbital margin.** Margo infraorbitalis. Lower margin of the orbit formed in part by the maxilla. A
- 8 **Anterior surface.** Facies anterior. A
- 9 **Infraorbital foramen.** Foramen infraorbitale. Opening of the infraorbital canal traversed by the infraorbital nerve and its accompanying artery. Pressure point for the second division of the trigeminal nerve. A
- 10 **Canine fossa.** Fossa canina. Depressed area below the infraorbital canal. Site of origin of levator anguli oris muscle. A
- 11 **Nasal notch.** Incisura nasalis. Curved margin of the bony anterior nasal (piriform) aperture. A
- 12 **Anterior nasal spine.** Spina nasalis anterior. Spinous projection at the lower boundary of the anterior nasal aperture. Attachment site of the cartilaginous nasal septum. A B
- 13 **Zygomatocomaxillary suture.** Sutura zygomaticomaxillaris. Suture occasionally present from the infraorbital margin to the infraorbital foramen. A
- 14 **Infratemporal surface.** Facies infratemporalis. Surface of the maxilla situated behind the zygomatic process. A
- 15 **Alveolar foramina.** Foramina alveolaria. Small openings on the infratemporal surface for passage of nerves and vessels to the molars. A
- 16 **Alveolar canals.** Canales alveolares. Canals leading to the alveolar foramina for the transport of nerves and vessels for the teeth. A
- 17 **Tuber of maxilla.** Tuber maxillare (eminentia maxillaris). Thin-walled tuberosity on the posterior wall of the maxillary sinus. A
- 18 **Nasal surface.** Facies nasalis. Medial surface of maxilla forming a portion of the lateral nasal wall. B
- 19 **Lacrimal sulcus.** Sulcus lacrimalis. Groove for the nasolacrimal duct. B
- 20 **Conchal crest.** Crista conchalis. Oblique ridge for attachment of the inferior nasal concha. B
- 21 **Lacrimal margin.** Margo lacrimalis. Border of the maxilla articulating with the lacrimal bone. A B
- 22 **Maxillary hiatus.** Hiatus maxillaris. Large opening in the medial bony wall of the maxillary sinus. It is bounded by the uncinata, maxillary, and ethmoidal processes and by the palatine bone. This leaves only a narrow opening to the maxillary sinus at the upper edge of its medial wall. B
- 23 **Greater palatine sulcus** **[[pterygopalatine sulcus]].** Sulcus palatinus major **[[sulcus pterygopalatinus]].** Groove at the posterior border of the maxilla. It combines with a similar groove on the palatine bone to form a canal for the greater palatine nerve and descending palatine artery. B
- 24 **Maxillary sinus.** Sinus maxillaris. Paranasal cavity within the body of the maxilla. It measures over 3 cm vertically and sagittally and 2.5 cm in the frontal plane. Its floor usually lies at least 1 cm below the floor of the nasal cavity. B
- 25 **Frontal process of maxilla.** Processus frontalis. A B
- 26 **Anterior lacrimal crest.** Crista lacrimalis anterior. Bony ridge in front of the entrance to the nasolacrimal canal. A
- 27 **Lacrimal notch.** Incisura lacrimalis. Crescent-shaped notch at the entrance to the nasolacrimal canal. B
- 28 **Ethmoidal crest.** Crista ethmoidalis. Oblique ridge on the medial surface of the frontal process for the attachment of the middle nasal concha. B
- 29 **Zygomatic process.** Processus zygomaticus. Lateral process of the maxilla for articulation with the zygomatic bone. A

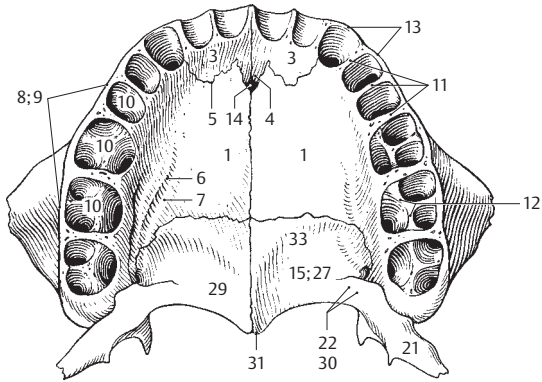


A Left maxilla, lateral view

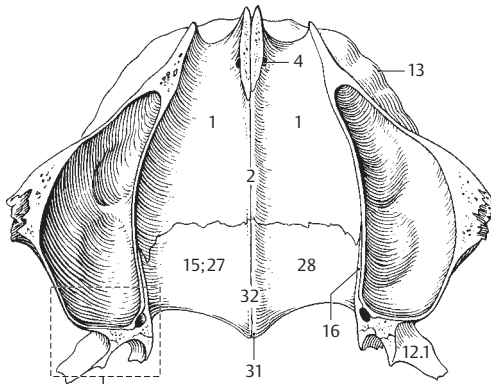


B Left maxilla, medial view

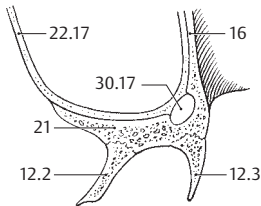
- 1 **Palatine process.** Processus palatinus. Horizontal plate which forms the largest part of the hard palate. A B
- 2 **Nasal crest.** Crista nasalis. Midline bony ridge for the attachment of the nasal septum. B
- 3 **Incisive bone (premaxilla).** [Os incisivum]. Separate fetal bone which becomes incorporated into the adult maxilla and houses the incisor teeth. A
- 4 **Incisive canal.** Canalis incisivus. It originates as a paired canal from the floor of the nasal cavity and unites with the palate in the uniform fossa incisiva. A B
- 5 **Incisive suture.** [Sutura incisiva]. Suture between the premaxilla and the palatine process of the maxilla (visible only during development). It usually extends from the incisive foramen to the space between the canine and second incisor. A
- 6 **Palatine spines.** Spinae palatinae. Bony ridges along the palatine grooves. A
- 7 **Palatine grooves.** Sulci palatini. Grooves running from posterior to anterior along the inferior surface of the palate for passage of nerves and vessels from the greater palatine foramen. A
- 8 **Alveolar process.** Processus alveolaris. Crested process that bears the teeth. A
- 9 **Alveolar arch.** Arcus alveolaris. Curved free border of the alveolar process. A
- 10 **Dental alveoli.** Alveoli dentales. Sockets in the alveolar process that house the roots of the teeth. A
- 11 **Interalveolar septa.** Septa interalveolarina. Bony ridges between adjacent alveoli. A
- 12 **Interradicular septa.** Septa interradicularia. Bony partitions, each forming compartments for the roots of a tooth. A
- 13 **Alveolar juga.** Juga alveolaria. Eminences on the external surface of the jaw produced by the protrusion of the tooth sockets. A B
- 14 **Incisive foramen.** Foramen incisivum. Opening of the incisive canal into the oral cavity. A
- 15 **Palatine bone.** Os palatinum. Bone forming the posterior continuation of the maxilla. A B D E
- 16 **Perpendicular plate.** Lamina perpendicularis. Vertical plate which forms part of the medial wall of the maxillary sinus. B C D E
- 17 **Nasal surface.** Facies nasalis. Surface of the perpendicular plate facing the nasal cavity. E
- 18 **Maxillary surface.** Facies maxillaris. Lateral surface of the perpendicular plate, parts of which border with the pterygopalatine fossa and the maxillary sinus. D
- 19 **Sphenopalatine notch.** Incisura sphenopalatina. Part of the sphenopalatine foramen at the superior margin of the perpendicular plate. D E
- 20 **Greater palatine sulcus (pterygopalatine sulcus).** Sulcus palatinus major [sulcus pterygopalatinus]. Groove which combines with the greater palatine sulcus of the maxilla to form the greater palatine canal for the greater palatine nerves and the descending palatine artery. D E
- 21 **Pyramidal process.** Processus pyramidalis. Process inserted into the pterygoid notch (fissure). A C D E
- 22 **Lesser palatine canals.** Canales palatini minores. Canals in the pyramidal process for the lesser palatine arteries and nerves. A
- 23 **Conchal crest.** Crista conchalis. Ridge for attachment of the inferior nasal concha. D E
- 24 **Ethmoidal crest.** Crista ethmoidalis. Ridge for attachment of the middle nasal concha. D E
- 25 **Orbital process.** Processus orbitalis. Process that projects forward and upward between the maxillary, ethmoid and sphenoid bones. D E
- 26 **Sphenoidal process.** Processus sphenoidalis. Process in the superior portion of the palatine bone behind the sphenopalatine notch. D E
- 27 **Horizontal plate.** Lamina horizontalis. Plate that forms the posterior portion of both the hard palate and the floor of the nasal cavity. A B D E
- 28 **Nasal surface.** Facies nasalis. Surface facing the nasal cavity. B D
- 29 **Palatine surface.** Facies palatina. Surface facing the oral cavity. A D
- 30 **Lesser palatine foramina.** Foramina palatina minora. Openings of the lesser palatine canals. A
- 31 **Posterior nasal spine.** Spina nasalis posterior. Tip of the nasal crest along the median plane at the junction with the palatine bone of the opposite side. A B E
- 32 **Nasal crest.** Crista nasalis. Median bony ridge at the union with the palatine bone of the opposite side. B D E
- 33 **Palatine crest.** Crista palatina. Ridge frequently present on the inferior surface of the horizontal plate behind its anterior margin. A



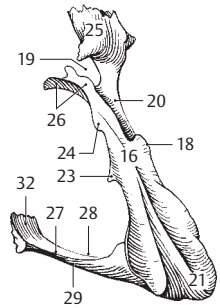
A Hard palate, view from below



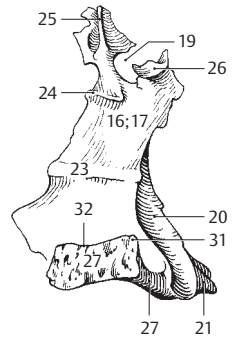
B Hard palate and maxillary sinuses (opened), superior view



C Schematic segment of B

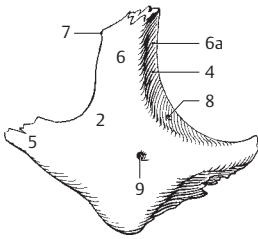


D Right palatine bone, posterolateral view

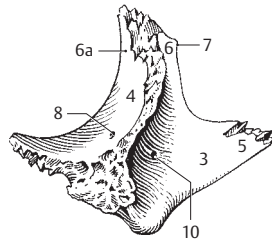


E Right palatine bone, medial view

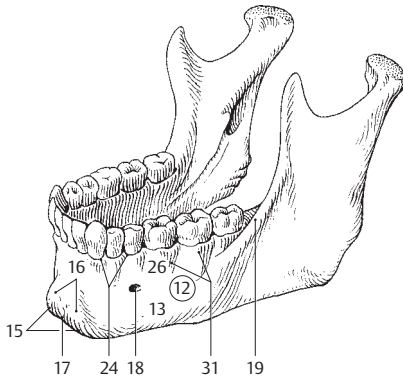
- 1 **Zygomatic bone.** Os zygomaticum. It forms a large part of the lateral wall of the orbit and a part of the zygomatic arch. A B
- 2 **Lateral surface.** Facies lateralis. A
- 3 **Temporal surface.** Facies temporalis. Surface forming much of the anterior wall of the temporal fossa. B
- 4 **Orbital surface.** Facies orbitalis. Surface facing the orbit. A B
- 5 **Temporal process.** Processus temporalis. Posteriorly directed process which combines with the zygomatic process of the temporal bone to form the zygomatic arch. A B
- 6 **Frontal process.** Processus frontalis. Process which unites with the zygomatic process of the frontal bone. A B
- 6a **Orbital eminence.** Eminentia orbitalis. Small tubercle just within the lateral margin of the orbit. Gives attachment to the lateral palpebral ligament, among others. A B
- 7 **Marginal tubercle.** [Tuberculum marginale]. Prominence usually present on the posterior margin of the frontal process. Attachment site of the temporalis muscle. A B
- 8 **Zygomatico-orbital foramen.** Foramen zygomatico-orbitale. Foramen on the orbital surface leading into a bony canal for the zygomatic nerve. A B
- 9 **Zygomaticofacial foramen.** Foramen zygomaticofaciale. Opening on the lateral surface for passage of the zygomaticofacial nerve. A
- 10 **Zygomaticotemporal foramen.** Foramen zygomaticotemporale. Foramen on the temporal surface for passage of the zygomaticotemporal nerve. B
- 11 **Mandible.** Mandibula. Lower jaw bone. C D E
- 12 **Body of mandible.** Corpus mandibulae. Horizontal part of the mandible to which the mandibular rami are attached. C
- 13 **Base of mandible.** Basis mandibulae. Lower portion of the body of the mandible minus the alveolar part. C
- 14 **Symphysis menti.** Symphysis mandibulae (medialis). Median connective tissue bridge between the right and left halves of the mandible. It becomes ossified in the first postnatal year.
- 15 **Mental protuberance.** Protuberantia mentalis. Prominence of the chin. C
- 16 **Mental tubercle.** Tuberculum mentale. Prominence on either side of the mental protuberance. C
- 17 **Gnathion.** A cephalometric landmark indicating the lowest point on the midline of the mandible. C
- 18 **Mental foramen.** Foramen mentale. Opening for the mental nerve below the second premolar. Pressure point for the third division of the trigeminal nerve. C
- 19 **Oblique line.** Linea obliqua. Oblique ridge extending from the mandibular ramus to the external surface of the body of the mandible. C
- 20 **Digastric fossa.** Fossa digastrica. A pea-to bean-sized depression on the lower internal surface of the body of the mandible near the symphysis, for attachment of the digastric muscle. D
- 21 **Mental spine.** Spina mentalis. Bony elevation at the back of the symphysis projecting toward the tongue. Origin of the genioglossus and geniohyoid muscles. D
- 22 **Mylohyoid line.** Linea mylohyoidea. Oblique ridge extending from the posterosuperior to anteroinferior aspect of the body of the mandible. Origin of the mylohyoid muscle. Its posterior end is the origin of the mylopharyngeal part of the superior constrictor muscle of the pharynx. D
- 23 **[Torus mandibularis].** Bony outgrowth above the mylohyoid line at the level of the premolars. Possible hindrance to prostheses. D
- 24 **Sublingual fovea.** Fovea sublingualis. Depression for the sublingual gland on the anterior part of the mandible above the mylohyoid line. D
- 25 **Submandibular fovea.** Fovea submandibularis. Depression for the submandibular gland on the posterior half of the body of the mandible below the mylohyoid line. D
- 26 **Alveolar part.** Pars alveolaris. Pectinate process on the base of the mandible that houses the roots of the teeth. C
- 27 **Alveolar arch.** Arcus alveolaris. Curved free margin of the alveolar part. E
- 28 **Dental alveoli.** Alveoli dentales. Sockets for reception and fixation of the roots of the teeth. E
- 29 **Interalveolar septa.** Septa interalveolaria. Bony ridges between the dental alveoli. E
- 30 **Interradicular septa.** Septa interradicularia. Bony partitions between the roots of the teeth. E
- 31 **Alveolar juga.** Juga alveolaria. Protrusions on the external surface of the mandible caused by the fan-like roots of the teeth. C E



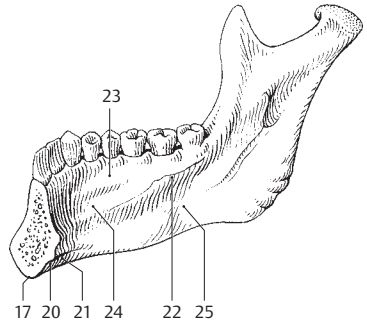
A Zygomatic bone, lateral view



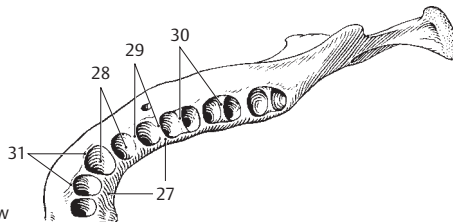
B Zygomatic bone, medial view



C Mandible

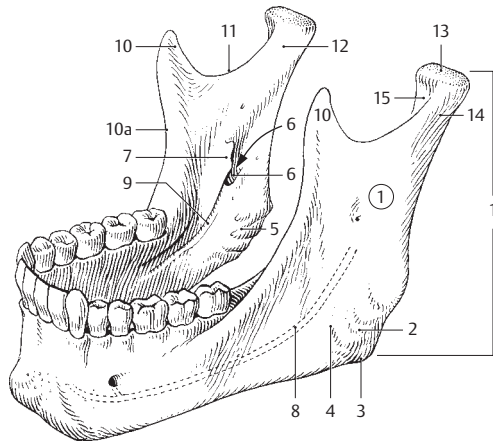


D Mandible, medial view

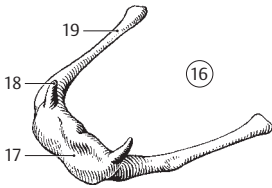


E Mandible, superior view

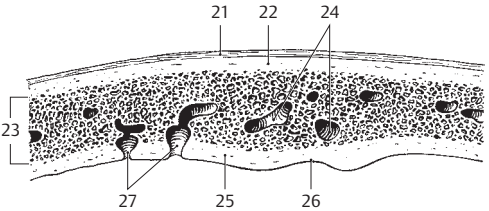
- 1 **Ramus of mandible.** Ramus mandibulae. Process that projects superiorly from the mandible. A
- 2 **Angle of mandible.** Angulus mandibulae. Angle between the body and ramus of the mandible. It is most erect in adults and very wide in newborns and toothless elderly individuals (ca. 140°). A
- 3 **Gonion.** Anthropometric landmark indicating the most inferior, posterior, and lateral point of the angle of the mandible. A
- 4 **Masseteric tuberosity.** Tuberositas masseterica. Roughened area occasionally present on the external surface of the angle of the mandible. Attachment site of the masseter muscle. A
- 5 **Pterygoid tuberosity.** Tuberositas pterygoidea. Roughened area occasionally present on the internal surface near the angle of the mandible. Attachment site of the medial pterygoid muscle. A
- 6 **Mandibular foramen.** Foramen mandibulae. Opening on the inner aspect of the mandibular ramus leading into the mandibular canal. A
- 7 **Lingula of mandible.** Lingula mandibulae. Bony projection medial to the mandibular foramen. Attachment site of the sphenomandibular ligament. A
- 8 **Mandibular canal.** Canalis mandibulae. Bony canal within the mandible for passage of the inferior alveolar artery and nerve. It begins at the mandibular foramen and passes beneath the roots of the teeth to the vicinity of the median plane. A
- 9 **Mylohyoid groove.** Sulcus mylohyoideus. Groove extending forward and downward from the mandibular foramen and housing the mylohyoid nerve and the mylohyoid branch of the inferior alveolar artery. A
- 10 **Coronoid process.** Processus coronoideus. Muscular process separated from the posteriorly situated condylar process by the mandibular notch. Attachment site of the temporalis muscle. A
- 10a **Temporal crest.** Crista temporalis. Sharp bony ridge at the anterior margin of the coronoid process for attachment of the temporalis muscle. A
- 11 **Mandibular notch.** Incisura mandibulae. Indentation between the condylar and coronoid processes. A
- 12 **Condylar process.** Processus condylaris. Articular process. A
- 13 **Head of mandible.** Caput mandibulae. Articular head of the mandible. A
- 14 **Neck of mandible.** Collum mandibulae. Narrow segment below the head of the mandible. A
- 15 **Pterygoid fovea.** Fovea pterygoidea. Anteromedial pit below the head of the mandible for attachment of the lateral pterygoid muscle. A
- 16 **Hyoid bone.** Os hyoideum. It starts to ossify before birth. B
- 17 **Body of hyoid.** Corpus ossis hyoidea. Anterior segment between the right and left (greater and lesser) horns. B
- 18 **Lesser horn (cornu).** Cornu minus. B
- 19 **Greater horn (cornu).** Cornu majus. B
- 20 **SKULL.** Cranium. D E F
- 20a **CRANIAL CAVITY.** Cavitas cranii.
- 21 **Periosteum of the external skull surface.** Pericranium. C
- 22 **External table (lamina).** Lamina externa. Outer layer of bone comprising the skull cap (calvaria). C
- 23 **Diploë.** Layer of spongy bone (spongiosa) between the external and internal tables, especially in the cranial bones. C
- 24 **Diploic canals.** Canales diploici. Large venous canals in the diploë. C
- 25 **Internal table (lamina).** Lamina interna. Inner layer of bone comprising the skull cap. C
- 26 **Groove for the superior sagittal sinus.** Sulcus sinus sagittalis superioris. C
- 27 **Granular pits (pacchionian granulations).** Foveolae granulares [[Pacchioni]]. Small pits occupied by the arachnoid granulations. C
- 28 **NORMA VERTICALIS (calvaria).** Normal outline of skull cap as viewed from above. F
- 29 **Bregma.** Point of intersection of the sagittal and coronal sutures. F
- 30 **Crown of head.** Vertex. Highest point of the vault of the skull. E
- 31 **Occiput.** Back part of the head. E F
- 32 **NORMA FACIALIS.** Normal outline of skull as viewed from in front. D
- 33 **Forehead.** Frons. Front of calvaria above the eyes. D E
- 34 **Nasion.** Median point between the intersection of frontal and nasal bones. D E



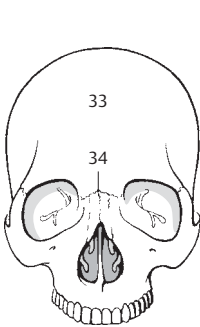
A Mandible



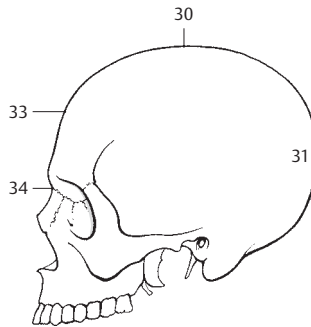
B Hyoid bone, anteriosuperior view



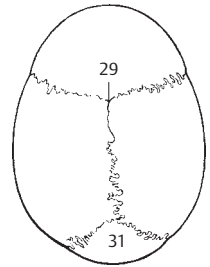
C Cross section of skull cap segment



D Norma facialis

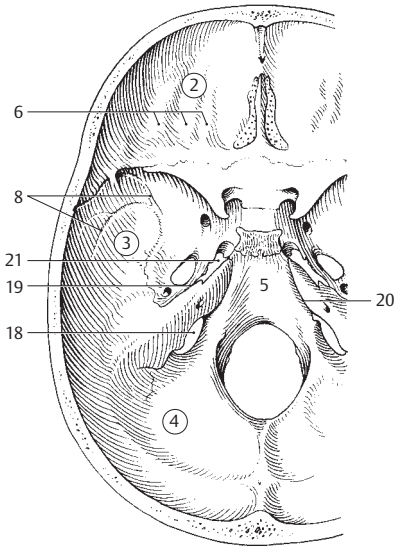


E Norma lateralis

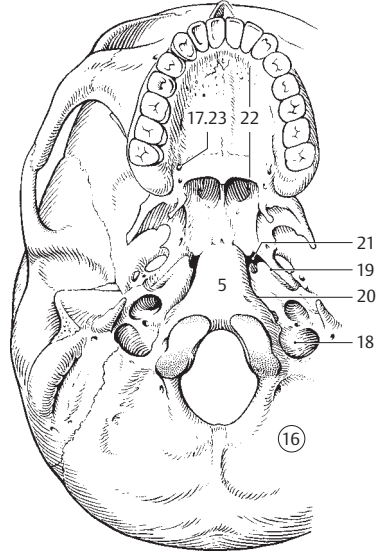


F Norma verticalis

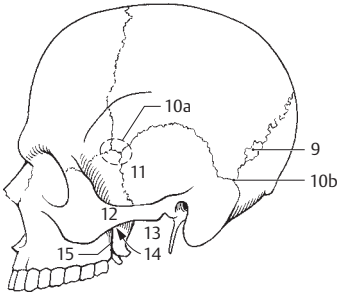
- 1 **INTERNAL BASE OF CRANIUM.** Basis cranii interna. Superior aspect of the skull base and its cranial cavities. A
- 2 **Anterior cranial fossa.** Fossa cranii [cranialis] anterior. Cranial cavity extending from the wall of the frontal bone to the lesser wing of the sphenoid. A
- 3 **Middle cranial fossa.** Fossa cranii [cranialis] media. Cranial cavity extending from the lesser wing of the sphenoid to the petrous ridge of the temporal bone. A
- 4 **Posterior cranial fossa.** Fossa cranii [cranialis] posterior. Cranial cavity extending from the petrous ridge to the posterior (occipital) wall of the skull. A
- 5 **Clivus.** Posteriorly descending segment of bone between the sella turcica and foramen magnum. It is formed by the occipital and sphenoid bones. A B
- 6 **Digital impressions.** Impressiones digitatae (gyrorum). Flat indentations corresponding to the cerebral gyri which produce them. A
- 7 **Venous grooves.** Sulci venosi. Grooves for meningeal veins occasionally present on the inner wall of the parietal bone.
- 8 **Arterial grooves.** Sulci arteriales. Grooves on the inner wall of the skull produced primarily by the middle meningeal artery and its branches. A
- 9 **Sutural (wormian) bones.** Ossa suturalia. Bones occasionally present in cranial sutures. C
- 10 **NORMA LATERALIS.** Normal outline of skull as viewed laterally. C
- 10a **Pterion.** Important cephalometric landmark indicating the point where the frontal, parietal, temporal, and sphenoid bones meet. C
- 10b **Asterion.** Point where the lambdoid, parietomastoid and occipitomastoid sutures meet. C
- 11 **Temporal fossa.** Fossa temporalis. Area between the temporal line and the zygomatic arch. C
- 12 **Zygomatic arch.** Arcus zygomaticus. Bony arch formed by the union of the zygomatic process of the temporal bone with the temporal process of the zygomatic bone. C
- 13 **Infratemporal fossa.** Fossa infratemporalis. Inferior continuation of the temporal fossa located between the ramus of the mandible and the greater wing of the sphenoid. It contains the pterygoid muscles, the pterygoid plexus, and the ramus of the mandibular nerve. C
- 14 **Pterygopalatine fossa.** Fossa pterygopalatina. The part of the infratemporal fossa just lateral to the sphenopalatine foramen and the perpendicular lamina of the palatine bone. Its lateral boundary is formed by the pterygomaxillary fissure. C
- 15 **Pterygomaxillary fissure.** Fissura pterygomaxillaris. Cleft located between the maxilla and the lateral pterygoid plate. C D
- 16 **NORMA BASILARIS (BASIS CRANII EXTERNA).** Normal outline of skull base as viewed from below. External base of cranium. B
- 17 **Greater palatine canal.** Canalis palatinus major. Canal formed by the palatine bone and maxilla for the descending palatine artery and the greater palatine nerve. B E. See 25 C
- 18 **Jugular foramen.** Foramen jugulare. Fibrous, divided opening between the occipital and temporal bones. Point where the sigmoid sinus and inferior petrosal sinus unite. The internal jugular vein and nerves IX, X, and XI pass through it. A B
- 19 **Sphenopetrosal fissure.** Fissura sphenopetrosa. Medial continuation of the petrosquamous fissure. Its expansion forms the foramen lacerum. Point of passage of the lesser petrosal nerve and point of exit of the chorda tympani from the skull. A B
- 20 **Petro-occipital fissure.** Fissura petro-occipitalis. Cleft between the petrous temporal and occipital bones extending medially from the jugular foramen. A B
- 21 **Foramen lacerum.** Foramen lacerum. Irregular, fibrocartilage-covered opening in the middle cranial fossa between the apex of the petrous part of the temporal bone and the sphenoid bone. The deep and greater petrosal nerves pass through it. A B
- 22 **Bony (hard) palate.** Palatum osseum. B E
- 23 **Greater palatine foramen.** Foramen palatinum majus. Opening of the greater palatine canal located near the posterior margin of the bony palate between the palatine bone and maxilla. B E
- 24 **Incisive fossa.** Fossa incisiva. Tiny (matchhead-sized), epithelium-covered depression which receives the incisive canal and the incisive foramina. E
- 25 **Incisive canal.** Canalis incisivus. Canal for the incisive nerve. Cf. page 24.4 E
- 26 **Incisive foramina.** Foramina incisiva. Two or four openings for the incisive canals. E
- 27 **[Torus palatinus].** Longitudinal elevation occasionally present in the midline of the hard palate projecting toward the oral cavity. E
- 28 **Palatovaginal canal.** Canalis palatovaginalis. Small canal between the vaginal process of the sphenoid and palatine bone for branches of the maxillary artery and the pterygopalatine ganglion. See 12.8
- 29 **Vomerovaginal canal.** Canalis vomerovaginalis. Small canal occasionally present between the vomer and the vaginal process of the sphenoid for transmission of a branch of the sphenopalatine artery. See 12.9
- 30 **Vomerorostral canal.** Canalis vomerorostralis. Small canal between the vomer and sphenoidal rostrum.



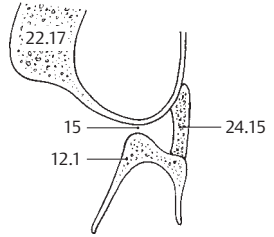
A Internal base of cranium.
Superior aspect of skull base.



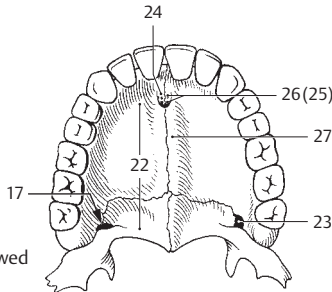
B Skull base
viewed from below



C Skull from left

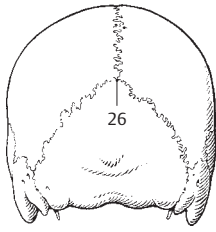


D Schematic
horizontal section
through the
pterygopalatine fossa

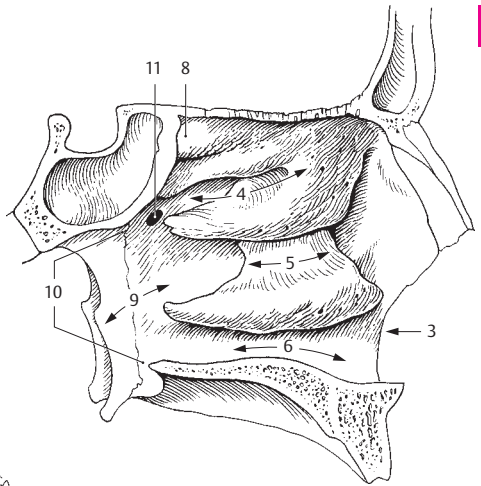


E Hard palate viewed
from below

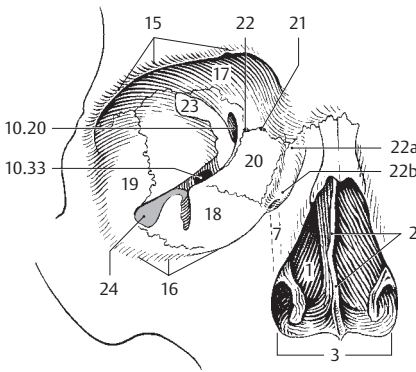
- 1 **NASAL CAVITY.** Cavitas nasi. A C
- 2 **Bony nasal septum.** Septum nasi osseum. Bony partition formed by the vomer and the perpendicular plate of the ethmoid. C. See page 136.4
- 3 **Piriform aperture.** Apertura piriformis (nasalis anterior). Pear-shaped anterior nasal opening in the bony skull. A C D
- 4 **Superior nasal meatus.** Meatus nasalis superior. Space above the middle nasal concha. A
- 5 **Middle nasal meatus.** Meatus nasalis medius. Space between the middle and inferior nasal conchae. A
- 6 **Inferior nasal meatus.** Meatus nasalis inferior. Space below the inferior nasal concha. A
- 7 **Nasolacrimal canal.** Canalis nasolacrimalis. Passageway for the nasolacrimal duct which opens beneath the inferior nasal concha. C
- 8 **Sphenoethmoidal recess.** Recessus sphenoethmoidalis. Space above the superior nasal concha. A
- 9 **Nasopharyngeal meatus.** Meatus nasopharyngeus. Part of the nasal cavity that extends from the posterior margin of the conchae to the choana. A
- 10 **Posterior apertures of the nose.** Choanae. Bilateral openings between the nasal cavity and the nasopharynx. A
- 11 **Sphenopalatine foramen.** Foramen sphenopalatinum. Superior opening in the pterygopalatine fossa leading into the nasal cavity. The largest part is formed by the palatine bone, a lesser part by the sphenoid. A
- 12 **ORBIT.** Orbita. Bony cavity that contains the eyeball. C D
- 13 **Orbital aditus.** Aditus orbitalis. Anterior opening (base) of the orbit. D
- 14 **Orbital margin.** Margo orbitalis. Bony margin of orbit.
- 15 **Supraorbital margin.** Margo supraorbitalis. Upper margin of orbital aditus. C
- 16 **Infraorbital margin.** Margo infraorbitalis. Lower margin of orbital aditus. C
- 16a **Lateral margin.** Margo lateralis. Lateral border of orbital aditus.
- 16b **Medial margin.** Margo medialis. Medial border of orbital aditus.
- 17 **Superior wall.** Paries superior. Roof of the orbit. C
- 18 **Inferior wall.** Paries inferior. Floor of the orbit. C
- 19 **Lateral wall of orbit.** Paries lateralis. C
- 20 **Medial wall of orbit.** Paries medialis. C
- 21 **Anterior ethmoidal foramen.** Foramen ethmoidale anterius. Anterior opening in the medial wall of the orbit between the frontal and ethmoid bones for passage of the anterior ethmoidal nerve and vessels from the anterior cranial fossa. C
- 22 **Posterior ethmoidal foramen.** Foramen ethmoidale posterius. Posterior opening in the medial wall of the orbit between the frontal and ethmoid bones for passage of the posterior ethmoidal vessels and nerve. C
- 22a **Lacrimal sulcus.** Sulcus lacrimalis. Groove-like beginning of the nasolacrimal canal. C
- 22b **Fossa of lacrimal sac.** Fossa sacci lacrimalis. Expanded depression for the lacrimal sac at the beginning of the nasolacrimal canal. C
- 23 **Superior orbital fissure.** Fissura orbitalis superior. Fissure in the posterior part of the lateral wall of the orbit between the greater and lesser wings of the sphenoid. It leads from the cranial cavity to the orbit and transmits the ophthalmic, oculomotor, trochlear and abducens nerves as well as the superior ophthalmic vein. C
- 24 **Inferior orbital fissure.** Fissura orbitalis inferior. Cleft between the greater wing of the sphenoid and the orbital surface of the maxilla for passage of the zygomatic nerve and the infraorbital nerve and vessels. C
- 25 **NORMA OCCIPITALIS.** Normal outline of skull viewed from behind. B
- 25a **Inion.** Cephalometric landmark at the center of the external occipital protuberance.
- 26 **Lambda.** Junction point of the lambdoid and sagittal sutures. B
- 27 **CRANIAL FONTANELLES.** Fonticuli cranii. Membrane-covered gaps between the developing skull bones (fetal and infant). D E
- 28 **Anterior fontanelle.** Fonticulus anterior. Rhomboid, large space located anteriorly in the sagittal suture between the temporal and frontal anlagen. It is obliterated in the 2nd and 3rd postnatal year. D E
- 29 **Posterior fontanelle.** Fonticulus posterior. Small triangular gap at the junction of the sagittal and lambdoid sutures, i.e., between the paired temporal bones and the occipital bone. It closes within 3 months after birth. D E
- 30 **Sphenoidal (anterolateral) fontanelle.** Fonticulus sphenoidalis (anterolateralis). Lateral gap between the frontal, parietal, temporal and sphenoid bones, i.e., at the site of the pterion. D
- 31 **Mastoid (posterolateral) fontanelle.** Fonticulus mastoideus (posterolateralis). Lateral space between the parietal, occipital and temporal bones, i.e., at the site of the asterion. D



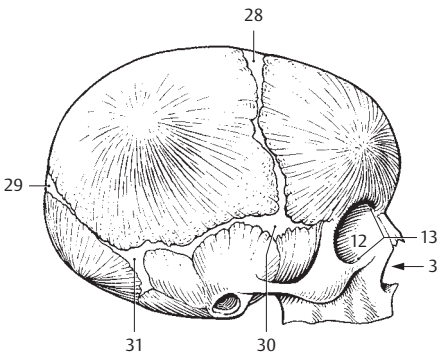
A Lateral wall of nasal cavity with frontal and sphenoidal sinuses



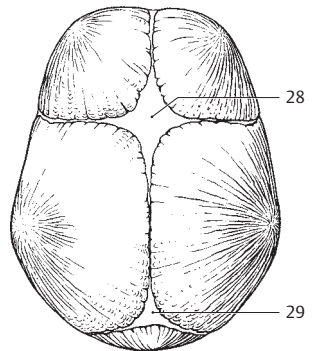
B Normal outline of skull viewed from behind (norma occipitalis)



C Right bony orbital cavity

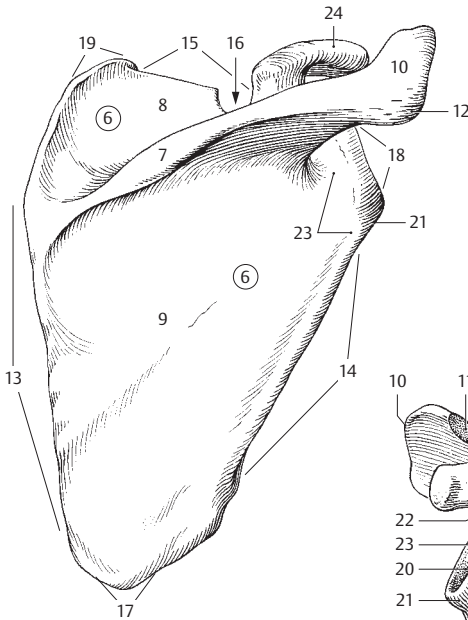


D Skull of newborn, dextralateral view

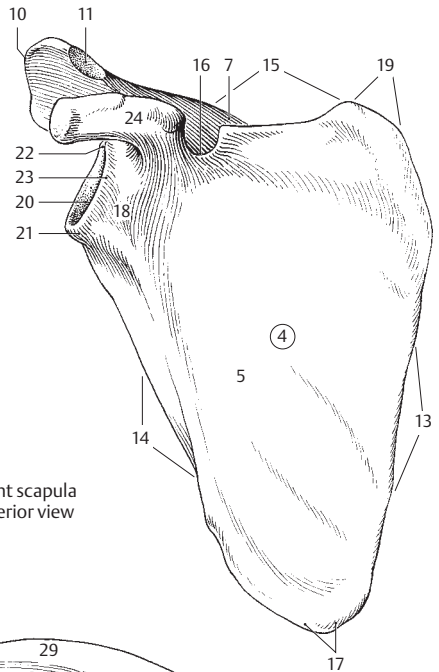


E Skull of newborn, superior view

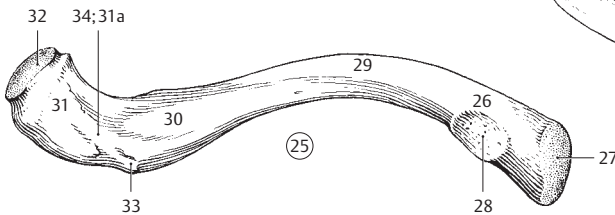
- APPENDICULAR SKELETON.** Skeleton appendiculare. Bones of the limbs.
- 1 **BONES OF THE UPPER LIMB.** Ossa membri superioris.
 - 2 **SHOULDER (PECTORAL) GIRDLE.** Cingulum membri superioris (Cingulum pectorale).
 - 3 **Scapula.** Shoulder blade. A B
 - 4 **Costal (anterior) surface.** Facies costalis (anterior). Scapular surface facing the ribs. B
 - 5 **Subscapular fossa.** Fossa subscapularis. Concavity on the costal surface. B
 - 6 **Posterior surface.** Facies posterior. Scapular surface facing the skin of the back. A
 - 7 **Spine of scapula.** Spina scapulae. Long bony ridge on the posterior scapular surface extending into the acromion. A B
 - 8 **Supraspinous fossa.** Fossa supraspinata (supraspinosa). Fossa that extends from above the spinous process to the superior margin of the scapula. A
 - 9 **Infraspinous fossa.** Fossa infraspinata (infraspinosa). Fossa that extends from below the spinous process to the inferior angle of the scapula. A
 - 10 **Acromion.** Free end of the scapular spine projecting over the head of the humerus. A B
 - 11 **Acromial articular surface.** Facies articularis acromii. Articular facet for the clavicle. B
 - 12 **Acromial angle.** Angulus acromialis. Sharp bend at the site where the spine of the scapula becomes continuous with the lateral margin of the acromion. A
 - 13 **Medial margin.** Margo medialis. Border of the scapula facing the vertebral column. A B
 - 14 **Lateral margin.** Margo lateralis. Border of the scapula facing the humerus. A B
 - 15 **Superior margin.** Margo superior. Upper border of the scapula. A B
 - 16 **Scapular notch.** Incisura scapulae (scapularis). Indentation in the superior margin of the scapula just medial to the coracoid process. It is traversed by the suprascapular nerve. A B
 - 17 **Inferior angle.** Angulus inferior. Lower angle of the scapula. A B
 - 18 **Lateral angle.** Angulus lateralis. Lateral angle of the scapula bearing the glenoid cavity. A B
 - 19 **Superior angle.** Angulus superior. Upper medial angle of the scapula. A B
 - 20 **Glenoid cavity.** Cavitas glenoidalis. Articular cavity of the shoulder. B
 - 21 **Infraglenoid tubercle.** Tuberculum infraglenoidale. Small tubercle at the inferior margin of the glenoid cavity for the origin of the long head of the triceps. A B
 - 22 **Supraglenoid tubercle.** Tuberculum supraglenoidale. Small tubercle at the superior margin of the glenoid cavity for the origin of the long head of the biceps. B
 - 23 **Neck of scapula.** Collum scapulae. The portion of the scapula situated medial to the margin of the glenoid cavity. A B
 - 24 **Coracoid process.** Processus coracoideus. Hook-shaped process projecting anteriorly from the superior margin of the scapula just lateral to the scapular notch. Attachment site of the pectoralis minor, coracobrachialis and short head of the biceps muscles. A B
 - 25 **Clavicle.** Clavicula. Collar bone. C
 - 26 **Extremitas sternalis.** Sternal (medial) end of the clavicle facing the sternum. C
 - 27 **Sternal articular surface.** Facies articularis sternalis. Articular surface on the medial end of clavicle for articulation with the sternum. C
 - 28 **Impression for the costoclavicular ligament.** Impressio ligamenti costoclavicularis. Roughened area on the inferior surface of the clavicle near the sternal end for attachment of the costoclavicular ligament. C
 - 29 **Body (shaft) of clavicle.** Corpus claviculae (claviculare). Middle portion of the clavicle. C
 - 30 **Subclavian groove.** Sulcus musculi subclavii. Elongated groove representing the deep attachment field of the subclavius muscle. C
 - 31 **Acromial (lateral) end.** Extremitas acromialis. End of the clavicle facing the acromion. C
 - 31 a **Tuberosity for the coracoclavicular ligament.** Tuberositas ligamenti coracoclavicularis. Roughened area for attachment of the two portions of the coracoclavicular ligament (conoid and trapezoid ligaments). C
 - 32 **Acromial articular surface.** Facies articularis acromialis. Joint surface for the acromion. C
 - 33 **Conoid tubercle.** Tuberculum conoideum. Small eminence on the inferior surface of the acromial end of the clavicle for attachment of the conoid ligament. C
 - 34 **Trapezoid line.** Linea trapezoidea. Attachment site for the trapezoid ligament on the inferior surface of the acromial end of the clavicle. C



A Right scapula, posterior view

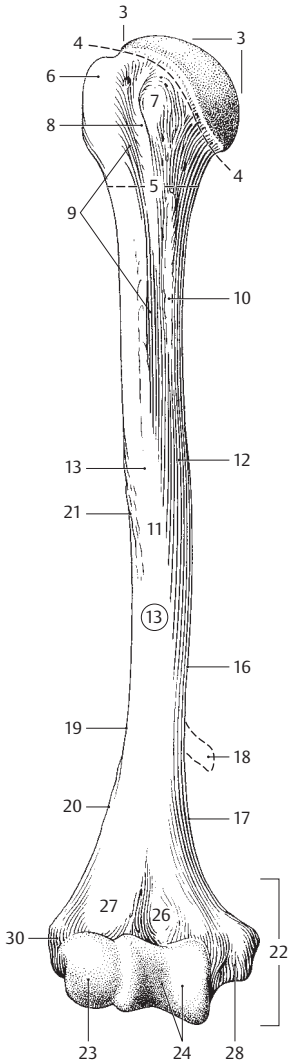


B Right scapula anterior view

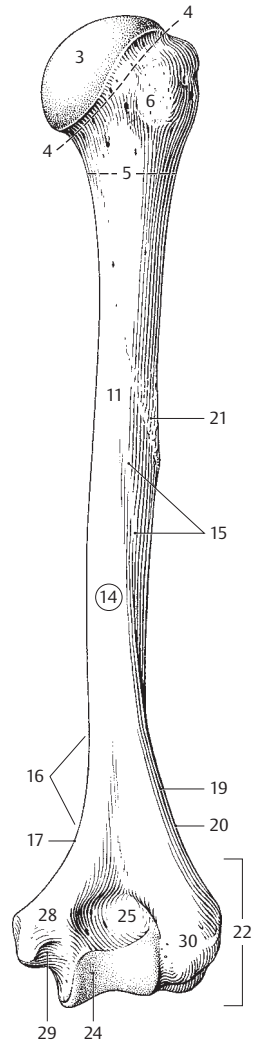


C Right clavicle, inferior view

- 1 **FREE PART OF UPPER LIMB.** Pars libera membri superioris. Bones of the arm and hand.
- 2 **Humerus.** The bone of the upper arm. A B
- 3 **Head of humerus.** Caput humeri (humerales). A B
- 4 **Anatomical neck.** Collum anatomicum. Area between the head and the (greater and lesser) tubercles of the humerus. A B
- 5 **Surgical neck.** Collum chirurgicum. Tapering region distal to the tubercles and continuous with the shaft. A B
- 6 **Greater tubercle.** Tuberculum majus. Large prominence at the posterolateral end of the humerus. Site of muscle attachment. A B
- 7 **Lesser tubercle.** Tuberculum minus. Smaller prominence on the anterior surface of humerus. Site of muscle attachment. A
- 8 **Intertubercular groove.** Sulcus intertubercularis. Groove located between the two tubercles for passage of the tendon of the long head of the biceps. A
- 9 **Crest of greater tubercle.** Crista tuberculi majoris. Bony ridge extending downward from the greater tubercle. Attachment site for the pectoralis major. A
- 10 **Crest of lesser tubercle.** Crista tuberculi minoris. Bony ridge extending downward from the lesser tubercle. Attachment site for the teres major and latissimus dorsi. A
- 11 **Body of humerus.** Corpus humeri. Shaft between the two end of the humerus. A B
- 12 **Anteromedial surface.** Facies anterior medialis (anteromedialis). Surface of the humerus lying medial to the prolongation of the crest of the greater tubercle. A
- 13 **Anterolateral surface.** Facies anterior lateralis (anterolateralis). Surface of the humerus located lateral to the prolongation of the crest of the greater tubercle. A
- 14 **Posterior surface of humerus.** Facies posterior. B
- 15 **Groove for radial nerve.** Sulcus nervi radialis. Oblique groove descending laterally on the posterior surface of the humerus. B
- 16 **Medial margin.** Margo medialis. Inner margin of the humerus continuous distally with the medial supracondylar ridge. A B
- 17 **Medial supracondylar ridge.** Crista supracondylaris medialis. Lower, sharp-edged end of the medial margin. It communicates with the medial epicondyle. A B
- 18 **Supracondylar process.** [Processus supracondylaris]. Bony spur, phylogenetically conditioned, and occasionally present (1%) at the medial margin of the distal humerus. A
- 19 **Lateral margin.** Margo lateralis. Outer margin of the humerus continuous distally with the lateral supracondylar ridge. A B
- 20 **Lateral supracondylar ridge.** Crista supracondylaris lateralis. Lower, sharp-edged terminal portion of the lateral margin ending at the lateral epicondyle. A B
- 21 **Deltoid tuberosity.** Tuberositas deltoidea. Rough area on the anterolateral surface near the middle of the humerus for attachment of the deltoid muscle. A B
- 22 **Condyle of humerus.** Condylus humeri. Distal end of the humerus comprising the olecranon fossa, coronoid fossa, radial fossa and the articular surfaces. A B
- 23 **Capitulum of humerus.** Capitulum humeri. Rounded projection at the distal end of the humerus for articulation with the radius. A
- 24 **Trochlea of humerus.** Trochlea humeri. Articular cylinder at the distal end of the humerus for articulation with the ulna. A B
- 25 **Olecranon fossa.** Fossa olecrani. Deep pit above the trochlea on the posterior aspect of the humerus that receives the olecranon when the elbow joint is extended. B
- 26 **Coronoid fossa.** Fossa coronioidea. Depression on the anterior aspect of the humerus proximal to the trochlea that receives the coronoid process of the ulna when the elbow joint is flexed. A
- 27 **Radial fossa.** Fossa radialis. Depression above the capitulum on the anterior aspect of the humerus that receives the head of the radius when there is strong flexion of the elbow joint. A
- 28 **Medial epicondyle.** Epicondylus medialis. Medial protuberance which gives origin to the flexor muscles of the forearm. A B
- 29 **Groove for the ulnar nerve.** Sulcus nervi ulnaris. It occupies the posterior surface of the medial epicondyle. B
- 30 **Lateral epicondyle.** Epicondylus lateralis. Protuberance lateral to the capitulum that gives attachment to the extensor muscles of the forearm. A B

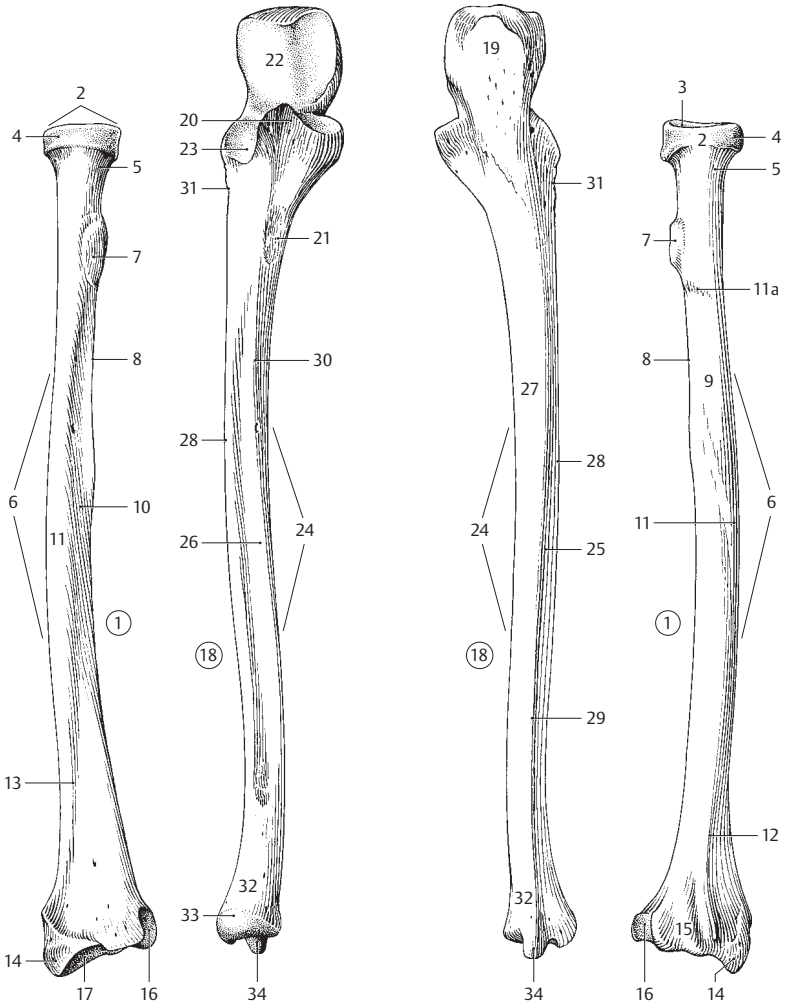


A Right humerus, anterior view



B Right humerus, posterior view

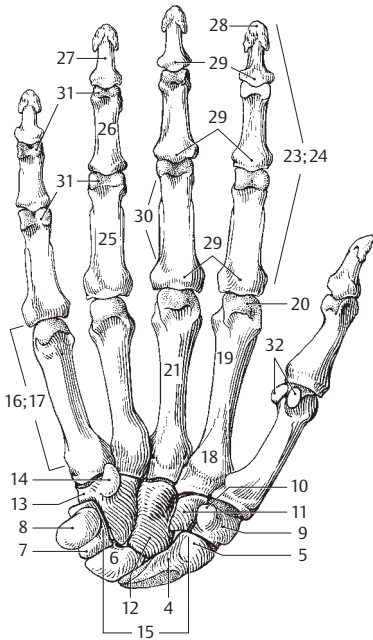
- 1 **Radius.** The lateral of the two forearm bones. A B
- 2 **Head of radius.** Caput radii (radiale). Proximal end of the radius which articulates with the capitulum of the humerus. A B
- 3 **Articular fovea.** Fovea articularis. Concavity that receives the capitulum of the humerus. B
- 4 **Articular circumference.** Circumferentia articularis. Rim-like surface on the head of the radius for articulation with the radial notch of the ulna. A B
- 5 **Neck of radius.** Collum radii. Slender region at the proximal end of the radius between the head and tuberosity. A B
- 6 **Body of radius.** Corpus radii. Radial shaft. A B
- 7 **Radial tuberosity.** Tuberositas radii. Roughened prominence on the medial aspect of the radius about 2 cm distal to the proximal end. Attachment site of the biceps tendon. A B
- 8 **Interosseous margin.** Margo interosseus. Border facing the ulna and giving attachment to the interosseous membrane. A B
- 9 **Posterior border.** Facies posterior. B
- 10 **Anterior border.** Facies anterior. A
- 11 **Lateral border.** Facies lateralis. A B
- 11a **Pronator tuberosity.** Tuberositas pronatoria. Roughened area at the middle of the lateral surface. Attachment site of the pronator teres muscle. B
- 12 **Posterior margin.** Margo posterior. B
- 13 **Anterior margin.** Margo anterior. Margin facing anterolaterally. A
- 14 **Styloid process.** Processus styloideus. Downward projection of the lateral surface of the radius at its distal end. A B
- 15 **Dorsal tubercle.** Tuberculum dorsale. Bony ridge on the posterior aspect of the lower end of the radius between the grooves for the extensor pollicis longus and extensor carpi radialis brevis muscles. It is often palpable through the skin. B
- 16 **Ulnar notch.** Incisura ulnaris. Concavity forming the medial surface at the end of the radius for articulation with the ulna. A B
- 17 **Articular carpal surface.** Facies articularis carpalis. Joint surface on the inferior surface of the lower end of the radius for articulation with the carpus. A
- 18 **Ulna.** Medial forearm bone. A B
- 19 **Olecranon.** Proximal, posterior end of the ulna. Attachment site of the extensor muscles of the elbow joint. B
- 20 **Coronoid process.** Processus coronoideus. Anteriorly directed projection at the anterior end of the trochlear notch. A
- 21 **Ulnar tuberosity.** Tuberositas ulnae. Roughened area on the anterior surface of the upper part of the ulnar shaft for attachment of the brachialis muscle. A
- 22 **Trochlear notch.** Incisura trochlearis. Articular surface at the proximal end of the anterior surface of the ulna for articulation with the trochlea of the humerus. A
- 23 **Radial notch.** Incisura radialis. Joint surface on the lateral aspect of the ulna at the level of the coronoid process for articulation with the articular circumference of the radius. A
- 24 **Body of ulna.** Corpus ulnae. Ulnar shaft. A B
- 25 **Posterior surface.** Facies posterior. B
- 26 **Anterior surface.** Facies anterior. A
- 27 **Medial surface.** Facies medialis. Surface facing the trunk. B
- 28 **Interosseous border.** Margo interosseus. Margin providing attachment for the interosseous membrane. A B
- 29 **Posterior margin.** Margo posterior. B
- 30 **Anterior margin.** Margo anterior. Anteromedial margin of the ulna. A
- 31 **Supinator crest.** Crista m. supinatoris. Bony ridge extending distally from the radial notch for attachment of the supinator muscle. A B
- 32 **Head of ulna.** Caput ulnae. Distal end of the ulna. A B
- 33 **Articular circumference.** Circumferentia articularis. Anterolateral articular surface of the head of the ulna for articulation with the ulnar notch of the radius. A
- 34 **Styloid process.** Processus styloideus. Peg-like process projecting downward from the posteromedial aspect of the lower end of the ulna. Attachment site of the articular disc and the ulnar collateral ligament. A B



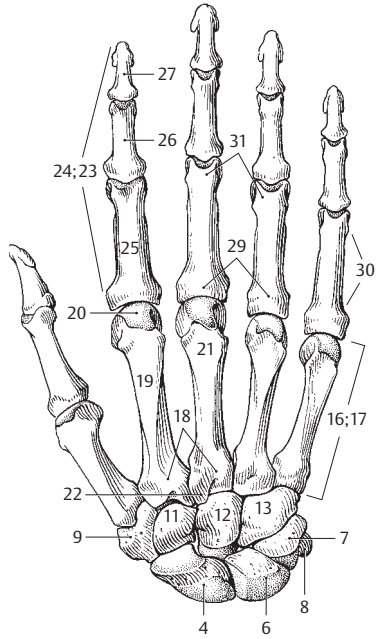
A Right radius and ulna, anterior view

B Right ulna and radius, posterior view

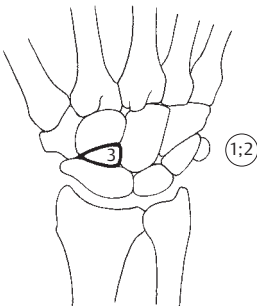
- BONES OF THE HAND.** Ossa manus.
- 1 **CARPUS.** The wrist, which is situated between the forearm and metacarpal bones. A B C
 - 2 **CARPAL BONES.** Ossa carpi (carpalia). The eight wrist bones. A B C
 - 3 **Accessory carpal bone (ossicle).** [Os centrale]. It is occasionally found between the capitate, scaphoid and trapezoid bones. When present, it is usually fused with the scaphoid. C
 - 4 **Scaphoid.** Os scaphoideum [[os naviculare]]. Proximal carpal bone situated between the lunate and trapezium bones. A B
 - 5 **Scaphoid tubercle.** Tuberculum ossis scaphoidei. Elevation on the anterior surface of the scaphoid. It protrudes visibly with radial abduction of the hand. A
 - 6 **Lunate.** Os lunatum. Proximal carpal bone located between the scaphoid and triquetrum. A B
 - 7 **Triquetrum.** Os triquetrum. Proximal carpal bone situated between the hamate and lunate bones, dorsal to the pisiform bone. A B
 - 8 **Pisiform.** Os pisiforme. Proximal carpal bone residing on the palmar aspect of the triquetrum with which it articulates. It represents a true sesamoid bone within the tendon of the flexor carpi ulnaris. A B
 - 9 **Trapezium.** Os trapezium [[os multangulum majus]]. Distal carpal bone located between the 1st metacarpal and the scaphoid. A B
 - 10 **Tubercle of trapezium.** Tuberculum ossis trapezii. Elevation on the palmar side of the trapezium distal to the scaphoid tubercle and radial to the groove for the flexor carpi radialis. A
 - 11 **Trapezoid.** Os trapezoideum [[os multangulum minus]]. Distal carpal bone positioned between the 2nd metacarpal and the scaphoid and between the trapezium and capitate bones. A B
 - 12 **Capitate.** Os capitatum. Distal carpal bone centered between the 3rd metacarpal and the lunate bone. A B
 - 13 **Hamate.** Os hamatum. Distal carpal bone located between the 4th and 5th metacarpals, capitate and triquetrum. A B
 - 14 **Hamulus (hook) of hamate.** Hamulus ossis hamati. Hook-shaped process on the palmar aspect of the hamate distal to the pisiform bone. A
 - 15 **Carpal groove.** Sulcus carpi. Palmar concavity between the tubercles of the scaphoid and trapezium on the radial side, and the hamulus and pisiform bone on the ulnar side. A transverse ligament converts it into a closed canal (carpal tunnel) for the flexor tendons of the fingers. A
 - 16 **METACARPUS.** Region of the hand between the fingers and the wrist. A B
 - 17 **METACARPAL BONES I–V.** Ossa metacarpi (metacarpalia) [I–V]. A B
 - 18 **Base of metacarpal bone.** Basis metacarpalis. Proximal, broad end of a metacarpal bone. A B
 - 19 **Body (shaft) of metacarpal bone.** Corpus metacarpale. A B
 - 20 **Head of metacarpal bone.** Caput metacarpale. Distal articular end of a metacarpal bone. A B
 - 21 **Third metacarpal bone.** Os metacarpale tertium [III]. Metacarpal bone lying proximal to the middle finger. A B
 - 22 **Styloid process.** Processus styloideus. Pointed process at the base of metacarpal III, radial to the capitate. B
 - 23 **FINGERS (DIGITS).** Ossa digitorum (phalanges). A B
 - 24 **PHALANGES.** Bony segments comprising the fingers. A B
 - 25 **Proximal phalanx.** Phalanx proximalis. Proximal bone of a finger. A B
 - 26 **Middle phalanx.** Phalanx media. The middle bones of the fingers. A B
 - 27 **Distal (terminal) phalanx.** Phalanx distalis. Distal, nail-bearing segment of the finger. A B
 - 28 **Tuberosity of distal phalanx.** Tuberositas phalangis distalis. Roughened expansions at the distal flexor side of each terminal phalanx for attachment of the tactile pads. A
 - 29 **Base of phalanx.** Basis phalangis. Proximal, thickened, articular end of the phalanx. A B
 - 30 **Body (shaft) of phalanx.** Corpus phalangis. A B
 - 31 **Distal end (trochlea) of phalanx.** Caput (trochlea) phalangis. A B
 - 32 **Sesamoid bones.** Ossa sesamoidea. Bones embedded in tendons or ligaments. A



A Skeleton of right hand from palmar side

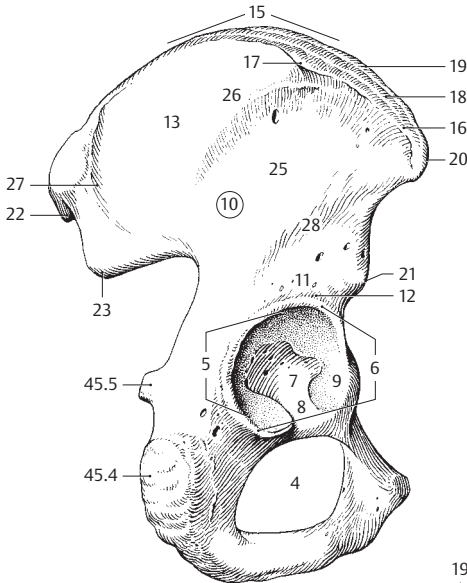


B Skeleton of right hand from dorsal side

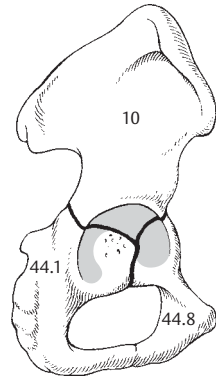


C Central bone of right hand

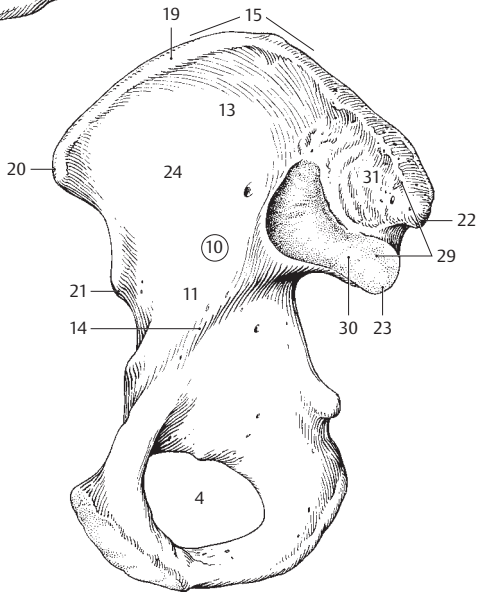
- 1 **BONES OF THE LOWER LIMB.** Ossa membri inferioris.
- 2 **PELVIC GIRDLE.** Cingulum membri inferioris (Cingulum pelvicum). It is composed of the sacrum and the two ilia.
- 3 **HIP BONE.** Os coxae (pelvicum). Bony structure comprised of the ilium, ischium and pubis. A B C
- 4 **Obturator foramen.** Foramen obturatum (obturatorium). Large opening between the pubis and ischium. A C
- 5 **Acetabulum.** Hip joint socket. Cavity formed by the ilium, ischium and pubis. A
- 6 **Margin of the acetabulum.** Limbus acetabuli (margo acetabularis). Margin interrupted by the acetabular notch. A
- 7 **Acetabular fossa.** Fossa acetabuli (acetabularis). Deeper part embraced by the lunate surface. A
- 8 **Acetabular notch.** Incisura acetabuli (acetabularis). Notch in the lunate surface of the acetabulum facing the obturator foramen and continuous with the acetabular fossa. A
- 9 **Lunate surface.** Facies lunata. Cartilage covered, sickle-shaped articular surface of the acetabulum. A
- 10 **Ilium.** Os ilii (ilium, os iliacum). A B C
- 11 **Body of the ilium.** Corpus ossis ilii. The central portion of the ilium situated near the acetabulum. A B C
- 12 **Supra-acetabular sulcus.** Sulcus supraacetabularis. Groove formed between the acetabular margin and the body of the ilium. A
- 13 **Wing (or ala) of the ilium.** Ala ossis ilii. A C
- 14 **Arcuate line.** Linea arcuata. Prominent bony ridge at the boundary between the greater and lesser pelvis. C
- 15 **Iliac crest.** Crista iliaca. A C
- 16 **External lip of the iliac crest.** Labium externum. Bony ridge for attachment of the external abdominal oblique muscle. A
- 17 **Tubercle of iliac crest.** Tuberculum iliacum. Palpable projection on the external lip of the iliac crest about 5 cm behind the anterior iliac spine at the junction of the anterior gluteal line with the iliac crest. A
- 18 **Linea intermedia.** Rough bony area between the external and internal lips of the iliac crest. Origin of the internal abdominal oblique muscle. A
- 19 **Internal lip of the iliac crest.** Labium internum. Bony ridge on the inner margin of the iliac crest for attachment of the transversus abdominis muscle. A C
- 20 **Anterior superior iliac spine.** Spina iliaca anterior superior. Bony projection marking the anterior limit of the iliac crest. Origin of the sartorius muscle. A C
- 21 **Anterior inferior iliac spine.** Spina iliaca anterior inferior. Bony process at the anterior margin of the ilium. Origin of the rectus femoris muscle. A C
- 22 **Posterior superior iliac spine.** Spina iliaca posterior superior. Bony process at the posterior end of the iliac crest. A C
- 23 **Posterior inferior iliac spine.** Spina iliaca posterior inferior. Bony process at the superior end of the greater sciatic notch. A C
- 24 **Iliac fossa.** Fossa iliaca. A concavity forming the internal surface of the ala of the ilium. C
- 25 **Gluteal surface.** Facies glutealis. External surface of the ala of the ilium. A
- 26 **Anterior gluteal line.** Linea glutealis anterior. A flat ridge situated somewhat in the middle of the ala of the ilium between the fields of origin of the gluteus medius and minimus muscles. A
- 27 **Posterior gluteal line.** Linea glutealis posterior. Bony ridge between the fields of origin of the gluteus medius and maximus muscles. A
- 28 **Inferior gluteal line.** Linea glutealis inferior. Bony ridge above the acetabulum between the fields of origin of the gluteus minimus and rectus femoris muscles. A
- 29 **Sacropelvic surface.** Facies sacropelvina. Surface of the dorsal segment of the ilium facing the sacrum and consisting of the following two parts. C
- 30 **Auricular surface.** Facies auricularis. The ear-shaped surface which articulates with the sacrum. It is covered with fibrocartilage. C
- 31 **Iliac tuberosity.** Tuberositas iliaca. Roughened area behind and above the auricular surface. Gives attachment to the sacroiliac ligaments. C



A Right hip bone, lateral view

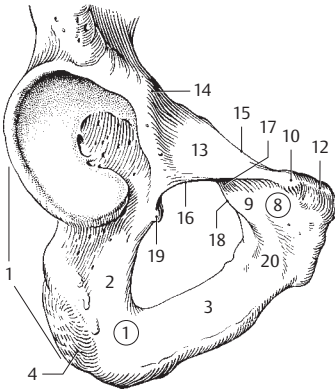


B Epiphyses plates in the hip bone of an adolescent

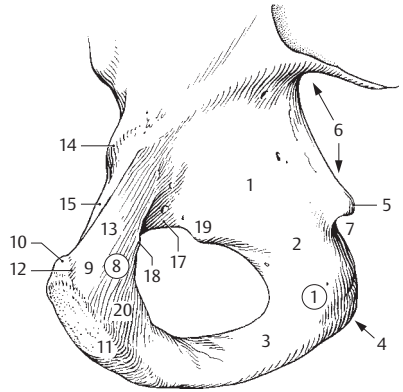


C Right hip bone, medial view

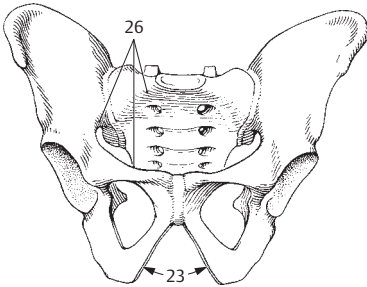
- 1 **Ischium.** Os ischii. Bone which forms the posterior and inferior boundary of the obturator foramen. A B
- 2 **Body of ischium.** Corpus ossis ischii. The portion of the ischium situated behind the obturator foramen. A B
- 3 **Ramus of ischium.** Ramus ossis ischii. The portion of the ischium situated below the obturator foramen. The anterior end unites with the inferior ramus of the pubis. A B
- 4 **Ischial tuberosity.** Tuber ischiadicum (ischiale). Ischial process at the lower end of the lesser sciatic notch. A B
- 5 **Ischial spine.** Spina ischiadica (ischialis). Bony prominence between the greater and lesser sciatic notches. B
- 6 **Greater sciatic notch.** Incisura ischiadica (ischialis) major. Large notch between the posterior inferior iliac spine and the ischial spine. B
- 7 **Lesser sciatic notch.** Incisura ischiadica (ischialis) minor. Notch between the ischial spine and the ischial tuberosity. B
- 8 **Pubis.** Os pubis. Bone which forms the anterior and inferior borders of the obturator foramen. A B
- 9 **Body of the pubis.** Corpus ossis pubis. A B
- 10 **Pubic tubercle.** Tuberculum pubicum. Protuberance located anterolateral to the symphysis. A B
- 11 **Symphyseal surface.** Facies symphysialis. The median surface of the symphysis facing the contralateral pubis. B
- 12 **Pubic crest.** Crista pubica. Ridge extending medially from the pubic tubercle to the symphysis. Attachment site of the rectus abdominis muscle. A B
- 13 **Superior ramus of the pubis.** Ramus superior ossis pubis. The part of the pubis situated above the obturator foramen. A B
- 14 **Iliopubic (iliopectineal) eminence.** Eminencia iliopubica [e. iliopectinea]. Flat prominence at the proximal portion of the pubis. A B
- 15 **Pecten (pectineal line) of the pubis.** Pecten ossis pubis. Sharp, bony ridge which passes to the pubic tubercle as a continuation of the arcuate line. Origin of the pectineus muscle. A B
- 16 **Obturator crest.** Crista obturatoria. It extends from the pubic tubercle to the acetabulum. Origin of the pubofemoral ligament. A
- 17 **Obturator groove.** Sulcus obturatorius. Sulcus above the obturator foramen. A B
- 18 **Anterior obturator tubercle.** Tuberculum obturatorium anterius. Small protuberance anterior to the obturator groove. A B
- 19 **Posterior obturator tubercle.** [Tuberculum obturatorium posterius]. Prominence occasionally present behind the obturator groove. A B
- 20 **Inferior ramus of pubis.** Ramus inferior ossis pubis. The portion of the pubis located anteroinferior the obturator foramen between the symphysis and the suture line with the ischium. A B
- 21 **PELVIS.** Portion of the body located between the stomach and lower extremities, i.e., a bony ring comprised of the sacrum, ilium, pubis and ischium. C D E F
- 21 a **Pelvic cavity.** Cavitas pelvis (pelvica).
- 22 **Pubic arch.** Arcus pubis. The arch below the symphysis formed by the right and left pubic bones. D
- 23 **Subpubic angle.** Angulus subpubicus. The angle between the right and left inferior ramus of the pubis (average of 75° in men and 90°–100° in women). C
- 24 **Greater pelvis.** Pelvis major. The space between the two alae of the ilium above the linea terminalis.
- 25 **Lesser pelvis.** Pelvis minor. The space below the linea terminalis.
- 26 **Terminal line.** Linea terminalis. Line extending along the arcuate line from the promontory to the upper margin of the symphysis. It marks the boundary between the greater pelvis and lesser pelvis as well as the plane of the pelvic inlet. C D E
- 27 **Upper pelvic aperture (pelvic inlet).** Apertura pelvis (pelvica) superior. Upper opening of the lesser pelvis in the plane of the linea terminalis. D
- 28 **Lower pelvic aperture (pelvic outlet).** Apertura pelvis (pelvica) inferior. Lower opening of the lesser pelvis between the coccyx, pubic arch and sacrotuberous ligaments. F
- 29 **Pelvic axis.** Axis pelvis. Imaginary line passing through all median connecting lines between the symphysis and the anterior surface of the sacrum. The fetal head follows its course during birth. F
- 30 **Conjugate diameter.** Diameter conjugata. Anteroposterior diameter of the pelvis, measured from the sacral promontory to the posterior surface of the symphysis (about 11 cm). E F
- 31 **Transverse diameter of pelvis.** Diameter transversa. Widest part of the inlet (ca. 13 cm). E
- 32 **Oblique diameter.** Diameter obliqua. It is measured from the iliosacral joint obliquely forward to the iliopubic eminence of the opposite side (ca. 12.5 cm). E
- 33 **Pelvic inclination.** Inclinatio pelvis. The angle between the plane of the pelvic inlet and the horizontal plane. F



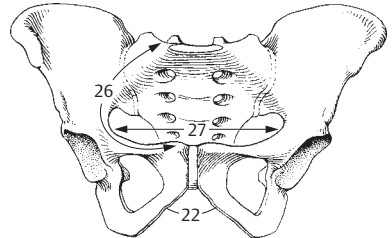
A Lower half of right hip bone, external surface



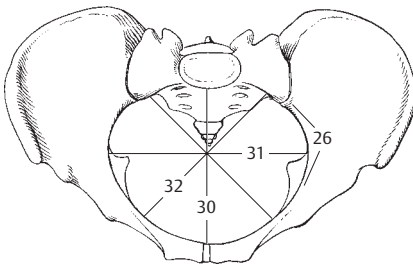
B Lower half of right hip bone, internal surface



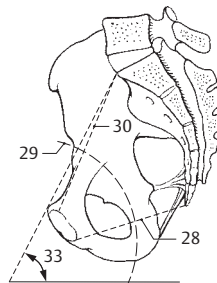
C Male pelvis, anterior view



D Female pelvis, anterior view

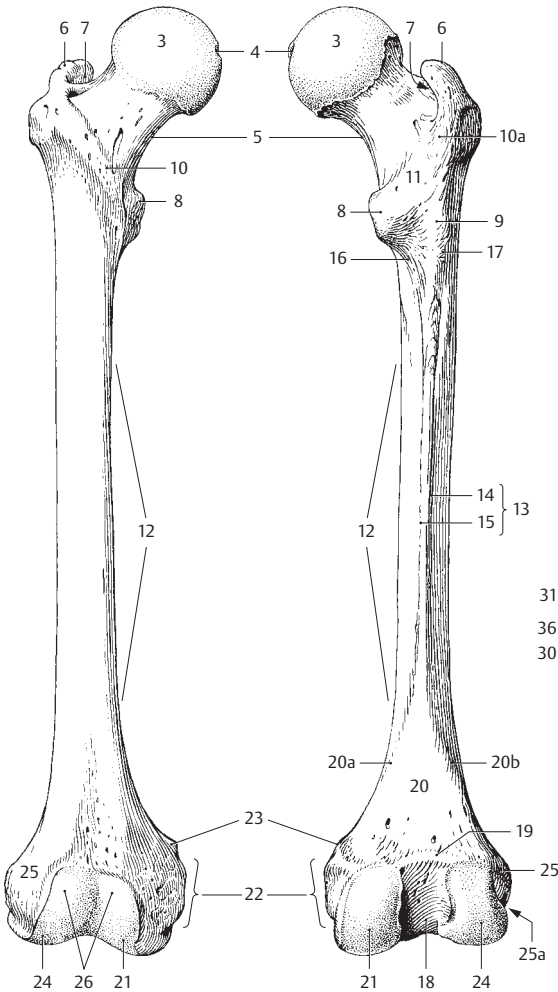


E Pelvis, superior view



F Pelvis, medial view

- 1 **FREE LOWER LIMB.** Pars libera membri inferioris.
- 2 **Femur. Thigh bone.** (Os femoris). A B
- 3 **Head of femur.** Caput femoris. A B
- 4 **Pit (fovea) in the head of the femur.** Fovea capitis femoris. Depression for attachment of the ligament of the head of the femur. A B
- 5 **Neck of femur.** Collum femoris. Portion of the femur between the femoral head and greater trochanter. A B
- 6 **Greater trochanter.** Trochanter major. Large prominence on the superolateral aspect of the femur shaft for attachment of the gluteus medius, gluteus minimus, and piriformis muscles. A B
- 7 **Trochanteric fossa.** Fossa trochanterica. Depression medial to the root of the greater trochanter. Origin of the internal obturator and gemelli muscles. A B
- 8 **Lesser trochanter.** Trochanter minor. Small prominence on the posteromedial aspect of the proximal femur shaft for attachment of the iliopsoas muscle. A B
- 9 **[Trochanter tertius].** Process occasionally present posteriorly at the lateral end of the linea aspera at the level of the lesser trochanter for attachment of a part of the gluteus maximus. B
- 10 **Intertrochanteric line.** Linea intertrochanterica. Rough anterior line between the shaft and neck of the femur, extending from the greater to the lesser trochanter. A
- 10a **Quadrate tubercle.** Tuberculum quadratum. Rounded elevation on the intertrochanteric crest. B
- 11 **Intertrochanteric crest.** Crista intertrochanterica. Posterior bony ridge between the shaft and neck of the femur, running from the greater to the lesser trochanter. B
- 12 **Shaft of femur.** Corpus femoris. A B
- 13 **Linea aspera.** Rough double line on the posterior aspect of the femur for attachment of two vasti muscles and the short head of the biceps. Insertion of the adductors, gluteus maximus, and pectineus muscles. B
- 14 **Lateral lip of the linea aspera.** Labium laterale. B
- 15 **Medial lip of the linea aspera.** Labium mediale. B
- 16 **Pectineal line.** Linea pectinea. Bony ridge extending downward from the lesser trochanter, nearly reaching the linea aspera. Gives attachment to the pectineus muscle. B
- 17 **Gluteal tuberosity.** Tuberositas glutealis. Rough, oblong field continuous with the linea aspera superolaterally. Insertion of the gluteus maximus. B
- 18 **Intercondylar fossa.** Fossa intercondylaris. Posterior notch between the femoral condyles. B
- 19 **Intercondylar line.** Linea intercondylaris. Posterior ridge between the roots of the condyles. B
- 20 **Popliteal surface.** Facies poplitea. Triangular field on the posterior aspect of the femur between the intercondylar line and the diverging lips (supracondylar lines) of the linea aspera. B
- 20a **Medial supracondylar line.** Linea supracondylaris medialis. Continuation of the medial lip of the linea aspera toward the medial condyle. B
- 20b **Lateral supracondylar line.** Linea supracondylaris lateralis. Continuation of the lateral lip of the linea aspera toward the lateral condyle. B
- 21 **Medial condyle.** Condylus medialis. Medial knee joint surface of the femur. A B
- 22 **Medial epicondyle.** Epicondylus medialis. Bony elevation on the medial aspect of the medial condyle. A B
- 23 **Adductor tubercle.** Tuberculum adductorium. Small process situated above the medial epicondyle for attachment of the adductor magnus muscle. A B
- 24 **Lateral condyle.** Condylus lateralis. Articular surface of the femur on the lateral aspect of the knee joint. A B
- 25 **Lateral epicondyle.** Epicondylus lateralis. Bony elevation on the lateral aspect of the lateral condyle. A B
- 25a **Groove for popliteus.** Sulcus popliteus. Groove between the lateral condyle and the lateral epicondyle. B
- 26 **Patellar surface.** Facies patellaris. Surface that articulates with the patella. A
- 27 **Tibia.** C D
- 28 **Superior articular surface.** Facies articularis superior. Tibial articular surface of the knee joint. C D
- 29 **Medial condyle.** Condylus medialis. Medial expansion at the proximal end of the tibia. C D
- 30 **Lateral condyle.** Condylus lateralis. Lateral expansion at the proximal end of the tibia. C D
- 31 **Articular facet for the fibula.** Facies articularis fibularis. Articular surface for the head of the fibula on the posterolateral aspect of the lateral condyle. C D
- 32 **Anterior intercondylar area.** Area intercondylaris anterior. Area between the knee joint surfaces of the tibia and in front of the intercondylar eminence. C D
- 33 **Posterior intercondylar area.** Area intercondylaris posterior. The region between the knee joint surfaces of the tibia and behind the intercondylar eminence. D
- 34 **Intercondylar eminence.** Eminentia intercondylaris. Bony elevation between the articular surfaces of the tibia, for attachment of the cruciate ligaments and menisci. C D
- 35 **Medial intercondylar tubercle.** Tuberculum intercondylare mediale. Elevation of the medial articular surface at the margin facing the intercondylar eminence. C D
- 36 **Tuberculum intercondylare laterale.** Elevation of the lateral articular surface at the margin facing the intercondylar eminence. C D



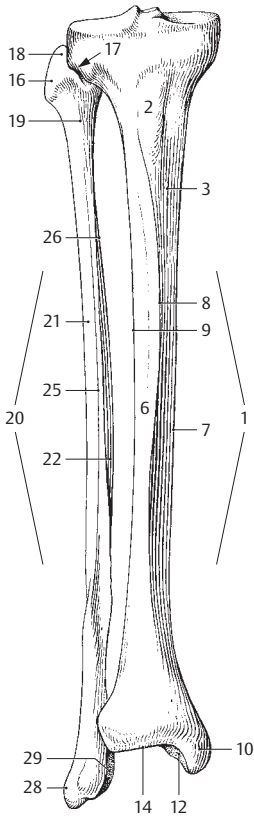
A Right femur, anterior view

B Right femur, posterior view

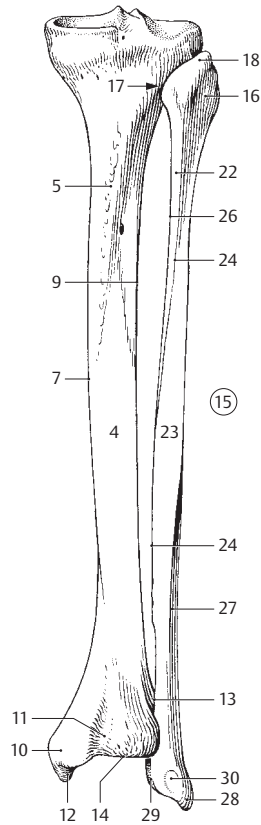
C Head of right tibia, anterior view

D Head of right tibia, superior view

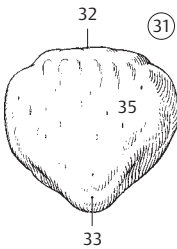
- 1 **Shaft of tibia.** Corpus tibiae (tibiale). A B D
- 2 **Tibial tuberosity.** Tuberositas tibiae. Roughened area on the upper end of the anterior margin of the tibia. Attachment site of the patellar ligament. A
- 3 **Medial surface.** Facies medialis. Surface of tibia directed anteromedially. A D
- 4 **Posterior surface of tibia.** Facies posterior. B D
- 5 **Soleal line of tibia.** Linea musculi solei. Line extending obliquely from the upper, lateral part of the tibia, downward and across to the medial part, giving attachment to the soleus muscle. B
- 6 **Facies lateralis.** Lateral surface of tibia facing anterolaterally. A D
- 7 **Medial (inner) margin.** Margo medialis. A B D
- 8 **Anterior margin.** Margo anterior. A D
- 9 **Interosseous margin.** Margo interosseus. Border facing the fibula and providing attachment to the interosseous membrane along most of its margin. A B D
- 10 **Medial malleolus.** Malleolus medialis. A B
- 11 **Malleolar groove.** Sulcus malleolaris. Small groove on the posterior aspect of the medial malleolus for the tendon of the tibialis posterior muscle. B
- 12 **Articular surface of malleolus.** Facies articularis malleoli. Lateral surface of the medial malleolus facing the talus. A B
- 13 **Fibular notch.** Incisura fibularis. Depression on the lateral surface of the distal end of the tibia. Articulates with the fibula. B
- 14 **Inferior articular surface.** Facies articularis inferior. Inferior joint surface facing the talus. A B
- 15 **Fibula.** A B D
- 16 **Head of fibula.** Caput fibulae (fibulare). The proximal end of the fibula. A B
- 17 **Facies articularis capitis fibulae.** Articular surface facing the tibia at the proximal end of the fibula. A B
- 18 **Apex (styloid process) of head of fibula.** Apex capitis fibulae. Upward pointing process on the head of the fibula. A B
- 19 **Neck of fibula.** Collum fibulae. A
- 20 **Shaft of fibula.** Corpus fibulae. A
- 21 **Facies lateralis.** Lateral surface that faces slightly upward. A D
- 22 **Facies medialis.** Medial surface between the anterior and interosseous margins. It faces the tibia. A B D
- 23 **Facies posterior.** Posterior surface between the posterior and interosseous margins. B D
- 24 **Medial crest.** Crista medialis. Bony ridge on the posterior surface at the border between the origins of the tibialis posterior and flexor hallucis longus muscles. B D
- 25 **Anterior margin.** Margo anterior. A D
- 26 **Interosseous margin.** Margo interosseus. Osseous ridge located between the anterior margin and the medial crest for attachment of a portion of the interosseous membrane. A B D
- 27 **Margin posterior.** Margo posterior, directed posterolaterally. B D
- 28 **Lateral malleolus.** Malleolus lateralis. A B
- 29 **Articular surface of malleolus.** Facies articularis malleoli. Articular surface on the lateral malleolus facing the talus. A B
- 30 **Lateral malleolar fossa.** Fossa malleoli lateralis. Depression on the posteromedial aspect of the lateral malleolus for attachment of the posterior talofibular ligament. B
- 30a **Sulcus malleolaris.** Groove lateral to the malleolar fossa.
- 31 **Patella.** The knee cap, which is embedded in the quadriceps tendon. C
- 32 **Base of patella.** Basis patellae. Broad, superior border of the patella. C
- 33 **Apex of patella.** Apex patellae. Inferior, pointed border of the patella. C
- 34 **Facies articularis.** Cartilage-covered articular surface of the patella facing the femur.
- 35 **Facies anterior.** Anterior surface of the patella. C



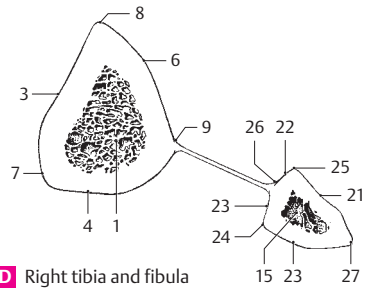
A Right tibia and fibula, anterior view



B Right tibia and fibula, posterior view



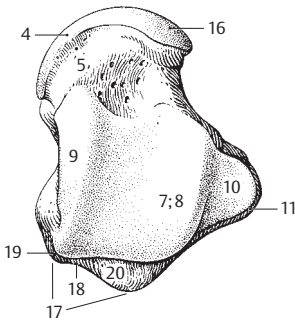
C Patella, anterior view



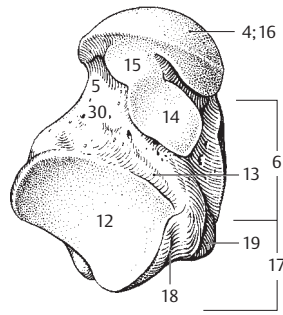
D Right tibia and fibula in cross section

OSSA PEDIS. Bones of the foot.

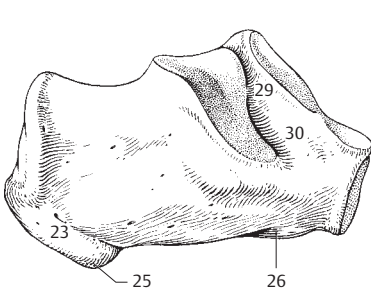
- 1 **TARSUS.** The region of articulation extending from the heel to the metatarsals. E
- 2 **TARSAL BONES.** Ossa tarsi (tarsalia). The seven bones of the ankle, including the talus, calcaneus, os cuboideum, and three cuneiform bones. E
- 3 **Talus.** The ankle bone, which is located between the tibia, calcaneus, navicular bone, and fibula. A B E
- 4 **Head of talus.** Caput tali (talare). It articulates with the navicular bone. A B
- 5 **Neck of talus.** Collum tali. Proximal tapering part of the head of the talus. A B
- 6 **Body of talus.** Corpus tali. B
- 7 **Trochlea tali (talare).** Cylindrical surface of the talus that articulates with the tibia and fibula. A
- 8 **Superior surface.** Facies superior. Upper surface of the talus that articulates with the inferior articular surface of the tibia. A
- 9 **Medial malleolar surface.** Facies malleolaris medialis. Almost sagittally oriented surface of the talus that articulates with the medial malleolus. A
- 10 **Lateral malleolar surface.** Facies malleolaris lateralis. Surface on the lateral part of the talus that articulates with the lateral malleolus. A
- 11 **Lateral process of the talus.** Processus lateralis tali. Bony projection below the lateral malleolar surface. A
- 12 **Posterior calcaneal facet.** Facies articularis calcanea posterior. Posteroinferior surface that articulates with the calcaneus. B
- 13 **Sulcus of talus.** Sulcus tali. A groove between the middle and posterior articular facets for the calcaneus. B
- 14 **Middle calcaneal facet.** Facies articularis calcanea media. Middle articular surface of the calcaneus. B
- 15 **Anterior calcaneal facet.** Facies articularis calcanea anterior. Anterior articular surface of the calcaneus below the head of the talus. B
- 16 **Facies articularis navicularis.** Surface on the anterior part of the head of the talus that articulates with the navicular bone. A B
- 17 **Posterior process of talus.** Processus posterior tali. Broad process below the posterior margin of the trochlea. It bears the medial and lateral tubercles with the groove for the tendon of the flexor hallucis longus between them. A B
- 18 **Sulcus tendinis m. flex. hall. longi.** Groove for the flexor hallucis longus tendon posteromedial to the posterior process of the talus. A B
- 19 **Medial tubercle.** Tuberculum mediale. Bony process anteromedial to the groove for the flexor hallucis longus tendon. A B
- 20 **Lateral tubercle.** Tuberculum laterale. Bony process lateral to the groove for the flexor hallucis longus tendon. A
- 21 **[Os trigonum].** Independent bone occasionally formed by the lateral tubercle of the posterior process of the talus due to a separate ossific center. E
- 22 **Calcaneus.** Heel bone. C D E
- 23 **Tuber calcanei.** Tuberosity on the posterior aspect of the calcaneus. C D
- 24 **Medial process of calcaneus.** Processus medialis tuberis calcanei. Weak process anterior, medial and inferior to the tuberosity of the calcaneus. D
- 25 **Lateral process of calcaneus.** Processus lateralis tuberis calcanei. Weak process inferolateral to the tuberosity of the calcaneus. C
- 26 **Anterior tubercle of calcaneus.** Tuberculum calcanei. Eminence on the anterior aspect of the inferior surface of the calcaneus. Attachment site of the plantar calcaneocuboid ligament. C
- 27 **Sustentaculum tali.** Medial prolongation of the calcaneus bearing the medial posterior facet of the calcaneus. D E
- 28 **Sulcus tendinis m. flex. hall. longi.** Bony groove for the flexor hallucis longus tendon located below the sustentaculum tali. D
- 29 **Sulcus calcanei.** Groove between the middle and posterior articular facets. C D
- 30 **Sinus tarsi.** Laterally opening, funnel-shaped space forming a continuation of the calcaneal sulcus and the sulcus of the talus. The inferior ankle joint is palpable here. B C. See also pp. 53C, 71 AC



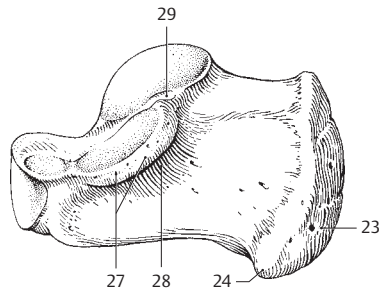
A Right talus, superior view



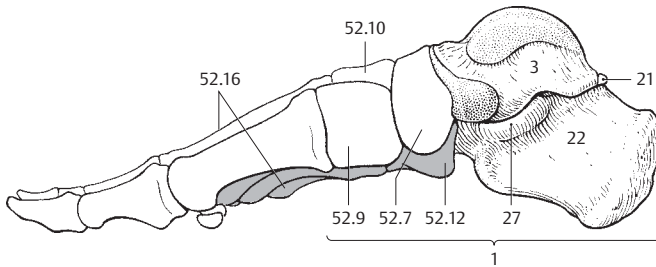
B Right talus, inferior view



C Right calcaneus, lateral view

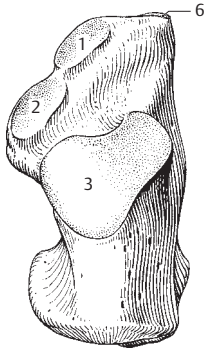


D Right calcaneus, medial view

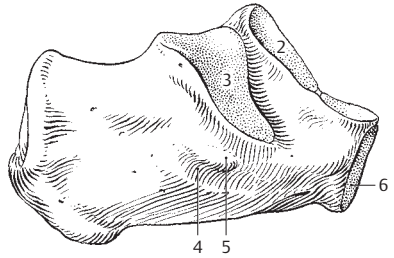


E Right foot, medial view

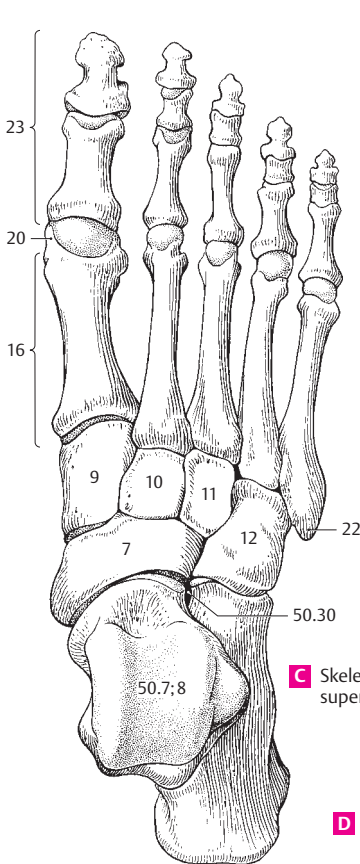
- 1 **Anterior facet for the talus.** Facies articularis talaris anterior. Small anterior articular surface for the head of the talus. A B
- 2 **Middle facet for the talus.** Facies articularis talaris media. Middle articular surface for the talus separated from the posterior facet by the sulcus calcanei. A B
- 3 **Posterior facet for the talus.** Facies articularis talaris posterior. Large posterior surface for articulation with the talus. A B
- 4 **Sulcus tendinis m. peronei (fibularis) longi.** Groove for the tendon of the peroneus longus muscle on the lateral aspect of the calcaneus below the peroneal trochlea. B
- 5 **Peroneal trochlea.** Trochlea peronealis (fibularis). Bony eminence above the groove for the tendon of the peroneus longus. It functions like a pulley for this muscle and attaches a part of the peroneal retinaculum. The peroneal brevis runs cranial to the trochlea. B
- 6 **Facies articularis cuboidea.** Cuboid articular surface forming the anterior aspect of the calcaneus. A B
- 7 **Navicular bone.** Os naviculare. Bone medial to the head of the talus and the three cuneiform bones. C D
- 8 **Tuberosity of navicular bone.** Tuberositas ossis navicularis. Rough area on the inferomedial aspect of the navicular bone, for attachment of the tibialis posterior muscle. It is palpable through the skin. D
- 9 **Medial cuneiform.** Os cuneiforme mediale. Most medial of the cuneiform bones, located between the navicular and the 1st metatarsal bones. Its wedge-shaped base is directed downward. C D
- 10 **Intermediate cuneiform.** Os cuneiforme intermedium. Middle cuneiform bone located between the navicular and 2nd metatarsal bones. Its wedge-shaped base is directed upward. C D
- 11 **Lateral cuneiform.** Os cuneiforme laterale. Most lateral cuneiform bone located between the navicular and 3rd metatarsal bones. Its wedge-shaped base is directed upward. C D
- 12 **Cuboid bone.** Os cuboideum. Bone found between the calcaneus and the fourth and fifth metatarsals. C D
- 13 **Groove for tendon of peroneus longus.** Sulcus tendinis musculi peronei (fibularis) longi. Groove on the inferolateral aspect of the cuboid that serves as a guide for the tendon. D
- 14 **Tuberosity of cuboid.** Tuberositas ossis cuboidei. Bony elevation on the inferior aspect of the cuboid bone proximal to the groove for the peroneus longus. D
- 15 **Calcanean process.** Processus calcaneus. Plantar process of the cuboid bone. The inferior segment of the proximal articular surface projects upwardly and obliquely to support the calcaneus. D
- 16 **METATARSUS.** The part of the foot situated between the tarsus and the toes. It comprises five metatarsal bones. C D
- 17 **METATARSAL BONES.** Ossa metatarsi (metatarsalia) [I–V]. The five metatarsal bones. D
- 18 **Base of metatarsal bone.** Basis metatarsalis. The thickened proximal end of the metatarsal bones. D
- 19 **Shaft of metatarsal bone.** Corpus metatarsale. D
- 20 **Head of metatarsal bone.** Caput metatarsale. C D
- 21 **Tuberosity of first metatarsal.** Tuberositas ossis metatarsalis primi (I). Protuberance projecting downward and laterally from the proximal part of the first metatarsal bone. D
- 22 **Tuberosity of fifth metatarsal.** Tuberositas ossis metatarsalis quinti (V). Protuberance projecting laterally from the proximal part of the fifth metatarsal bone. Attachment site of the peroneus brevis muscle. C D
- 23 **PHALANGES OF TOES.** Ossa digitorum pedis. C D
- 24 **PHALANGES.** Osseous segments or bones that comprise the toes. C D
- 25 **Proximal phalanx.** Phalanx proximalis. First or proximal phalanx of the toes. D
- 26 **Middle phalanx.** Phalanx media. Middle segment of the toes. D
- 27 **Distal phalanx.** Phalanx distalis. Distal or terminal nail-bearing bone of the toe. D
- 28 **Distal tuberosity of toes.** Tuberositas phalangis distalis. Roughened area located on the plantar aspect of the distal end of the distal phalanx for attachment of the tactile pads. D
- 29 **Base of phalanx.** Basis phalangis. Proximal end of each phalanx with an acetabular articular surface. D
- 30 **Shaft of phalanx.** Corpus phalangis. D
- 31 **Head of phalanx.** Caput phalangis. Distal, articular end of the phalanx. D
- 32 **Sesamoid bones.** Ossa sesamoidea. Wormian bones embedded in tendons or ligaments. They regularly occur below the head of the first metatarsal on both sides of the tendon of the flexor hallucis longus muscle. D



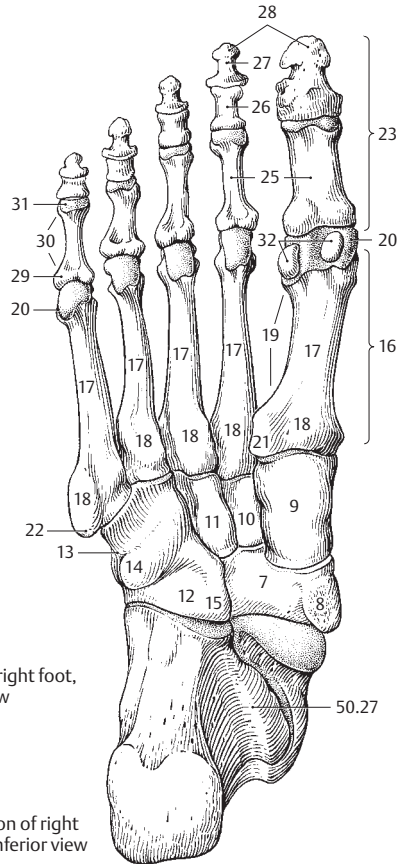
A Right calcaneus, superior view



B Right calcaneus, lateral view



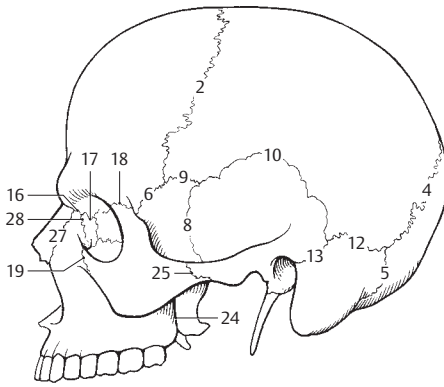
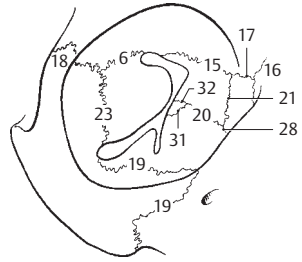
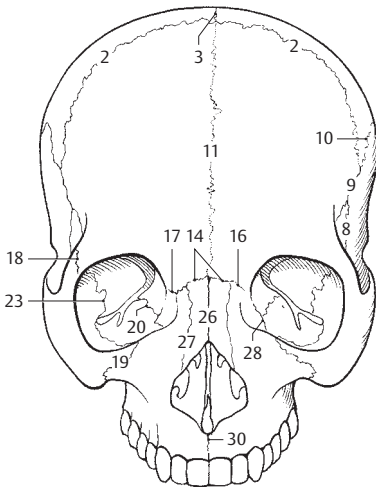
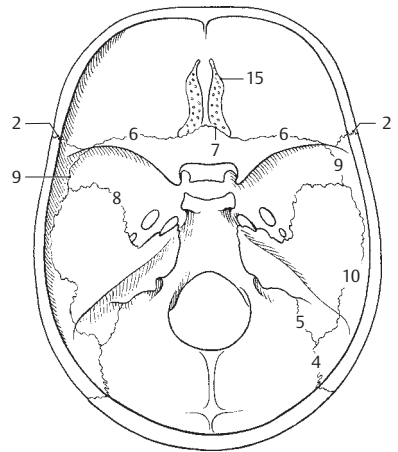
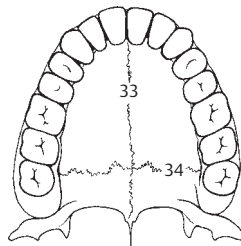
C Skeleton of right foot, superior view



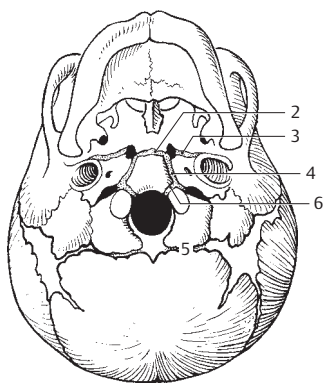
D Skeleton of right foot, inferior view

ARTICULAR SYSTEM

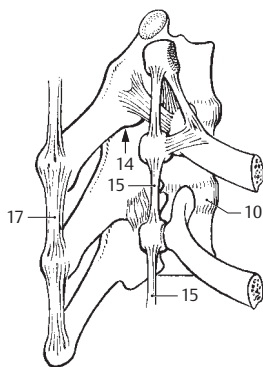
- 1 **SUTURES OF THE SKULL.** Suturae cranii (craniales).
- 2 **Coronal suture.** Sutura coronalis. It lies between the frontal bone and the two parietal bones. A C D
- 3 **Sagittal suture.** Sutura sagittalis. The median suture situated between the right and left parietal bones. C
- 4 **Lambdoidal suture.** Sutura lamboidea. It is located between the occipital bone and the two parietal bones. A D
- 5 **Occipitomastoid suture.** Sutura occipitomas-toidea. Continuation of the lambdoidal suture that extends to the base of the skull. A D
- 6 **Sphenofrontal suture.** Sutura sphenofrontalis. Smooth suture that extends flatly upward and backward lateral to the skull to join the greater wing of the sphenoid bone and the frontal bone. In the skull, it joins the frontal bone and the lesser wing of the sphenoid bone. A B D
- 7 **Sphenoethmoidal suture.** Sutura sphenoeth-moidalis. Short line in front of the jugum sphenoidale that connects the body of the sphenoid and the ethmoid. D
- 8 **Sphenosquamosal suture.** Sutura sphenosqua-mosa. Line of junction between the squamous portion of the temporal bone and the greater wing of the sphenoid. A C D
- 9 **Sphenoparietal suture.** Sutura sphenoparietalis. Line of junction between the greater wing of the sphenoid and the parietal bone. A C D
- 10 **Squamous suture.** Sutura squamosa. Line of junction between the squamous temporal and parietal bones. A C D
- 11 **Frontal (metopic) suture.** [Sutura frontalis (su-tura metopical)]. Suture connecting the right and left halves of the frontal bone. It generally fuses within 2 to 3 years after birth, but persists in 7–8% of all Central Europeans. C
- 12 **Parietomastoid suture.** Sutura parietomas-toidea. Posterior suture connecting the parietal bone and the mastoid process of the temporal bone. A
- 13 **Squamosomastoid suture.** [Sutura squamo-somastoidea]. Line of junction between the squamous and mastoid portions of the temporal bone that generally fuses early in life. A
- 14 **Frontonasal suture.** Sutura frontonasalis. Anterior line of junction between the frontal and nasal bones. C
- 15 **Frontoethmoidal suture.** Sutura frontoeth-moidalis. Internal line of junction between the ethmoid and frontal bones. B D
- 16 **Frontomaxillary suture.** Sutura frontomaxil-laris. Suture lateral to the nasal bone that connects the nasal portion of the frontal bone and the frontal process of the maxilla. A B C
- 17 **Frontolacrimal suture.** Sutura frontolacrimalis. Line of junction between the frontal and lacrimal bones. A B C
- 18 **Frontozygomatic suture.** Sutura frontozygo-matica. Suture at the lateral margin of the orbit between the frontal and zygomatic bones. A B C
- 19 **Zygomaticomaxillary suture.** Sutura zygomaticomaxillaris. Suture in the floor of the orbit connecting the zygomatic bone and the maxilla. A B C
- 20 **Ethmoidomaxillary suture.** Sutura ethmoi-domaxillaris. Suture in the medial wall of the orbit connecting the orbital plate of the ethmoid bone and the maxilla. B C
- 21 **Ethmoidolacrimal suture.** Sutura ethmoidolacrimalis. Suture in the medial wall of the orbit between the ethmoid and lacrimal bones. B
- 22 **Sphenovomerine suture.** Sutura sphenovomer-iana. Suture at the nasal septum connecting the sphenoid bone and the vomer.
- 23 **Sphenozygomatic suture.** Sutura sphenozygo-matica. Suture in the lateral wall of the orbit connecting the greater wing of the sphenoid and zygomatic bone. B C
- 24 **Sphenomaxillary suture.** Sutura sphenomaxil-laris. Inconstant suture connecting the ptery-goid process and the maxillae lateral to the palatine bone. A
- 25 **Temporozygomatic suture.** Sutura temporozy-gomatica. Suture connecting the zygomatic process of the temporal bone and the zygomatic bone on the lateral aspect of the zygomatic arch. A
- 26 **Internasal suture.** Sutura internasalis. Suture connecting the right and left nasal bones. C
- 27 **Nasomaxillary suture.** Sutura nasomaxillaris. Suture connecting the nasal bone and the frontal process of the maxilla. A C
- 28 **Lacrimomaxillary suture.** Sutura lacrimomax-illaris. Suture connecting the anterior margin of the lacrimal bone and the maxilla. A B C
- 29 **Lacrimoconchal suture.** Sutura lacrimo-conchalis. Suture within the nasal cavity connecting the lacrimal bone and the inferior nasal concha.
- 30 **Intermaxillary suture.** Sutura intermaxillaris. Medial line of junction between the right and left maxillary bones, located just below the anterior nasal spine. C
- 31 **Palatomaxillary suture.** Sutura palatomaxil-laris. Line of junction between the palatine bone and the maxilla situated posteriorly in the orbit and on the lateral wall of the nasal cavity. B
- 32 **Palatoethmoidal suture.** Sutura palatoeth-moidalis. Suture in the back of the orbit connect-ing the palatine and ethmoid bones. B
- 33 **Median palatine suture.** Sutura palatina medi-ana. Suture within the oral cavity connecting both halves of the palatine bone. E
- 34 **Transverse palatine suture.** Sutura palatina transversa. Line of junction between the palatine process of the maxilla and the palatine bone. E

**A** Skull from left**B** Right orbit, anterior view**C** Skull, anterior view**D** Base of skull, superior view**E** Hard palate, inferior view

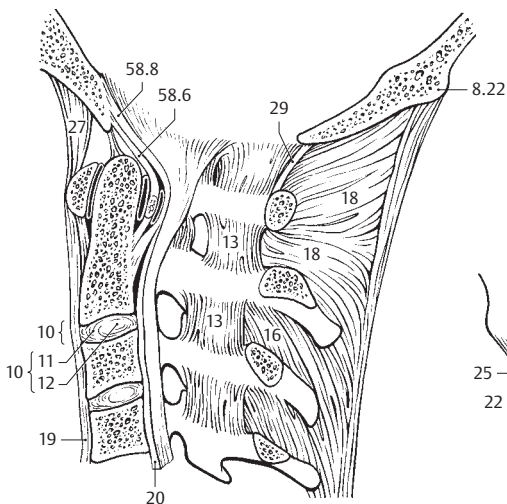
- 1 **CRANIAL SYNCHONDROSES.** Synchondroses cranii (craniales). Cartilaginous joints between skull bones. Most are temporary and become ossified.
- 2 **Spheno-occipital synchondrosis.** Synchondrosis spheno-occipitalis. Developmental cartilaginous joint postero-inferior to the sella turcica between the sphenoid and occipital bones. A
- 3 **Sphenopetrosal synchondrosis.** Synchondrosis sphenopetrosa. Cartilaginous union between the sphenoid and petrous bones in the lateral continuation of the foramen lacerum, for transmission of the lesser petrosal nerve. A
- 4 **Petro-occipital synchondrosis.** Synchondrosis petro-occipitalis. Anteromedial cartilaginous continuation of the jugular foramen. A
- 4a **Intraoccipital synchondroses.** Synchondroses intraoccipitalis. Cartilaginous joints between developmental parts of the occipital bone.
- 5 **Posterior intraoccipital synchondrosis.** [Synchondrosis intra-occipitalis posterior]. Developmental synchondrosis between the posterior and lateral ossific centers of the occipital bone. It usually disappears within 1–2 years after birth. A
- 6 **Anterior intraoccipital synchondrosis.** [Synchondrosis intra-occipitalis anterior]. Developmental cartilaginous joint between the anterior and lateral ossific centers of the occipital bone beginning at the anterior circumference of the foramen magnum. Disappears during the 6th year of life. A
- 7 **Sphenoethmoidal synchondrosis.** Synchondrosis spheno-ethmoidalis. Cartilaginous precursor of the spheno-ethmoidal suture. See page 54.7.
- 8 **JOINTS OF VERTEBRAL COLUMN, THORAX AND SKULL.** Articulationes columnae vertebralis, Thoracis et cranii. The connections of the vertebral column, thorax and skull.
- 9 **Intervertebral symphysis.** Symphysis intervertebralis. Union between adjacent vertebral bodies.
- 10 **Intervertebral disc.** Discus intervertebralis. An elastic plate consisting of ring-shaped fibrous lamellae, fibrocartilage, and a central gelatinous nucleus located on either side of a vertebral body, between the adjacent vertebrae. B C
- 11 **Anulus fibrosus.** Annular fibrous connection between adjacent vertebral bodies consisting of obliquely oriented connective tissue fibers arranged in alternating directions. B
- 12 **Nucleus pulposus.** Gelatinous, semifluid mass forming the central core of an intervertebral disc. B
- 13 **Ligamenta flava.** Yellow ligaments. Elastic networks of roughly parallel fibers between the vertebral arches. B
- 14 **Zygapophysial joints.** Articulationes zygapophysiales. Joints between articular processes of vertebrae. C
- 15 **Intertransverse ligaments.** Ligg. intertransversaria. Narrow ligaments between transverse processes of vertebrae. C
- 16 **Interspinal ligaments.** Ligg. interspinalia. Broad ligaments between adjacent spinous processes. B
- 17 **Supraspinal ligaments.** Ligg. supraspinalia. Longitudinal ligaments connecting the tips of the spinous processes. C
- 18 **Ligamentum nuchae.** Sagittal extension of the supraspinal ligaments in the upper neck region. B
- 19 **Anterior longitudinal ligament.** Lig. longitudinale anterius. Longitudinal ligament attached to the ventral surface of the vertebral bodies. B
- 20 **Posterior longitudinal ligament.** Lig. longitudinale posterius. Longitudinal ligament connecting the intervertebral discs. It is attached to the dorsal surface of the vertebral bodies and thus lies on the anterior wall of the vertebral canal. It fuses with the tectorial membrane from the 3rd cervical vertebrae upward. B
- 21 **Sacrococcygeal joint.** Articulatio sacrococcygea. Connection between the sacrum and coccyx; it is frequently a true joint, but often occurs as a synchondrosis. D
- 22 **Superficial dorsal sacrococcygeal ligament.** Lig. sacrococcygeum posterius (dorsale) superficiale. D
- 23 **Deep dorsal sacrococcygeal ligament.** Lig. sacrococcygeum posterius (dorsale) profundum. D
- 24 **Ventral sacrococcygeal ligament.** Lig. sacrococcygeum anterius (ventrale).
- 25 **Lateral sacrococcygeal ligament.** Lig. sacrococcygeum laterale. D
- 26 **Atlanto-occipital joint.** Articulatio atlanto-occipitalis. Joint between the atlas and the occipital bone. See page 59 A B
- 27 **Anterior atlanto-occipital membrane.** Membrana atlanto-occipitalis anterior. Membranous connection between the arch of the atlas and the occipital bone. It lies in front of the apical ligament of the dens. B
- 28 **Anterior atlanto-occipital ligament.** [Lig. atlanto-occipitale anterius]. Thickened portion of the atlanto-occipital membrane emanating from the anterior tubercle.
- 29 **Posterior atlanto-occipital membrane.** Membrana atlanto-occipitalis posterior. Connection between the arch of the atlas and the occipital bone situated in the posterior wall of the vertebral canal. B
- 30 **Lateral atlanto-occipital membrane.** Lig. atlanto-occipitale laterale. Oblique tract of fibers extending from the transverse process of the atlas to the jugular process of the occipital bone.



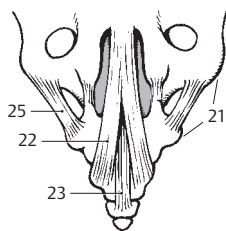
A Skull of newborn,
inferior view



C Ligaments of vertebral column
and ribs, lateral view

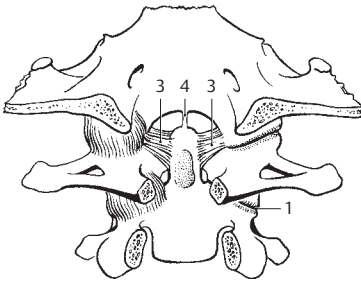


B Ligaments of cervical vertebral column,
medial view

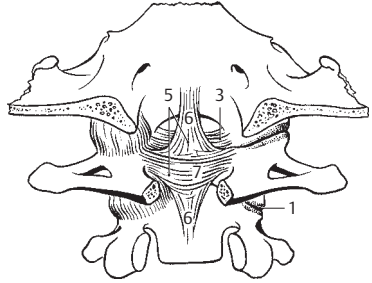


D Coccygeal ligaments, posterior view

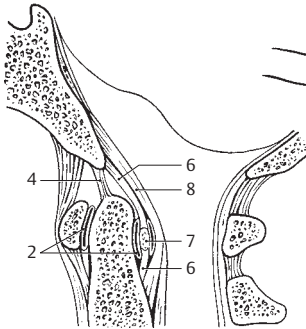
- 1 **Lateral atlanto-axial joint.** *Articulatio atlanto-axialis lateralis.* Joint between the inferior articular facet of the atlas and the superior articular facet of the axis. A B
- 2 **Median atlanto-axial joint.** *Articulatio atlanto-axialis mediana.* Articulation between the atlas and the dens of the axis. C
- 3 **Alar ligaments.** *Ligg. alaria.* Paired ligaments extending from the dens of the axis to the lateral margin of the foramen magnum. A B
- 4 **Apical ligament of the dens.** *Lig. apicis dentis.* Unpaired ligament extending from the apex of the dens to the anterior margin of the foramen magnum. A C
- 5 **Cruciform ligament of atlas.** *Lig. cruciforme atlantis.* Cruciate ligament consisting of the two following ligamentous bands (6, 7) located between the dens and the tectorial membrane. B
- 6 **Longitudinal fasciculi of cruciform ligament.** *Fasciculi longitudinales.* Connective tissue tracts from the body of the axis to the anterior margin of the foramen magnum. They are situated behind the dens and its apical ligament. B C
- 7 **Transverse ligament of atlas.** *Lig. transversum atlantis.* Part of the cruciform ligament of the atlas passing behind the dens and extending transversely from one side of the atlas to the other. It holds the dens in position. B C
- 8 **Tectorial membrane.** *Membrana tectoria.* Bilayered continuation of the posterior longitudinal ligament. It passes from the axis to the anterior margin of the foramen magnum and is continuous with the dura-periosteal layer of the skull base. C
- 9 **JOINTS OF THORAX.** *Articulationes thoracis.* Articular connections of the skeleton of the thorax.
- 10 **COSTOVERTEBRAL JOINTS.** *Articulationes costovertebrales.* Joints between the ribs and vertebrae. D
- 11 **Joints of rib heads.** *Articulatio capitis costae (costalis).* Articular unions that connect the heads of the ribs with the vertebral bodies and intervertebral discs. D
- 12 **Radiate ligament of head of rib.** *Lig. capitis costae radiatum.* Ligament radiating predominantly from the anterior side of the head of a rib to the adjacent vertebral body and intervertebral disc. D E
- 13 **Intra-articular ligament of head of rib.** *Lig. capitis costae intra-articulare.* Ligament extending from the crest of the head of the rib to the intervertebral disc. It lies between the two articular facets of the head of the rib. E
- 14 **Costotransverse joint.** *Articulatio costotransversaria.* Joint between the articular surface of the tubercle of the rib and the transverse process of the corresponding vertebra. D
- 15 **Costotransverse ligament.** *Lig. costotransversarium.* Ligament between the neck of a rib and the transverse process of the corresponding vertebra. D
- 16 **Superior costotransverse ligament.** *Lig. costotransversarium superius.* Ligament extending from a rib to the next higher transverse process. E
- 17 **Lateral costotransverse ligament.** *Lig. costotransversarium laterale.* Ligament extending from the end of a transverse process to the corresponding rib. D
- 18 **Lumbocostal ligament.** *Lig. lumbocostale.* Deep layer of the thoracolumbar fascia. Fibrous connection between the costal process of the lumbar vertebrae, the twelfth rib, and the edge of the pelvis.
- 19 **Costotransverse foramen.** *Foramen costotransversarium.* Opening for the intercostal nerves between the superior costotransverse ligament and the neck of the rib. E
- 20 **Sternocostal joint.** *Articulationes sternocostales.* Articulations between the costal cartilage and sternum. F
- 21 **Intra-articular sternocostal ligament.** *Lig. sternocostale intra-articulare.* Ligament within the articular cavity between the costal cartilage and sternum, especially pronounced at the 2nd rib. F
- 22 **Radiate sternocostal ligaments.** *Ligg. sternocostalia radiata.* Fiber tracts located in front of the sternocostal joint and radiating from the end of the costal cartilage to the sternum. F
- 23 **Sternal membrane.** *Membrana sterni.* Membranous covering of the anterior surface of the sternum formed by the fibers of the radiate sternocostal ligaments. F
- 24 **Costoxiphoid ligaments.** *Ligg. costoxiphoidae.* Fiber tracts extending downward from the 7th costal cartilage to the xiphoid process.
- 25 **External intercostal membrane.** *Membrana intercostalis externa.* Continuation of the external intercostal muscles at the sternal end of the intercostal space. F
- 26 **Internal intercostal membrane.** *Membrana intercostalis interna.* Continuation of the internal intercostal muscles near the vertebral end of the intercostal space. E
- 26a **Sternocostal synchondrosis of the first rib.** *Synchondrosis sternocostalis costae primae.*
- 27 **Interchondral joints.** *Articulationes interchondrales.* Articulations between the costal cartilages, usually between those of ribs 6–9. See page 7 D
- 28 **Costochondral joints.** *Articulationes costochondrales.* Unions between the bony and cartilaginous parts of ribs without an articular cavity.



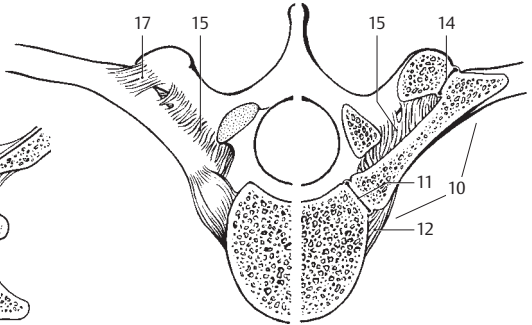
A Dens of axis with ligaments, posterior view



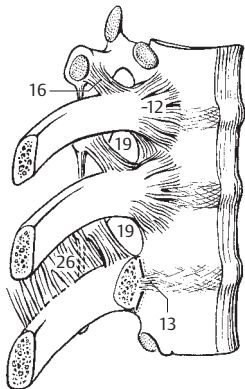
B Atlanto-occipital articulation, posterior view



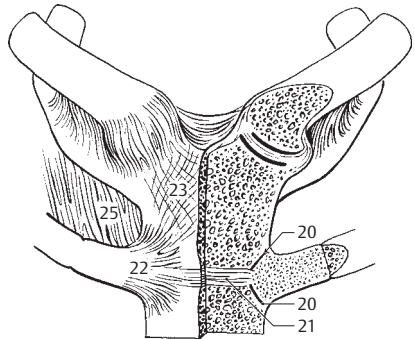
C Ligaments between atlas, axis and occipital bone



D Ligaments of vertebral column and ribs, on right in cross section

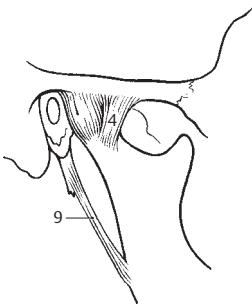


E Ligaments of vertebral column and ribs

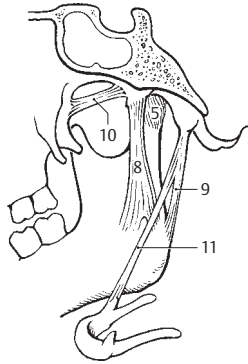


F Sternocostal articulations

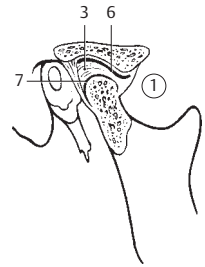
- 1 **SYNOVIAL JOINTS OF THE SKULL.** Articulationes synoviales cranii. Cf. pp. 56,26, 58,1, 58,2
- 2 **Temporomandibular joint.** Articulatio temporomandibularis. A B C
- 3 **Articular disc.** Discus articularis. Biconcave disc of fibrous tissue and fibrocartilage positioned between the head of the mandible and the articular fossa. Since it is connected with the articular capsule on all sides, it divides the joint into two compartments, both of which are functional units of the discocapsular system. C
- 4 **Lateral (temporomandibular) ligament.** Lig. laterale. A strong fibrous band occasionally present on the lateral surface of the joint. It passes obliquely upward and forward from the neck of the mandible. A
- 5 **Medial ligament.** Lig. mediale. Reinforcement of the medial wall of the capsule. B
- 6 **Superior synovial membrane.** Membrana synovialis superior. Synovial lining of the superior articular cavity. C
- 7 **Inferior synovial membrane.** Membrana synovialis inferior. Synovial lining of the inferior articular cavity. C
- 8 **Sphenomandibular ligament.** Lig. sphenomandibulare. Flat ligament on the inner aspect of the mandibular ramus extending from the mandibular foramen to the spine of the sphenoid bone lateral to the foramen spinosum. B
- 9 **Stylomandibular ligament.** Lig. stylomandibulare. Ligament passing from the anterior surface of the styloid process to the angle of the mandible. A B
- 10 **Pterygospinal ligament.** Lig. pterygospinale. Broad connective tissue band extending from the upper part of the lateral plate of the pterygoid process to the spine of the sphenoid. B
- 11 **Stylohyoid ligament.** Lig. stylohyoideum. Ligament running between the styloid process and the lesser horn of the hyoid bone. Vestige of the second pharyngeal arch. B
- 12 **JOINTS OF THE SHOULDER GIRDLE.** Articulationes cinguli pectoralis. D E F G
- 13 **Coracoacromial ligament.** Lig. coracoacromiale. Strong band extending from the coracoid process to the acromion. It forms the roof of the shoulder joint. D
- 14 **Superior transverse scapular ligament.** Lig. transversum scapulae superius. Ligament lying medial to the coracoid process and bridging the scapular notch. D
- 15 **Inferior transverse scapular ligament.** [Lig. transversum scapulae inferius]. Weak fibrous band passing from the root of the spine of the scapula to the posterior margin of the glenoid cavity. F
- 16 **Acromioclavicular joint.** Articulatio acromioclavicularis. Joint between the acromion and the clavicle. D
- 17 **Acromioclavicular ligament.** Lig. acromioclavicularae. Strong fibrous band within and above the articular capsule serving to protect and hold together the clavicle and acromion. D
- 18 **Articular disc.** Discus articularis. Fibrocartilaginous interarticular disc. D
- 19 **Coracoclavicular ligament.** Lig. coracoclavicularae. Two-part band connecting the coracoid process and the clavicle. D
- 20 **Trapezoid ligament.** Lig. trapezoideum. The portion of the coracoclavicular ligament taking an upward and lateral course from the coracoid process to the clavicle. It lies between the conoid and coraco-acromial ligaments. D
- 21 **Conoid ligament.** Lig. conoideum. The portion of the coraco-clavicular ligament medial to the trapezoid ligament. It arises from the root of the coracoid process. D
- 22 **Sternoclavicular joint.** Articulatio sternoclavicularis. Two-chambered joint between the sternum and clavicle. G
- 23 **Articular disc.** Discus articularis. Interarticular disc anchored below to the first rib and above to the clavicle. G
- 24 **Anterior sternoclavicular ligament.** Lig. sternoclavicularae anterioris. Band that reinforces the anterior wall of the joint capsule. G
- 25 **Posterior sternoclavicular ligament.** Lig. sternoclavicularae posterioris. Band that reinforces the posterior wall of the joint capsule.
- 26 **Costoclavicular ligament.** Lig. costoclavicularae. Ligamentous union between the first rib and the clavicle lateral to the sternoclavicular joint. G
- 27 **Interclavicular ligament.** Lig. interclavicularae. Ligament passing across the suprasternal notch and uniting both clavicles. G
- 28 **JOINTS OF THE FREE UPPER LIMB.** Articulationes membri superioris liberi.
- 29 **Shoulder (glenohumeral) joint.** Articulatio humeri (glenohumeralis). D E F
- 30 **Glenoid lip.** Labrum glenoidale. The fibrocartilaginous margin of the bony glenoid cavity. E
- 31 **Coracohumeral ligament.** Lig. coracohumeralae. Thickened portion of the capsule passing from the root of the coracoid process to the upper margin of the greater and lesser tubercles. D E
- 32 **Glenohumeral ligaments.** Ligg. glenohumeralia. Three thickened bands (superior, middle, inferior) within the anterior wall of the capsule. D E



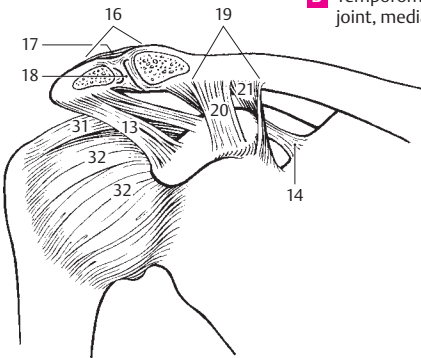
A Temporomandibular joint, lateral view



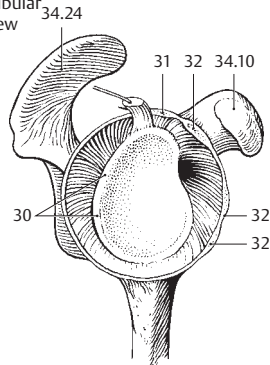
B Temporomandibular joint, medial view



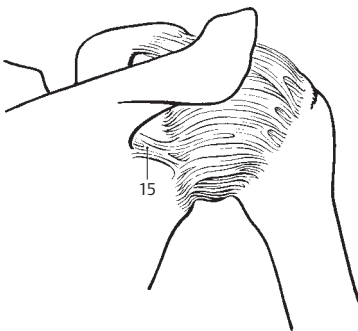
C Temporomandibular joint, sagittal section



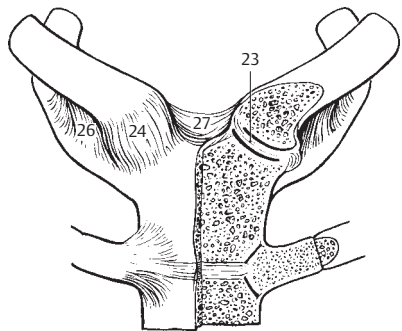
D Lateral ligaments of shoulder, anterior view



E Shoulder joint, disarticulated, lateral view

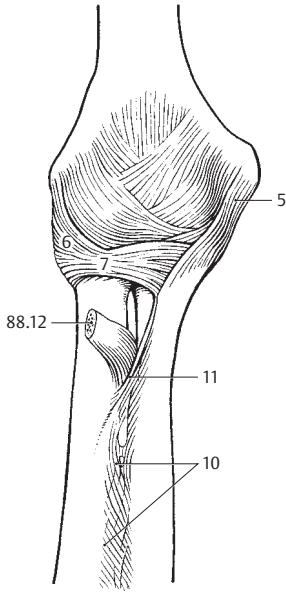


F Shoulder joint, posterior view

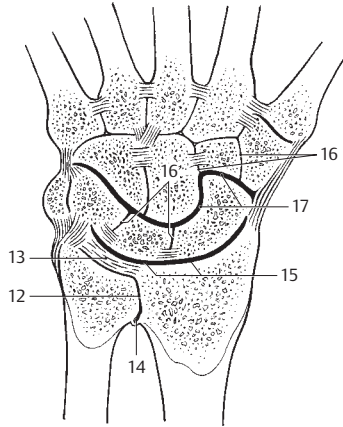


G Sternoclavicular joints

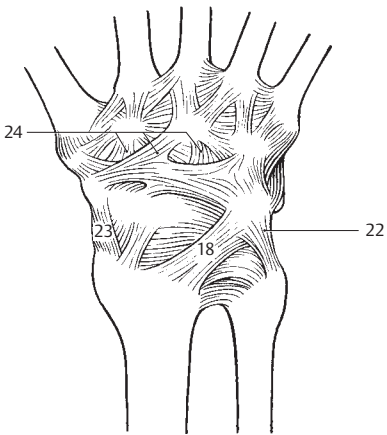
- 1 **Elbow joint.** *Articulatio cubiti (cubitalis).* Articular connection between the upper arm and forearm. A
- 2 **Humeroulnar joint.** *Articulatio humero-ulnaris.* Joint between the humerus and ulna.
- 3 **Humeroradial joint.** *Articulatio humero-radialis.* Joint between the humerus and radius.
- 4 **Proximal radioulnar joint.** *Articulatio radio-ulnaris proximalis.* Joint formed by the articular circumference of the radius and the radial notch of the ulna.
- 5 **Ulnar collateral ligament.** *Lig. collaterale ulnare.* Collateral ligament on the medial part of the arm between the ulna and humerus. A
- 6 **Radial collateral ligament.** *Lig. collaterale radiale.* Ligament which spreads from the lateral epicondyle to the annular ligament of the radius and the ulna. A
- 7 **Annular ligament of the radius.** *Lig. anulare radii.* Circular band embracing a part of the articular circumference of the radius. It is attached to the anterior and posterior margins of the radial notch of the ulna. A
- 8 **Quadrante ligament.** *Lig. quadratum.* Thin band of fibers passing from the distal margin of the radial notch of the ulna to the neck of the radius.
- 9 **Radioulnar syndesmosis (joint).** *Syndesmosis [articulatio] radioulnaris.* Fibrous joint between the radius and ulna.
- 10 **Interosseous membrane of forearm.** *Membrana interossea antebrachii.* Membranous sheet which spreads between the interosseous margins of the radius and ulna. A
- 11 **Oblique cord.** *Chorda obliqua.* Ligamentous band extending obliquely downward from the ulnar tuberosity to the radius. It runs in an opposite direction to most fibers of the interosseous membrane. A
- 12 **Distal radioulnar joint.** *Articulatio radioulnaris distalis.* B
- 13 **Articular disc.** *Discus articularis.* Interarticular disc between the ulna and carpus. It is attached at the radius and styloid process of the ulna and, as an intra-articular ligament, it connects the radius and ulna. B
- 14 **Recessus saciformis.** Proximal extension of the flaccid articular capsule. B
- 15 **Radiocarpal joint.** *Articulatio radiocarpalis.* Proximal wrist joint between the proximal row of carpal bones and the radius including the articular disc. B
- 15a **Carpal joints.** *Articulationes carpi.*
- 16 **Intercarpal joints.** *Articulationes intercarpales.* Joints between the carpal bones permitting only slight movement. B
- 17 **Midcarpal joint.** *Articulatio mediocarpalis.* The distal wrist joint between the proximal and distal rows of carpal bones. B
- 18 **Dorsal radiocarpal ligament.** *Lig. radiocarpale dorsale.* Ligament on the dorsum of the wrist extending from the radius to the triquetrum bone. C
- 19 **Palmar radiocarpal ligament.** *Lig. radiocarpale palmare.* Ligament on the flexor side radiating from the radius to the lunate and capitate bones. D
- 20 **Palmar ulnocarpal ligament.** *Lig. ulnocarpale palmare.* Ligament extending from the flexor side of the head of the ulnar chiefly to the capitate bone. It often unites with fibers of the palmar radiocarpal ligament. D
- 21 **Radiate carpal ligament.** *Lig. carpi radiatum.* Groups of fibers radiating to both sides of the wrist mainly from the head of the capitate bone. D
- 22 **Ulnar carpal collateral ligament.** *Lig. collaterale carpi ulnare.* Collateral ligament extending from the styloid process of the ulna to the triquetrum and pisiform bones. CD
- 23 **Radial carpal collateral ligament.** *Lig. collaterale carpi radiale.* External collateral ligament passing from the styloid process of the radius to the scaphoid bone. CD
- 24 **Dorsal intercarpal ligaments.** *Ligg. intercarpalia dorsalia.* Ligamentous bands extending between the proximal and distal rows of carpal bones on the dorsum of the wrist. C
- 25 **Palmar intercarpal ligaments.** *Ligg. intercarpalia palmaria.* Groups of ligaments between the carpal bones on the palmar aspect below the radiate carpal ligament. D



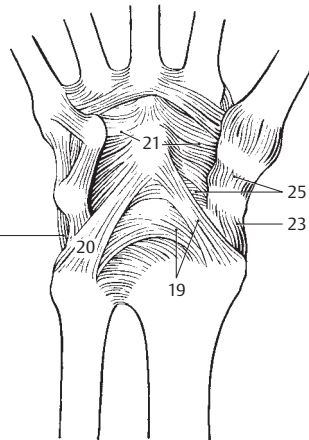
A Elbow joint, anterior view



B Carpal joints in horizontal section

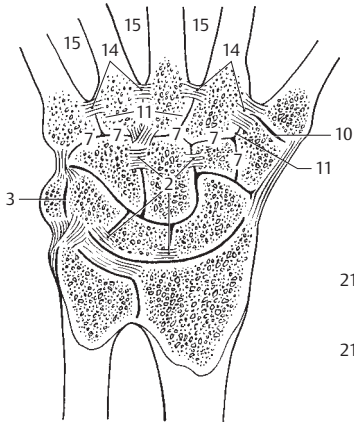


C Carpal ligaments, dorsal view

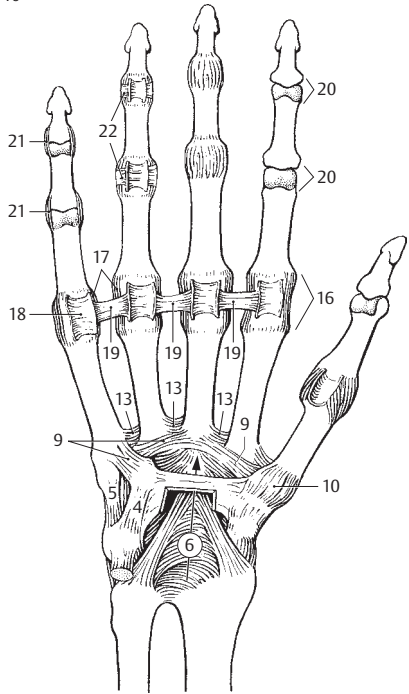


D Carpal ligaments, palmar view

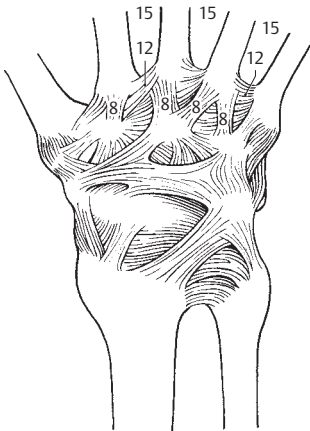
- 1 **JOINTS OF THE HAND.** Articulationes manus. A B C
- 2 **Interosseous intercarpal ligaments.** Ligg. intercarpalia interossea. Ligaments penetrating directly through the joint clefts between the carpal bones within a row. A
- 3 **Pisotriquetral joint.** Articulatio ossis pisiformis. Articulation between the pisiform and triquetrum bones. A
- 4 **Pisohamate ligament.** Lig. pisohamatum. Medial continuation of the tendon of the flexor carpi ulnaris to the hook of the hamate bone. B
- 5 **Pisometacarpal ligament.** Lig. pisometacarpale. Lateral continuation of the tendon of the flexor carpi ulnaris to the base of the fifth metacarpal. B
- 6 **Carpal canal or tunnel.** Canalis carpi (carpalis). Palmar canal located between the tubercles of the scaphoid and trapezium on the one side and the pisiform bone and the hook of the hamulus on the other side. It is bridged over by the flexor retinaculum (93.26). B
- 7 **Metacarpal articulations.** Articulationes carpometacarpales. Slightly movable joints between the distal carpal bones and the metacarpals. A
- 8 **Dorsal carpometacarpal ligaments.** Ligg. carpometacarpalia dorsalia. Rigid ligaments on the dorsum of the hand between the distal carpal bones and the metacarpal bones. C
- 9 **Palmar carpometacarpal ligaments.** Ligg. carpometacarpalia palmaria. Ligaments on the palmar side of the hand between the distal carpal bones and the metacarpal bones. B
- 10 **Carpometacarpal joint of the thumb.** Articulatio carpometacarpalis pollicis. Saddle joint between the first metacarpal and the trapezium. A B
- 11 **Intermetacarpal joints.** Articulationes intermetacarpales. Joints between the bases of the metacarpal bones. A
- 12 **Dorsal metacarpal ligaments.** Ligg. metacarpalia dorsalia. Ligaments between the proximal ends of the metacarpals on the extensor side. C
- 13 **Palmar metacarpal ligaments.** Ligg. metacarpalia palmaria. Ligaments between the bases of the metacarpal bones on the palmar side. B
- 14 **Interosseous metacarpal ligaments.** Ligg. metacarpalia interossea. Short, tense ligaments at the bases of the metacarpal bones. They lie in the intracapsular spaces between the dorsal and palmar metacarpal ligaments. A
- 15 **Interosseous spaces of metacarpus.** Spatia interossea metacarpi. Spaces between the metacarpal bones. A C
- 16 **Metacarpophalangeal joints.** Articulationes metacarpophalangeales. Joints between the heads of the metacarpal bones and the bases of the proximal phalanges. B
- 17 **Collateral ligaments.** Ligg. collateralia. Collateral ligaments of the metacarpophalangeal joints. They slacken during extension of the fingers and become tense when making a closed fist. B
- 18 **Palmar ligaments.** Ligg. palmaria. Fibers in the floor of the tendon sheaths extending from the root of the collateral ligaments to the palmar side. They should not be confused with the annular parts of the fibrous sheaths. See page 92.28. B
- 19 **Deep transverse metacarpal ligament.** Lig. metacarpale transversum profundum. Transversely oriented fibrous tracts on the palmar side of the heads of the metacarpal bones at the level of the joint spaces. They hold the distal parts of the metacarpus together. B
- 20 **Interphalangeal joints.** Articulationes interphalangeales manus. Middle and distal joints between the phalanges. B
- 21 **Collateral ligaments of the interphalangeal joints.** Ligg. collateralia. B
- 22 **Palmar ligaments.** Ligg. palmaria. Fibers which pass into the floor of the tendon sheaths above the interphalangeal joints. B



A Carpal joints in horizontal section

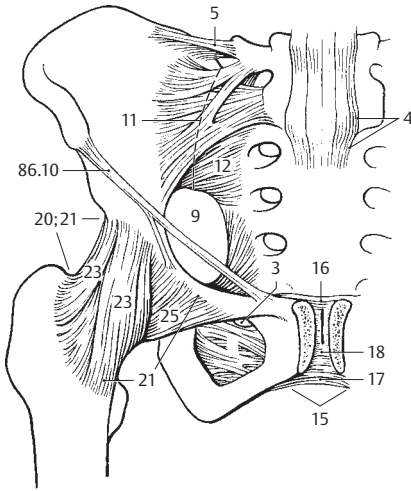


B Carpal joints, palmar view

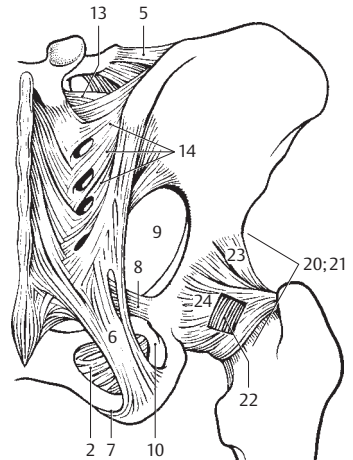


C Carpal joints of right hand, dorsal view

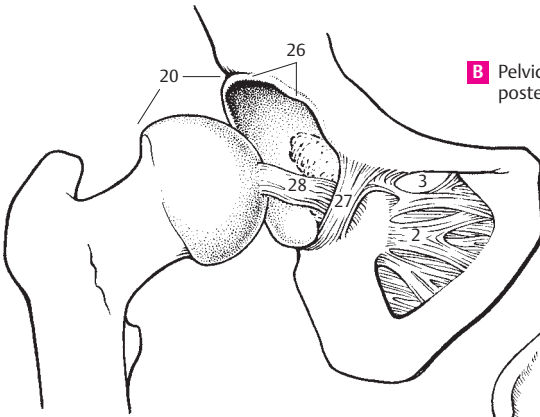
- 1 **JOINTS OF THE PELVIC GIRDL.** *Articulationes cinguli pelvici.*
- 2 **Obturator membrane.** *Membrana obturatoria.* Membrane which closes off the obturator foramen except for the obturator canal. It is covered by the obturator externus and internus muscles. A B C D
- 3 **Obturator canal.** *Canalis obturatorius.* Opening in the supralateral part of the obturator membrane. It corresponds to the obturator groove between the two obturator tubercles and is traversed by the obturator artery, vein and nerve. A C D
- 4 **Lumbosacral joint.** *Articulatio lumbosacralis.* Articulation between the sacrum and lumbar vertebra 5 (4). A
- 5 **Iliolumbar ligament.** *Lig. iliolumbale.* Strong ligament that passes to the ilium mainly from the transverse processes of L4 and 5. A B
- 6 **Sacroteruberous ligament.** *Lig. sacrotuberale.* Strong ligament that extends from the medial margin of the ischial tuberosity to the sacrum and ilium. B D
- 7 **Falciform process.** *Processus falciformis.* Slender extension of fibers from the sacrotuberous ligament to the inner aspect of the ischium. B D
- 8 **Sacrospinous ligament.** *Lig. sacrospinale.* Fibrous band medial to the sacrotuberous ligament. It passes from the ischial spine to the sacrum and coccyx and separates the greater from the lesser sciatic foramen. B D
- 9 **Greater sciatic foramen.** *Foramen sciaticum (ischiadicum) majus.* Foramen between the greater sciatic notch, sacrum, sacrospinous ligament and the upper part of the sacrotuberous ligament. It is traversed by the piriformis muscle, superior and inferior gluteal arteries, veins and nerves, the internal pudendal vein, pudendal nerve, sciatic nerve and posterior femoral cutaneous nerve. A B D
- 10 **Lesser sciatic foramen.** *Foramen sciaticum (ischiadicum) minus.* Foramen between the lesser sciatic notch and the sacrospinous and sacrotuberous ligaments. It transmits the obturator internus muscle as well as the internal pudendal artery and vein and the pudendal nerve to the ischiorectal fossa. B D
- 11 **Sacroiliac joint.** *Articulatio sacroiliaca.* Joint connected by fibers that permits little motion [[amphiarthrosis]]. It is located between the sacrum and the ilium and may become synostotic. A
- 12 **Ventral sacroiliac ligaments.** *Ligg. sacroiliaca anteriora (ventralia).* Thin but broad fibrous bands that extend from the anterior surface of the first and second sacral vertebrae to the ilium. A D
- 13 **Interosseous sacroiliac ligaments.** *Ligg. sacroiliaca interossea.* Dorsal mass of ligaments that pass from the tuberosity of the sacrum to the tuberosity of the ilium. B
- 14 **Dorsal sacroiliac ligaments.** *Ligg. sacroiliaca posteriora (dorsalia).* Superficial bundle of ligaments attached dorsally to the interosseous sacroiliac ligaments between the sacrum and ilium. B
- 15 **Pubic symphysis.** *Symphysis pubica.* Synchondrosis that articulates with the interpubic disc. A
- 16 **Superior pubic ligament.** *Lig. pubicum superius.* Fibrous connection between the two halves of the symphysis emanating from the pecten ossis pubis on either side. A
- 17 **Arcuate pubic ligament.** *Lig. arcuatum pubis.* Strong, curved ligament below the symphysis. A
- 18 **Interpubic disc.** *Discus interpubicus.* Fibrocartilage plate with a synovia-filled median groove, located between the articular surfaces made of hyaline cartilage on the right and left pubic bones. A
- 19 **JOINTS OF THE FREE LOWER LIMB.** *Articulationes membri inferioris liberi.*
- 20 **HIP JOINT.** *Articulatio coxae (iliofemoralis).* Joint formed by the acetabulum and the head of the femur. A B C
- 21 **Joint capsule.** *Capsula articularis.* It is attached anteriorly to the intertrochanteric line, posteriorly above to the intertrochanteric crest. A fracture of the neck of the femur can therefore be intracapsular when in the anterior region or extracapsular when in the posterior region. A
- 22 **Orbicular zone.** *Zona orbicularis.* Ligamentous fibers encircling the neck of the femur. B
- 23 **Iliofemoral ligament.** *Lig. iliofemorale.* Strong anterior ligament of the hip joint capsule extending from the ilium to the intertrochanteric line. A B
- 24 **Ischiofemoral ligament.** *Lig. ischiofemorale.* It radiates into the orbicular zone from the posterior margin of the acetabulum and is also attached to the anterior margin of the greater trochanter and to the intertrochanteric line. B
- 25 **Pubofemoral ligament.** *Lig. pubofemorale.* Ligament that arises medially from the joint capsule of the pubic bone and extends to the orbicular zone and to the part of the femur proximal to the lesser trochanter. A
- 26 **Acetabular lip.** *Labrum acetabulare.* A ring of fibrocartilage and connective tissue that completes and deepens the bony acetabulum. C
- 27 **Transverse acetabular ligament.** *Lig. transversum acetabuli.* It bridges the acetabular notch. C
- 28 **Ligament of head of femur.** *Lig. capitis femoris.* A smooth ligament extending from the acetabular notch to the pit on the head of the femur. It transmits blood vessels and has no direct mechanical action. C



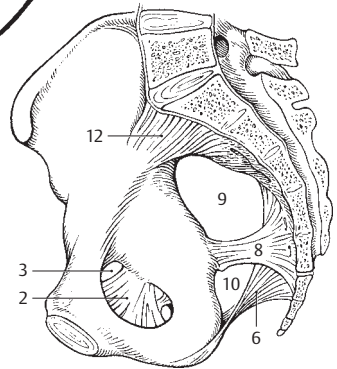
A Pelvic ligaments, anterior view



B Pelvic ligaments, posterior view

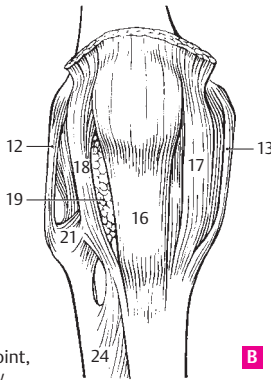


C Hip joint, opened

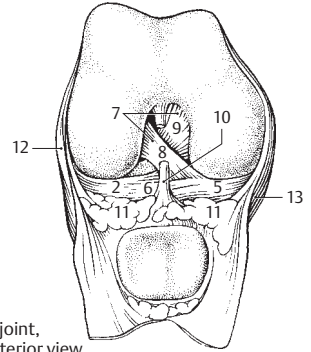


D Pelvic ligaments, medial view

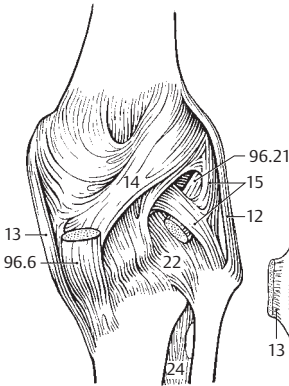
- 1 **Knee joint.** Articulatio genus [genualis]. ABCDE
- 2 **Lateral meniscus.** Meniscus lateralis. Roughly circular ring, the superficial layer of which is made of fibrocartilage, whereas the deep layer is more tendinous. It is located below the lateral femoral condyle and has close-set bases. It is relatively mobile because it is not fused with the lateral collateral ligament. B D E
- 3 **Anterior menisiofemoral ligament.** Lig. menisiofemorale anterius. Fibrous band occasionally found connecting the posterior part of the lateral meniscus with the anterior cruciate ligament. It passes in front of the posterior cruciate ligament. D E
- 4 **Posterior menisiofemoral ligament.** Lig. menisiofemorale posterius. It passes posterior to the lateral meniscus to the fibular surface of the medial femoral condyle behind the posterior cruciate ligament. D E
- 5 **Medial meniscus.** Meniscus medialis. A crescent-shaped ring segment located below the medial femoral condyle. It is not very mobile because it is fused with the medial collateral ligament. Its histological structure is like that of the lateral meniscus. B D E
- 6 **Transverse ligament of knee.** Lig. transversum genus [genuale]. Transverse ligament joining the anterior ends of the lateral and medial menisci. B D
- 7 **Cruciate ligaments of knee.** Ligg. cruciata genus [genualia]. They prevent displacement of the tibia and femur in the sagittal plane. B E
- 8 **Anterior cruciate ligament.** Lig. cruciatum anterius. It passes from the inner surface of the lateral femoral condyle obliquely forward and inferomedially to the anterior intercondylar area. It prevents inward rotation and forward displacement of the tibia toward the femur. B D E
- 9 **Posterior cruciate ligament.** Lig. cruciatum posterius. It passes from the inner surface of the medial femoral condyle to the posterior condylar area, stabilizes the joint when flexed, and prevents backward displacement of the tibia away from the femur. B D E
- 10 **Infrapatellar synovial fold.** Plica synovialis infrapatellaris. Connective tissue that often contains fat. It extends from the infrapatellar adipose body to the intercondylar fossa. B
- 11 **Alar folds.** Plicae alares. Deformable, paired bulges of the adipose body that fill empty spaces in the anterior part of the joint cavity. B
- 12 **Fibular collateral ligament.** Lig. collaterale fibulare. Lateral collateral ligament that extends from the lateral epicondyle to the head of the fibula independent of the capsule and meniscus. A B C D E
- 13 **Tibial collateral ligament.** Lig. collaterale tibiale. Medial collateral ligament extending from the medial epicondyle to the tibia. It is fused with the joint capsule and the meniscus. A B C D E
- 14 **Oblique popliteal ligament.** Lig. popliteum obliquum. Fibrous band originating in the posterior wall of the capsule, extending upward and outward from the tendon of the semimembranosus muscle, thereby reinforcing the capsule. C
- 15 **Arcuate popliteal ligament.** Lig. popliteum arcuatum. Curved band of fibers extending from the epicondyle, across the origin of the popliteal muscle to the head of the fibula, thus reinforcing the posterior wall of the capsule. C
- 16 **Patellar ligament.** Ligamentum patellae. Wide (2–3 cm) and thick (ca. 0.5 cm) fibrous band that forms the continuation of the tendon of the quadriceps femoris muscle. It extends from the apex of the patella to the tibial tuberosity. A
- 17 **Medial retinaculum of patella.** Retinaculum patellae mediale. Aponeurosis from a part of the vastus medialis muscle that extends medially from the patella and attaches to the medial margin of the tibial tuberosity. It maintains the pathway of movement of the patella via muscular contraction and serves as a reserve extension apparatus. A
- 18 **Lateral retinaculum of patella.** Retinaculum patellae laterale. Aponeurosis of a part of the vastus lateralis lateral to the patella with attachment lateral to the tibial tuberosity. Its action is comparable to that of no. 17. A
- 19 **Infrapatellar fat pad.** Corpus adiposum infrapatellare. Large, wedge-shaped mass of fatty tissue in front of the knee joint space. It includes the infrapatellar alar and synovial folds. A
- 20 **Tibiofibular joint.** Articulatio tibiofibularis. Articulation between the head of the fibula and the lateral condyle of the tibia. E
- 21 **Anterior ligament of head of fibula.** Lig. capitis fibulae anterius. Group of fibers passing anteriorly from the head of the fibula to the tibia, thus holding the two bones together. A
- 22 **Posterior ligament of head of fibula.** Lig. capitis fibulae posterius. Weaker group of fibers extending from the posterior part of the head of the fibula to the tibia. C D E
- 23 **Tibiofibular syndesmosis [joint].** Syndesmosis [articulatio] tibiofibularis. Distal union of tibia with fibula.
- 24 **Interosseous membrane.** Membrana interossea cruris. Membrane attached to the interosseous margins of the tibia and fibula. It is the field of origin of the lower leg muscles and ensures the stability of the malleolar bifurcation. A C F G
- 25 **Anterior tibiofibular ligament.** Lig. tibiofibulare anterius. Anterior fibrous bands connecting the fibular incisure to the lateral malleolus, thus stabilizing the malleolar bifurcation. F
- 26 **Posterior tibiofibular ligament.** Lig. tibiofibulare posterius. Posterior fibrous bands connecting the fibular incisure to the lateral malleolus, thus stabilizing the malleolar bifurcation. G



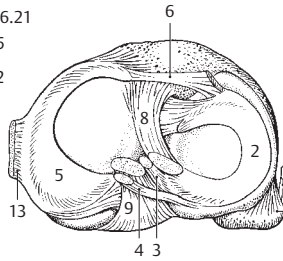
A Right knee joint, anterior view



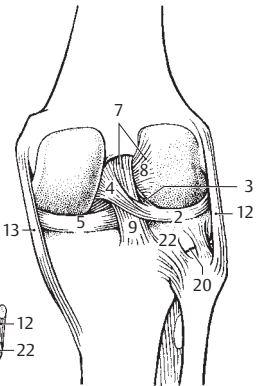
B Right knee joint, opened, anterior view



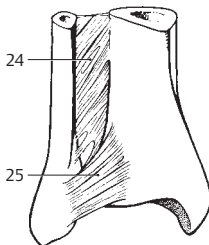
C Right knee joint, posterior view



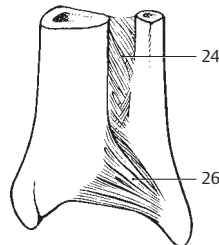
D Right knee joint, opened, superior view



E Right knee joint, opened, posterior view

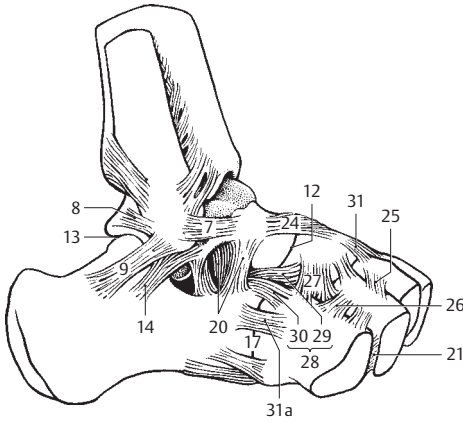


F Distal area of right leg, anterior view

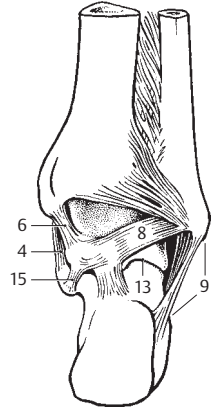


G Distal area of right leg, posterior view

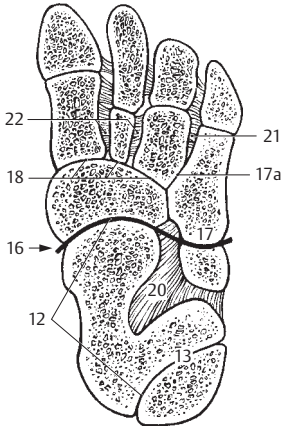
- 1 **Ankle (talocrural) joint.** *Articulatio talocruralis.* Upper ankle joint between the talus, tibia and fibula. D
- 2 **Medial or deltoid ligament.** *Lig. mediale (deltoideum) articulationis talocruralis.* Ligament on the medial side of the ankle which consists of the four segments described below. D
- 3 **Tibionavicular part.** *Pars tibionavicularis.* Group of fibers connecting the medial malleolus to the dorsal and medial surfaces of the navicular bone. D
- 4 **Tibiocalcaneal part.** *Pars tibiocalcanea.* Group of fibers connecting the medial malleolus to the sustentaculum tali. B D
- 5 **Anterior tibiotalar part.** *Pars tibiotalaris anterior.* Segment of the deltoid ligament that connects the medial malleolus to the medial surface of the talus as far as the neck of the talus. D
- 6 **Posterior tibiotalar part.** *Pars tibiotalaris posterior.* Fibers extending posteriorly from the medial malleolus almost as far as the posterior process of the talus. B D
- 7 **Anterior talofibular ligament.** *Lig. talofibulare anterius.* Ligament extending from the lateral malleolus to the lateral surface of the neck of the talus. A
- 8 **Posterior talofibular ligament.** *Lig. talofibulare posterius.* It originates in the lateral malleolar fossa and inserts at the lateral tubercle of the posterior process of the talus. A B
- 9 **Calcaneofibular ligament.** *Lig. calcaneofibulare.* It passes obliquely and posteriorly from the apex of the lateral malleolus to the calcaneus. A B
- 10 **Intertarsal joints.** *Articulationes intertarsae.* Joints between the tarsal bones.
- 11 **JOINTS OF THE FOOT.** *Articulationes pedis.*
- 12 **Talocalcaneonavicular joint.** *Articulatio talocalcaneonavicularis.* The anterior portion of the lower ankle joint in which the talus articulates with the calcaneus and navicular bones. A C
- 13 **Subtalar joint.** *Articulatio subtalaris (talocalcanea).* Joint between the talus and calcaneus that represents the posterior part of the lower ankle joint. A B C D
- 14 **Lateral talocalcaneal ligament.** *Lig. talocalcaneum laterale.* Ligament that passes from the trochlea of the talus to the lateral surface of the calcaneus. It is partially covered by the calcaneofibular ligament. A
- 15 **Medial talocalcaneal ligament.** *Lig. talocalcaneum mediale.* Ligament on the medial side of the foot that extends from the medial tubercle of the posterior process of the talus to the sustentaculum tali. B D
- 15 a **Posterior talocalcaneal ligament.** [*Lig. talocalcaneum posterius.*] Fibrous band extending from the posterior process of the talus to the calcaneus, thereby bridging the sulcus of the tendon of the flexor hallucis longus muscle.
- 16 **Transverse tarsal (midtarsal) joint** [*Chopart's joint*] *Articulatio tarsi transversa.* Joint situated in front of the talus and calcaneus but proximal to the cuboid and navicular bones. C
- 17 **Calcaneocuboid joint.** *Articulatio calcaneocuboidea.* Joint between the calcaneus and cuboid bones. A C
- 17 a **Cuneocuboid joint.** *Articulatio cuneocuboidea.* Articulation between the cuboid bone and lateral cuneiform bone. C
- 18 **Cuneonavicular joint.** *Articulatio cuneonavicularis.* Joint between the navicular bone and cuneiform bones. C D
- 18 a **Intercuneiform joints.** *Articulationes intercuneiformes.* Joint between the cuneiform bones.
- 19 **Interosseous ligaments of the tarsus.** *Ligg. tarsi interossea.* The following three interosseous ligaments are present between the tarsal bones:
- 20 **Interosseous talocalcaneal ligament.** *Lig. talocalcaneum interosseum.* Strong mass of ligaments in the sinus tarsi. A C
- 21 **Interosseous cuneocuboid ligament.** *Lig. cuneocuboideum interosseum.* Taut connection between the lateral cuneiform bone and the cuboid bone. A C
- 22 **Interosseous intercuneiform ligaments.** *Ligg. intercuneiformia interossea.* Taut ligaments between the three cuneiform bones. C
- 23 **Dorsal ligaments of the tarsus.** *Ligg. tarsi dorsalia.* The following eight dorsal ligaments are present between the tarsal bones.
- 24 **Talonavicular ligament.** *Lig. talonaviculare.* Dorsal ligament between the head of the talus and the navicular bone. A D
- 25 **Dorsal intercuneiform ligaments.** *Ligg. intercuneiformia dorsalia.* Dorsal ligaments between the cuneiform bones. A
- 26 **Dorsal cuneocuboid ligaments.** *Lig. cuneocuboideum dorsale.* Dorsal ligaments between the lateral cuneiform bone and the cuboid bone. A
- 27 **Dorsal cuboideonavicular ligament.** *Lig. cuboideonaviculare dorsale.* Ligament between the cuboid and navicular bones. A
- 28 **Bifurcate ligament.** *Lig. bifurcatum.* V-shaped double ligament in front of the sinus tarsi on the dorsum of the foot. It extends forward from the calcaneus and consists of the following two parts. A
- 29 **Calcaneonavicular ligament.** *Lig. calcaneonaviculare.* It extends laterally from the head of the talus to the navicular bone. A
- 30 **Calcaneocuboid ligament.** *Lig. calcaneocuboideum.* It extends from the calcaneus and attaches near the middle of the cuboid bone. A
- 31 **Dorsal cuneonavicular ligaments.** *Ligg. cuneonavicularia dorsalia.* Broad group of ligaments on the dorsum of the foot connecting the navicular bone with the three cuneiform bones. A
- 31 a **Dorsal calcaneocuboid ligament.** *Lig. calcaneocuboideum dorsale.* Moderate reinforcement of the joint capsule lateral to the bifurcate ligament. A



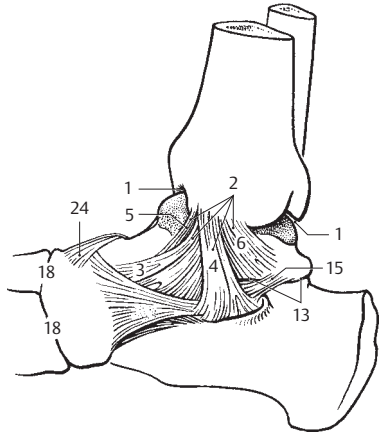
A Ligaments of right foot, lateral view



B Ligaments of right ankle (talocrural) joint, posterior view

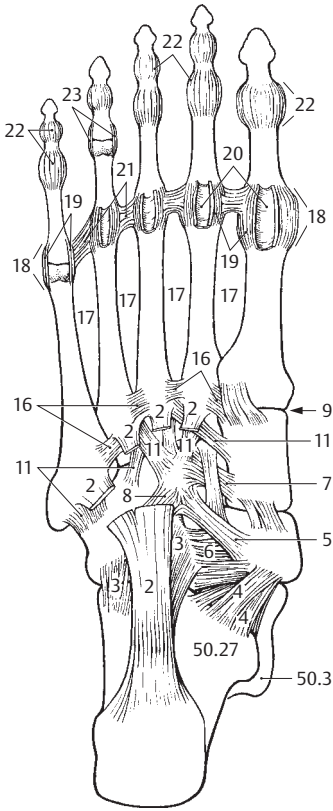


C Tarsometatarsal bones of right foot, horizontal section

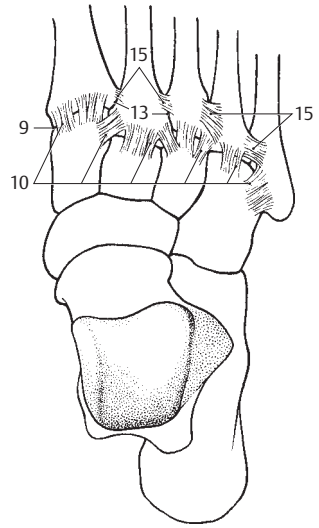


D Ligaments of right foot, medial view

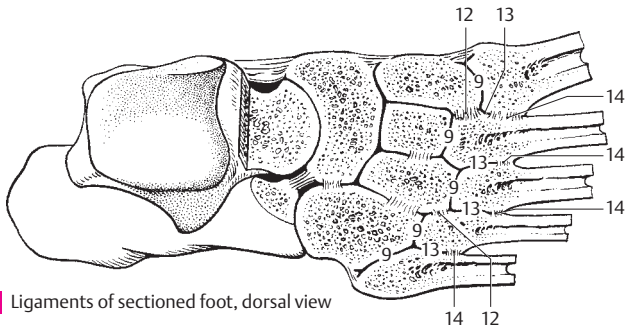
- 1 **Plantar ligaments of tarsus.** Ligg. tarsi plantaria. Ligaments on the palmar aspect of the foot. They are particularly important for the bracing of both plantar arches of the foot.
- 2 **Long plantar ligament.** Lig. plantare longum. Stout ligament which passes from the calcaneus closely in front of its tuber to the cuboid bone and to the bases of metatarsals II–V. It supports the longitudinal arch. A
- 3 **Plantar calcaneocuboid ligament or short plantar ligament.** Lig. calcaneocuboideum plantare. Shorter portion of the long plantar ligament. A
- 4 **Plantar calcaneonavicular (spring) ligament.** Lig. calcaneonaviculare plantare. It lies medial to the above-mentioned ligament and supports, according to more traditional view, the articular cavity for the head of the talus. Since the talar side of the ligament is quite loose and contains no fibrocartilage, this concept is questionable. A
- 5 **Plantar cuneonavicular ligaments.** Ligg. cuneonavicularia plantaria. Groups of ligaments that connect the navicular bone with the cuneiform bones lodged in front of it. A
- 6 **Plantar cuboideonavicular ligament.** Lig. cuboideonaviculare plantare. A plantar ligament coursing somewhat obliquely to the axis of the foot connecting the cuboid and navicular bones. It supports the transverse plantar arch of the foot. A
- 7 **Plantar intercuneiform ligaments.** Ligg. intercuniformalia plantare. Fibrous bands lying on the plantar aspect of the foot between the cuneiform bones. They support the transverse plantar arch of the foot. A
- 8 **Plantar cuneocuboid ligament.** Lig. cuneocuboideum plantare. Fibrous brace on the plantar aspect of the foot between the lateral cuneiform and cuboid bones. A
- 9 **Tarsometatarsal joints.** Articulationes tarsometatarsales. Joints between the tarsal and metatarsal bones of the foot. A B C
- 10 **Dorsal tarsometatarsal ligaments.** Ligg. tarsometatarsalia dorsalia. Ligaments located on the dorsum of the foot between the tarsal and metatarsal bones. B
- 11 **Plantar tarsometatarsal ligaments.** Ligg. tarsometatarsalia plantaria. Ligaments located on the plantar aspect of the foot between the tarsal and metatarsal bones. A
- 12 **Interosseous cuneometatarsal ligaments.** Ligg. cuneometatarsalia interossea. Ligaments occupying the joint spaces between the cuneiform and metatarsal bones. C
- 13 **Intermetatarsal joints.** Articulationes intermetatarsales. Joints between the bases of the metatarsal bones. B C
- 14 **Interosseous metatarsal ligaments.** Ligg. metatarsalia interossea. Ligaments between the bases of the metatarsal bones. They form the distal limits of the articular spaces between the metatarsal bones. C
- 15 **Dorsal metatarsal ligaments.** Ligg. metatarsalia dorsalia. Ligaments between the bases of the metatarsal bones on the dorsum of the foot. B
- 16 **Plantar metatarsal ligaments.** Ligg. metatarsalia plantaria. Ligaments found between the bases of the metatarsal bones on the plantar aspect of the foot. A
- 17 **Metatarsal interosseous spaces.** Spatia interossea metatarsi. Spaces between the shafts of the metatarsal bones. They are occupied by the corresponding muscles. A
- 18 **Metatarsophalangeal joints.** Articulationes metatarsophalangeales. A
- 19 **Collateral ligaments.** Ligg. collateralia. A
- 20 **Plantar ligaments.** Ligg. plantaria. Connective tissue reinforcement of the capsule of the metatarsophalangeal joint. It is more firmly fused with the proximal phalanx than with the head of the metatarsals and forms a stroma for the flexor tendons. A
- 21 **Deep transverse metatarsal ligament.** Lig. metatarsale transversum profundum. Transversely oriented ligament connecting the heads of the metatarsal bones. A
- 22 **Interphalangeal joints of the foot.** Articulationes interphalangeales pedis. The middle and terminal joints between the phalanges of the foot. A
- 23 **Collateral ligaments.** Ligg. collateralia. A
- 24 **Plantar ligaments.** Ligg. plantaria. Fibrous bands that reinforce the plantar aspect of the interphalangeal articular capsules.



A Ligaments of right foot, plantar view



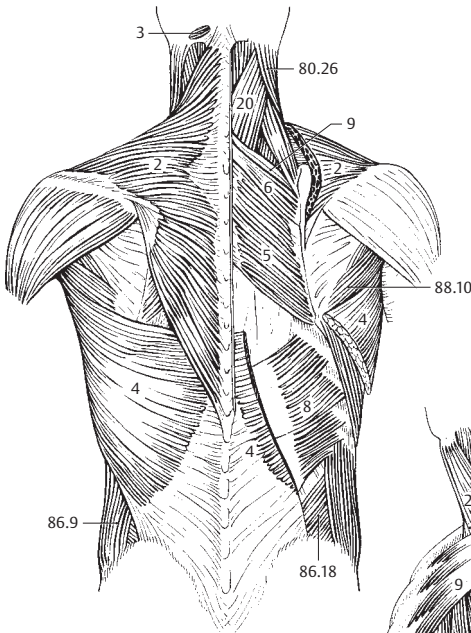
B Ligaments of foot, dorsal view



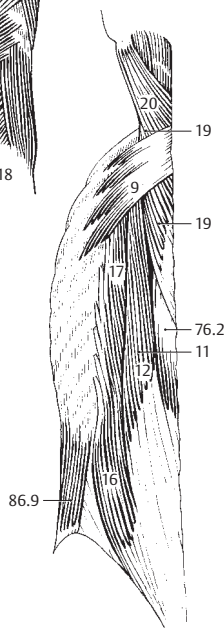
C Ligaments of sectioned foot, dorsal view

MUSCULAR SYSTEM

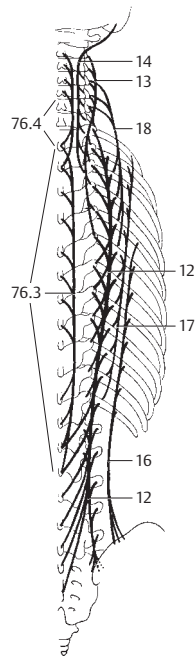
- 1 **DORSAL MUSCLES.** Musculi dorsi. The muscles of the back. True back muscles are innervated by the dorsal rami of spinal nerves, whereas the muscles of the shoulder girdle are not. A B C
- 2 **M. trapezius.** o: Spinous processes of vertebrae T1–T12 and C1, the nuchal ligament, occipital protuberance, and superior nuchal line. i: Spine of scapula, acromion, and clavicle. A: Rotates, raises, lowers, and adducts the scapula; rotates the head. I: Accessory nerve, cervical plexus. A
- 3 **M. transversus nuchae.** (Rare, 25%). Platysmal muscle situated between the insertions of the trapezius and sternocleidomastoid. It passes transversely, either superficial or deep, to the trapezius. A
- 4 **M. latissimus dorsi.** o: Thoracolumbar fascia, spinous processes of vertebrae T7–L5, sacrum, iliac crest, and four lower ribs. i: Crest of lesser tubercle of humerus. A: Adduction and medial rotation of the arm. I: Thoracodorsal nerve. A
- 5 **M. rhomboideus major.** o: Spinous processes of vertebrae T1–4. i: Medial margin of scapula. A: Medial and upward movement of scapula. I: Dorsal scapular nerve. A
- 6 **M. rhomboideus minor.** o: Spinous processes of cervical vertebrae 6–7. i: Medial margin of scapula above the spine. A: Medial and upward movement of scapula. I: Dorsal scapular nerve. A
- 7 **M. levator scapulae.** o: Posterior tubercle of transverse processes of cervical vertebrae 1–4. i: Superior angle of scapula. A: Elevates superior angle of scapula and rotates neck. I: Dorsal scapular nerve and cervical plexus. A
- 8 **M. serratus posterior inferior.** o: Spinous processes of vertebrae T11–L2. i: Four lower ribs. A: Retroversion of four lower ribs. I: Intercostal nerves. A
- 9 **M. serratus posterior superior.** o: Spinous processes of vertebrae C6–T2. i: Second to fifth ribs. A: Raises ribs in inspiration. I: Intercostal nerves. A B
- 10 **M. ERECTOR SPINAE.** Collective term for the muscles of the lateral and medial tracts of the back. I: Posterior rami of spinal nerves. o: Iliac crest, spinous processes of L1–S4, mamillary processes of L1–2, transverse processes of T7–12. i: Costal and accessory processes of lumbar vertebrae, angle of 11 lower ribs, all thoracic transverse processes. A: Lateral and backward flexion of vertebral column. B C
- 10a **[[Lateral tract]].** [Tractus laterale].
- 11 **M. longissimus.** It consists of the following three parts. B
- 12 **M. longissimus thoracis.** o: Iliac crest, spinous processes of L1–S4, mamillary processes of L1–2, transverse processes of T7–12. i: Costal and accessory processes of lumbar vertebrae, angle of lower 11 ribs all thoracic transverse processes. A: Lateral and backward flexion of vertebral column. B C
- 13 **M. longissimus cervicis.** o: Transverse processes T1–6. i: Transverse processes of vertebrae C2–7. It lies between the iliocostalis cervicis and longissimus capitis muscles. C
- 14 **M. longissimus capitis.** o: Transverse processes of vertebrae C3–T3. i: Mastoid process. It lies between the longissimus cervicis and semispinalis capitis muscles. A: Lateral and backward flexion of the head. It rotates the face toward the ipsilateral side. C
- 15 **M. iliocostalis.** Iliocostal muscle, which consists of the following three segments.
- 16 **M. iliocostalis lumborum.** o: Iliac crest. i: Angle of ribs 5–12. A: Extension and lateral flexion of lower vertebral column. B C
- 17 **M. iliocostalis thoracis.** o: Medial sides of 6 lower rib angles. i: Six uppermost rib angles. A: Flattening of thoracic kyphosis, lateral flexion. B C
- 18 **M. iliocostalis cervicis.** o: Upper and middle ribs. i: Transverse processes of middle cervical vertebrae. C
- 19 **M. splenius cervicis.** o: Spinous processes of T3–5. i: Posterior tubercle of transverse processes of C1–2. A: Backward flexion and rotation of head. B
- 20 **M. splenius capitis.** o: Spinous processes of C4–T3. i: External half of superior nuchal line and mastoid process. A: Backward flexion and rotation of head. A B
- 21 **MM. INTERTRANSVERSARI.** Muscular connection of adjacent transverse processes. A: Lateral flexion. See p. 77 C D E
- 22 **Mm. intertransversarii laterales lumborum.** Muscles between adjacent costal processes. I: Ventral rami of spinal nerves. See p. 77 C
- 23 **Mm. intertransversarii mediales lumborum.** Muscles between the mamillary processes. See p. 77 C
- 24 **Mm. intertransversarii thoracis.** Usually absent. See p. 77 C
- 25 **Mm. intertransversarii posteriores cervicis.** Muscles between posterior tubercles of transverse processes of cervical vertebrae. See p. 77
- 26 **Pars medialis.** Medial part of 25.
- 27 **Pars lateralis.** Lateral part of 25. I: Ventral ramus of spinal nerves.
- 28 **Mm. intertransversarii anteriores cervicis.** Muscles connecting the anterior tubercles of the cervical transverse processes. I: Ventral ramus of spinal nerves. See p. 77 E



A Superficial dorsal muscles

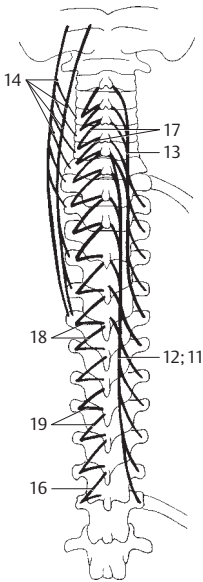


B Deep dorsal muscles

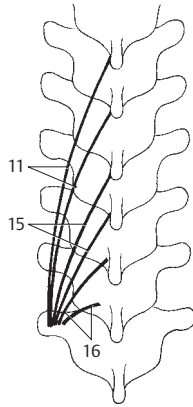


C Autochthonous dorsal muscles, schematic view

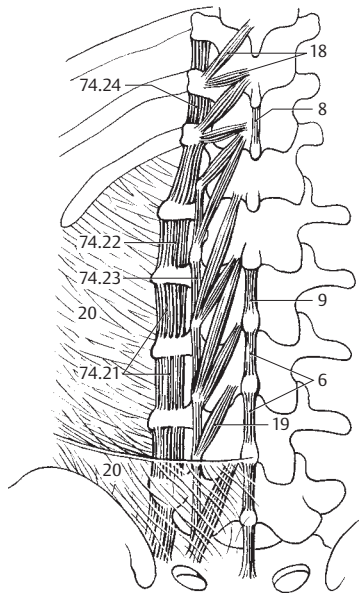
- 1 **[[Medial tract]].** [Tractus medialis].
- 2 **M. spinalis.** Muscular system attached to the spinous processes and consisting of the following three segments: See p. 75 B
- 3 **M. spinalis thoracis.** o: Transverse processes of T11–L2. i: Spinous processes of T2–11. A: Back flexion. See p. 75 C
- 4 **M. spinalis cervicis.** o: Transverse processes of C6–T2. i: Spinous processes of C2–4. A: Back flexion. See p. 75 C
- 5 **M. spinalis capitis.** Inconstant part of semispinalis capitis with additional origins from the upper thoracic and lower cervical spinous processes.
- 6 **Mm. interspinales.** Unlike the spinal muscles, these muscles extend only between the spinous processes of continuous vertebrae. A: Dorsiflexion. C D
- 7 **Mm. interspinales cervicis.** These are paired because of the bifid cervical spinous processes. D
- 8 **Mm. interspinales thoracis.** Usually absent. C
- 9 **Mm. interspinales lumborum.** Especially strong muscle bands. C
- 10 **Mm. transversospinales.** Collective term for the following nine muscles. A B C
- 11 **M. semispinalis.** The longest superficial portion of the transversospinales. It spans four or more vertebrae and comprises the following three segments: A B
- 12 **M. semispinalis thoracis.** o: Transverse processes of T7–L2. i: Spinous processes of C6–T6. A: Primarily dorsiflexion. A
- 13 **M. semispinalis cervicis.** o: Transverse processes of T1–6. i: Spinous processes of C2–5. A: Mainly dorsiflexion. A
- 14 **M. semispinalis capitis.** o: Transverse processes of C4–T6. i: Occipital bone between superior and inferior nuchal lines. A: Dorsiflexion of head and rotation, depending on starting position. A
- 15 **Mm. multifidi.** Portion of the transversospinal system spanning 2–4 vertebrae. A: Dorsolateral flexion and slight rotation. B
- 16 **Mm. rotatores.** Deepest layer of the transversospinal system with short fibers taking an especially transverse course, thereby providing stronger rotation. They attach to an adjacent or superior vertebra. A B C
- 17 **Mm. rotatores cervicis.** o: Inferior articular process. i: Arch or root of spinous process of cervical vertebrae. A
- 18 **Mm. rotatores thoracis.** o: Transverse process of thoracic vertebrae. i: Spinous process. A C
- 19 **Mm. rotatores lumborum.** o: Mamillary process. i: Roots of spinous process of lumbar vertebrae. A C
- 20 **Thoracolumbar fascia.** Fascia thoracolumbalis. Encasing fascia of the erector spinae muscle. It is attached to the spinous processes with a superficial layer, to the costal processes with a deep layer, both layers being united laterally. Associated muscles: transversus abdominis, serrati posteriores, latissimus dorsi and, in some cases, the internal oblique muscle of the abdomen. F
- 21 **Nuchal fascia.** Fascia nuchae (nuchalis). Dorsal continuation of the superficial layer of the cervical fascia. (Investing fascia of the true neck musculature.)
- 22 **HEAD MUSCLES.** Musculi capitis.
- 23 **Mm. SUBOCCIPITALES.** The following seven muscles:
- 24 **M. rectus capitis anterior.** o: Lateral mass of the atlas. i: Basilar part of occipital bone. A: Forward flexion of head. I: Anterior rami of spinal nerves. E
- 25 **M. rectus capitis posterior major.** o: Spinous process of axis. i: Middle of inferior nuchal line. A: Outward rotation and dorsiflexion of head. I: Suboccipital nerve. D. See also p. 79 A
- 26 **M. rectus capitis posterior minor.** o: Posterior tubercle of atlas. i: Inner third of inferior nuchal line. A: Mainly dorsiflexion of head. I: Suboccipital nerve. D. See also p. 79 A



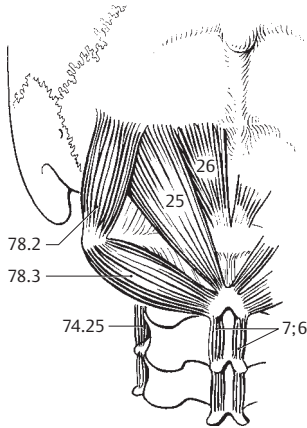
A Systems of mm. transversospinales



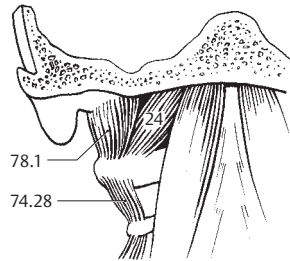
B Transversospinal system



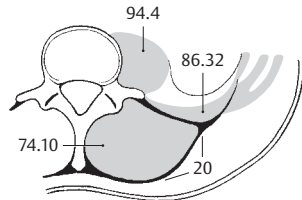
C Short muscles of the vertebral column



D Short neck muscles

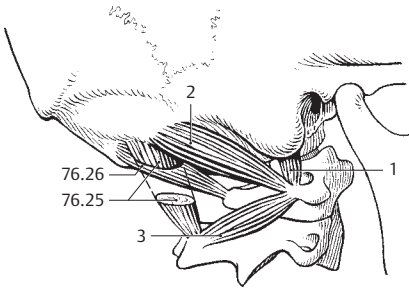


E Deep neck muscles, anterior view

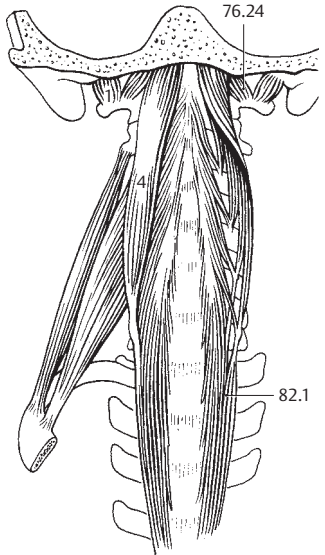


F Thoracolumbar fascia

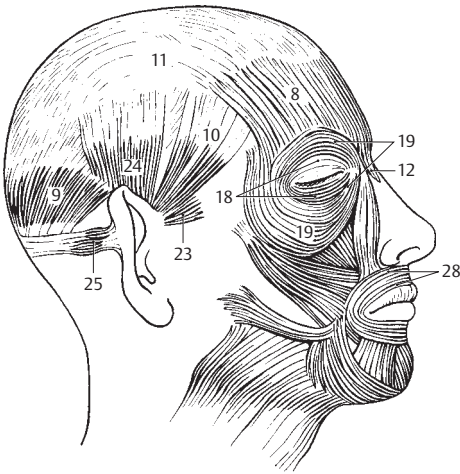
- 1 **M. rectus capitis lateralis.** o: Transverse process of atlas. i: Jugular process of occipital bone. A: Lateral flexion of head. I: Anterior rami of spinal nerves C1–2. A B, see also p. 77 E
- 2 **M. obliquus capitis superior.** o: Transverse process of atlas. i: Field above attachment of rectus capitis posterior major. A: Backward and lateral flexion of head. I: Posterior rami of spinal nerves C1–2. A, see also p. 77 D
- 3 **M. obliquus inferior.** o: Spinous process of axis. i: Transverse process of atlas. A: Lateral rotation of atlas and face toward the same side. I: Posterior rami of spinal nerves C1–2. A, see also p. 77 D
- 4 **M. longus capitis.** o: Anterior tubercle of transverse processes of C3–6. i: Basal part of occipital bone. A: Forward and lateral flexion of head and cervical vertebral column. I: Anterior rami of spinal nerves C1–2. B
- 5 **FACIAL AND MASTICATORY MUSCLES.** Musculi faciales et masticatorii.
- 6 **M. epicranii.** Collective term for the muscles attaching to the galea aponeurotica. I: Facial nerve. C
- 7 **M. occipitofrontalis.** Muscle extending anteriorly and posteriorly into the galea aponeurotica. C
- 8 **Frontal belly.** Venter frontalis. The portion of the occipitofrontalis which passes from the galea aponeurotica to the eyebrows. A: Moves scalp forward and raises the eyebrows. C
- 9 **Occipital belly.** Venter occipitalis. The portion of the occipitofrontalis which passes from the supreme nuchal line to the galea aponeurotica. A: Moves galea aponeurotica backward. C
- 10 **M. temporoparietalis.** o. Region of superior auricular muscle. i: Galea aponeurotica. C
- 11 **Galea aponeurotica (aponeurosis epicranialis).** Displaceable, helmet-like, superficial tendon for the two parts of the epicranii. It lies against the periosteum and is attached to the supreme nuchal line and to the external occipital protuberance. C
- 12 **M. procerus.** o: Dorsum of nose. i: Skin above the nose. A: Depression of frontal skin. I: Facial nerve. C
- 13 **M. nasalis.** Common term for the following two nasal muscles: I: Facial nerve. D
- 14 **Transverse part of nasalis.** Pars transversa [[compressor naris]]. o: Field over root of canine tooth. i: Superficial tendon on dorsum of nose. D
- 15 **Alar part of nasalis.** Pars alaris [[dilator naris]]. o: Above the lateral incisor tooth. i: Margins of the nasal openings and the adjacent region. D
- 16 **M. depressor septi.** o: Above the medial incisor tooth. i: Cartilaginous nasal septum. A: Depresses tip of nose. I: Facial nerve. D
- 17 **M. orbicularis oculi.** Circular sphincter muscle of the eye. Comprises three segments. It closes the eyelids and assists the flow of tears into the lacrimal sac and into the nose. i: Facial nerve. C D
- 18 **Palpebral part.** Pars palpebralis. Fibers situated in the eyelids passing from the medial palpebral ligament and the adjacent bones to the lateral palpebral ligament. C
- 19 **Orbital part.** Pars orbitalis. Arises from the medial palpebral ligament and adjacent bones, thus encircling the eye. C
- 20 **Lacrimal part.** Pars lacrimalis. o: Posterior lacrimal crest. It curves around the lacrimal canaliculus, extends partially behind the lacrimal sac and radiates into the palpebral part of the orbicularis oculi muscle below the medial palpebral ligament. D
- 21 **M. corrugator supercilii.** o: Nasal part of frontal bone. i: Skin over the middle of the eyebrow. Located below the orbicularis oculi muscle. I: Facial nerve. D
- 22 **M. depressor supercilii.** Muscle medial to the corrugator supercilii that radiates from the orbicular oculi into the skin of the medial part of the eyebrow. I: Facial nerve. D
- 23 **M. auricularis anterior.** Muscle in front of the ear. o: Temporal fascia. i: Spine of helix. I: Facial nerve. C
- 24 **M. auricularis superior.** o: Galea aponeurotica. i: Root of pinna. I: Facial nerve. C
- 25 **M. auricularis posterior.** o: Mastoid process. i: Root of pinna. I: Facial nerve. C
- 26 **M. orbicularis oris.** Encircles the mouth opening and consists of two parts (see nos. 27, 28). It assists in closing the lips and helps to empty the vestibule of the mouth. I: Facial nerve. C D E
- 27 **Marginal part.** Pars marginalis. The peripheral margin radiating into the neighboring muscles. D
- 28 **Labial part.** Pars labialis. The main part of the orbicularis oris including the portion which takes a hook-like bend externally below the red portion of the lips. C D E



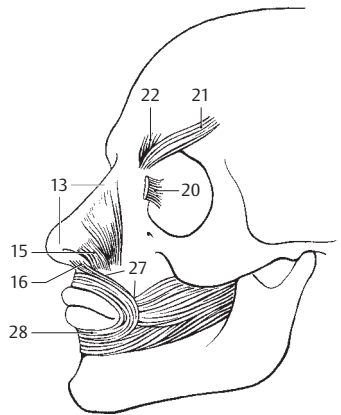
A Deep suboccipital muscles, lateral view



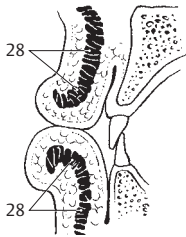
B Neck, anterior view



C Superficial muscles of head

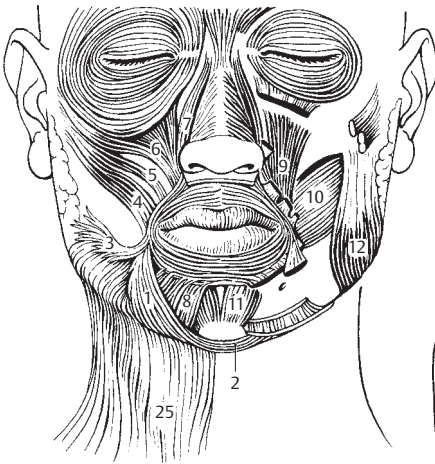


D Deep mimetic muscles

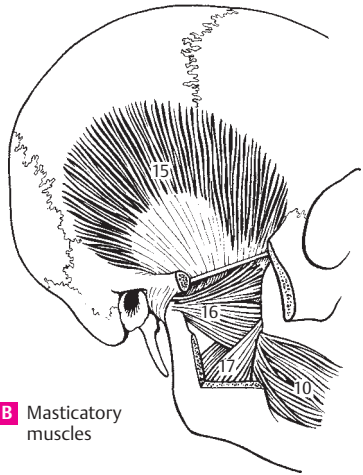


E Sagittal section through the lips

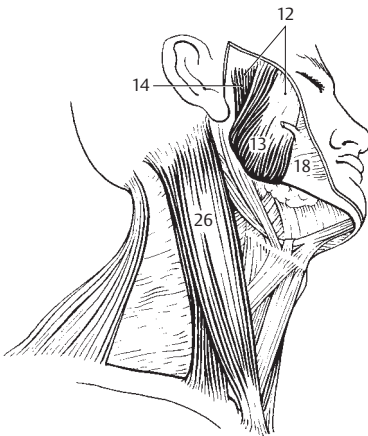
- 3
- 1 **M. depressor anguli oris.** [[Triangularis]]. o: Anterior and lateral part of mandible. i: Angle of mouth. l: Facial nerve. A
 - 2 **M. transversus menti.** Transverse muscular connection between the right and left depressor anguli oris muscles below the chin. l: Facial nerve. A
 - 3 **M. risorius.** o: Parotid fascia and buccal skin. i: Angle of mouth. l: Facial nerve. A
 - 4 **M. zygomaticus major.** o: Lateral side of zygomatic bone. i: Angle of mouth. l: Facial nerve. A
 - 5 **M. zygomaticus minor.** o: Anterior side of zygomatic bone. i: Upper lip. l: Facial nerve. A
 - 6 **M. levator labii superioris** [[quadratus labii sup., M. levator nasi et labii maxillaris lat.]]. o: Above the infra-orbital foramen. Radiates into orbicularis oris. l: Facial nerve. A
 - 7 **M. levator labii superioris alaeque nasi** [[quadratus labii sup., M. lev. nasi et labii maxillaris med]]. o: Medial to orbit. i: Nasal ala and upper lip. l: Facial nerve. A
 - 8 **M. depressor labii inferioris** [[quadr. labii inf.]]. Located below the depressor anguli oris. o: Platysma and mandible. i: Lower lip. l: Facial nerve. A
 - 9 **M. levator anguli oris** [[Caninus]]. o: Canine fossa. i: Angle of mouth. l: Facial nerve. A
 - 9a **Modiolus.** Palpable muscular mass lateral to the angle of the mouth. Point of convergence of adjacent muscles radiating into the orbicularis oris.
 - 10 **M. buccinator.** Cheek muscle. o: Pterygomandibular raphe and adjoining parts of upper and lower jaw. i: Angle of mouth and orbicularis oris. l: Facial nerve. A B
 - 11 **M. mentalis.** Arises over the roots of the lower incisors. i: Skin of chin (chin dimple). l: Facial nerve. A
 - 12 **M. masseter.** Most prominent masticatory muscle. Closes jaw and, together with the temporal and medial pterygoid muscles, determines the degree of masticatory power. It is comprised of a superficial and deep part. l: Mandibular nerve. A C
 - 13 **Superficial part.** Pars superficialis. o: Anterior two-thirds of zygomatic arch. i: Angle of mandible. It courses obliquely backward and downward. It also draws the mandible somewhat forward. C
 - 14 **Deep part.** Pars profunda. Size varies. Arises from the zygomatic arch proximal to the mandibular joint and discocapsular system. i: Mandible. Action: Together with fibers of the temporal muscles, it ensures lateral stabilization of the discocapsular system during laterotrusion movement. C
 - 15 **M. temporalis.** o: Temporal fossa. i: Coronoid process that extends downward to the occlusal plane and to the region of the pterygomandibular raphe. Action: Elevation and retraction of the mandible, fixation of the pharynx when swallowing; cf. pp. 12, 14. l: Mandibular nerve. B
 - 16 **Lateral pterygoid muscle.** M. pterygoideus lateralis. o: Lateral surface of lateral pterygoid plate and lower surface of greater wing of sphenoid. Arises by two heads (variant: three heads), one from the discocapsular system, the other from the pterygoid fossa. The inferior head pulls the mandible and discocapsular system forward. The superior head determines the velocity at which the discocapsular system is pulled back into place. l: Mandibular nerve. B
 - 17 **Medial pterygoid muscle.** M. pterygoideus medialis. o: Pterygoid fossa and tuber of maxilla. i: Pterygoid tuberosity and inner aspect of angle of mandible. It courses obliquely downward and backward and is a synergist to the temporalis and masseter muscles. l: Mandibular nerve. B
 - 18 **Buccopharyngeal fascia.** Fascia buccopharyngea. It lies on the buccinator muscle and extends from the angle of the mouth deeply as far as the pharyngeal constrictor muscle. C
 - 19 **Masseteric fascia.** Fascia masseterica. Fascia covering the masseter muscle, part of which attaches below the parotid at the upper end of the zygomatic arch. D
 - 20 **Parotid fascia.** Fascia parotidea. Fascial covering of the parotid, partly identical with the masseteric fascia. D
 - 21 **Temporal fascia.** Fascia temporalis. External connective tissue investment of the temporalis muscle between the superior temporal line and the zygomatic arch. It consists of the following two layers. D
 - 22 **Superficial layer.** Lamina superficialis. Layer of the temporal fascia attached to the outer margin of the zygomatic arch. D
 - 23 **Deep layer.** Lamina profunda. Layer of the temporal fascia attached to the inner margin of the zygomatic arch. D
 - 24 **NECK MUSCLES.** Musculi colli (cervicis). A C
 - 25 **Platysma.** Cutaneous muscle occupying an extensive area of the neck. It extends from the lower part of the face to the upper thorax. l: Facial nerve. A D
 - 26 **Sternocleidomastoid muscle.** M. sternocleidomastoideus. o: Sternum and clavicle. i: Mastoid process and superior nuchal line. It elevates the chin and rotates it to the opposite side. l: Accessory nerve, cervical plexus. C



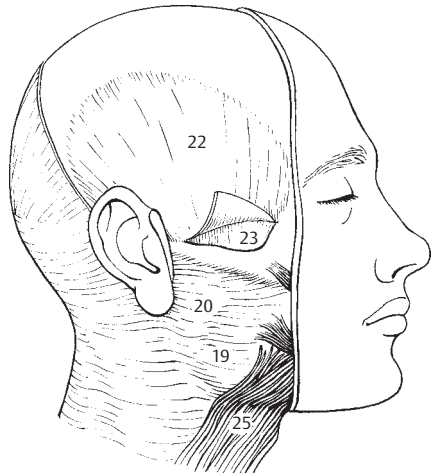
A Facial muscles, anterior view



B Masticatory muscles

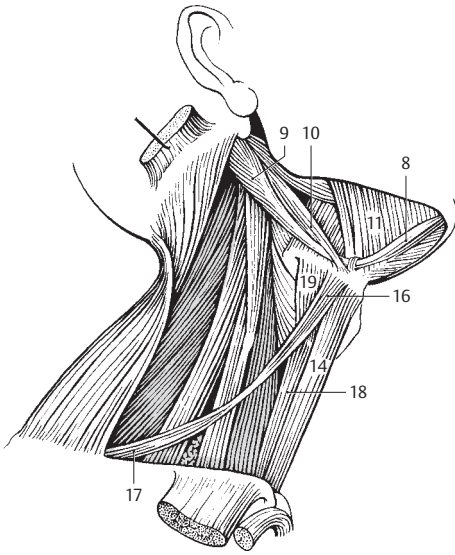


C Muscles of head and neck, right inferior view

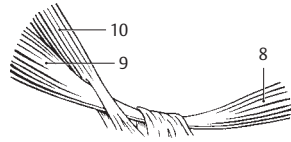


D Fasciae of the head

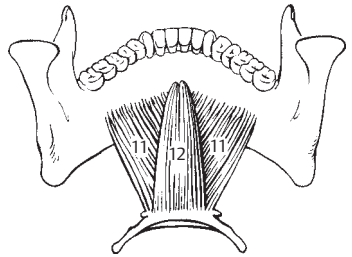
- 1 **M. longus colli.** Arches to connect the 2nd to 5th cervical vertebrae with the lower cervical and upper thoracic vertebrae. Its fibers also extend from the vertebral bodies to the transverse processes with the C6 transverse process as the central point. A: Lateral and forward flexion of the neck. I: Ventral ramus of spinal nerve. D
- 2 **M. scalenus anterior.** o: Transverse processes of C3–6. i: Scalene tubercle on 1st rib. A: Elevation of 1st rib, lateral flexion and rotation of neck. It separates the anterior and posterior or scalenus gaps. I: see p. 1. D
- 3 **M. scalenus medius.** o: Transverse processes of C4–7. i: 1st rib behind groove for subclavian artery. A: Elevation of 1st rib and lateral flexion of neck. I: see p. 1. D
- 4 **M. scalenus posterior.** o: Transverse processes of C4–6. i: Upper margin of 2nd rib. A: Elevates the rib, laterally flexes the neck. I: see p. 1. D
- 5 **[M. scalenus minimus].** Extra muscle occasionally present between scalenus anterior and medius. o: Transverse processes of C6 or 7. i: 1st rib and pleural cupola.
- 6 **SUPRAHYOID MUSCLES.** Mm. suprahyoidei. The following muscles above the hyoid bone. A
- 7 **M. digastricus.** o: Notch medial to the mastoid process. i: Inner side of mandible. It has an intermediate tendon which acts on the lesser horn of the hyoid bone by means of a connective tissue sling. A: Elevation of hyoid. A
- 8 **Anterior belly.** Venter anterior. It extends from the mandible to the intermediate tendon. A: Pulls mandible forward and depresses it. I: Mylohyoid nerve. A E
- 9 **Posterior belly.** Venter posterior. It passes from the mastoid process to the intermediate tendon. A: It draws back the hyoid bone. I: Facial nerve. A E
- 10 **M. stylohyoideus.** o: Styloid process. i: Lesser horn of hyoid bone. It accompanies the posterior belly of the digastric muscle and can pass through it via a fissure. A: It pulls the hyoid backward and upward. I: Facial nerve. A E
- 11 **M. mylohyoideus.** Muscle of the floor of the mouth. o: Mylohyoid line of mandible. i: Body of hyoid bone. A: Draws the hyoid forward and upward and forms the diaphragma oris. I: Mylohyoid nerve. A B
- 12 **M. geniohyoideus.** o: Mental spine. i: Body of hyoid bone. A: Draws the hyoid forward and upward. I: C1 via the hypoglossal nerve. B
- 13 **Infrahyoid muscles.** Mm. infrahyoidei. The muscles below the hyoid bone (infrahyoid m.). I: Ansa cervicalis. A
- 14 **M. sternohyoideus.** o: Posterior surface of manubrium sterni. i: Body of hyoid bone. A: Draws the hyoid downward. I: see p. 13. A
- 15 **M. omohyoideus.** o: Upper margin of scapula medial to scapular notch. i: Body of hyoid bone. An intermediate tendon situated above the jugular vein divides it into two bellies. A: Draws the hyoid downward and tenses the cervical fascia. I: see p. 13. A C
- 16 **Superior belly.** Venter superior. Upper segment of omohyoid between the hyoid and intermediate tendon. A
- 17 **Inferior belly.** Venter inferior. Lower half of omohyoid from the intermediate tendon to the scapular notch. A
- 18 **M. sternothyroideus.** o: Posterior surface of manubrium and 1st rib. i: Oblique line of thyroid cartilage. A: Draws larynx downward. I: see p. 13. A
- 19 **M. thyrohyoideus.** o: Oblique line of thyroid cartilage. i: Greater horn of hyoid bone. A: Brings hyoid and thyroid cartilage closer together. I: C1 via hypoglossal nerve. A
- 20 **[M. levator glandulae thyroideae].** Part of the thyrohyoid muscle that extends to the thyroid gland.
- 21 **CERVICAL FASCIA.** Fascia cervicalis. Collective term for the connective tissue layers of the neck.
- 22 **Superficial (investing) layer.** Lamina superficialis. Superficial layer of cervical fascia that surrounds the sternocleidomastoid and trapezius muscles. It is attached to the anterior margin of the manubrium, the clavicle and the mandible. C
- 23 **Pretracheal layer.** Lamina pretrachealis. Layer that spreads between the two omohyoid muscles and is attached to the posterior margin of the manubrium and clavicle. It surrounds the infrahyoid muscles. C
- 24 **Prevertebral layer.** Lamina prevertebralis. Layer that lies between the vertebral column and pharyngeal constrictors as well as the esophagus, covers the scaleni muscles and contains the sympathetic trunk and phrenic nerve. C
- 25 **Carotid sheath.** Vagina carotica. Connective tissue investing the neurovascular bundle (carotid artery, jugular vein and vagus nerve) and continuous with the pretracheal layer. C



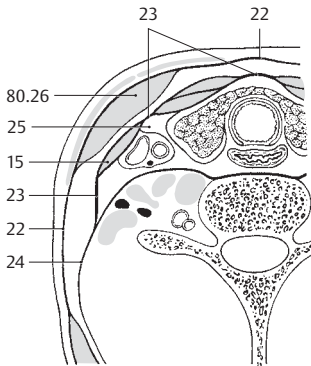
A Muscles of hyoid bone



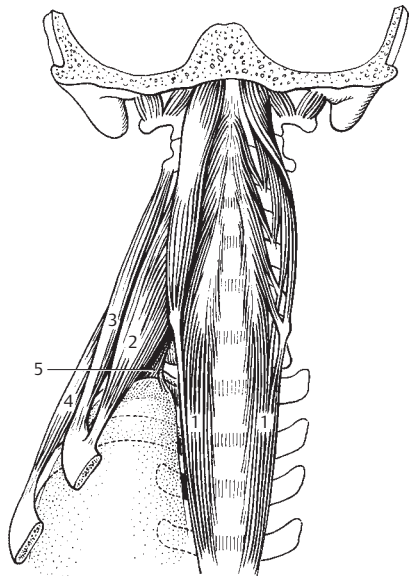
E Segment of A



B Muscles of floor of mouth from above and behind

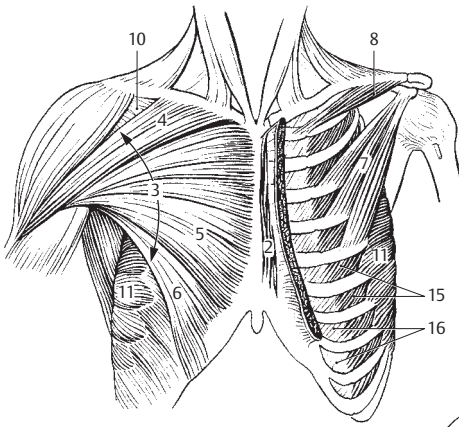


C Fasciae of the neck

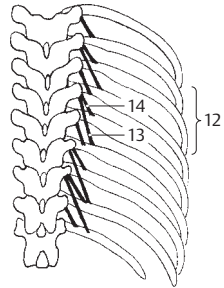


D Deep neck muscles, anterior view

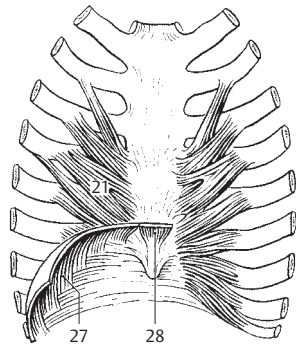
- 1 **MUSCLES OF THORAX.** Musculi thoracis. A–F
- 2 [**M. sternalis**]. Muscle that occasionally (4%) crosses the pectoralis major muscle parallel and proximal to the sternum. A
- 3 **M. pectoralis major.** Consists of the three parts listed below (nos. 4–6). o: Clavicle, sternum, first 4–6 costal cartilages and rectus sheath. i: Crest of greater tubercle and humerus. A: Adduction and medial rotation of arm. I: Medial and lateral pectoral nerves. A
- 4 **Clavicular part.** Pars clavicularis. The portion originating from the clavicle. A
- 5 **Sternocostal part.** Pars stenocostalis. The portion arising from the sternum and ribs. A
- 6 **Abdominal part.** Pars abdominalis. The portion arising from the rectus sheath. A
- 7 **M. pectoralis minor.** It lies beneath the pectoralis major. o: Ribs 3–5. i: Coracoid process. A: Draws scapula forward and downward and ribs upward. Accessory respiratory muscle. I: see p. 3. A
- 8 **M. subclavius.** o: 1st costal cartilage. i: Lower surface of clavicle. A: Stabilizes sternoclavicular joint against tension. I: Subclavian nerve. A
- 9 **Pectoral fascia.** Fascia pectoralis. It covers the pectoralis major muscle, is attached to the clavicle and sternum and is continuous with the axillary fascia.
- 10 **Clavipectoral fascia.** Fascia clavipectoralis. Fascia attached to the coracoid process and the clavicle. It covers the pectoralis minor and subclavian muscles. A
- 11 **M. serratus anterior.** o: Ribs 1–9. i: Medial margin of scapula. A: Supports, lowers and rotates the scapula and draws it forward. It assists in raising the arm high above the horizontal plane. I: Long thoracic nerve. A
- 12 **Mm. levatores costarum.** Muscles behind and below the long back muscles. o: Thoracic transverse processes. i: Ribs. I: Posterior ramus of spinal nerve. B
- 13 **Mm. levatores costarum longi.** o: Transverse processes. i: Passes over a rib to insert on the next lower rib. A: Elevates the ribs. B
- 14 **Mm. levatores costarum breves.** o: Transverse process. i: Next lower rib. B
- 15 **External intercostal muscles.** Mm. intercostales externi. They extend obliquely forward and downward between the ribs. A: Inspiration, bracing of the ribs. I: Intercostal nerves. A E F
- 16 **External intercostal membrane.** Membrana intercostalis externa. Membrane that replaces the external intercostal muscles anteriorly between the costal cartilages. A
- 17 **Internal intercostal muscles.** Mm. intercostales interni. They pass obliquely backward and downward between the ribs. A: Partially expiratory, bracing of the ribs. I: Intercostal nerves. E F
- 18 **Internal intercostal membrane.** Membrana intercostalis interna. Continuation of the internal intercostal muscles from the rib angle to the vertebrae. E
- 19 **Innermost intercostal muscles.** Mm. intercostales intimi. Internal portion of the internal intercostal muscles separated by the intercostal vessels. F
- 20 **Subcostal muscles.** Mm. subcostales. Internal intercostal muscles that pass over 1–2 ribs. I: see p. 17. E
- 21 **M. transversus thoracis.** Situated on the inner surface of the anterior thoracic wall, it radiates obliquely upward from the sternum to costal cartilages 2–6. I: see p. 17. C
- 22 **Thoracic fascia.** Fascia thoracica. Epimysium of the inner thoracic musculature.
- 23 **Diaphragm.** Diaphragma [thoraco-abdominale]. Dome-shaped, muscular partition between the thoracic and abdominal cavities. I: Phrenic nerve. C D
- 24 **Lumbar part of diaphragm.** Pars lumbalis diaphragmatis. Medial part of the diaphragm arising from the lumbar vertebral bodies, intervertebral discs and fibrous arches. D
- 25 **Right crus of lumbar part.** Crus dextrum. o: L1–3(4). D
- 26 **Left crus of lumbar part.** Crus sinistrum. o: L1–2(3). D
- 27 **Costal part of diaphragm.** Pars costalis diaphragmatis. The part of the diaphragm originating from ribs 7–12. C D
- 28 **Sternal part of diaphragm.** Pars sternalis diaphragmatis. The part of the diaphragm arising from the sternum. C D
- 29 **Aortic (opening) hiatus.** Hiatus aorticus. Passageway for the aorta between the right and left crus of the lumbar part. D
- 30 **Esophageal (opening) hiatus.** Hiatus oesophageus. Passageway for the esophagus and the vagus nerves above the aortic opening. D
- 31 **Central tendon.** Centrum tendineum. Cloverleaf-shaped, tendinous central area of the diaphragm. D
- 32 **Foramen for the inferior vena cava.** Foramen venae caevae. Opening in the central tendon for the inferior vena cava. D
- 33 **Medial arcuate ligament.** Lig. arcuatum mediale. Tendinous arch between the body and transverse process of L1 or L2 forming the passageway for the psoas muscle. D
- 34 **Lateral arcuate ligament.** Lig. arcuatum laterale. Tendinous arch over the quadratus lumborum muscle between the transverse process of L1 and the 12th rib. D
- 35 **Median arcuate ligament.** Lig. arcuatum medianum. Tendinous arch over the aortic hiatus. D



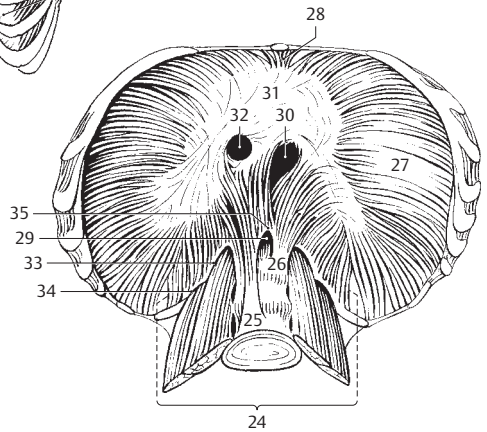
A Muscles of thorax, anterior view



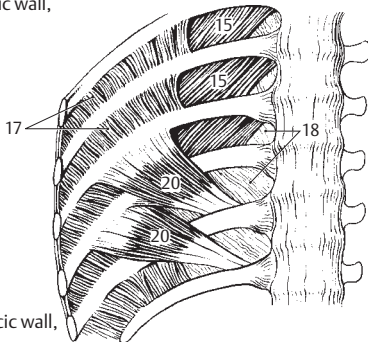
B Levator muscles of ribs



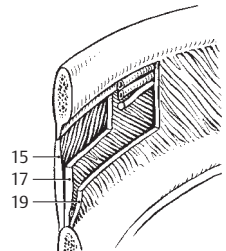
C Anterior thoracic wall, posterior view



D Diaphragm, inferior view

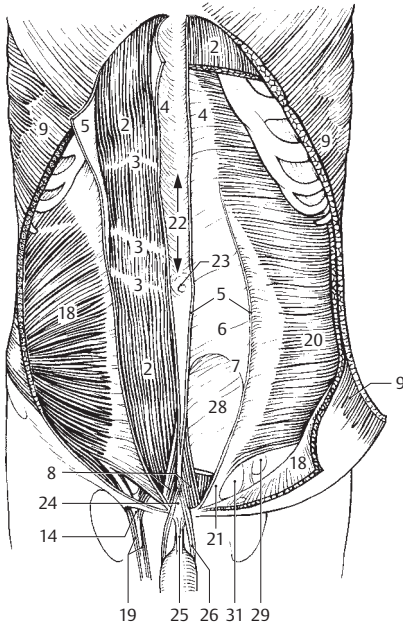


E Posterior thoracic wall, anterior view

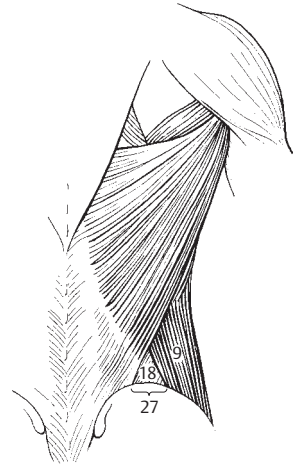

F Intercostal muscles

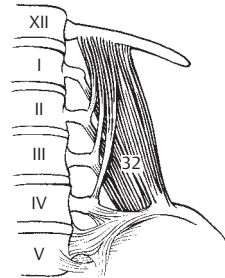
- 1 **ABDOMINAL MUSCLES.** Musculi abdominis.
- 2 **M. rectus abdominis.** o: Costal cartilages 5–7. i: Pubis and symphysis. A: Forward flexion of trunk, lowering of thorax, elevation of pelvis. I: Intercostal nerves 7–12. A E
- 3 **Tendinous intersections.** Intersectiones tendineae. The 3–4 intermediate tendons of the rectus abdominis muscle. They fuse with the anterior wall of the rectus sheath. A
- 4 **Rectus sheath.** Vagina m. recti abdominis. Covering of the rectus abdominis muscle formed by the aponeuroses of the flat abdominal muscles. A
- 5 **Anterior layer of rectus sheath.** Lamina anterior. A
- 6 **Posterior layer of rectus sheath.** Lamina posterior. A
- 7 **Arcuate line.** Linea arcuata. Caudal end of the posterior layer of the rectus sheath. A
- 8 **M. pyramidalis.** Muscle enclosed within the split anterior layer of the rectus sheath. It passes from the pubis and symphysis to the linea alba. I: Subcostal nerve. A
- 9 **External abdominal oblique muscle.** M. obliquus externus abdominis. o: Outer surface of ribs 5–12. i: Iliac crest, rectus sheath, linea alba. A: Lowering of thorax, rotation of trunk, lateral flexion. I: Intercostal nerves 5–12. A B D
- 10 **Inguinal ligament.** Lig. inguinale (Arcus inguinalis). The lower edge of the external oblique aponeurosis. It passes from anterior superior iliac spine to the pubic tubercle. D E
- 11 **Lacunar ligament.** Lig. lacunare. Connective tissue fibers arching downward to the pubis at the medial attachment of the inguinal ligament. D
- 12 **Pectineal ligament.** Lig. pectineale. Continuation of the lacunar ligament along the pecten pubis. D
- 13 **Reflected ligament.** Lig. reflexum. Curved band of fibers passing upward from the medial attachment of the inguinal ligament and forming the medial lining of the superficial inguinal ring. D
- 14 **Superficial inguinal ring.** Anulus inguinalis superficialis. External opening of the inguinal canal. A D
- 15 **Medial crus.** Crus mediale. Group of fibers of the external oblique aponeurosis ascending obliquely medial to the superficial inguinal ring. D
- 16 **Lateral crus.** Crus laterale. Group of fibers of the external oblique aponeurosis ascending lateral to the superficial inguinal ring. D
- 17 **Intercrural fibers.** Fibrae intercrurales. Curved fibers between the medial and lateral crura. D
- 18 **Internal abdominal oblique muscle.** M. obliquus internus abdominis. o: Thoracolumbar fascia, iliac crest, inguinal ligament. i: Ribs 10–12 and rectus sheath. A: Lowering of ribs, forward and lateral flexion. I: Intercostal nerves 8–12, iliohypogastric and ilio-inguinal nerves. A B
- 19 **M. cremaster.** Muscle fibers derived primarily from the internal oblique abdominal muscle. It invests the spermatic cord and elevates the testis. A
- 20 **M. transversus abdominis.** o: Inner surface of ribs 7–12, thoracolumbar fascia, iliac crest, inguinal ligament. i: Rectus sheath. I: Intercostal nerves 7–12, iliohypogastric, ilio-inguinal, genitofemoral nerves. A
- 21 **Conjoined tendon.** Falx inguinalis (tendo conjunctivus). Fibers arching from the aponeurosis of the transversus muscle into the pectineal ligament. A E
- 22 **Linea alba.** The white tendinous line (raphe) formed by the abdominal aponeuroses. It is situated between the right and left rectus abdominis muscles. A E
- 23 **Umbilical ring.** Anulus umbilicalis. Fibrous ring around the umbilicus in the linea alba. A
- 24 **Adminiculum lineae albae.** Inferior attachment of the linea alba at the symphysis. A E
- 25 **Suspensory ligament of penis (clitoris).** Lig. suspensorium penis/clitoridis. It radiates from the pubis into the deep fascia of the penis (clitoris). A
- 26 **Fundiform ligament of penis.** Lig. fundiforme penis. Elastic band arising from the abdominal fascia and linea alba and extending sling-like onto the penis. A
- 27 **Lumbar triangle.** Trigonum lumbale. Weak area of the back bordered by the latissimus dorsi, external abdominal oblique m. and iliac crest. B
- 28 **Transversalis fascia.** Fascia transversalis. Fascia between the peritoneum and abdominal musculature. A E
- 29 **Deep inguinal ring.** Anulus inguinalis profundus. Inner inguinal ring at the transition of the transversalis fascia into the internal spermatic fascia. A E
- 30 **Inguinal canal.** Canalis inguinalis. Walls: Inguinal ligament, external oblique aponeurosis, internal oblique and transversus abdominis muscles, interfoveolar ligament. It contains the spermatic cord. E
- 31 **Interfoveolar ligament.** Lig. interfoveolare. Thickened portion of the transversalis fascia behind the inguinal canal. A E
- 32 **M. quadratus lumborum.** o: Iliac crest and processes of lumbar vertebrae. i: 12th rib, transverse processes of lumbar vertebrae. A: Lowers ribs, lateral flexion. I: 12th intercostal nerve, lumbar plexus. C
- 33 **Linea semilunaris.** Arched musculotendinous margin of the transversus abdominis muscle.



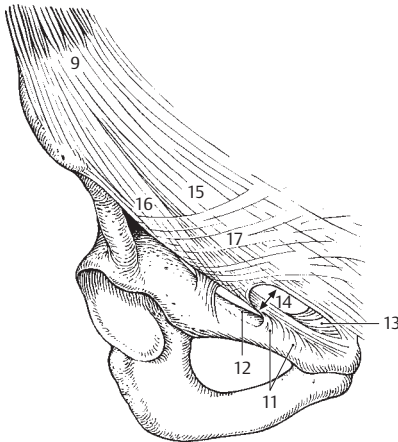
A Abdominal muscles, anterior view



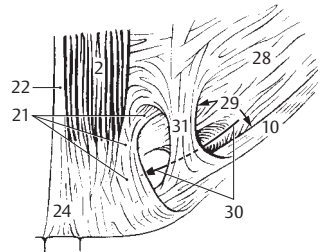
B Lumbar triangle



C Musculus quadratus lumborum, anterior view

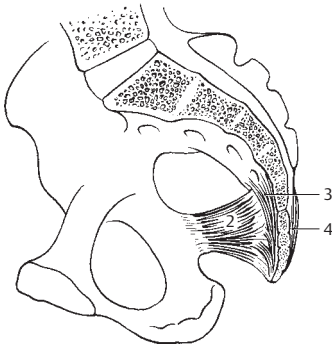


D Inguinal region, anterior view

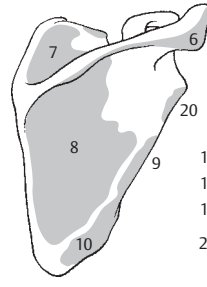


E Inguinal region, posterior view

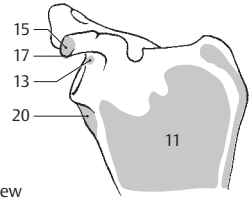
- 1 **COCYGEAL MUSCLES.** Musculi coccygei.
- 2 **M. coccygeus.** o: Ischial spine. i: Coccyx and adjoining sacrum. It lies medial to the sacrospinous ligament. I: Spinal nerve. A. See also p. 174. 13.
- 3 **[[Ventral (anterior) sacrococcygeus muscle]].** M. sacrococcygeus ventralis. Occasional rudiment of the primitive coccygeal musculature passing anteriorly from the sacrum to the coccyx. A
- 4 **[[Dorsal (posterior) sacrococcygeus muscle]].** M. sacrococcygeus dorsalis. Rudimentary remnant of coccygeal musculature passing posteriorly from the sacrum to the coccyx. A
- 5 **MUSCLES OF THE UPPER LIMB.** Musculi membri superioris.
- 6 **M. deltoideus.** o: Spine of scapula, acromion clavicle. i: Deltoid tuberosity of humerus. A: Lateral and medial rotation, abduction, adduction, forward and backward flexion. I: Axillary nerve. B E F G
- 7 **M. supraspinatus.** o: Supraspinous fossa. i: Greater tubercle of humerus. A: Abduction, medial and lateral rotation. I: Suprascapular nerve. B E F G
- 8 **M. infraspinatus.** o: Infraspinous fossa. i: Greater tubercle of humerus. A: Lateral rotation. I: Suprascapular nerve. B F G
- 9 **M. teres minor.** o: Beside the infraspinatus muscle. i: Greater tubercle. A: Lateral rotation and weak adduction. I: Axillary nerve. B F G
- 10 **M. teres major.** o: Lateral margin of scapula. i: Crest of lesser tubercle. A: Medial rotation and adduction with dorsiflexion of arm. I: Subscapular nerve. B D E G
- 11 **M. subscapularis.** o: Subscapular fossa. i: Lesser tubercle. Medial rotation of arm. I: Subscapular nerve. C D E
- 12 **M. biceps brachii.** Two-headed upper arm muscle with the three parts described below (nos. 13–15). i: Radial tuberosity and ulna via the bicipital aponeurosis. A: Flexion and supination of the elbow joint. I: Musculocutaneous nerve. D
- 13 **Long head of biceps.** Caput longum. o: Supraglenoid tubercle. i: Radial tuberosity and ulna. A: Flexion and supination of the elbow joint, weak abduction of the shoulder joint. C D
- 14 **Intertubercular tendon sheath.** Vagina tendinis intertubercularis. Synovial sheath for the tendon of the long head of the biceps in the intertubercular groove. D
- 15 **Short head of biceps.** Caput breve. o: Coracoid process. i: Radial tuberosity of ulna. A: Flexion of the elbow joint and supination, forward flexion of the arm at the shoulder joint. C D
- 16 **Bicipital aponeurosis.** Aponeurosis m. bicipitis brachii (aponeurosis bicipitalis) [[lacetus fibrosus]]. Medial expansion of the biceps tendon that attaches to the forearm fascia. A: Transmits the pull of the biceps to the ulna when the arm is supinated. D
- 17 **M. coracobrachialis.** o: Coracoid process. i: Middle third of humerus anteriorly. A: Forward flexion, weak adduction and medial rotation of the arm. I: Musculocutaneous nerve. C D E
- 18 **M. brachialis.** o: Lower 2/3 of anterior surface of humerus. i: Ulnar tuberosity. A: Flexion of the elbow joint. I: Musculocutaneous nerve. D E F
- 19 **M. triceps brachii.** Three-headed upper arm muscle with common attachment to the olecranon. G
- 20 **Long head of triceps.** Caput longum. o: Infraglenoid tubercle. i: Olecranon. A: Extension of the elbow joint, adduction of the shoulder joint. It separates the medial (triangular) from the lateral (quadrangular) space. B C D G
- 21 **Lateral head of triceps.** Caput laterale. o: Posterior surface of humerus lateral and proximal to groove for radial nerve. i: Olecranon. A: Extension of the elbow joint. F G
- 22 **Medial head of triceps.** Caput mediale. o: Medial and distal to groove for radial nerve. i: Olecranon. A: Extension of the elbow joint. F G
- 23 **Superior and inferior apertures.** [[Aperturæ superior et inferior]]. Medial and lateral ends of the fascial cone for the large neurovascular bundles in the axilla.
- 24 **M. anconeus.** o: Lateral humeral epicondyle. Continuation of medial head of triceps. i: Lateral margin of olecranon and posterior surface of ulna. A: Extension of the elbow joint. I: Radial nerve. G
- 25 **M. articularis cubiti.** Articular muscle of elbow. Its fibers pass from the triceps brachii to the articular capsule. A: Tenses the capsule. I: Radial nerve.
- 26 **M. pronator teres.** o: Medial epicondyle of humerus and coronoid process of ulna. i: Middle of lateral surface of radius. A: Pronation and flexion of the elbow joint. I: Median nerve. D
- 27 **Humeral head of pronator teres.** Caput humerale. The portion arising from the medial epicondyle. D E
- 28 **Ulnar head of pronator teres.** Caput ulnare. The part arising from the coronoid process. D



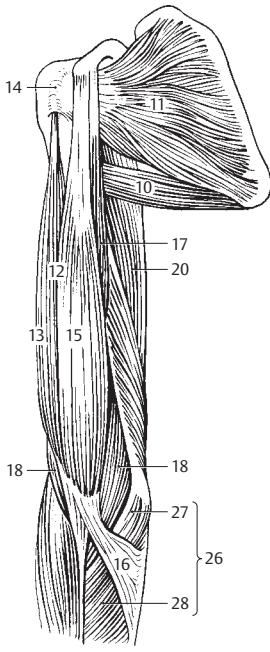
A Right half of pelvis, medial view



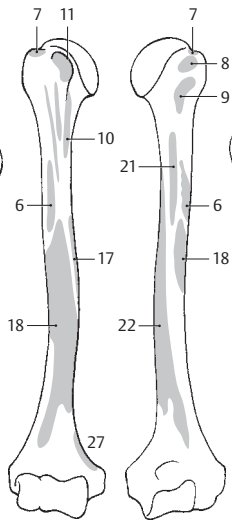
B Scapula, posterior view



C Scapula, anterior view

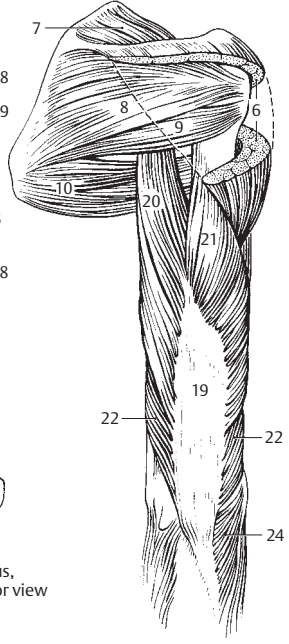


D Upper arm, anterior view



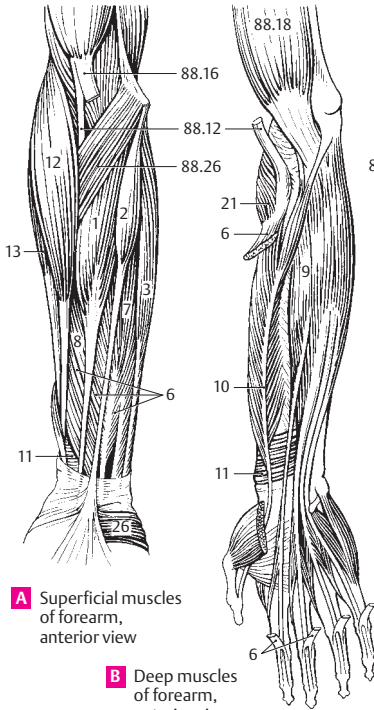
E Humerus, anterior view

F Humerus, posterior view



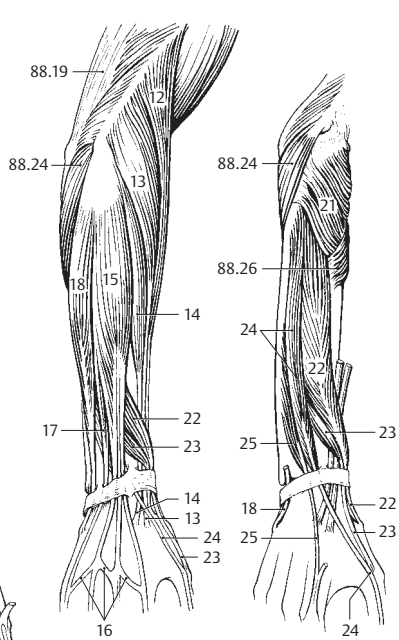
G Upper arm, posterior view

- 3
- 1 **M. flexor carpi radialis.** o: Medial epicondyle of humerus. i: Base of 2nd metacarpal bone. A: Pronation, flexion and radial abduction of the wrist joint. I: Median nerve. A
 - 2 **M. palmaris longus.** o: Medial epicondyle of humerus. i: Palmar aponeurosis. A: Tenses aponeurosis and flexes the wrist joint and fingers 2–5 at the metacarpophalangeal joints. Its tendon lies above the flexor retinaculum. I: Median nerve. A
 - 3 **M. flexor carpi ulnaris.** o: Medial epicondyle of humerus, olecranon and ulna. i: Pisiform bone as well as the hamate and 5th metacarpal bones via the pisohamate and pisometacarpal ligaments. A: Ulnar abduction and flexion of the wrist joint. I: Ulnar nerve. A
 - 4 **Humeral head of flexor carpi ulnaris.** Caput humerale. The part arising from the epicondyle of the humerus.
 - 5 **Ulnar head of flexor carpi ulnaris.** Caput ulnare. The portion originating from the ulna. E
 - 6 **M. flexor digitorum superficialis.** o: Medial epicondyle of humerus, coronoid process of ulna and anterior surface of radius. i: Middle phalanx of fingers 2–5. A: Flexion of all joints it crosses. Each tendon is perforated by the corresponding tendon from the flexor digitorum profundus. I: Median nerve. A B
 - 7 **Humero-ulnar head of flexor digitorum superficialis.** Caput humero-ulnare. The portion arising from the humerus and ulna. A E F
 - 8 **Radial head of flexor digitorum superficialis.** Caput radiale. The portion arising from the radius. A E
 - 9 **M. flexor digitorum profundus.** o: Upper half of ulna. i: Base of distal phalanges of fingers 2–5. A: Flexion of all joints crossed. The tendon perforates the corresponding superficial flexor tendon. I: Median and ulnar nerves. B E F
 - 10 **M. flexor pollicis longus.** o: Middle of anterior surface of radius and usually the medial epicondyle. i: Distal phalanx of thumb. A: Flexion of joints crossed. I: Median nerve. B E
 - 11 **M. pronator quadratus.** o: Lower fourth of anterior surface of ulna. i: Lower fourth of anterior surface of radius. A: Pronation. I: Median nerve. A B E
 - 12 **M. brachioradialis.** o: Intermuscular septum and lateral margin of humerus. i: Styloid process of radius. A: Flexion of the elbow joint. It brings the arm from the extreme pronation and supination position to the intermediate position. I: Radial nerve. A C E
 - 13 **M. extensor carpi radialis longus.** o: Lateral intermuscular septum, lateral epicondyle. i: Extensor side of metacarpal 2. A: Radial abduction and dorsiflexion of the wrist joint. Flexion of the elbow joint. I: Radial nerve. A C
 - 14 **M. extensor carpi radialis brevis.** o: Lateral epicondyle of humerus. i: Proximal extensor side of third metacarpal. A: Extension and radial abduction of wrist joint. I: Radial nerve. C
 - 15 **M. extensor digitorum.** o: Lateral epicondyle of humerus. i: Distal phalanges 2–5 via their dorsal aponeurosis. A: Extension of fingers and dorsiflexion of the wrist joint. I: Radial nerve. C
 - 16 **Intertendinous connections.** Connexus intertendineus [[juncturae tendineum]]. Oblique tendinous connections between the extensor tendons of the fingers on the dorsum of the hand. C
 - 17 **M. extensor digiti minimi.** o: Lateral epicondyle of humerus. i: Dorsal aponeurosis of 5th finger. A: Extension of little finger, abduction and dorsiflexion of the wrist joint. I: Radial nerve. C
 - 18 **M. extensor carpi ulnaris.** o: Lateral epicondyle of humerus, radial collateral ligament, posterior surface of ulna. i: Base of 5th metacarpal. A: Dorsiflexion, ulnar abduction. I: Radial nerve. C D
 - 19 **Humeral head of extensor carpi ulnaris.** Caput humerale. The part arising from the humerus.
 - 20 **Ulnar head of extensor carpi ulnaris.** Caput ulnare. The portion arising from the ulna. F
 - 21 **M. supinator.** o: Lateral epicondyle, radial collateral ligament, supinator crest of ulna. i: Anterior surface of radius. A: Supination. I: Radial nerve. D E F
 - 22 **M. abductor pollicis longus.** o: Dorsal side of interosseous membrane and adjacent surfaces of radius and ulna. i: Base of 1st metacarpal. A: Radial abduction and dorsiflexion of the metacarpophalangeal joint of the thumb. Supination. I: Radial nerve. C D F
 - 23 **M. extensor pollicis brevis.** o: Radius (extensor side) and interosseous membrane. i: Base of proximal phalanx of thumb. A: Abduction and extension of thumb at the metacarpophalangeal joint. I: Radial nerve. C D F
 - 24 **M. extensor pollicis longus.** o: Interosseous membrane and dorsal surface of ulna. i: Distal phalanx of thumb. A: Adducts and extends the thumb. Supinator. I: Radial nerve. C D F
 - 25 **M. extensor indicis.** o: Interosseous membrane and dorsal surface of ulna. i: Dorsal aponeurosis of index finger. A: Extends the index finger and wrist joint. I: Radial nerve. D F
 - 26 **M. palmaris brevis.** o: Ulnar side of palmar aponeurosis. i: Skin of ulnar aspect of hand. I: Ulnar nerve. A



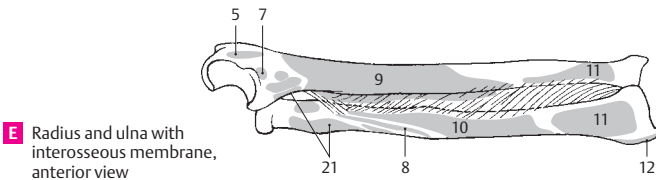
A Superficial muscles of forearm, anterior view

B Deep muscles of forearm, anterior view

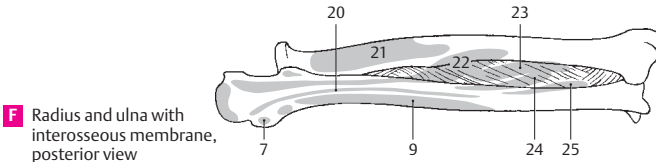


C Superficial extensor muscles of forearm

D Deep extensor muscles of forearm

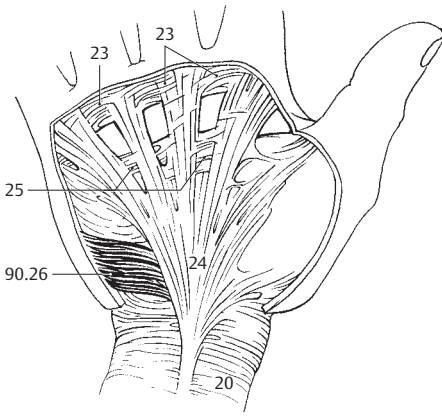


E Radius and ulna with interosseous membrane, anterior view

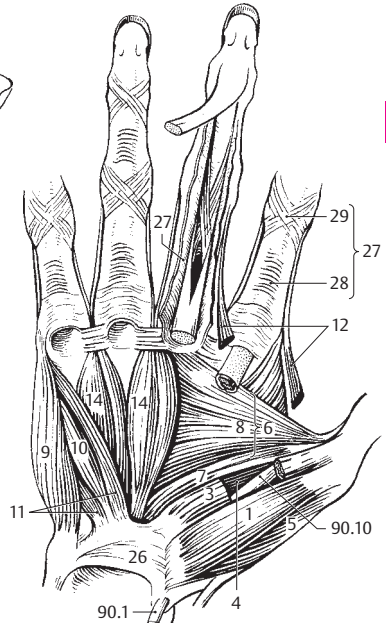


F Radius and ulna with interosseous membrane, posterior view

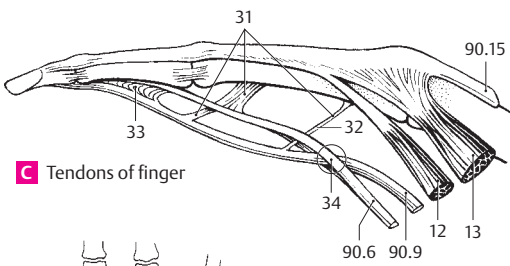
- 1 **M. abductor pollicis brevis.** o: Scaphoid bone and flexor retinaculum. i: Lateral sesamoid bone and, radially, the proximal phalanx of the thumb. A: Abduction and flexion of the thumb. I: Median nerve. B
- 2 **M. flexor pollicis brevis.** o: Carpal bones, base of 1st metacarpal and flexor retinaculum. i: Lateral sesamoid bone, radially aspect of proximal phalanx of thumb. A: Adducts and flexes thumb. B
- 3 **Superficial head of flexor pollicis brevis.** Caput superficiale. The portion situated on the tendon of the flexor pollicis longus and innervated by the median nerve. B
- 4 **Deep head of flexor pollicis brevis.** Caput profundum. The portion situated below the tendon of the flexor pollicis longus and innervated by the ulnar nerve. B
- 5 **M. opponens pollicis.** o: Trapezium and flexor retinaculum. i: First metacarpal. A: Adduction and opposition of thumb. I: Median nerve. B
- 6 **M. adductor pollicis.** o: Capitate, radiate carpal ligament, metacarpal bone 3. i: Medial sesamoid bone, ulnar aspect of base of proximal phalanx of thumb. A: Adduction and opposition of thumb. I: Ulnar nerve. B
- 7 **Oblique head of adductor pollicis.** Caput obliquum. The portion arising from the capitate and radiate carpal ligament. B
- 8 **Transverse head of adductor pollicis.** Caput transversum. The portion originating from the 3rd metacarpal bone. B
- 9 **M. abductor digiti minimi.** o: Pisiform and flexor retinaculum. i: Base of proximal phalanx of little finger and dorsal aponeurosis. A: Abduction, flexion and extension of the little finger. I: Ulnar nerve. B
- 10 **M. flexor digiti minimi brevis.** o: Hook of hamate and flexor retinaculum. i: Base of proximal phalanx of little finger. A: Flexion of finger at the metacarpophalangeal joint. I: Ulnar nerve. B
- 11 **M. opponens digiti minimi.** o: Hook of hamulus and flexor retinaculum. i: Head and shaft of 5th metacarpal. A: Draws the little finger toward the palm of the hand. I: Ulnar nerve. B
- 12 **Mm. lumbricales.** o: Tendons of flexor digitorum profundus. i: Dorsal aponeuroses of fingers 2–5. A: Flexion of finger at the metacarpophalangeal joints, extension at the interphalangeal joints. I: Ulnar and median nerves. B,C
- 13 **Mm. interossei dorsales.** o: Arises by two heads from the metacarpals. i: Dorsal aponeurosis of fingers 2–4. A: Spreading of fingers 2–4 away from axis of middle finger, radial and ulnar abduction of middle finger, flexion of finger at the metacarpophalangeal joint and extension of the interphalangeal joints. I: Ulnar nerve. C,D,E
- 14 **Mm. interossei palmares.** o: Metacarpal bones 2, 4 and 5. i: Dorsal aponeuroses of fingers 2, 4 and 5. A: Adduction of index, ring and little fingers toward the middle finger, flexion of the metacarpophalangeal joints, extension of the interphalangeal joints. I: Ulnar nerve. B,D
- 15 **Axillary fascia.** Fascia axillaris. Situated on the adipose body of the axilla. It unites the lateral margins of the pectoral and latissimus dorsi muscles. G
- 16 **Deltoid fascia.** Fascia deltoidea. Strongly fused investing fascia of the deltoid muscle.
- 17 **Brachial fascia.** Fascie brachii (brachialis). Fascia enclosing the upper arm muscles. F
- 18 **Medial intermuscular septum of the arm.** Septum intermusculare brachii mediale. Tendinous sheet for muscle origin between the medial margin of the humerus and the brachial fascia. F
- 19 **Lateral intermuscular septum of the arm.** Septum intermusculare brachii laterale. Tendinous sheet for muscle attachment between the lateral margin of the humerus and the brachial fascia. F
- 20 **Antebrachial fascia.** Fascia antebrachii. Fascia enveloping the forearm muscles. A
- 21 **Fascia of the dorsum of the hand.** Fascia dorsalis manus. Fascia situated on the dorsal tendons of the hand. E
- 22 **Extensor retinaculum.** Retinaculum extensorum [[lig. carpi dors.]]. Transverse fascial fibers over the 6 conduction canals of the 10 extensor tendons. E
- 23 **Superficial transverse metacarpal ligament.** Lig. metacarpale transversum superficiale. Transverse reinforcement of the palmar fascia of the hand at the level of the heads of the metacarpals. A
- 24 **Palmar aponeurosis.** Aponeurosis palmaris. Membranous expansion of the tendon of the palmaris longus muscle. A
- 25 **Transverse fasciculi.** Fasciculi transversi. Transversely oriented fibrous bundles of the palmar aponeurosis. A
- 26 **Flexor retinaculum.** Retinaculum flexorum [[lig. carpi transversum]]. Stout fibrous band between the scaphoid, trapezoid, pisiform and hamate bones. It binds the flexor tendons. B
- 27 **Fibrous sheaths of fingers.** Vaginae fibrosae digitorum manus. Fibrous synovial tunnel for the digital flexor tendons. B
- 28 **Annular part of fibrous sheath.** Pars anularis vaginae fibrosae. Very compact circular fibers of the fibrous sheath located between the joints. B
- 29 **Cruciate part of fibrous sheath.** Pars cruciformis vaginae fibrosae. Crossed fibers that reinforce the joints. B
- 30 **Synovial sheaths of the fingers.** Vaginae synoviales digitorum manus. Tendon sheaths of the digital flexor tendons.
- 31 **Vincula tendinum.** Connective tissue fasciculi (mesotendons) transporting vessels to the tendons. C
- 32 **Vinculum longum.** Longer fasciculus at the level of the proximal phalanx. C
- 33 **Vinculum breve.** Shorter fasciculus near the insertions of the tendons. C
- 34 **Chiasma tendinum.** Crossing of the tendons of the flexor digitorum superficialis and profundus. C



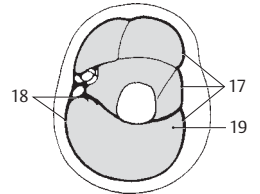
A Palmar aponeurosis and fasciae



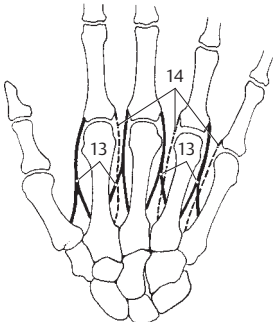
B Palm muscles



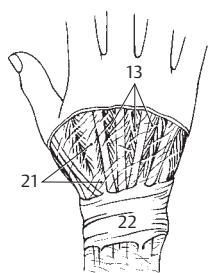
C Tendons of finger



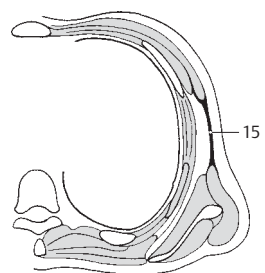
F Cross section of upper arm



D Interosseous muscles, schematic

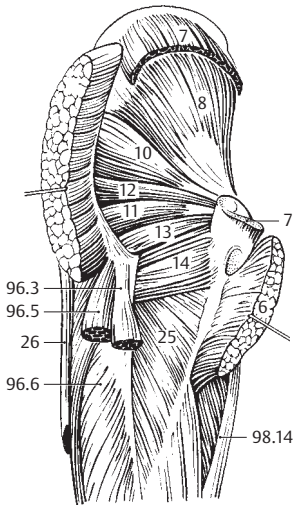


E Dorsum of hand

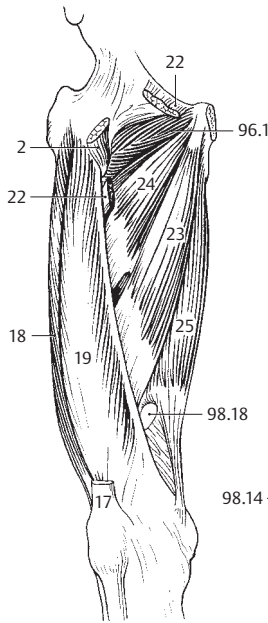


G Cross section of thorax

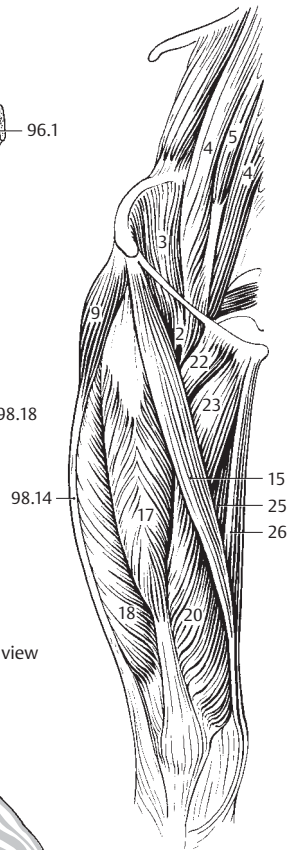
- 1 **MUSCLES OF LOWER LIMB.** Musculi membri inferioris.
- 2 **M. iliopsoas.** Comprised of two muscles, the psoas major and iliacus. o: Lesser trochanter. A: Most important flexor and pre-elevator muscle of the legs; medial and lateral rotation of thigh at the hip joint. B C D
- 3 **M. iliacus.** o: Iliac fossa. i: Lesser trochanter. A: Flexion, medial and lateral rotation of thigh at the hip joint. I: Femoral nerve and lumbar plexus. C
- 4 **M. psoas major.** o: Bodies and transverse processes of L1–4. i: Lesser trochanter. A: Flexion, medial and lateral rotation of thigh at the hip joint. I: Lumbar plexus. C
- 5 **[M. psoas minor].** o: Bodies of T12 and L1. i: Iliac fascia. I: Lumbar plexus. C
- 6 **M. gluteus maximus.** o: Posterior, external surface of ilium, sacrum, coccyx, sacrotuberous ligament. i: Iliotibial tract, gluteal tuberosity, lateral intermuscular septum, linea aspera. A: Extension, lateral rotation, abduction and adduction of thigh at the hip joint. I: Inferior gluteal nerve. A D E
- 7 **M. gluteus medius.** o: External surface of ilium. i: Greater trochanter. A: Abduction, medial and lateral rotation, flexion and extension of thigh at the hip joint. I: Superior gluteal nerve. A D E
- 8 **M. gluteus minimus.** o: External surface of ilium between anterior and inferior gluteal lines. i: Greater trochanter. A: Abduction, medial and lateral rotation, flexion and extension of the thigh at the hip joint. I: Superior gluteal nerve. A D E
- 8a **Gluteal aponeurosis.** Aponeurosis glutealis. Deep, sheet-like tendon of origin of the gluteus maximus lying on the gluteus medius.
- 9 **M. tensor fasciae latae.** o: Near the anterior superior iliac spine. i: Above the iliotibial tract lateral to the tibial tuberosity. A: Flexion, abduction and medial rotation of thigh at the hip joint. Flexion, extension and final rotation at the knee joint. I: Superior gluteal nerve. C E
- 10 **M. piriformis.** o: Anterior surface of sacrum. i: Greater trochanter, inner side of apex. A: Abduction, extension and lateral rotation of thigh at the hip joint. I: Sacral plexus. A D
- 11 **M. obturator internus.** o: Inner surface of obturator membrane and environment. i: Trochanteric fossa. A: Lateral rotation, abduction and adduction of thigh. I: Sacral plexus. A D
- 12 **M. gemellus superior.** o: Ischial spine. i: Tendon of obturator internus and trochanteric fossa. A: Lateral rotation, adduction and abduction of thigh. I: Sacral plexus. A D E
- 13 **M. gemellus inferior.** o: Ischial tuberosity. i: Tendon of obturator internus, trochanteric fossa. A: Lateral rotation, adduction and abduction of thigh. I: Sacral plexus. A D E
- 14 **M. quadratus femoris.** o: Ischial tuberosity. i: Intertrochanteric crest. A: Lateral rotation and adduction of thigh. I: Sacral plexus. A D E
- 15 **M. sartorius.** o: Anterior superior iliac spine. i: Medial to tibial tuberosity. A: Flexion, abduction, lateral rotation of thigh at the hip joint, flexion and medial rotation of leg at the knee joint. I: Femoral nerve. C E
- 16 **M. quadriceps femoris.** The muscle group comprising the three vasti muscles and the rectus femoris. I: Femoral nerve.
- 17 **M. rectus femoris.** o: Anterior inferior iliac spine = straight head and upper margin of acetabulum. = reflected head. i: Tibial tuberosity. A: Flexion of thigh at the hip joint, extension of leg at the knee joint. B C E
- 18 **M. vastus lateralis.** o: Greater trochanter, lateral lip of linea aspera. i: Quadriceps tendon. A: Extension of leg at the knee joint. B C D
- 19 **M. vastus intermedius.** o: Anterior surface of femur. i: Quadriceps tendon. A: Extension of leg at the knee joint. B D
- 20 **M. vastus medialis.** o: Distal to intertrochanteric line, medial lip of linea aspera. i: Quadriceps tendon. A: Extension of leg at the knee joint. C D
- 21 **M. articularis genus.** o: Anterior surface of femur. i: Knee joint capsule. A: Tenses capsule. I: Femoral nerve. D
- 22 **M. pectineus.** o: Pecten pubis. i: Pectineal line below the lesser trochanter. A: Flexion, adduction and lateral rotation of thigh at the hip joint. I: Femoral and obturator nerves. B C D E
- 23 **M. adductor longus.** o: Near the symphysis. i: Medial lip of linea aspera. A: Adduction and flexion of thigh at the hip joint. I: Obturator nerve. B C D E
- 24 **M. adductor brevis.** o: Inferior ramus of pubis. i: Medial lip of linea aspera. A: Adduction, flexion, extension and lateral rotation of thigh at the hip joint. I: Obturator nerve. B D E
- 25 **M. adductor magnus.** o: Ischial tuberosity, ischial ramus. i: Medial lip of linea aspera and with a long tendon to the medial epicondyle. A: Adduction and extension of thigh at the hip joint. I: Obturator and sciatic nerves. B C D E
- 25a **M. adductor minimus.** Uppermost part of the adductor magnus muscle. It arises from a more anterior part of the pelvis.
- 26 **M. gracilis.** o: Inferior ramus of pubis medial to the adductor magnus muscle. i: Medial to tibial tuberosity. A: Adduction, flexion and extension of thigh at the hip joint. Flexion and medial rotation of the knee joint. I: Obturator nerve. A C E



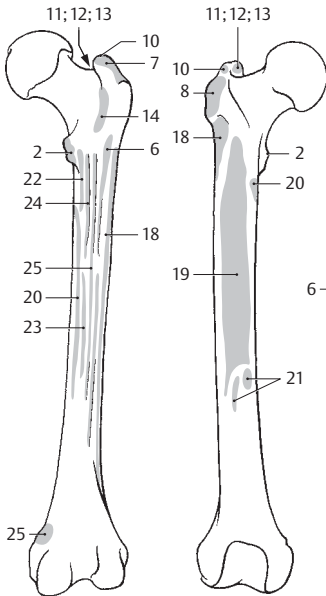
A Deep muscles of hip, posterior view



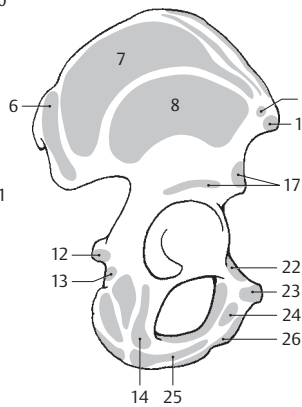
B Thigh, anterior view



C Thigh, anterior view

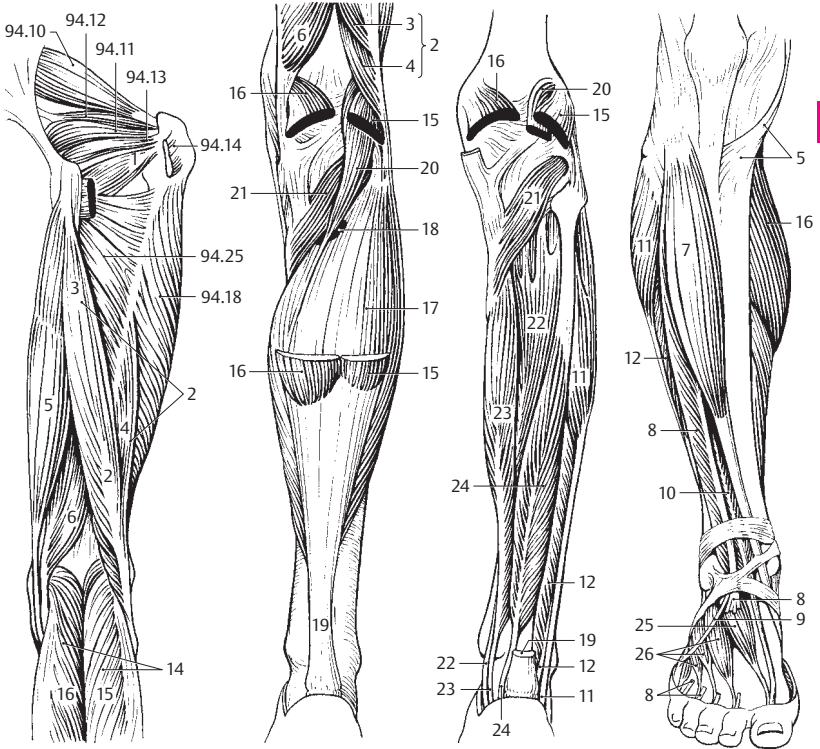


D Femur, posterior and anterior views



E Hip bone, lateral view

- 3
- 1 **M. obturator externus.** o: External surface of obturator membrane and environment. i: Trochanteric fossa. A: Lateral rotation and adduction of thigh at the hip joint. I: Obturator nerve. A
 - 2 **M. biceps femoris.** o: Arises from the pelvis and femur via two heads. i: Head of fibula. I: Sciatic nerve, tibial part. A B E F
 - 3 **Long head of biceps femoris.** Caput longum. o: Ischial tuberosity. i: Head of fibula. A: Extension, adduction and lateral rotation of thigh at the hip joint; flexion and lateral rotation of the knee joint. I: Tibial nerve. A B
 - 4 **Short head of biceps femoris.** Caput breve. o: Lateral lip of linea aspera. i: Head of fibula. A: Flexion and lateral rotation of the knee joint. I: Common peroneal nerve. A B
 - 5 **M. semitendinosus.** o: Ischial tuberosity. i: Medial to tibial tuberosity [pes anserinus]. A: Extension, medial rotation and adduction at the hip joint; flexion and medial rotation at the knee joint. I: Tibial nerve. A D E
 - 6 **M. semimembranosus.** o: Ischial tuberosity. i: Medial condyle of tibia and oblique popliteal ligament. It is partially covered by the semitendinosus muscle. A: Extension, adduction and medial rotation of thigh at the hip joint; flexion and medial rotation of the knee joint. Tenses knee joint capsule. I: Tibial nerve. A B F
 - 7 **M. tibialis anterior.** o: Lateral surface of tibia, interosseous membrane, fascia of leg (crural fascia). i: Medial aspect of medial cuneiform bone and 1st metatarsal. A: Dorsiflexion and supination of foot. I: Deep fibular nerve. D E
 - 8 **M. extensor digitorum longus.** o: Lateral tibial condyle, interosseous membrane, fibula. i: Dorsal aponeurosis of toes 2–5. A: Dorsiflexion and pronation of foot, extension of toes. I: Deep fibular nerve. D E
 - 9 **M. peroneus tertius (m. fibularis tertius).** Muscle split off from the extensor digitorum longus and inserting into the base of the 5th metacarpal. A: Dorsiflexion and pronation of foot. I: Deep fibular nerve. D
 - 10 **M. extensor hallucis longus.** o: Interosseous membrane and fibula. i: Distal phalanx of big toe. A: Dorsiflexion of foot, extension of big toe. I: Deep fibular nerve. D E
 - 11 **M. peroneus longus [[m. fibularis longus]].** o: Fibula and crural fascia. i: Medial cuneiform bone and 1st metatarsal after an oblique course below the dorsum of the foot. A: Plantar flexion and pronation of foot. I: Superficial fibular nerve. C D E F
 - 12 **M. peroneus brevis [[m. fibularis brevis]].** o: Distal 2/3 of fibula. i: Tuberosity of 5th metatarsal. A: Plantar flexion and pronation. I: Superficial fibular nerve. C D E F
 - 13 **M. triceps surae.** Muscle group consisting of the gastrocnemius and soleus; it forms the Achilles tendon (tendo calcaneus). I: Tibial nerve.
 - 14 **M. gastrocnemius.** The superficial calf muscle with two heads (lateral, medial). A: Flexes the knee joint, plantar flexes and supinates the ankle joint. I: A B C D
 - 15 **Lateral head of gastrocnemius.** Caput laterale. o: Proximal to the lateral femoral condyle. i: Achilles tendon. A B C
 - 16 **Medial head of gastrocnemius.** Caput laterale. o: Proximal to the medial femoral condyle. i: Achilles tendon. A B C D
 - 17 **M. soleus.** o: Proximal ends of fibula and tibia. i: Achilles tendon. A: Plantar flexes and supinates the foot. B F
 - 18 **Tendinous arch of soleus muscle.** Arcus tendineus musculi solei. Tendinous arch above the interosseous membrane. Passageway for the tibial nerve and posterior tibial artery and vein. B
 - 19 **Tendo calcaneus [[Achilles tendon]].** The tendon of the triceps surae at the tuber of the calcaneus. B C
 - 20 **M. plantaris.** o: Above the lateral femoral condyle. i: Achilles tendon or tuberosity of the calcaneus. I: Tibial nerve. B C
 - 21 **M. popliteus.** o: Lateral femoral condyle. i: Posterior surface of tibia. A: Flexion of knee joint and medial rotation of leg. B C F
 - 22 **M. tibialis posterior.** o: Tibia, fibula, interosseous membrane. i: Navicular, cuneiforms, cuboid and metatarsals 2–4. One bundle of fibers extends backward to the sustentaculum tali of the calcaneus. A: Plantar flexor and supinator. I: Tibial nerve. C F
 - 23 **M. flexor digitorum longus.** o: Tibia. i: Distal phalanges of toes 2–5. A: Plantar flexion and supination of foot, flexion of toes. I: Tibial nerve. C F
 - 24 **M. flexor hallucis longus.** o: Fibula. i: Distal phalanx of big toe. A: Plantar flexion and supination of foot, flexion of big toe. I: Tibial nerve. C F
 - 25 **M. extensor hallucis brevis.** o: Dorsal surface of calcaneus. i: Proximal phalanx of big toe. A: Extends the big toe. I: see p. 26. D
 - 26 **M. extensor digitorum brevis.** o: Dorsal surface of calcaneus. i: Dorsal aponeuroses of toes 2–4. A: Extends toes. I: Deep fibular nerve. D



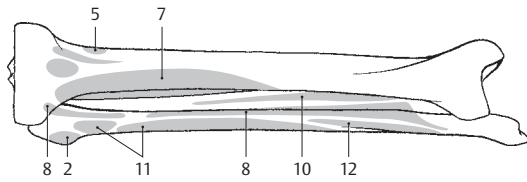
A Thigh, posterior view

B Lower leg, posterior view

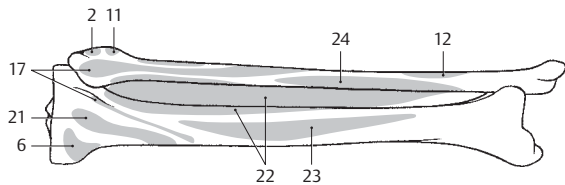
C Deep muscles of lower leg, posterior view

D Lower leg, anterior view

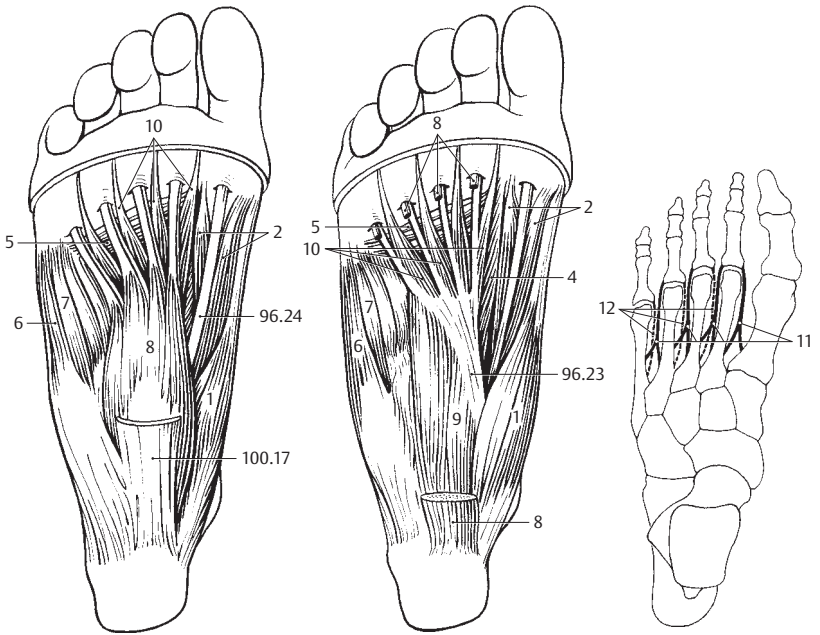
E Tibia and fibula, anterior view



F Tibia and fibula, posterior view



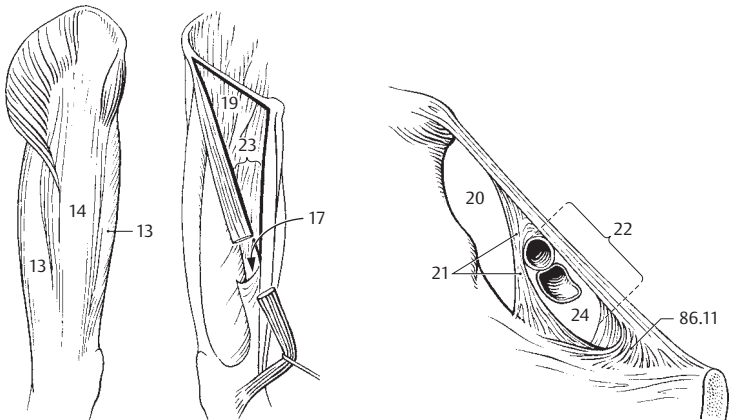
- 1 **M. abductor hallucis.** Abductor muscle of great toe. o: Medial process of tuber calcanei. i: Medial sesamoid and proximal phalanx of big toe. A: Medial abduction, supports the longitudinal arch. I: See 2. A B
- 2 **M. flexor hallucis brevis.** Short flexor muscle of the great toe. Origin: Cuneiform I, long plantar ligament, tendon of the posterior tibial m. and plantar aponeurosis. Forms a groove for transmission of the flexor hallucis longus m., stabilizes the longitudinal arch. A B
- 2a **Medial head.** Caput mediale. o: Tendon of the abductor m. of the great toe, sesamoid bone and proximal phalanx.
- 2b **Lateral head.** Caput laterale. o: Tendon of the adductor m. of the great toe, lateral sesamoid bone and proximal phalanx of the great toe.
- 3 **M. adductor hallucis.** Important muscle for the transverse arch of the foot consisting of the following two heads.
- 4 **Oblique head.** Caput obliquum. o: Metatarsals 2–4, lateral cuneiform and cuboid bones. i: Lateral sesamoid bone and proximal phalanx of big toe together with the transverse head. A: Important for stabilization of transverse and longitudinal arches. B
- 5 **Transverse head.** Caput transversum. o: Capsules of metatarsophalangeal joints 3–5. i: Lateral sesamoid bone. A: Primary function is to support the transverse arch of the foot. A B
- 6 **M. abductor digiti minimi.** o: Calcaneus and plantar aponeurosis. i: Laterally on proximal phalanx of 5th toe. A: Plantar flexion and abduction of the 5th toe. I: Lateral plantar nerve. A B
- 7 **M. flexor digiti minimi brevis.** o: Base of 5th metatarsal, long plantar ligament. i: Proximal phalanx of little toe. A: Flexion and abduction of little toe. I: Lateral plantar nerve. A B
- 7a **[M. opponens digiti minimi].** Muscle occasionally split off from the flexor digiti minimi brevis. o: Distal half of 5th metatarsal.
- 8 **M. flexor digitorum brevis.** o: Tuber calcanei and plantar aponeurosis. i: Middle phalanges of toes 2–5 via divided tendons. A: Flexes toes and supports the longitudinal arch of the foot. I: Medial plantar nerve. A B
- 9 **M. quadratus plantae (m. flexor accessorius).** o: Calcaneus. i: Lateral border of tendon of flexor digitorum longus. A: Flexes toes and supports longitudinal arch of foot. I: Lateral plantar nerve. B
- 10 **Mm. lumbricales pedis.** Lumbrical muscles of the foot. o: Tendons of flexor digitorum longus. i: Bases of proximal phalanges 2–5. A: Flexion at the metatarsophalangeal joint. Brings toes closer to the big toe. I: Medial and lateral plantar nerves. A B
- 11 **Mm. interossei dorsales pedis.** o: Arises by two heads from adjacent metatarsal bones. i: Base of the proximal phalanx, plantar ligament. A: Abduction and flexion of toes at the metatarsophalangeal joints and extension at the interphalangeal joints. I: Lateral plantar nerve. C
- 12 **Mm. interossei plantares.** o: Single-headed from metatarsal bones 3–5. i: Base of proximal phalanges. A: Adduction and flexion of toes at the metatarsophalangeal joints. I: cf. p. 11. C
- 13 **Fascia lata.** Fascia of thigh which envelops the entire thigh musculature. D
- 14 **Iliotibial tract.** Tractus iliotibialis. Vertical thick band of fascia lata that extends from the anterior segment of the iliac crest to the lateral tibial condyle and into which radiate the tensor fasciae latae and gluteus maximus. D
- 15 **Lateral intermuscular septum of thigh.** Septum intermusculare femoris laterale. Firm connective tissue layer extending from the fascia lata to the lateral lip of the linea aspera between the biceps femoris and vastus lateralis muscles.
- 16 **Medial intermuscular septum of thigh.** Septum intermusculare femoris mediale. Stout connective tissue layer extending from the fascia lata to the medial lip of the linea aspera between the vastus medialis, sartorius and adductor muscles.
- 17 **Adductor canal.** Canalis adductorius. Channel between adductors, vastus medialis and [vastoadductor membrane]. It ends with the hiatus tendineus within the adductor magnus. D
- 18 **Hiatus tendineus (adductorius).** Opening near the attachment of the adductor magnus at the level of the inferior margin of the adductor longus.
- 19 **Iliac fascia.** Fascia iliaca. Fascia over the iliac and inferior portion of the psoas muscles. It attaches to the iliac crest and arcuate line as well as the inguinal ligament. D
- 20 **Muscular lacuna.** Lacuna musculorum. Compartment for passage of the iliopsoas muscle and the femoral and lateral femoral cutaneous nerves between the ilium, inguinal ligament and iliopsoas arch. E
- 21 **Iliopectineal arch.** Arcus iliopsoas. Portion of the iliac fascia between the inguinal ligament and the iliopubic [iliopsoas] eminence. It separates the vascular and muscular lacunae. E
- 22 **Vascular lacuna.** Lacuna vasorum. Compartment between the pubis, inguinal ligament and iliopsoas arch for passage of the femoral artery and the femoral branch of the genitofemoral nerve. E
- 23 **Femoral triangle.** Trigonum femorale. Triangle between the sartorius and adductor longus muscles and the inguinal ligament. D
- 24 **Femoral canal.** Canalis femoralis. Passage within the medial segment of the vascular lacuna that extends from the inguinal ligament to the saphenous opening. E



A Superficial plantar muscles

B Deep plantar muscles

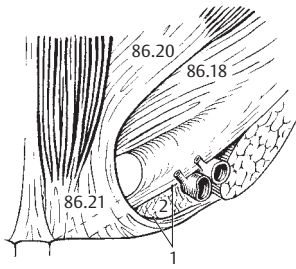
C Interosseous muscles



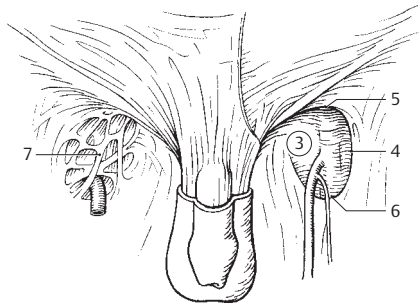
D Thigh, lateral and anterior medial view

E Vascular lacuna

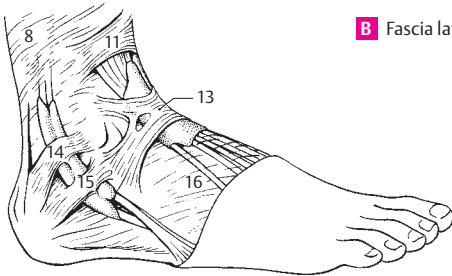
- 1 **Femoral ring.** Anulus femoralis. Entrance into the femoral canal bordered by the femoral vein, inguinal ligament, falx inguinalis and pectineal ligament. A
- 2 **Femoral septum.** Septum femorale. Fibrous membrane that closes the entrance of the femoral canal. A
- 3 **Saphenous opening.** Hiatus saphenus. Large opening in the fascia lata directly below the inguinal ligament for passage of the great saphenous vein. B
- 4 **Falciform margin.** Margo falciformis. Curved, principal lateral margin of the saphenous opening. B
- 5 **Superior horn.** Cornu superius. Upper, curved portion of the falciform margin. B
- 6 **Inferior horn.** Cornu inferius. Lower, curved portion of the falciform margin. B
- 7 **Cribriiform fascia.** Fascia cribrosa. Loose, perforated connective tissue lamina covering the saphenous opening. B
- 8 **Fascia of the leg (crural fascia).** Fascia cruris. Superficial investing fascia of the leg which serves partially for muscle attachment and is fused to the free bony margins of the tibia. C D F
- 9 **Anterior intermuscular septum of leg.** Septum intermusculare cruris anteriorius. Connective tissue septum between the peroneal and extensor compartments. F
- 10 **Posterior intermuscular septum of leg.** Septum intermusculare cruris posteriorius. Connective tissue septum between the peroneal and flexor compartments. F
- 11 **Superior extensor retinaculum.** Retinaculum mm. extensorum superius. Transverse thickened (about two finger's breadth) of the crural fascia that hold the extensor tendons in place. C D
- 12 **Flexor retinaculum.** Retinaculum mm. flexorum. Fibrous band on the long flexor tendons that extends from the medial malleolus to the calcaneus. It forms an osteofibrous compartment for the posterior tibial m., then divides into two parts. The lower portion forms compartments for the flexor digitorum longus and flexor hallucis longus muscles. The tibial nerve and posterior tibial artery and vein lie between the two membranous parts. D
- 13 **Inferior extensor retinaculum.** Retinaculum mm. extensorum inferius. Usually cruciate band that supports the extensor tendons, extending from both malleoli to the foot margins of the opposite side, primarily to the calcaneus. C D
- 14 **Superior peroneal (fibular) retinaculum.** Retinaculum mm. peroneorum (fibularium) superius. Upper band that holds peroneal tendons in place; it extends from the lateral malleolus to the calcaneus. C
- 15 **Inferior (fibular) peroneal retinaculum.** Retinaculum mm. peroneorum (fibularium) inferius. Lower band that holds the peroneal tendons in place. It passes from the extensor retinaculum to the outer surface of the calcaneus. A fibrous tract goes to the peroneal trochlea and separates the upper lying peroneus brevis from the peroneus longus muscle. C
- 16 **Fascia dorsalis pedis.** Thin fascia on the dorsum of the foot connected above with the inferior extensor retinaculum. C D
- 17 **Plantar aponeurosis.** Aponeurosis plantaris. Tough, tendinous sheet on the sole of the foot extending from the tuber calcanei to as far as the middle phalanges. It braces the longitudinal arch of the foot. E
- 18 **Transverse fasciculi.** Fasciculi transversi. Transverse fibrous sheets in the distal plantar aponeurosis. E
- 19 **Superficial transverse metatarsal ligament.** Lig. metatarsale transversum superficiale. Transverse fibrous tract in the vicinity of the distal transverse fibers of the plantar aponeurosis. E G
- 19a **Synovial bursae (sacs) and sheaths.** Bursae et vaginae synoviales.
- 20 **Synovial sheaths of the digits of the foot.** Vaginae synoviales tendinum digitorum pedis. Synovial portion of the tendon sheaths for the flexors of the toes. G
- 21 **Vincula tendinum.** Connective tissue tract passing obliquely through the tendon sheaths bearing blood vessels. G
- 22 **Fibrous sheaths of the digits of the foot.** Vaginae fibrosae tendinum digitorum pedis. Tough fibrous sheath that reinforces the tendon sheaths on the flexor side of the toes. G
- 23 **Annular part of fibrous sheath.** Pars annularis vaginae fibrosae. Circular tracts in the fibrous sheaths between the joints. G
- 24 **Cruciate part of fibrous sheath.** Pars cruciformis vaginae fibrosae. Cruciate connective tissue tracts in the fibrous sheaths over the joints. G



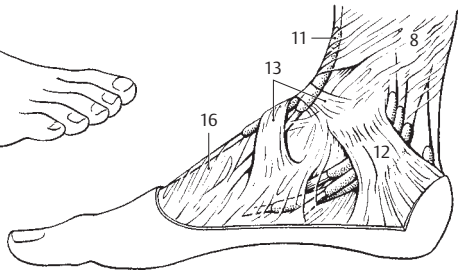
A Vascular lacuna from behind



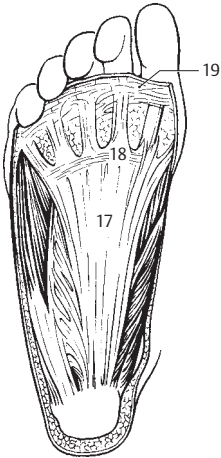
B Fascia lata in inguinal region



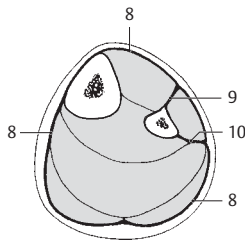
C Foot, lateral view



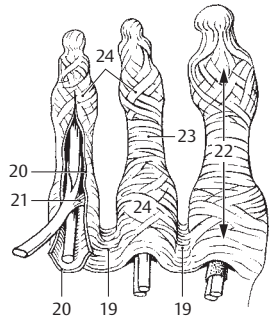
D Foot, medial view



E Plantar surface of foot

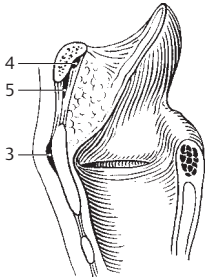


F Cross-section of lower leg

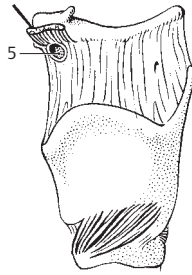


G Toes, plantar view

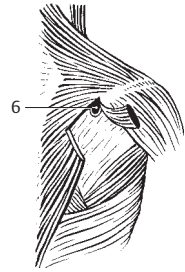
- 4
- 1 **Tendon sheath of superior oblique muscle.** Vagina tendinis m. obliqui superioris. Synovial sheath of the superior oblique m. of the eyeball, situated at the site where its tendon passes through the trochlea. See p. 364. 12
 - 2 **Synovial bursa of tensor veli palatini.** Bursa m. tensoris veli palatini. Synovial bursa between the pterygoid hamulus and the tendon of the tensor veli palatini muscle. See pp. 116.20, 117. C
 - 3 **Subcutaneous bursa of the laryngeal prominence.** B. subcutanea prominentiae laryngealis. Synovial bursa between the skin and the laryngeal prominence of the thyroid cartilage. A
 - 4 **Retrohyoid bursa.** B. retrohyoidea. Synovial bursa between the body of the hyoid bone and the median thyrohyoid ligament. A
 - 5 **Infrahyoid bursa.** B. infrahyoidea. Synovial bursa between the upper end of the sternohyoid muscle and the thyrohyoid membrane. A B
 - 5a **Synovial bursae of upper limb.** Bursae membri superiores.
 - 6 **Subtendinous bursa of trapezius.** B. subtendinea m. trapezii. Synovial bursa between the trapezius muscle (ascending part) and the spine of the scapula. C
 - 7 **[B. subcutanea acromialis].** Synovial bursa between acromion and the skin. D
 - 8 **Subacromial bursa.** B. subacromialis. Synovial bursa between the acromion, coracoacromial ligament and supraspinous tendon. It and its tendons lie on the joint capsule. D E
 - 9 **Subdeltoid bursa.** B. subdeltoidea. Synovial bursa between the deltoid muscle and the greater tubercle of the humerus. It often communicates with the subacromial bursa. D
 - 10 **Coracobrachial bursa.** [b. m. coracobrachialis]. Synovial bursa between the tendons of the subscapularis and coracobrachialis muscles below the apex of the coracoid process. D
 - 11 **Subtendinous bursa of infraspinatus muscle.** B. subtendinea m. infraspinati. Synovial bursa between the tendon of the infraspinatus and the capsule of the shoulder joint. E
 - 12 **Subtendinous bursa of subscapularis muscle.** B. subtendinea m. subscapularis. Synovial bursa between the tendon of the subscapularis and the capsule of the shoulder joint. It communicates with the joint cavity. D
 - 13 **Subtendinous bursa of teres major muscle.** B. subtendinea m. tertis majoris. Synovial bursa between the tendon of the teres major and the humerus. D
 - 14 **Subtendinous bursa of latissimus dorsi muscle.** B. subtendinea m. latissimi dorsi. Synovial bursa between the tendons of the teres major and latissimus dorsi. D
 - 15 **Subcutaneous bursa of olecranon.** B. subcutanea olecrani. Synovial bursa between the olecranon and the skin. F
 - 16 **Intratendinous bursa of olecranon.** [B. intratendinea olecrani]. Synovial bursa within the triceps tendon near the olecranon. F
 - 17 **Subtendinous bursa of triceps brachii.** B. subtendinea m. tricipitis brachii. Synovial bursa between the triceps tendon and the olecranon. F
 - 18 **Bicipitoradial bursa.** B. bicipitoradialis. Synovial bursa between the biceps tendon and the anterior part of the radial tuberosity. F
 - 19 **[B. cubitalis interossea].** Synovial bursa between the biceps tendon and the ulna or oblique cord. F
 - 20 **Tendon sheath of abductor pollicis longus and extensor pollicis brevis muscles.** Vag. tendinum mm. abductoris longi et extensoris brevis pollicis. Common tendon sheath forming the first tendon compartment on the dorsum of the hand. G
 - 21 **Tendon sheath of extensor carpi radialis longus and brevis muscles.** Vag. tendinum mm. extensorum carpi radialis. Common tendon sheath forming the second tendon compartment on the dorsum of the hand. G
 - 22 **Tendon sheath of extensor pollicis longus muscle.** Vag. tendinis m. extensoris pollicis longi. Forms the third tendon compartment. G
 - 23 **Tendon sheath of extensor digitorum and extensor indicis muscles.** Vag. tendinum mm. extensoris digitorum et extensoris indicis. Tendon sheath forming the fourth tendon compartment on the dorsum of the hand. G
 - 24 **Tendon sheath of extensor digiti minimi muscle.** Vag. tendinis m. extensoris digiti minimi. Forms the fifth tendon compartment on the dorsum of the hand. G
 - 25 **Tendon sheath of extensor carpi ulnaris muscle.** Vag. tendinis m. extensoris carpi ulnaris. Forms the sixth tendon compartment on the dorsum of the hand. G
 - 26 **Sheath of extensor carpi radialis brevis muscle.** Vag. m. extensoris carpi radialis brevis. Synovial bursa at the attachment between the tendon and base of the 3rd metacarpal.



A Sagittal section of larynx

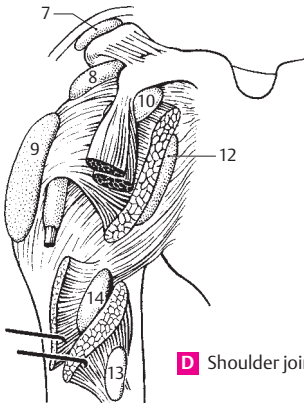


B Larynx, lateral view

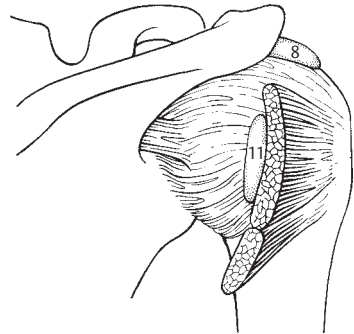


C Right shoulder, posterior view

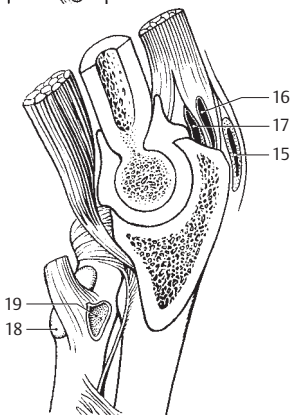
4



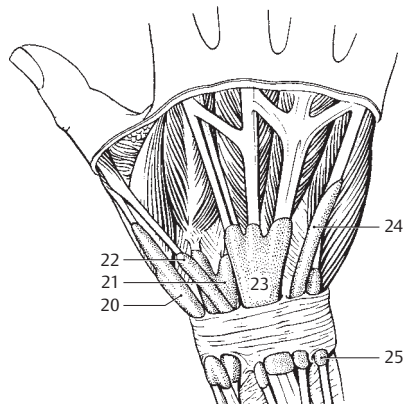
D Shoulder joint, anterior view



E Shoulder joint, posterior view

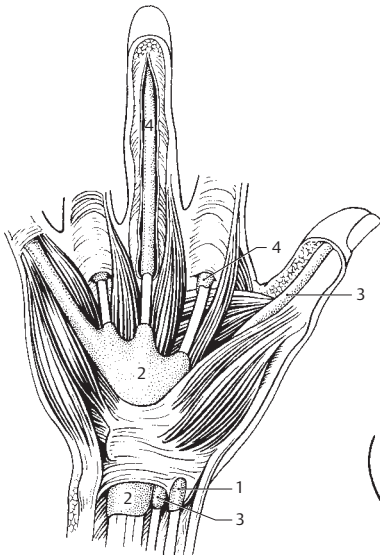


F Section of elbow joint sawed open

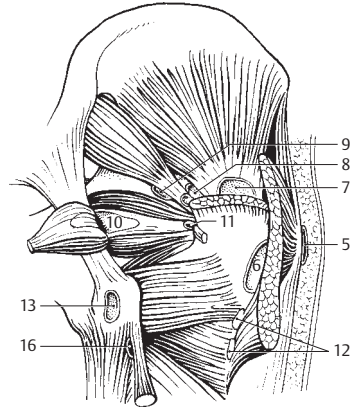


G Wrist and hand, dorsal view

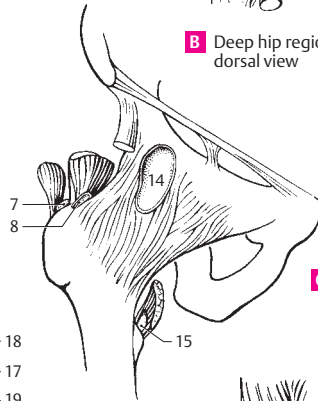
- 1 **Tendon sheath of flexor carpi radialis muscle.** Vag. tendinis m. flexoris carpi radialis. Individual tendon sheath for the flexor carpi radialis at the insertion of the tendon to the base of the 2nd metacarpal bone. A
- 2 **Common sheath of flexor muscles.** Vag. communis mm. flexorum. Common tendon sheath for the two long flexors of the fingers. A
- 3 **Tendon sheath of flexor pollicis longus muscle.** Vag. tendinis m. flexoris pollicis longi. Separate synovial sheath for the long flexor of the thumb. A
- 4 **Tendon sheaths for flexors in region of fingers.** Vag. tendinum digitorum manus. A
- 4a **Synovial bursae of lower limb.** Bursae membri inferioris.
- 5 **Subcutaneous trochanteric bursa.** Bursa subcutanea trochanterica. Synovial bursa on the tendon of the gluteus maximus between the skin and greater trochanter. B
- 6 **Trochanteric bursa of gluteus maximus.** B. trochanterica m. glutei maximi. Synovial bursa between the tendon of the gluteus maximus and the greater trochanter. B
- 7 **Trochanteric bursae of gluteus medius.** Bb. trochantericae m. glutei medii. This designation comprises two synovial bursae, an anterior one between the tendon of insertion of the gluteus medius and the greater trochanter and a posterior one between this tendon and the piriformis muscle. B C
- 8 **Trochanteric bursa of gluteus minimus.** B. trochantericae m. glutei minimi. Synovial bursa between the tendon of insertion of the gluteus minimus and the greater trochanter. B C
- 9 **Bursa of piriformis muscle.** B. m. piriformis. Synovial bursa between the piriformis tendon, femur and superior gemellus muscle. B
- 10 **Ischial bursa of obturator internus muscle.** B. ischiadica (sciatica) m. obturatoris interni. Synovial bursa between the cartilage-covered surface of the lesser sciatic notch and the tendon of the obturator internus. B
- 11 **Subtendinous bursa of obturator internus muscle.** B. subtendinea m. obturatoris interni. Synovial bursa below the insertion of the obturator internus. B
- 12 **Intermuscular bursae of gluteal muscles.** Bb. intermusculares mm. gluteorum. 2–3 synovial bursae that extend inferiorly from the gluteus maximus to the linea aspera. B
- 13 **Ischial bursa of gluteus maximus muscle.** B. ischiadica (sciatica) m. glutei maximi. Synovial bursa between the ischial tuberosity and the inferior surface of the gluteus maximus. B
- 14 **Iliopectineal bursa.** [B. iliopectinea]. Synovial bursa between the iliopsoas muscle and the pelvic bone. It lies above and often communicates with the hip joint. C
- 15 **Subtendinous iliac bursa.** B. subtendinea iliaca. Synovial bursa between the lesser trochanter and the iliopsoas tendon. C
- 16 **Superior bursa of biceps femoris muscle.** B. m. bicipitis femoris superior. Synovial bursa between the origins of the biceps femoris and semimembranosus muscles. B
- 17 **Subcutaneous prepatellar bursa.** B. subcutanea prepatellaris. Synovial bursa directly between the skin and the fascia in front of the knee. D
- 18 **Subfascial prepatellar bursa.** [B. subfascialis prepatellaris]. Synovial bursa between the investing fascia of the knee and the tendon of the quadratus femoris muscle. D
- 19 **Subtendinous prepatellar bursa.** [B. subtendinea prepatellaris]. Synovial bursa directly on the knee joint below the tendon of the quadratus femoris. D
- 20 **Suprapatellar bursa.** B. suprapatellaris. Synovial bursa between the quadriceps tendon and the femur. It almost always communicates with the joint cavity. D
- 21 **Subcutaneous infrapatellar bursa.** B. subcutanea infrapatellaris. Synovial bursa between the ligamentum patellae and the skin. D
- 22 **Deep infrapatellar bursa.** B. infrapatellaris profunda. Synovial bursa between the ligamentum patellae and the tibia. D
- 23 **Subcutaneous bursa of tibial tuberosity.** B. subcutanea tuberositas tibiae. Synovial bursa between the tibial tuberosity and the skin. It is mostly involved in kneeling. D
- 24 **Subtendinous bursae of sartorius muscle.** Bb. subtendineae m. sartorii. Synovial bursae between the sartorius tendon and the tendons of the gracilis and semitendinosus situated below it. E



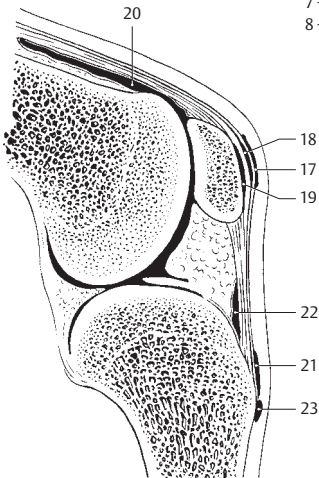
A Palmar view of hand



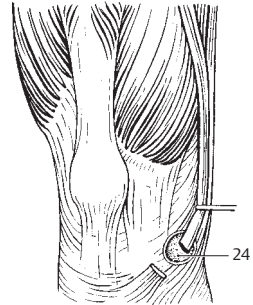
B Deep hip region, dorsal view



C Hip joint, anterior view

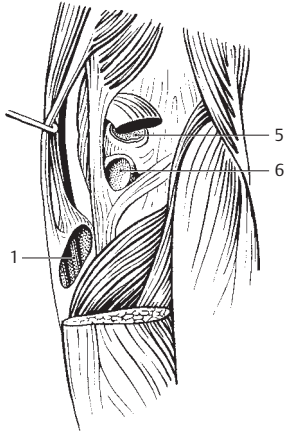


D Knee, sagittal section sawed open

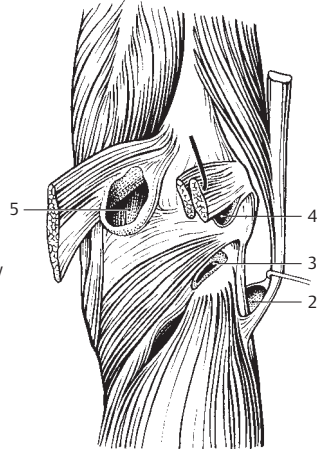


E Knee, anterior view

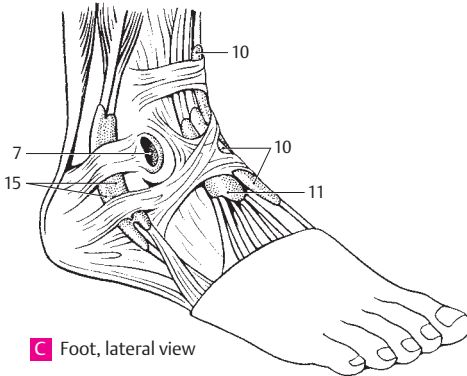
- 1 **Anserine bursa.** B. anserina. Synovial bursa on the tibial collateral ligament below the tendons of the semitendinosus, gracilis and sartorius muscles. It occasionally communicates with the subtendinous bursa of the sartorius. A
- 2 **Inferior subtendinous bursa of biceps femoris muscle.** B. subtendinea m. bicipitis femoris inferior. Synovial bursa located partially on the fibular collateral ligament below the tendon of insertion of the biceps femoris. B
- 3 **Subpopliteal recess.** Recessus subpopliteus [bursa m. poplitei]. Synovial bursa on the lateral femoral condyle below the tendon of origin of the popliteal muscle. It always communicates with the knee joint cavity, more rarely with the tibiofibular joint. B
- 4 **Lateral subtendinous bursa of gastrocnemius muscle.** B. subtendinea m. gastrocnemii lateralis. Synovial bursa between the lateral condyle of the femur and the lateral gastrocnemius tendon. B
- 5 **Medial subtendinous bursa of gastrocnemius muscle.** B. subtendinea m. gastrocnemii medialis. Synovial bursa between the medial condyle of the femur and the medial gastrocnemius tendon. A B
- 6 **Bursa of semimembranosus muscle.** B. m. semimembranosi. Synovial bursa between the semimembranosus tendon and the upper margin of the tibia. A
- 7 **Subcutaneous bursa of lateral malleolus.** B. subcutanea malleoli lateralis. Synovial bursa between the skin and the lateral malleolus. C
- 8 **Subcutaneous bursa of medial malleolus.** B. subcutanea malleoli medialis. Synovial bursa between the skin and the medial malleolus. D
- 9 **Tendon sheath of tibialis anterior muscle.** Vag. tendinis m. tibialis anterioris. It begins just below the extensor retinaculum. D
- 10 **Tendon sheath of extensor hallucis longus muscle.** Vag. tendinis m. extensoris hallucis longi. Sheath extending below the extensor retinaculum and further distal. C D
- 11 **Tendon sheath of extensor digitorum longus muscle.** Vag. tendinum m. extensoris digitorum pedis longi. Sheath extending below the extensor retinaculum and further distal. C
- 12 **Tendon sheath of flexor digitorum longus muscle.** Vag. tendinum m. flexoris digitorum pedis longi. It lies behind and below the medial malleolus covered by the flexor retinaculum. D
- 13 **Tendon sheath of tibialis posterior muscle.** Vag. tendinis m. tibialis posterioris. It resides below the flexor retinaculum and begins at the point where it is crossed over by the flexor digitorum longus. D
- 14 **Tendon sheath of flexor hallucis longus muscle.** Vag. tendinis m. flexoris hallucis longi. It extends up to the proximal end of the sole, where it crosses under the tendon of the flexor digitorum longus. D
- 15 **Common tendon sheath for peroneal muscles.** Vag. tendinum mm. peroneorum (fibularium) communis. It lies below the peroneal retinaculum and extends to the cuboid bone. C
- 16 **Subtendinous bursa of tibialis anterior muscle.** B. subtendinea m. tibialis anterioris. Synovial bursa between the tibialis anterior tendon and the medial cuneiform bone. D
- 17 **Subcutaneous calcaneal bursa.** B. subcutanea calcanea. Synovial bursa between the skin and the posterior surface of the calcaneus. D
- 18 **Bursa of calcaneal [[Achilles]] tendon.** B. tendinis calcanei [Achilles]. Synovial bursa between the calcaneus and the Achilles tendon. D
- 19 **Tendon sheath of peroneus longus muscle at the sole of the foot.** Vag. tendinis m. peronei (fibularis) longi plantaris. D
- 20 **Tendon sheaths for the flexors of the toes.** Vagg. tendinum digitorum pedis. D



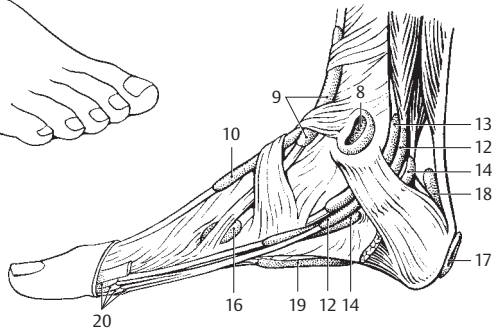
A Right knee joint, posterior view



B Right knee joint, posterior view

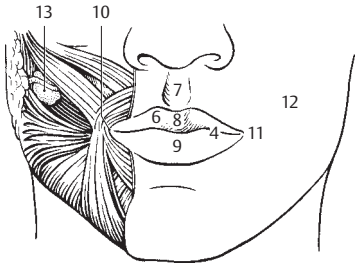


C Foot, lateral view

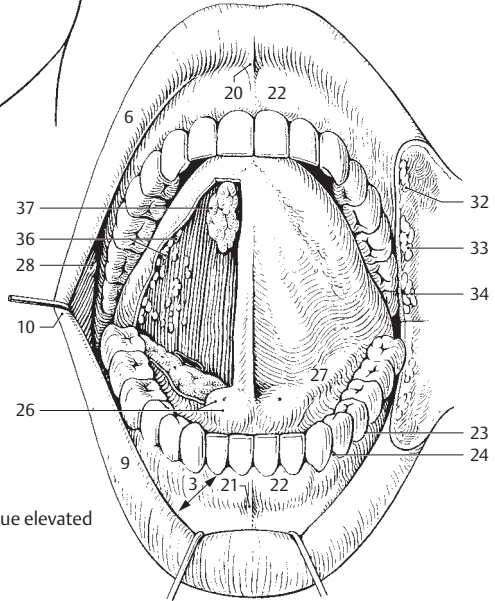


D Foot, medial view

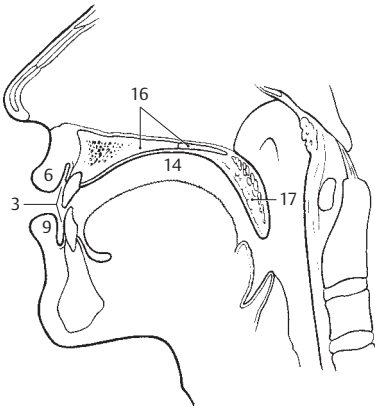
- 1 **DIGESTIVE SYSTEM.** Apparatus digestorius (systema alimentarium).
- 2 **ORAL CAVITY.** Cavitas oris.
- 3 **Vestibule of mouth.** Vestibulum oris. Space between the rows of teeth and the lips or cheeks. B C
- 4 **Oral fissure.** Rima oris. Mouth opening between the lips. A
- 5 **Lips.** Labia oris.
- 6 **Upper lip.** Labium superius. A B C
- 7 **Philtrum.** Groove extending from nasal septum to upper lip. A
- 8 **Tuberculum.** Small eminence on upper lip marking end of philtrum. A
- 9 **Lower lip.** Labium inferius. A B C
- 10 **Commissure of lips.** Commissura labiorum. Transition of upper lip into lower lip at the angle of the mouth. A B
- 11 **Angle of mouth.** Angulus oris. A
- 12 **Cheek.** Bucca. Lateral wall of vestibule of mouth. A
- 13 **Buccal fat pad.** Corpus adiposum buccae. [[Bichat]]. Encapsulated body of fat between the buccinator and masseter muscles. A
- 14 **Oral cavity proper.** Cavitas oris propria. True oral cavity enclosed anteriorly and laterally by the teeth and extending as far as the isthmus of fauces (oropharyngeal isthmus). C
- 15 **Palate.** Palatum. Partition between oral and nasal cavities.
- 16 **Hard palate.** Palatum durum. Hard, bony part of the palate. C D
- 17 **Soft palate.** Palatum molle (velum palatinum). Soft, posterior part of the palate. C D
- 18 **Palatine raphe.** Raphe palati. Median mucosal ridge at the junction of the right and left bony palatal processes. D
- 19 **Oral mucosa.** Tunica mucosa oris. Mucous membrane of oral cavity consisting of stratified, nonkeratinized squamous epithelium throughout and underlying mixed glands.
- 20 **Frenulum of upper lip.** Frenulum labii superioris. Median mucosal fold between the gums and upper lip. B
- 21 **Frenulum of lower lip.** Frenulum labii inferioris. Median mucosal fold between the gums and lower lip. B
- 22 **Gums.** Gingivae. Mucous membrane united firmly with the teeth and jaw bones. B D
- 23 **Gingival (gum) margin.** Margo gingivalis. B D
- 24 **Gingival (interdental) papilla.** Papilla gingivalis (interdentalis). B D
- 25 **Gingival sulcus.** Sulcus gingivalis. Shallow furrow between the gum margin and the tooth. Its deepening leads to cavity formation. See p. 113. A
- 26 **Sublingual papilla.** Caruncula sublingualis. A small mucosal eminence on either side of the frenulum. It receives the opening of the submandibular duct and the major sublingual duct. B
- 27 **Sublingual fold.** Plica sublingualis. Mucosal fold overlying the sublingual gland and extending posterolaterally from the sublingual papilla. B
- 28 **Parotid papilla.** Papilla ductus parotidei. Small mucosal elevation at the opening of the parotid duct lateral to the second upper molar tooth. B
- 29 **Transverse palatine folds.** Plicae palatinae transversae. Mucosal folds running transversely on the anterior part of the hard palate. D
- 30 **Incisive papilla.** Papilla incisiva. Small mucosal elevation over the incisive foramen at the anterior end of the palatine raphe. D
- 30a **GLANDULAE ORIS.** The glands of the mouth.
- 31 **Small glands of the oral cavity.** Glandulae salivariae minores.
- 32 **Labial glands.** Gll. labiales. Small salivary glands at the inner aspect of the lips. B
- 33 **Buccal glands.** Gll. buccales. Small mucous salivary glands at the inner aspect of the cheeks. B
- 34 **Molar glands.** Gll. molares. Salivary glands corresponding to the buccal glands situated beneath the mucosal at the level of the molar teeth. B
- 35 **Palatine glands.** Gll. palatinae. Salivary glands situated beneath the mucosa of the palate. (Two large groups right and left of the midline.) D
- 36 **Lingual glands.** Gll. linguales. Numerous mucous, serous and mixed glands primarily in the lateral and posterior areas of the tongue. B
- 37 **Anterior lingual glands.** Gl. lingualis anterior [[gl. apicis linguae, Nuhn's glands]]. Mixed glands near the apex of the tongue providing several drainage ducts on the undersurface of the tongue. B



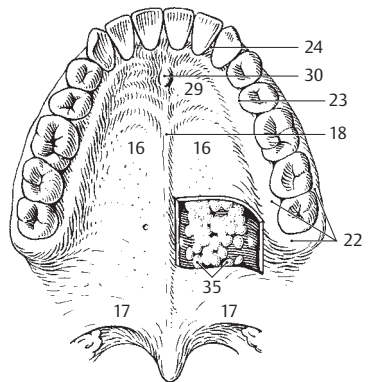
A Face, anterior view



B Mouth with tongue elevated

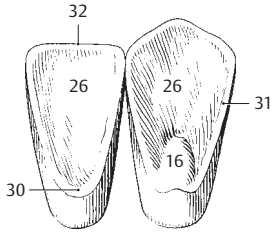


C Sagittal section of oral cavity

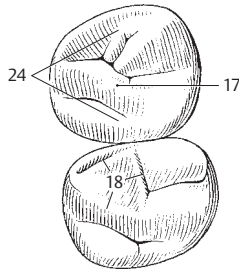


D Palate, inferior view

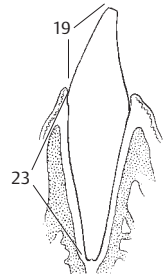
- 1 **Major salivary glands.** Glandulae salivariae majores.
- 2 **Sublingual gland.** Glandula sublingualis. Predominantly mucous gland situated on the mylohyoid muscle diaphragma oris. It contains several drainage ducts. D
- 3 **Major sublingual duct.** Ductus sublingulis major. Main drainage duct of the sublingual gland. It opens at the sublingual caruncle next to the submandibular duct. D
- 4 **Minor sublingual ducts.** Ductus sublinguales minores. About 40 small ducts that drain the sublingual gland and open along the sublingual fold and the sublingual caruncle. D
- 5 **Submandibular gland.** Glandula submandibularis. Predominantly serous salivary gland located almost entirely below the mylohyoid. D F
- 6 **Submandibular duct.** Ductus submandibularis. Duct that drains the submandibular gland. It loops around the posterior margin of the mylohyoid accompanied by glandular tissue and opens at the sublingual caruncle. D
- 7 **Parotid gland.** Glandula parotidea. Salivary gland located behind and on the mandibular ramus. F
- 8 **Superficial part.** Pars superficialis. The parts of the parotid gland located superficial to the facial nerve. F
- 9 **Deep part.** Pars profunda. Parts of the parotid gland located deep with respect to the facial nerve. F
- 10 **Accessory parotid gland.** Glandula parotidea accessoria. Portion of the parotid gland located on the masseter muscle near the parotid excretory duct. F
- 11 **Parotid duct.** Ductus parotideus. Excretory duct of the parotid gland. It passes around the anterior margin of the masseter and opens near the second upper molar tooth. F
- 12 **TEETH.** Dentes. A B C D E G
- 13 **Crown of tooth.** Corona dentis. Portion of the tooth covered by enamel. E
- 14 **Cusp of tooth.** Cuspis dentis [[tuberculum]]. 1–5 protuberances on the occlusal surface of tooth (with the exception of the incisors). E
- 15 **Apex of cusp.** Apex cuspidis. E
- 16 **Dental tubercle.** Tuberculum dentis. Distinct eminence on the side of the crown, especially in canine and incisor teeth. A
- 17 **Transverse ridge.** Crista transversalis. Transverse connecting ridge between adjacent cusps. B
- 18 **Triangular ridge.** Crista triangularis. Triangular connecting ridge between the cusps of the molars. B
- 19 **Clinical crown.** Corona clinica. Portion of the tooth projecting above the gum. C
- 20 **Neck of tooth.** Cervix [[collum]] dentis. Portion of the tooth at the enamel-cementum border. E
- 21 **Root of tooth.** Radix dentis. Portion of the tooth covered by cementum. E
- 22 **Apex of root of tooth.** Apex radices dentis. E
- 23 **Clinical root.** Radix clinica. Portion of the tooth situated below the gum. C
- 24 **Occlusal (masticatory) surface.** Facies occlusalis (masticatoria) dentis. B E
- 25 **Vestibular (facial) surface.** Facies vestibularis (facilis) dentis. Tooth surface facing the vestibule. D G
- 25a **Buccal surface.** Facies buccalis dentis. Tooth surface facing the cheek.
- 25b **Labial surface.** Facies labialis dentis. Tooth surface facing the lips.
- 26 **Lingual and palatine surfaces.** Facies lingualis/palatalis dentis. Tooth surfaces facing the tongue and palate, respectively. A G
- 27 **Approximal surface.** Facies approximalis. Tooth surface facing the adjacent tooth. G
- 28 **Mesial surface.** Facies mesialis. Vertical contact surface of a tooth turned away from the last molar. G
- 29 **Distal surface.** Facies distalis. Vertical contact surface of a tooth facing away from the first incisor. G
- 29a **Contingent area.** Area contingens. Direct contact surface of adjacent teeth.
- 30 **Cingulum.** Ridge near the neck of a tooth connecting both marginal crests at the lingual surface of incisor and canine teeth. A
- 31 **Marginal crest.** Crista marginalis. Lateral marginal ridge on the lingual surface of the incisor and canine teeth which goes over into the cingulum at the neck region. A
- 32 **Incisal margin.** Margo incisalis. Occlusal edge of incisor and canine teeth. A



A Incisor tooth and canine tooth, lingual surface

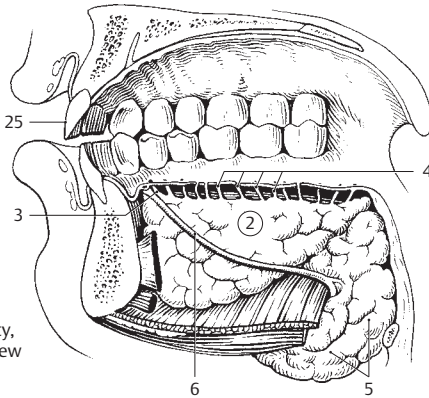


B First and second molars, occlusal surface

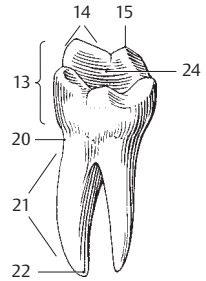


C Incisor, sagittal section

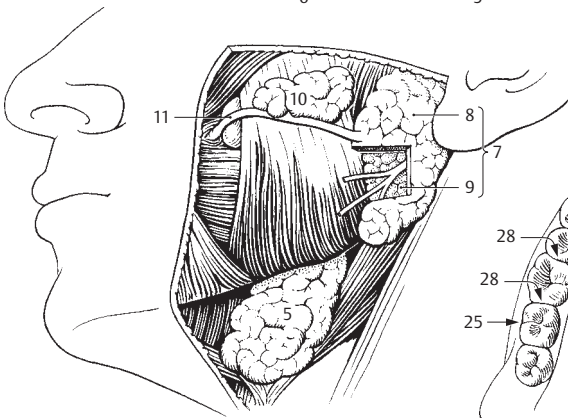
5



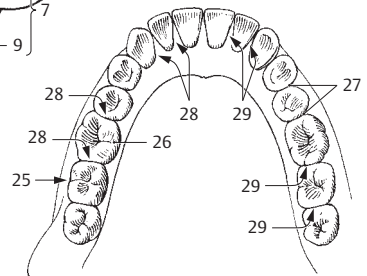
D Oral cavity, medial view



E First lower molar

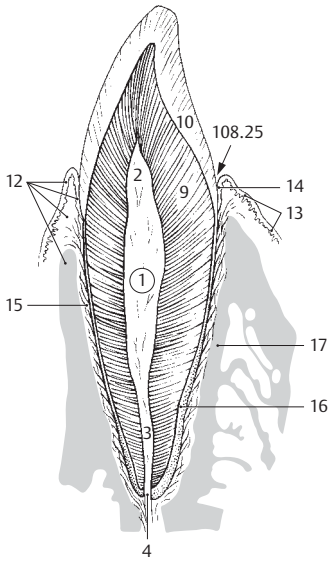


F Salivary glands, lateral view

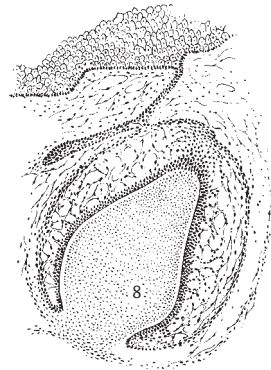


G Teeth of lower jaw

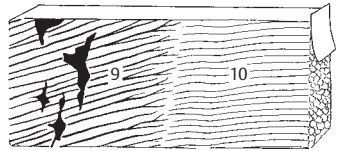
- 1 **Pulp cavity of tooth.** Cavitas dentis (pularis). Cavity in the dentin. Towards the root, it becomes continuous with the root canal. A
- 2 **Pulp chamber in the crown.** Cavitas coronae. Crown portion of the pulp cavity. A
- 3 **Root canal of tooth.** Canalis radialis dentis. Canal between the pulp cavity and the apical foramen. A
- 4 **Apical foramen of root of tooth.** Foramen apicis radialis dentalis. The opening of the root canal at the apex of the root. A
- 5 **Pulp of tooth.** Pulpa dentis. Contents of the pulp cavity consisting of loose, finely fibered connective tissue, blood vessels and nerves.
- 6 **Crown pulp.** Pulpa coronalis. Pulp within the crown portion of the pulp cavity.
- 7 **Root pulp.** Pulpa radialis. Pulp within the root canal portion of the pulp cavity.
- 8 **Dental papilla.** Papilla dentis. A mass of mesenchyme present in the bell stage of tooth development. B
- 9 **Dentine.** Dentinum [[substantia eburnea]]. Predominant mass of a tooth consisting of inorganic and organic material (especially collagenous fibers). A C
- 10 **Enamel.** Enamelum [[substantia adamantina]]. The extremely hard substance surrounding the crown of the tooth like a mantle. A C
- 11 **GOMPHOSIS.** Type of fibrous joint in which a conical process, e.g., a tooth, is inserted into a socket, e.g., alveolus of the jaw (dentoalveolar articulation).
- 12 **Periodontium.** Tissues that invest and support the tooth within the alveolus. It consists of the following parts: A
- 13 **Periodontium protectoris [[gingiva]].** The outer part of the periodontium with the external border epithelium. A
- 14 **Periodontium insertionis.** Portion of the periodontium touching the tooth. It consists of the inner border epithelium and the periodontal ligament. A
- 15 **Periodontal ligament.** Desmodontium. All connective tissue fibers which are anchored in the cementum and, with their vessels and nerves, extend partly into the gum and partly into the alveolar wall. A
- 16 **Cementum.** Substance similar to bone. It surrounds the tooth from the enamel border to the apex of the root and receives the fibers of the periodontal ligament. A
- 17 **Alveolar bone.** Os alveolare. Bony wall of the alveolus. A
- 18 **Superior dental arch.** Arcus dentalis superior. Curved row of teeth of the maxilla.
- 19 **Inferior dental arch.** Arcus dentalis inferior. Curved row of teeth of the mandible.
- 20 **Incisor teeth.** Dentes incisivi. Cutting teeth located on both sides of the midline at the 1st and 2nd positions of the dental arch. D
- 21 **Canine teeth.** Dentes canini. Teeth located at the 3rd position of the dental arch. D
- 22 **Premolar teeth.** Dentes premolares. Teeth occupying the 4th and 5th positions of the dental arch. D
- 23 **Molar teeth.** Dentes molares. Teeth located at the 6th, 7th and 8th positions of the dental arch. D
- 24 **Wisdom tooth.** Dens serotinus [molaris tertius]. Tooth located at the 8th position of the dental arch. D
- 25 **Deciduous (milk) teeth.** Dentes decidui.
- 26 **Permanent teeth.** Dentes permanentes. Teeth that develop after the deciduous teeth.
- 27 **Diastema.** Space between adjacent teeth.
- 28 **TONGUE.** Lingua. D E
- 29 **Body of tongue.** Corpus linguae. Portion of the tongue situated between the apex and root. E
- 30 **Root of tongue.** Radix linguae. Anchoring region of the tongue at the mandible and hyoid bone. Also the posterior, vertical segment of the tongue. E
- 31 **Dorsum of tongue.** Dorsum linguae. E
- 32 **Anterior, oral portion of tongue.** Pars presulcalis (anterior). The part of the dorsum of the tongue situated anterior to the sulcus terminalis. 115 B
- 33 **Posterior, pharyngeal part of tongue.** Pars postsulcalis (posterior). The vertical portion of the dorsum of the tongue between the sulcus terminalis and the epiglottis. 115 B
- 34 **Inferior surface of tongue.** Facies inferior linguae. D E
- 35 **Fimbriated fold.** Plica fimbriata. Serrated fold lateral to the frenulum. It is a remnant of the inferior tongue. D
- 36 **Lateral margin of tongue bordering the teeth.** Margo linguae. D
- 37 **Apex of tongue.** Apex linguae. D E



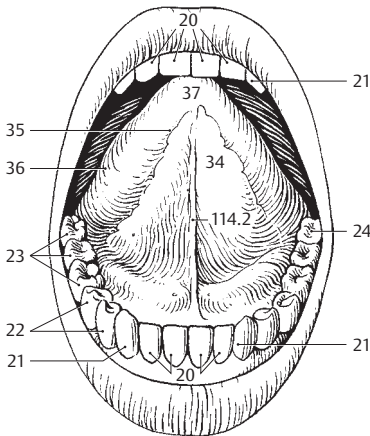
A Longitudinal section of tooth



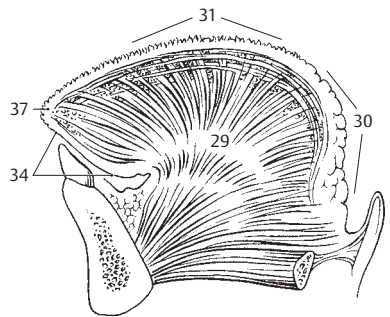
B Tooth development



C Enamel-dentin border

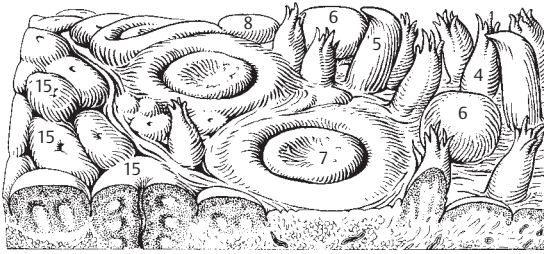


D Mouth with tongue elevated

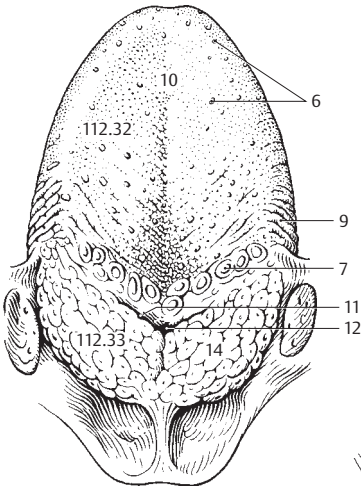


E Tongue, sagittal section

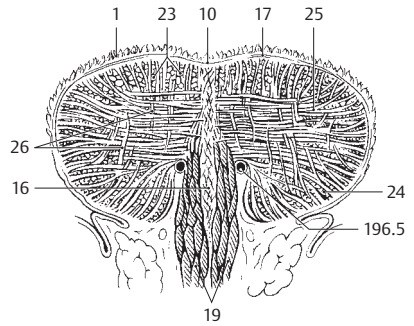
- 1 **Mucous membrane of tongue.** Tunica mucosa linguae. C
- 2 **Frenulum of tongue.** Frenulum linguae. Mucosal fold extending from the floor of the mouth to the inferior side of the tongue. D; see also p. 113. D
- 3 **Lingual papillae.** Papillae linguales. Collective term for the following five different types of mucosal formations: A B
- 4 **Filiform papillae.** Papillae filiformes. Fine, almost threadlike epithelial elevations on a connective tissue core. Their tips that are often cleft. A
- 5 **Conical papillae.** Papillae conicae. Special form of filiform papilla. They are somewhat larger, longer and exhibit conical apices which bend backwards. A
- 6 **Fungiform papillae.** Papillae fungiformes. Mushroom-like papillae which are not pointed at the tip, but terminate with a small plateau. A B
- 7 **Vallate (circumvallate) papillae.** Papillae vallatae. 7–12 large papillae located in front of the sulcus terminalis. They are circular in cross-section and are surrounded by a moat, the wall of which contains taste buds. A B
- 8 **Lenticular papillae.** Papilla lentiformes. Short fungiform papillae. A
- 9 **Foliate papilla.** Papillae foliatae. Several parallel folds containing taste buds at the posterolateral margin of the tongue. B D
- 10 **Median groove of tongue.** Sulcus medianus linguae. Shallow, median longitudinal groove situated above the lingual septum. B C
- 11 **Sulcus terminalis [“V” linguae].** Bilateral groove passing obliquely forward from the foramen caecum. It lies behind the row of vallate papillae which run parallel to it. B
- 12 **Foramen caecum linguae.** Pit situated at the apex of the sulcus terminalis. It is the embryological remains of the thyroglossal duct. B
- 13 **Thyroglossal duct.** Ductus thyroglossalis. Embryological connection between thyroid gland and tongue. At the site of the future foramen caecum, it extends downward from the base of the tongue as an epithelial cone.
- 14 **Lingual tonsil.** Tonsilla lingualis. Accumulation of lymphatic tissue (lingual follicles) which is irregularly distributed over the root of the tongue. B D
- 15 **Lingual follicles.** Folliculi linguales. Dome-shaped protrusions of the mucosa, 1–5 mm in diameter, caused by masses of lymphatic tissue beneath them. Each has a central crypt. A
- 16 **Lingual septum.** Septum lingualis. Connective tissue plate with a special fibrous architecture located in the midsagittal plane. C
- 17 **Lingual aponeurosis.** Aponeurosis lingualis. Stout connective tissue framework of the tongue between the muscles and the mucosa. C
- 18 **TONGUE MUSCULATURE.** Musculi linguae (linguales). The following eight tongue muscles are innervated by the hypoglossal nerve (XII).
- 19 **M. genioglossus.** o: Mental spine of mandible. i: Fan-shaped distribution within the tongue from the apex to the base. A: It pulls the tongue forward or towards the chin. I: Hypoglossal nerve. C D
- 20 **M. hyoglossus.** o: Body and greater horn of hyoid bone. i: Coming from below, it radiates into the lateral parts of the tongue and penetrates up to the mucosa. A: It draws the base of the tongue backward and downward. I: Hypoglossal nerve. D
- 21 **M. chondroglossus.** o: Lesser horn of hyoid. i: Same as hyoglossus. I: Hypoglossal nerve. D
- 22 **M. styloglossus.** o: Styloid process. i: Coming from behind and above, it radiates to the lateral parts of the tongue and interweaves with the hyoglossus. A: It draws the tongue backward and upward. I: Hypoglossal nerve. D
- 23 **Superior longitudinal muscle of tongue.** M. longitudinalis superior. Longitudinal bundles of muscle just below the mucosa that extend from the apex of tongue to the region of the hyoid bone. I: Hypoglossal nerve. C
- 24 **Inferior longitudinal muscle of tongue.** M. longitudinalis inferior. Longitudinal fibrous system situated close to the inferior surface of the tongue. It passes from the base to the apex of the tongue. I: Hypoglossal nerve. C
- 25 **Transverse muscle of tongue.** M. transversus linguae. Transversely oriented muscle fibers extending between the longitudinal system of fibers. o: Lingual septum. i: Mucous membrane along lateral margins of tongue. A: Extension of tongue together with the vertical muscle of the tongue. I: Hypoglossal nerve. C
- 26 **Vertical muscle of tongue.** M. verticalis linguae. Vertical muscle fibers coursing from the back of the tongue to the inferior surface. I: Hypoglossal nerve. C



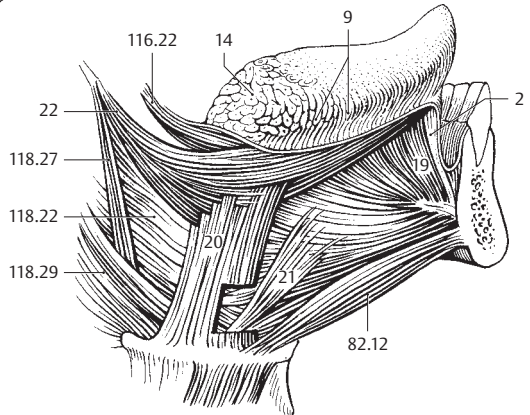
A Surface of tongue, enlarged



B Dorsum of tongue, overview

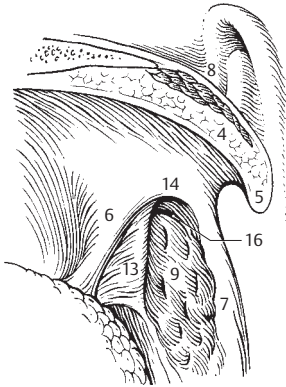


C Cross-section of tongue

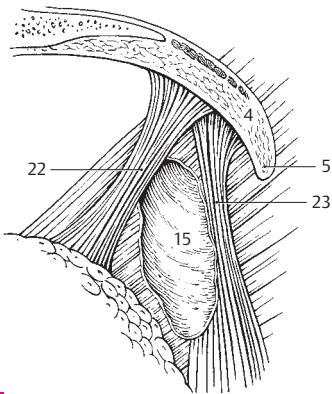


D Tongue muscles

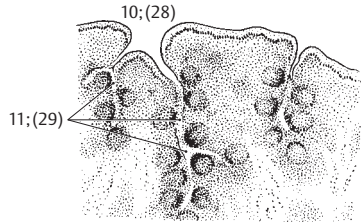
- 1 **Pharynx.** Passageway for air and food. 14–16 cm long, it extends from the fornix to the beginning of the esophagus in front of the 6th cervical vertebra. E
- 2 **FAUCES.** Space between soft palate and base of tongue. E
- 3 **Isthmus of fauces.** Isthmus faucium. Space between right and left palatoglossal and palatopharyngeal arches.
- 4 **Soft palate.** Palatum molle (velum palatinum). The dorsal portion projects downward in front of the posterior pharyngeal wall and assists in swallowing by closing off like a valve the nasopharyngeal space from the oral cavity. A D E
- 5 **Uvula.** Uvula palatina. Conical process projecting downward from the posterior margin of the soft palate. A D E
- 6 **Palatoglossal arch.** Arcus palatoglossus. Mucosal fold overlying the palatoglossal muscle and extending from the palate to the tongue in front of the tonsillar fossa. A
- 7 **Palatopharyngeal arch.** Arcus palatopharyngeus. Mucosal fold overlying the palatopharyngeal muscle and extending between the palate and pharyngeal wall behind the tonsillar fossa. A
- 8 **Salpingopalatine fold.** Plica salpingopalatina [[plica palatotubalis]]. Fold extending from the anterior lip of the auditory tube to the soft palate in front of the tubal elevation. A
- 9 **Palatine tonsil.** Tonsilla palatina. Tonsil situated between the palatoglossal and palatopharyngeal arches. A
- 10 **Tonsillar pits.** Fossulae tonsillae. Pit-like openings of the tonsillar crypts visible on the surface. B
- 11 **Tonsillar crypts.** Cryptae tonsillares. Epithelial invaginations extending into the tonsil from the tonsillar pits. B
- 12 **Capsule of tonsil.** Capsula tonsillaris. Fibrous capsule covering the organ.
- 13 **Triangular fold.** Plica triangularis. Triangular fold emanating from the palatoglossal arch in front of the tonsil. A
- 14 **Semilunar fold.** Plica semilunaris. Arched fold between the palatoglossal and palatopharyngeal arches. It forms the upper boundary of the tonsillar fossa. A
- 15 **Tonsillar fossa.** Fossa tonsillaris. Recess for the tonsil bordered by the palatoglossal and palatopharyngeal arches as well as by the triangular and semilunar folds. D
- 16 **Supratonsillar fossa.** Fossa supratonsillaris. Superior portion of tonsillar fossa not occupied by the tonsil. A
- 17 **Muscles of palate and fauces.** Musculi palati et faucium.
- 18 **Palatine aponeurosis.** Aponeurosis palatina. It is formed primarily by the tendon of the tensor veli palatini muscle. C
- 19 **M. levator veli palatini.** o: Petrous portion of temporal bone in front of the lower opening of the carotid canal. i: Palatine aponeurosis. It passes through the pharyngeal wall above the superior constrictor muscle and moves the soft palate backward and upward, thereby taking along the dorsomedial part of the auditory tube cartilage below the pharyngeal opening of the auditory tube. I: Vagus (X) nerve. C
- 20 **M. tensor veli palatini.** o: Spine of sphenoid, scaphoid fossa and anterior (lateral) lip of cartilaginous auditory tube. i: After looping around the pterygoid hamulus, it radiates into the palatine aponeurosis, stiffens the anterior (lateral) membranous wall of the auditory tube and tenses the soft palate. I: Mandibular nerve. C
- 21 **M. uvulae.** o: Palatine aponeurosis. i: Connective tissue of uvulae. I: Vagus nerve. C
- 22 **M. palatoglossus.** o: Transversus linguae muscle. i: Palatine aponeurosis. A: Elevates the base of the tongue, depresses the palate and narrows the isthmus of fauces. I: Vagus nerve. D
- 23 **M. palatopharyngeus [[m. pharyngopalatinus]].** o: Palatine aponeurosis, pterygoid hamulus and medial plate of pterygoid process. i: Lateral wall of pharynx and thyroid cartilage. A: It lowers the palate and constricts the isthmus of fauces. I: Vagus nerve. D
- 24 **PHARYNGEAL CAVITY.** Cavitas pharyngis. Space enclosed by the pharyngeal walls.
- 25 **Pharyngeal fornix.** Fornix pharyngis. Roof of the pharyngeal cavity beneath the sphenoid bone. E
- 26 **Nasopharynx.** Pars nasalis pharyngis. The portion of the pharyngeal cavity located behind the choanae. E
- 27 **Nasopharyngeal tonsil (adenoids).** Tonsilla pharyngealis (adenoidea). It lies at the pharyngeal fornix. E
- 28 **Tonsillar pits.** Fossulae tonsillares. Openings of crypts visible on surface of tonsil. See also p. 116.10. B
- 29 **Tonsillar crypts.** Cryptae tonsillares. Epithelial invaginations emanating from the tonsillar pits. See also p. 116.11. B



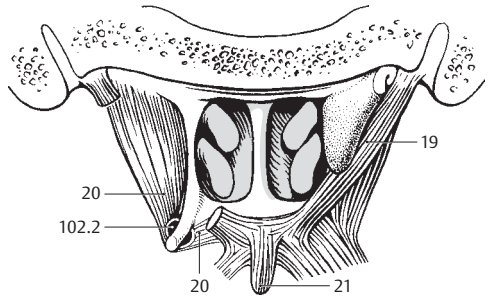
A Tonsillar fossa and soft palate



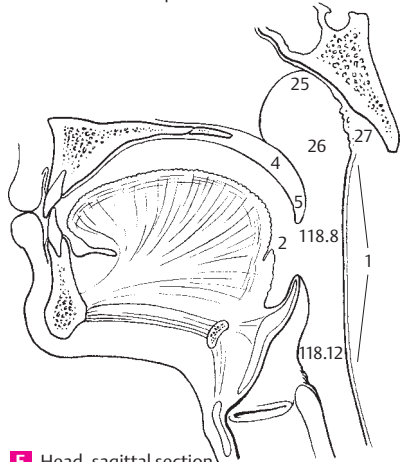
D Muscles of tonsillar fossa



B Palatine tonsil, microscopic view

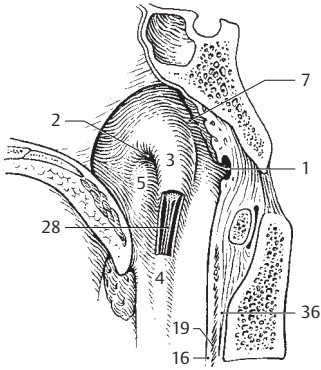


C Nasal cavity from behind and muscles of soft palate

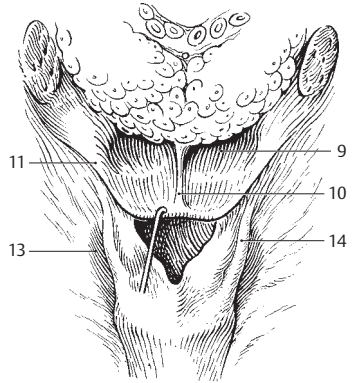


E Head, sagittal section

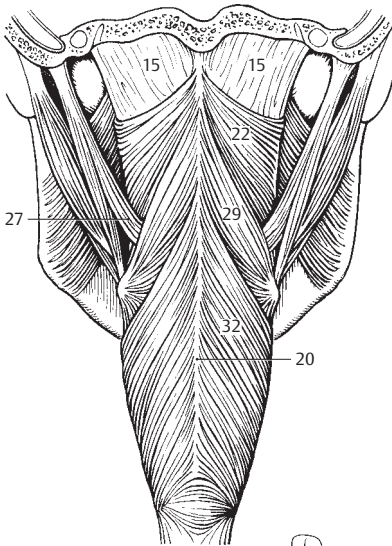
- 1 **Pharyngeal bursa.** [Bursa pharyngealis]. Blind pouch in the roof of the pharynx; it is more frequently present in children, less often in adults. A
- 2 **Pharyngeal opening of auditory tube.** Ostium pharyngeum tubae auditivae (auditoriae). Opening found in the nasopharynx. A
- 3 **Torus tubarius.** Elevation produced by the dorsomedial cartilage of the auditory tube posterior to the tube opening. A
- 4 **Salpingopharyngeal fold.** Plica salpingopharyngea. Mucosal fold overlying the salpingopharyngeal muscle and extending obliquely downward from the dorsomedial lip of the auditory tube cartilage. A
- 5 **Torus levatorius.** Elevation situated in front of the dorsomedial lip of the cartilage of the auditory tube and below the tube opening. It overlies the levator veli palatini muscle. A
- 6 **Tubal tonsil.** Tonsilla tubaria. Submucosal lymphatic tissue near the opening of the auditory tube.
- 7 **Pharyngeal recess.** Recessus pharyngeus [[Rosenmüller's]]. Lateral recess of the nasopharyngeal space behind the auditory tube. A
- 8 **Oropharynx.** Pars oralis pharyngis. The portion of the pharyngeal cavity located behind the oral cavity. See p. 117. E
- 9 **Vallecula epiglottica.** Fossa between the median and lateral glossoepiglottic folds. B
- 10 **Median glossoepiglottic fold.** Plica glossoepiglottica mediana. Unpaired mucosal fold located in the median plane between the base of the tongue and the epiglottis. B
- 11 **Lateral glossoepiglottic fold.** Plica glossoepiglottica lateralis. Bilateral mucosal fold between the base of the tongue and the epiglottis. B
- 12 **Laryngopharynx.** Pars laryngea pharyngis. The portion of the pharyngeal cavity situated behind the larynx. See p. 117. E
- 13 **Piriform recess.** Recessus piriformis. Channel between the aryepiglottic fold and the thyrohyoid membrane or thyroid cartilage. B
- 14 **Plica nervi laryngei.** Mucosal fold in the piriform recess produced by the underlying internal branch of the superior laryngeal nerve and the superior laryngeal artery. B
- 15 **Pharyngobasilar fascia.** Fascia pharyngobasilaris. Membranous wall of the uppermost muscle free portion of the pharynx. It corresponds to the thickened tela submucosa. C D E
- 16 **Submucosa.** Tela submucosa. Connective tissue layer between the mucosa and muscularis. A
- 17 **Mucosa.** Tunica mucosa. Pharyngeal mucous membrane lined by stratified squamous or pseudostratified ciliated columnar (nasopharynx) epithelium.
- 18 **Pharyngeal glands.** Gll. pharyngis. Small subepithelial mixed salivary glands.
- 19 **Muscularis of pharynx.** Tunica muscularis pharyngis. Muscular layer of pharyngeal wall. A
- 20 **Pharyngeal raphe.** Raphe pharyngis. Connective tissue band between the right and left pharyngeal muscles, extending posteriorly in the midline. C
- 21 **Pterygomandibular raphe.** Raphe pterygomandibularis. Tendinous seam between the buccinator muscle and the superior pharyngeal constrictor. It extends from the pterygoid hamulus to the mandible. D
- 22 **Superior pharyngeal constrictor muscle.** M. constrictor pharyngis superior. Uppermost constrictor of the pharynx consisting of the four parts described below, which attach to the pharyngeal raphe. I: Pharyngeal plexus. C D
- 23 **Pterygopharyngeal part.** Pars pterygopharyngea. o: Medial plate of pterygoid process and pterygoid hamulus. D
- 24 **Buccopharyngeal part.** Pars buccopharyngea. o: Pterygomandibular raphe. D
- 25 **Mylopharyngeal part.** Pars mylopharyngea. o: Posterior end of mylohyoid line of mandible. D
- 26 **Glossopharyngeal part.** Pars glossopharyngea. o: Intrinsic muscles of tongue. D
- 27 **M. stylopharyngeus.** o: Styloid process. i: Between superior and middle pharyngeal constrictors radiating into the pharyngeal wall, thyroid cartilage and epiglottis. I: Glossopharyngeal (IX) nerve. C
- 28 **M. salpingopharyngeus.** o: Dorsomedial lip of auditory tube cartilage and part of longitudinal musculature of pharyngeal wall. i: Lateral wall of pharynx. A: Prevents backward displacement of the levator veli palatini muscle. I: Pharyngeal plexus. A
- 29 **Middle pharyngeal constrictor muscle.** M. constrictor pharyngis medius. More centrally located pharyngeal constrictor arising from the hyoid bone. o: Pharyngeal raphe. I: Pharyngeal plexus. C
- 30 **Chondropharyngeal part.** Pars chondropharyngea. o: Lesser horn of hyoid. D
- 31 **Ceratopharyngeal part.** Pars ceratopharyngea. o: Greater horn of hyoid. D
- 32 **Inferior pharyngeal constrictor muscle.** M. constrictor pharyngis inferior. o: Larynx. I: Pharyngeal plexus. C D
- 33 **Thyropharyngeal part.** Pars thyropharyngea. o: Oblique line of thyroid cartilage. D
- 34 **Cricopharyngeal part.** Pars circopharyngea. o: Cricoid cartilage. D
- 34a **Buccopharyngeal fascia.** Fascia buccopharyngealis. Continuation of the buccopharyngeal fascia into the loose tissue connecting the pharynx to the deep cervical fascia.
- 35 **Peripharyngeal space.** Spatium peripharyngeum. Connective tissue space associated with the pharynx.
- 36 **Retropharyngeal space.** Spatium retropharyngeum. The portion of the peripharyngeal space between the pharynx and the prevertebral layer of the cervical fascia. A
- 37 **Lateropharyngeal space.** Spatium lateropharyngeum. Portion of the peripharyngeal space lateral to the pharynx.



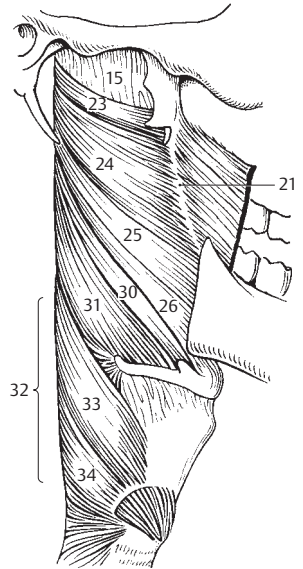
A Pharyngeal opening of auditory tube



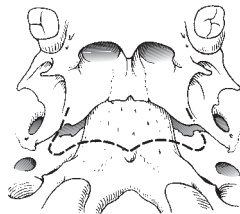
B Base of tongue and laryngeal opening



C Pharyngeal muscles from behind

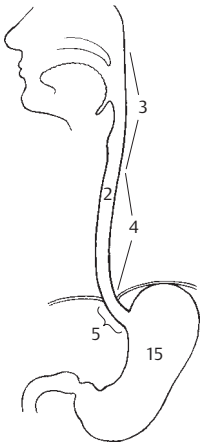


D Pharyngeal muscles from right

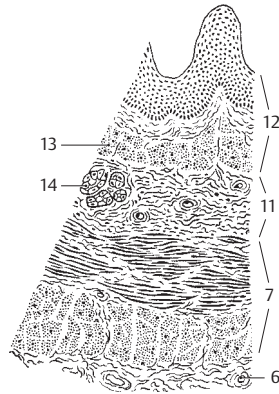


E Attachment of the pharyngobasilar fascia

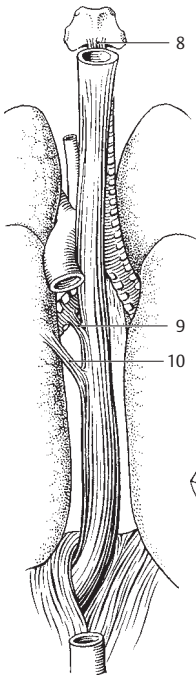
- 1 **DIGESTIVE TRACT (ALIMENTARY CANAL).** [[Canalis alimentarius]].
- 2 **ESOPHAGUS.** Oesophagus. 23–26 cm long passage extending from below the cricoid cartilage at the level of C6 to the cardiac part of the stomach. A B
- 3 **Cervical part.** Pars cervicalis. The segment of the esophagus situated in front of the cervical vertebral column (from C6–T1). A
- 4 **Thoracic part.** Pars thoracica. The portion of the esophagus extending from T1 to the passageway through the diaphragm (about T11). A
- 5 **Abdominal part.** Pars abdominalis. The short esophageal segment between the diaphragm and the stomach. A
- 6 **Tunica adventitia.** Loose connective tissue investment which binds the esophagus to the surrounding tissues and permits its movement. C
- 7 **Tunica muscularis.** Two layers of muscle, inner circular and outer longitudinal, occupying the esophageal wall and consisting of skeletal muscle in the upper third, smooth muscle in the lower third. C
- 8 **Cricoesophageal tendon.** Tendo cricoesophageus. Tendon that attaches the longitudinal muscle fibers of the esophagus to the posterior wall of the cricoid cartilage. B
- 9 **Bronchoesophageal muscle.** M. bronchoesophageus. Smooth muscle fibers from the left main bronchus to the esophagus. B
- 10 **Pleuroesophageal muscle.** M. pleuroesophageus. Smooth muscle tract between the esophagus and the left mediastinal pleura. B
- 11 **Tela submucosa.** Movable layer between the muscularis and mucosa consisting predominantly of collagenous connective tissue with blood vessels, nerves and glands. C
- 12 **Tunica mucosa.** Mucous membrane lining of the esophagus consisting of stratified, nonkeratinized squamous epithelium, lamina propria (connective tissue) and muscularis mucosae. C
- 13 **Lamina muscularis mucosae.** Distinct layer of smooth muscle between the submucosa and lamina propria. C
- 14 **Esophageal glands.** GII. esophageae. Discrete mixed glands scattered throughout the submucosa. C
- 15 **STOMACH.** Gaster (Ventriculus). It extends from the end of the esophagus to the pylorus. A D
- 16 **Anterior surface of stomach.** Paries anterior D
- 17 **Posterior surface of stomach.** Paries posterior. D
- 18 **Greater curvature of stomach.** Curvatura gastrica (ventricularis) major. Large curvature of the stomach profile directed toward the left and downward. D
- 19 **Lesser curvature of stomach.** Curvatura gastrica (ventricularis) minor. Small curvature of stomach directed toward the right and upward. D
- 20 **Angular notch.** Incisura angularis. Radiographically evident notch at the deepest point of the lesser curvature. D
- 21 **Cardiac part of stomach.** Pars cardiaca. The portion of the stomach into which the esophagus opens. D
- 22 **Cardiac orifice.** Ostium cardiacum (cardia). Opening of the esophagus into the cardiac stomach. D
- 23 **Fundic stomach.** Fundus gastricus (ventricularis). Fundus (dome) of the stomach located beneath the diaphragm. D
- 23a **Fornix of stomach.** Fornix gastricus (ventricularis). Forms the upper boundary of the lower diaphragm.
- 24 **Cardiac notch.** Incisura cardiaca. Acute angle between the esophagus and the stomach wall. D
- 25 **Body of stomach.** Corpus gastricum (ventriculare). Portion of stomach situated between the cardia/fundus and pylorus. D
- 26 **Gastric canal.** Canalis gastricus (ventricularis). Channel formed by the longitudinal mucosal folds along the lesser curvature of the stomach. D
- 27 **Pyloric part of stomach.** Pars pyloricum. Distal segment of the stomach beginning with the angular notch and ending with the pylorus. D
- 28 **Pyloric antrum.** Antrum pyloricum. Initial segment of the pyloric stomach beginning at the angular notch. It may be temporarily closed off from the rest of the gastric lumen during the passage of a peristaltic wave. D
- 29 **Pyloric canal.** Canalis pyloricus. Lower terminal segment of the stomach, about 2–3 cm long. D



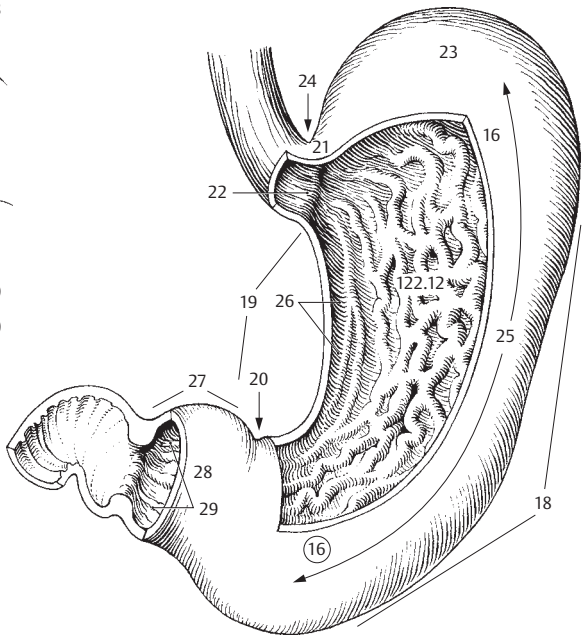
A Esophagus and stomach



C Microscopic cross-section of esophagus

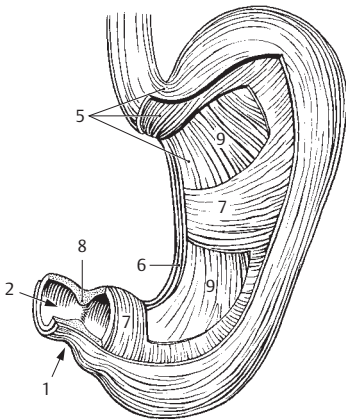


B Esophagus from behind

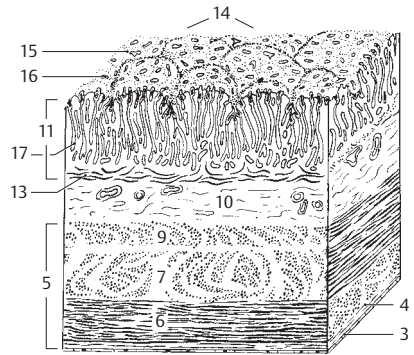


D Stomach from front right

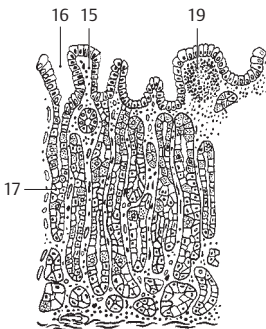
- 1 **Pylorus.** Distal end of the stomach reinforced by a strong band of circular muscle. A
- 2 **Pyloric opening.** Ostium pyloricum. Lumen of the pylorus connecting the stomach with the duodenum. A
- 3 **Serous membrane.** Tunica serosa. Serous, peritoneal covering containing simple squamous epithelium. B
- 4 **Tela subserosa.** Connective tissue component of the serosa underlying the epithelium. B
- 5 **Tunica muscularis.** Muscular coat of the stomach comprised of three types of fibers (longitudinal, circular, oblique). A B
- 6 **Longitudinal layer.** Stratum longitudinale. External layer of longitudinal muscle fibers situated primarily along the greater and lesser curvatures. A B
- 7 **Circular layer.** Stratum circulare. Middle layer of circular muscle. A B
- 8 **Pyloric sphincter.** M. sphincter pyloricus. Thick layer of circular muscle around the pylorus. A
- 9 **Oblique fibers.** Fibrae obliquae. Inner layer of obliquely coursing fibers of the tunica muscularis. A B
- 10 **Tela submucosa.** Displaceable layer between the muscularis mucosae and the muscularis; it is composed primarily of collagenous connective tissue bearing vessels and nerves. B
- 11 **Tunica mucosa.** Gastric mucous membrane consisting of simple columnar epithelium, connective tissue (lamina propria) and muscularis mucosae. B
- 12 **Gastric folds.** Plicae gastricae. Mucosal folds extending primarily in a longitudinal direction. See p. 121 D
- 13 **Lamina muscularis mucosae.** Layer of smooth muscle between the lamina propria and the submucosa. Its contraction produces folds in the mucosa. B
- 14 **Gastric (mamillated) areas.** Areae gastricae. Mamillated areas on the mucosal surface that are bounded by shallow grooves and have a diameter of 1–6 mm. B
- 15 **Villous folds.** Plicae villosae. Epithelial ridges invisible to the naked eye between the openings of glands. B C D
- 16 **Gastric pits (foveolae).** Foveolae gastricae. Openings of the gastric glands between the villous folds. B C D
- 17 **Gastric glands proper.** Glandula gastrica propria. Tubular glands in the fundus and body of the stomach made up of 4 cell types. B C
- 18 **Pyloric glands.** Glandula pylorica. Mucoïd glands in the pyloric part of the stomach consisting of two cell types. D
- 19 **Lymphatic nodules (follicles).** [Folliculi lymphatici gastrici]. Small aggregations of lymphatic tissue in the lamina propria. C D
- 20 **SMALL INTESTINE.** Intestinum tenue. It comprises the duodenum, jejunum and ileum.
- 21 **Tunica serosa.** Peritoneal covering containing simple squamous epithelium. F
- 22 **Tela subserosa.** Connective tissue underlying the serosa. F
- 23 **Tunica muscularis.** Two principal muscle layers of the intestinal wall. F
- 24 **Longitudinal layer.** Stratum longitudinale. Outer layer of longitudinally coursing muscle fibers. F
- 25 **Circular layer.** Stratum circulare. Inner layer of circularly coursing muscle fibers. F
- 26 **Tela sumucosa.** Displaceable layer between the muscularis mucosae and the muscularis consisting primarily of collagenous connective tissue bearing blood vessels and nerves. F
- 27 **Tunica mucosa.** Intestinal mucous membrane consisting of simple columnar epithelium, connective tissue (lamina propria) and muscularis mucosae.
- 28 **Lamina muscularis mucosae.** Layer of smooth muscle between the lamina propria and submucosa. Its action produces folds in the mucosa. F
- 29 **Circular folds [Valves of Kerckring].** Plicae circulares. Permanent folds of mucosa and submucosa spanning nearly 2/3 of the intestinal lumen and projecting up to 8 mm high, perpendicular to the intestinal axis. E F
- 30 **Intestinal villi.** Villi intestinales. Fingerlike projections about 0.5–1.5 mm in length. F
- 31 **Intestinal glands.** Gll. intestinales. Cryptlike glands. F
- 32 **Solitary lymphatic follicles.** Folliculi lymphatici solitarii. Solitary lymphatic nodules in the lamina propria (p. 405.42) F
- 33 **Aggregated lymphatic follicles [Peyer's patches].** Folliculi lymphatici aggregati. Aggregation of several lymphatic nodules in the ileum.



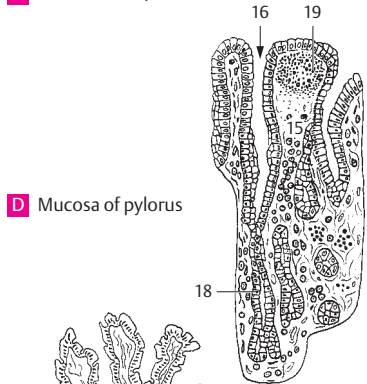
A Stomach musculature



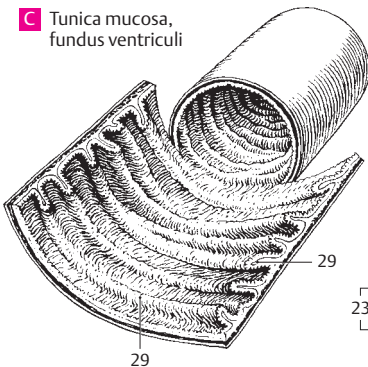
B Stomach wall, overview



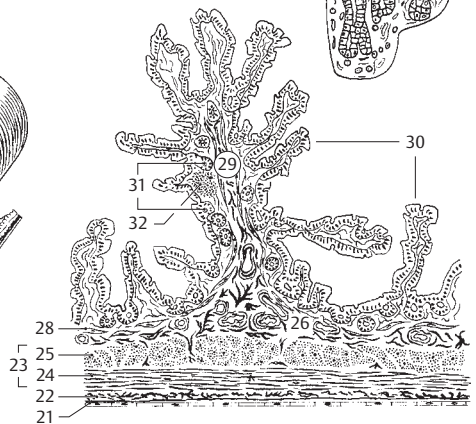
C Tunica mucosa, fundus ventriculi



D Mucosa of pylorus



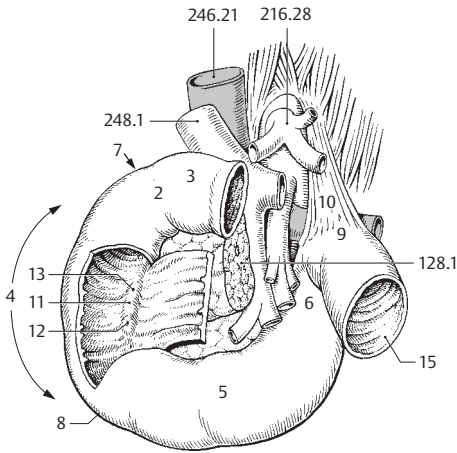
E Intestinal canal



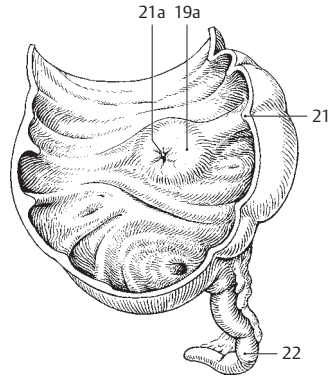
F Intestinal wall, histological section

5

- 1 **DUODENUM.** Initial segment of the small intestine, about 25–30 mm long, between the pylorus and the duodenojejunal flexure. A
- 2 **Superior part.** Pars superior. Horizontal beginning part of the duodenum. A
- 3 **Ampulla** [*bulbus duodeni*]. Functional dilatation at the beginning of the duodenum. It is briefly visible in radiograms. A
- 4 **Descending part.** Pars descendens. Lateral, vertical segment. A
- 5 **Horizontal (inferior) part.** Pars horizontalis (inferior). Horizontal segment below the head of the pancreas. A
- 6 **Ascending part.** Pars ascendens. Segment of duodenum lying to the left of the head of the pancreas and ascending up to the duodenojejunal flexure. A
- 7 **Superior duodenal flexure.** Flexura duodeni superior. Flexure between the superior and horizontal parts of the duodenum medial to the gallbladder. A
- 8 **Inferior duodenal flexure.** Flexura duodeni inferior. Flexure between the descending and horizontal parts of the duodenum. A
- 9 **Duodenojejunal flexure.** Flexura duodenojejunalis. Flexure between the duodenum and jejunum. A
- 10 **Suspensory muscle of duodenum.** M. suspensorius duodeni. Bundle of smooth muscle which attaches the duodenojejunal flexure to the diaphragm or to the celiac trunk. A
- 11 **Longitudinal folds of duodenum.** Plicae longitudinales duodeni. Longitudinal mucosal folds on the left side of the posterior wall of the descending part of the duodenum produced by the pancreatic and bile ducts. A
- 12 **Greater duodenal papilla.** Papilla duodeni major. Elevation at the end of the longitudinal fold at the openings of the common bile duct and pancreatic duct. A
- 13 **Lesser duodenal papilla.** Papilla duodeni minor. Elevation located superior to the greater duodenal papilla, usually at the opening of the accessory pancreatic duct. A
- 14 **Duodenal glands** [*Brunner's glands*]. Glandulae duodenales. Mucous glands located predominantly in the submucosa of the duodenum.
- 15 **JEJUNUM.** Middle segment of the small intestine. It extends about 2.5 meters from the duodenojejunal flexure. A C
- 16 **ILEUM.** Terminal segment of small intestine, about 3.5 mm long. C
- 17 **LARGE INTESTINE.** Intestinum crassum. About 1.5–1.8 m long; it extends from the cecum to the anus and consists of tenia, haustra and appendices epiploicae.
- 18 **CECUM.** Caecum. Initial portion of the large intestine, ca. 7 cm long, located below the opening of the ileum. C D
- 19 **Ileocecal valve.** Valva ileocaecalis (Valva ilealis). Two-lipped valve at the entrance of the ileum into the large intestine. D
- 19a **Papilla ilealis.** B
- 20 **Opening of ileocecal valve.** Ostium valvae ilealis. Transverse, slitlike aperture of ileum at entrance into the large intestine in the cadaver. D
- 21 **Frenulum valvae ilealis.** Fold formed by the union of the lips of the ileocecal valve. B D
- 21a **Ostium papillae ilealis.** B
- 22 **Vermiform appendix.** Appendix vermiformis. Appendage of the cecum, usually 9 cm long, with abundant lymphatic tissue. B C D
- 23 **Ostium appendicis vermiformis.** Opening of vermiform appendix into the cecum. D
- 24 **Aggregated lymphatic nodules of vermiform appendix.** Folliculi lymphatici aggregati appendicis vermiformis. Lymphatic tissue within the wall of the appendix.
- 25 **COLON.** Portion of large intestine extending from the ileocecal valve to the rectum.
- 26 **Ascending colon.** Colon ascendens. Segment of large intestine ascending retroperitoneally on the right side. C
- 27 **Right colic flexure.** Flexura coli dextra. Flexure between the ascending and transverse colon. C
- 28 **Transverse colon.** Colon transversum. Transverse segment of large intestine situated intraperitoneally between the right and left colic flexures. C
- 29 **Left colic flexure.** Flexura coli sinistra. Flexure between the transverse and descending colon below the left subphrenic space. In its vicinity lies Cannon-Böhm's ring, the boundary between the cranial (vagus nerve) and sacral parasympathetics. C
- 30 **Descending colon.** Colon descendens. Segment of large intestine extending retroperitoneally on the left side between the left colic flexure and sigmoid colon. C
- 31 **Sigmoid colon.** Colon sigmoideum. Portion of colon lying intraperitoneally between the descending colon and the rectum. C
- 32 **Semilunar folds of colon.** Plicae semilunares coli. Crescentic contraction folds between two haustra comprising all layers of the intestinal wall. C D
- 33 **Haustra (sacculaciones) coli.** Outpocketings between two semilunar folds. C D
- 34 **Appendices epiploicae (ommentales).** Serosa-covered appendages containing adipose tissue, located on the free and omental tenia. C

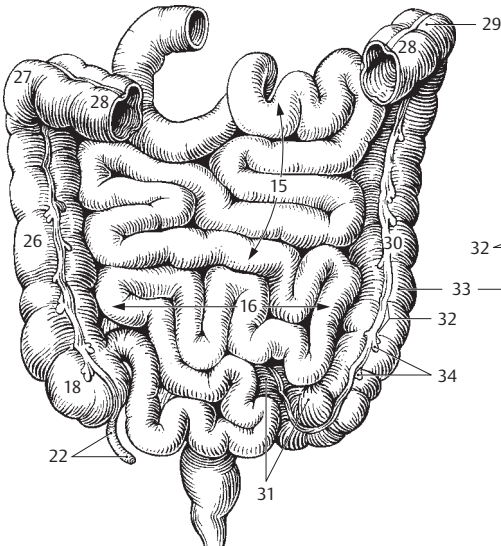


A Portal vein, inferior vena cava, aorta and duodenum

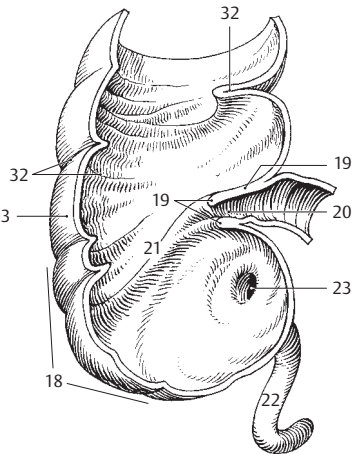


5

B Cecum in the living body

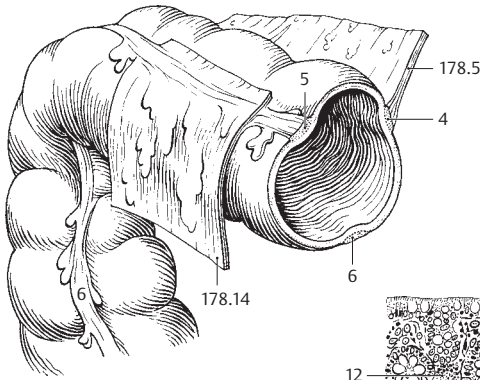


C Small and large intestines, anterior view

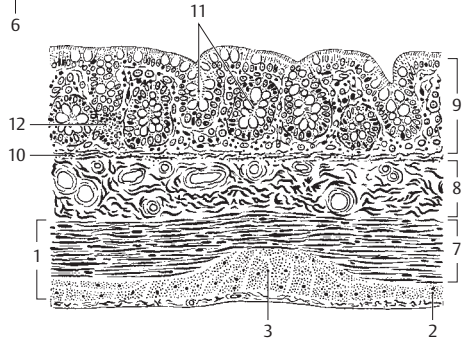


D Cecum in the cadaver

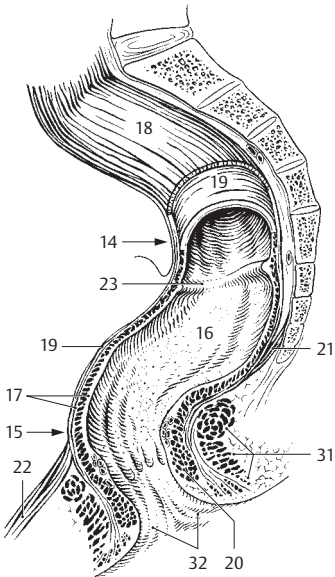
- 1 **Tunica muscularis.** Bilayered muscle wall of colon. B
- 2 **Longitudinal layer.** Stratum longitudinale. Distinct outer layer of longitudinally oriented muscle of variable thickness. B
- 3 **Taeniae coli.** About 1 cm wide, thickened bands of longitudinal muscle fibers. B
- 4 **Taenia mesocolica.** Tenia located at the attachment of the mesocolon in the posteromedial part of the ascending and descending colon. A
- 5 **Taenia omentalis.** Tenia of transverse colon located at the attachment of the greater omentum in the posteromedial part of the ascending and descending colon. A
- 6 **Taenia libera.** Free tenia located between the tenia mesocolica and tenia omentalis. A
- 7 **Circular layer.** Stratum circulare. Inner layer of circularly coursing muscle fibers of the colon. B
- 8 **Tela submucosa.** Displaceable layer between the muscularis mucosa and the muscularis, consisting mainly of collagenous connective tissue containing nerves and blood vessels. B
- 9 **Tunica mucosa.** Villus-free mucous coat of the colon comprised of simple, goblet-cell rich, columnar epithelium, connective tissue and lamina muscularis mucosae. B
- 10 **Lamina muscularis mucosae.** Layer of smooth muscle cells between the lamina propria and submucosa. Its contraction produces a wrinkling of the mucosa. B
- 11 **Intestinal glands.** Glandulae intestinales. Tubular glands of the colonic mucosa. B
- 12 **Solitary lymphatic nodules.** Nodi lymphatici solitarii. Individual lymphatic nodules dispersed throughout the lamina propria. B
- 13 **RECTUM.** Tenia-free segment, about 15 cm long, located between the sigmoid colon and the anus. C
- 14 **Sacral flexure.** Flexura sacralis. Anteriorly concave bend in the rectum that conforms with the sacrum. C
- 15 **Perineal flexure.** Flexura perinealis. Anteriorly convex bend in the rectum located just above the anus. C
- 16 **Ampulla recti.** Dilated portion of the rectum above the anal canal. C
- 17 **Tunica muscularis.** Muscular wall of rectum. C
- 18 **Longitudinal layer.** Stratum longitudinale. Layer of longitudinally oriented muscle fibers distributed uniformly throughout the entire circumference of the rectum. C
- 19 **Circular layer.** Stratum circulare. Inner layer of circularly oriented muscle fibers of the tunica muscularis; no semilunar folds form in this part of the rectum. C
- 20 **Internal anal sphincter.** M. sphincter ani internus. Thickened muscular ring of the circular layer at the anus, ca. 1–2 cm in height. C
- 21 **M. rectococcygeus.** Thin plate of smooth muscle extending from the 2nd to 3rd coccygeal vertebrae to the rectum. C
- 22 **M. rectourethralis.** Smooth muscle fibers extending from the membranous part of the urethra to the rectum. C
- 23 **Transverse rectal folds.** Plicae transversae recti. Usually three lateral transverse folds. The middle is the largest (Kohlrusch) and projects about 6 mm above the anus from the right side, the others from the left. C
- 24 **ANAL CANAL.** Canalis analis. Terminal segment of the digestive tube beginning with the anal columns. D
- 25 **Anal columns.** Columnae anales. Six to ten longitudinal folds provided with abundant venous plexuses. D
- 26 **Anal sinuses.** Sinus anales. Recesses between the anal columns. D
- 27 **Anal valves.** Valvulae anales. Small transverse folds bordering the anal sinuses distally. D
- 28 **Anorectal line.** Linea anorectalis. Upper border of anal canal formed by the puborectal muscle at the level of the levator sling just above the anal columns. D
- 29 **Anal pecten.** [[Pecten analis]]. A lighter stripe between the anal valves and the anocutaneous line. It is firmly connected with the underlying tissues by fibrous longitudinal muscles. D
- 30 **Anocutaneous line.** [[Linea anocutanea]]. Lower border of anal pecten at the level of the lower margin of the internal anal sphincter. D
- 31 **External anal sphincter.** M. sphincter ani externus. Circular layer of skeletal muscle lying on the internal anal sphincter. C D See p. 174.14–17
- 32 **Anus.** Lower opening of anal canal surrounded by the subcutaneous and superficial parts of the external anal sphincter. C D



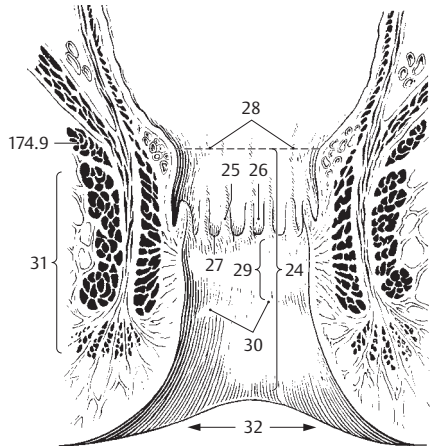
A Right colic flexure



B Wall of colon, histological section

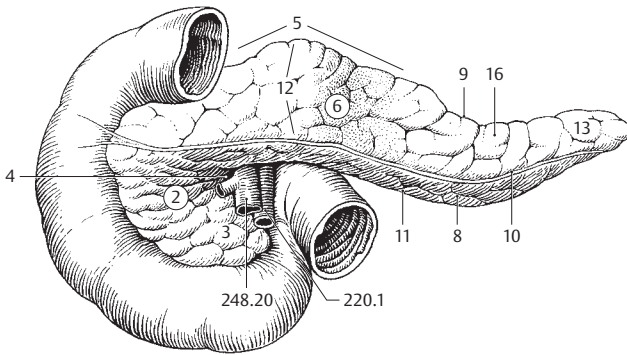


C Rectum

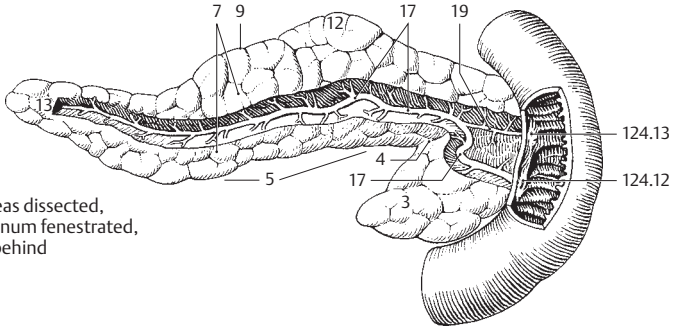


D Anus, frontal section

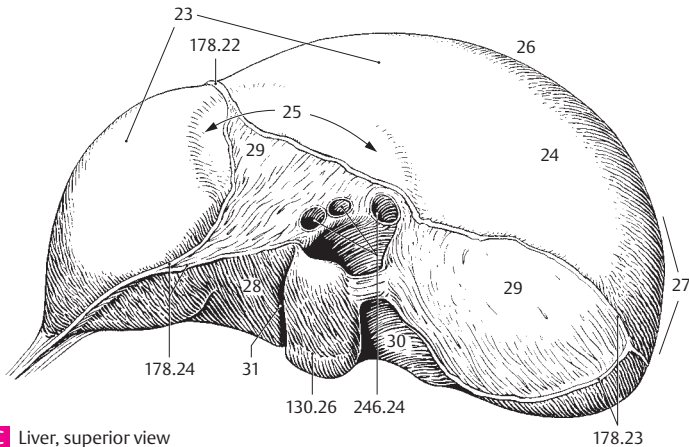
- 1 **PANCREAS.** Organ 13–15 cm in length that lies partly in the duodenal loop, partly behind the omental bursa at the level of L1–2. A B
- 2 **Head of pancreas.** Caput pancreatis. It is nestled within the loop of the duodenum. A
- 3 **Uncinate process.** Processus uncinatus. Hook-shaped process passing behind the superior mesenteric vessels. A B
- 4 **Pancreatic notch.** Incisura pancreatis. Groove between the uncinata process and the remaining part of the head of the pancreas. A B
- 5 **Body of pancreas.** Corpus pancreatis. Part of the pancreas lying mainly in front of the vertebral column. It arises from the dorsal anlage of the pancreas. A B
- 6 **Anterior surface.** Facies anterior. Anterosuperiorly directed anterior (front) surface of the pancreas. A
- 7 **Posterior surface.** Facies posterior. Posteriorly directed dorsal (back) surface of the pancreas. B
- 8 **Inferior surface.** Facies inferior. Anteroinferiorly directed inferior surface of the pancreas. It is bounded above by the root of the transverse mesocolon. A
- 9 **Superior margin.** Margo superior. Superior margin of the pancreas located between the anterior and posterior surfaces. A B
- 10 **Anterior margin.** Margo anterior. Anterior margin of the pancreas, which corresponds to the line of attachment of the transverse mesocolon (p. 178.5). It also forms the lower boundary of the omental bursa at the posterior abdominal wall. A
- 11 **Inferior margin.** Margo inferioris. Inferior margin of the pancreas situated between the lower anterior and posterior surfaces. A
- 12 **Tuber omentale.** Prominence on the body of pancreas near the head. It projects into the omental bursa and is caused by the vertebral column. A B
- 13 **Tail of pancreas.** Cauda pancreatis. Upper left tail of the pancreas that lies in contact with the spleen. A B
- 14 **Capsule of pancreas.** Capsula pancreatis.
- 15 **Exocrine pancreas.** Pars exocrina pancreatis. The bulk of the pancreas where pancreatic juice is produced.
- 16 **Pancreatic lobule.** Lobulus pancreaticus. The macroscopically visible lobule of the pancreas. A
- 17 **Pancreatic duct.** Ductus pancreaticus. Main excretory duct of the pancreas opening on the greater duodenal papilla together with the bile duct. B
- 18 **Sphincter muscle of pancreatic duct.** M. sphincter ductus pancreatici. Circular muscle before the duct opening. See p. 135 A
- 19 **Accessory pancreatic duct.** Ductus pancreaticus accessorius. Additional excretory duct usually found draining into the minor duodenal papilla (p. 124.13) above the major duodenal papilla. B
- 20 **Accessory pancreas.** (Pancreas accessorium). Pancreatic tissue dispersed within the wall of the stomach or duodenum.
- 21 **Endocrine pancreas.** Pars endocrina pancreatis. Part of the pancreas consisting of about 1 million Langerhans' islets, which produce glucagon and insulin.
- 22 **LIVER.** Hepar. It is divided into segments on the basis of the branchings of its blood vessels and biliary ducts. The individual segments are not represented uniformly in the literature. The International Nomenclature Committee has adopted Hjortsjö's classification. C
- 23 **Diaphragmatic surface.** Facies diaphragmatica. Surface of liver facing the diaphragm. C
- 24 **Superior part.** Pars superior. The cranially directed superior portion of the diaphragmatic liver surface. C
- 25 **Cardiac impression.** Impressio cardiaca. Flat impression made by the heart on the left side of the liver in front of the inferior vena cava. C
- 26 **Anterior part.** Pars anterior. The anteriorly directed portion of the diaphragmatic liver surface. C
- 27 **Right part.** Pars dextra. Portion of the diaphragmatic surface directed toward the right side of the body. C
- 28 **Posterior part.** Pars posterior. The posteriorly directed portion of the diaphragmatic surface. C
- 29 **Bare area.** Area nuda. [[Pars affixa]]. Bare portion of the diaphragmatic surface not covered by peritoneum. C
- 30 **Groove for vena cava.** Sulcus venae cavae. Deep groove for reception of the inferior vena cava. C
- 31 **Fissure for lig. venosum.** Fissura ligamenti venosi. Groove for the venous ligament extending from the liver hilum to the inferior vena cava between the caudate lobe and left lobe. C



A Duodenum and pancreas, anterior view

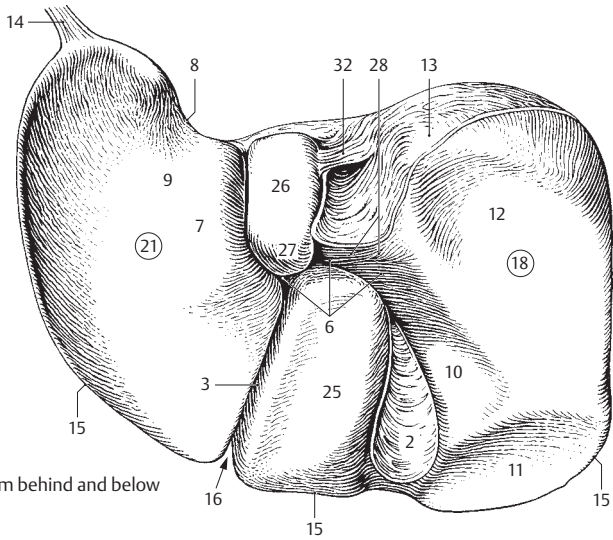


B Pancreas dissected, duodenum fenestrated, from behind

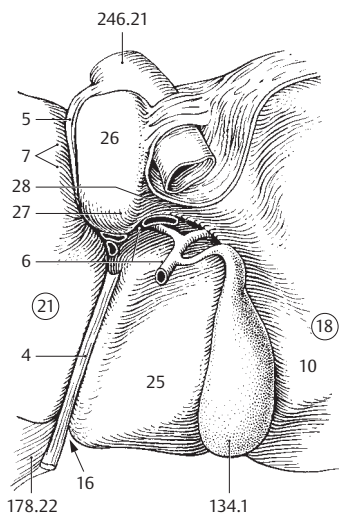


C Liver, superior view

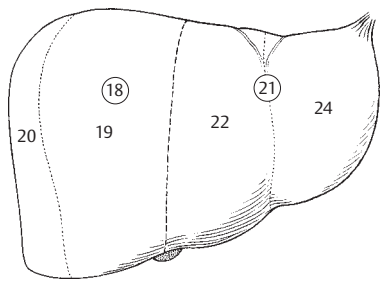
- 5
- 1 **Visceral surface.** Facies visceralis. Posteroinferior, partially concave surface of liver facing the viscera.
 - 2 **Fossa of gallbladder.** Fossa vesicae biliaris. Fossa on the visceral surface of the liver that lodges the gallbladder. A
 - 3 **Fissure for round ligament.** Fissura ligamenti teretis. Fissure on the visceral surface of the liver that lodges the ligamentum teres hepatis. A
 - 4 **Round ligament of liver.** Lig. teres hepatis. The connective tissue remains of the umbilical vein. B
 - 5 **Ligamentum venosum.** [[Arantii]]. Venous ligament of liver, the fibrous remains of the ductus venosus. B
 - 6 **Hilum of liver.** Porta hepatis. Fissure between the caudate and quadrate lobes in which run the hepatic artery proper, portal vein and hepatic duct. A B
 - 7 **Tuber omentale.** Bulge on the visceral surface of the left lobe to the left of the ligamentum venosum. A B
 - 8 **Esophageal impression.** Impressio oesophagea. Groove on the left lobe where the liver is indented by the esophagus. A
 - 9 **Gastric impression.** Impressio gastrica. Impression caused by contact of the stomach with the visceral surface of the left lobe of the liver. A
 - 10 **Duodenal impression.** Impressio duodenalis. Impression caused by contact of the duodenum with the right side of the visceral surface of the liver next to the neck of the gallbladder. A B
 - 11 **Colic impression.** Impressio colica. Impression caused by contact of the colon with the visceral surface of the right lobe of liver to the right of the gallbladder. A
 - 12 **Renal impression.** Impressio renalis. Impression caused by contact of the right kidney with the visceral surface of the right lobe. It overlaps the bare area. A
 - 13 **Suprarenal impression.** Impressio suprarenalis. Impression caused by contact of the right suprarenal gland with the bare area on the right side near the inferior vena cava. A
 - 14 **[Appendix fibrosa hepatis].** Connective tissue band occasionally present at the upper end of the left lobe of the liver. A
 - 15 **Inferior margin.** Margo inferior. Border between the diaphragmatic and visceral surfaces of the liver. A
 - 16 **Incisura lig. teretis.** Notch for round ligament at the lower border of the liver. A B
 - 17 **Lobes of liver.** Lobi hepatis. The four macroscopically visible lobes of the liver, which are described below.
 - 18 **Right lobe of liver.** Lobus hepatis dexter. Its border to the left lobe corresponds to the line connecting the inferior vena cava and fundus of the gallbladder. A B C
 - 19 **Anterior segment of liver.** Segmentum anterius. C D
 - 20 **Posterior segment of liver.** Segmentum posterius. C D
 - 21 **Left lobe of liver.** Lobus hepatis sinister. Its right border corresponds to a line connecting the inferior vena cava and fundus of gallbladder. A B C
 - 22 **Medial segment.** Segmentum mediale. C D
 - 23 **Quadrate part.** Pars quadrata. Part belonging to the quadrate lobe. D
 - 24 **Lateral segment.** Segmentum laterale. C D
 - 25 **Quadrate lobe.** Lobus quadratus. Liver lobe situated between the gallbladder, round ligament and hilum. A B
 - 26 **Caudate lobe.** Lobus caudatus. Liver lobe situated between the inferior vena cava, hilum and ligamentum venosum. A B
 - 27 **Papillary process.** Processus papillaris. Portion of caudate lobe projecting caudally. A B
 - 28 **Caudate process.** Processus caudatus. Parenchymal connection between the caudate and right lobes cranial to the hilum. A B
 - 29 **Tunica serosa.** Peritoneal covering containing simple squamous epithelium.
 - 30 **Tela subserosa.** Connective tissue layer beneath the serosa.
 - 31 **Tunica fibrosa.** Immobile connective tissue capsule of liver; thick, especially in the bare area not covered by peritoneum.
 - 32 **Ligament of vena cava.** [[Lig. venae caevae]]. Connective tissue bridging over the inferior vena cava.



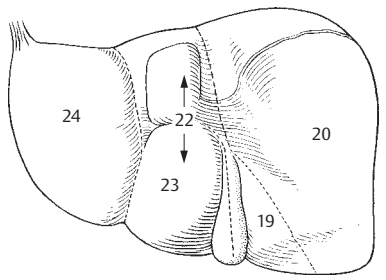
A Liver from behind and below



B Hepatic porta

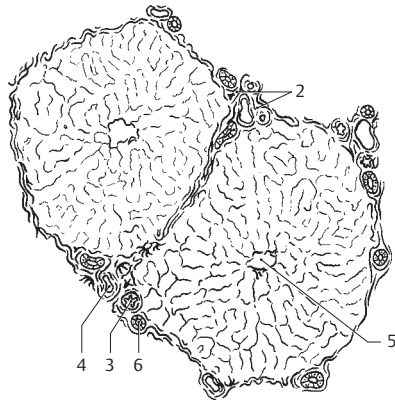


C Liver segments, anterior view

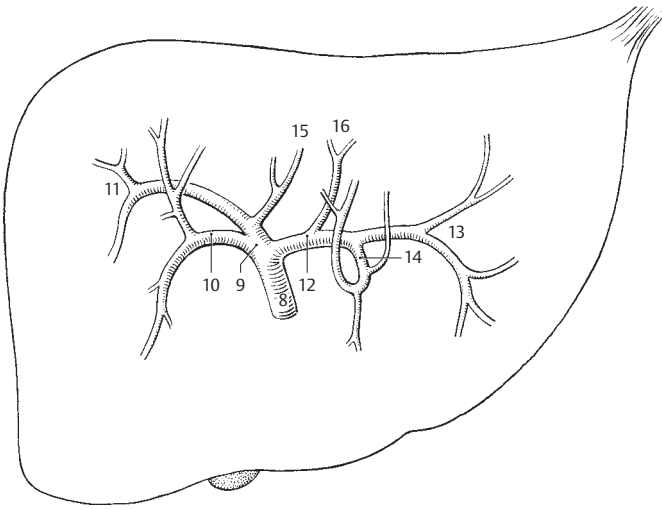


D Liver segments, posterior view

- 5
- 1 **Hepatic lobules.** Lobuli hepatis. They measure 1–2 mm in size. A
 - 2 **Perivascular fibrous capsule.** Capsula fibrosa perivascularis. Connective tissue sheath accompanying the liver vessels and biliary ducts until their terminal branches. A
 - 3 **Interlobular arteries.** Arteriae interlobulares. Branches of the hepatic artery proper between the liver lobules. A
 - 4 **Interlobular veins.** Venae interlobulares. Branches of the portal veins between the liver lobules. A
 - 5 **Central veins.** Venae centrales. Efferent veins in the center of the liver lobule. A
 - 6 **Interlobular ductules.** Ductuli interlobulares. Biliary drainage channels between the liver lobules. A
 - 7 **Ductuli biliferi.** Biliary drainage channels which connect the interlobular ductules with the right and left hepatic ducts.
 - 8 **Common hepatic duct.** Ductus hepaticus communis. Duct between the cystic duct and the junction of right and left hepatic ducts. B
 - 9 **Right hepatic duct.** Ductus hepaticus dexter. Duct arising from the right lobe of liver. B
 - 10 **Anterior branch.** Ramus anterior. Anterior branch of the right hepatic duct. B
 - 11 **Posterior branch.** Ramus posterior. Posterior branch of the right hepatic duct. B
 - 12 **Left hepatic duct.** Ductus hepaticus sinister. Duct arising from the left lobe of the liver. B
 - 13 **Lateral branch.** Ramus lateralis. Lateral branch of the left hepatic duct. B
 - 14 **Medial branch.** Ramus medialis. Medial branch of the left hepatic duct. B
 - 15 **Right duct of caudate lobe.** Ductus lobi caudati dexter. Branch coming from the right half of the caudate lobe and usually leading into right hepatic duct. B
 - 16 **Left duct of caudate lobe.** Ductus lobi caudati sinister. Branch arising from the left half of the caudate lobe and emptying usually into the left hepatic duct. B

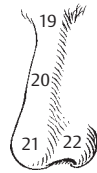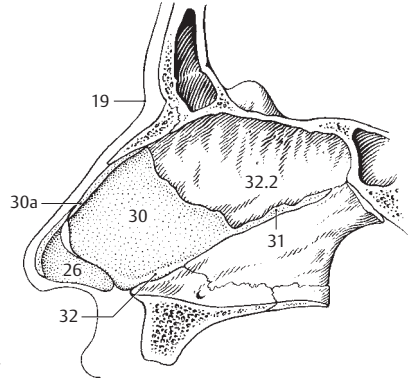
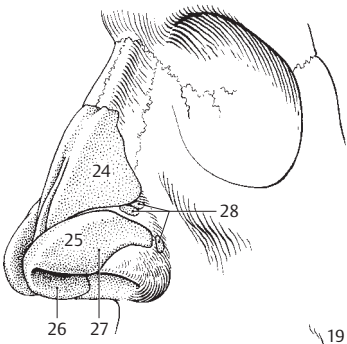
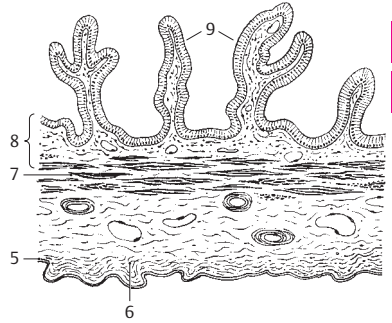
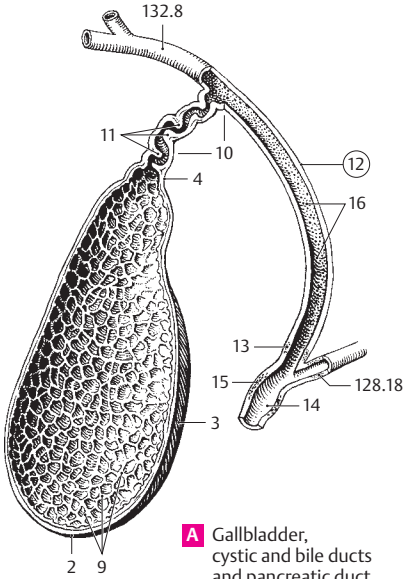


A Two liver lobules

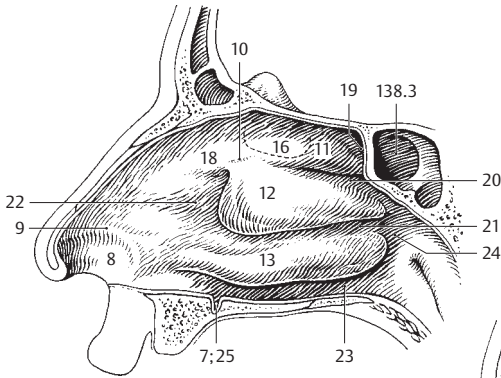


B Branches of the hepatic duct, anterior view

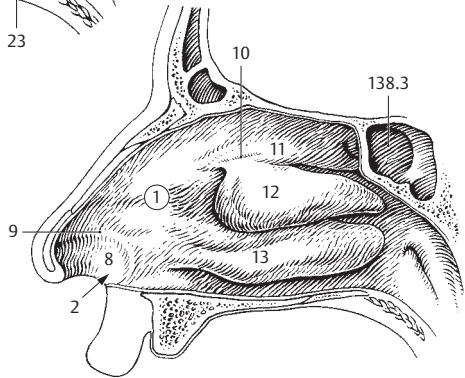
- 1 **GALLBLADDER.** Vesica biliaris (fellea). 8–12 cm long, pear-shaped reservoir for bile. A
- 2 **Fundus of gallbladder.** Fundus vesicae biliaris. Caudally directed rounded end of gallbladder. A
- 3 **Body of gallbladder.** Corpus ves. biliaris. Portion of gallbladder between the fundus and neck. A
- 4 **Neck of gallbladder.** Collum vesicae biliaris. The portion of the gallbladder continuous with the cystic duct. A
- 5 **Tunica serosa.** Peritoneal lining of the gallbladder. B
- 6 **Tela subserosa.** Connective tissue underlying the peritoneum. B
- 7 **Tunica muscularis.** Muscle layer in the wall of the gallbladder. B
- 8 **Tunica mucosa.** Mucous membrane of gallbladder with simple columnar epithelium comprised of tall prismatic cells. B
- 9 **Plicae mucosae.** Mucosal folds that project into the lumen, thus producing a loculate relief pattern. A B
- 10 **Cystic duct.** Ductus cysticus. Duct that drains the gallbladder. It joins the common hepatic duct to form the common bile duct (ductus choledochus). A
- 11 **Spiral fold.** Plica spiralis. A spiral elevation in the neck of the gallbladder and the cystic duct. A
- 12 **Bile duct.** Ductus choledochus (biliaris). Duct formed by the union of the cystic duct and common hepatic duct; it passes into the greater duodenal papilla. A
- 13 **Sphincter muscle of bile duct.** M. sphincter ductus choledochi. Thickened, annular muscle that forms sphincter directly before the hepatopancreatic ampulla. A
- 14 **Hepatopancreatic ampulla.** Ampulla hepatopancreatica. Dilatation in the wall of the duodenum immediately after the opening of the pancreatic duct into the bile duct. A
- 15 **M. sphincter ampullae hepatopancreaticae (sphincter ampullae).** Thickened annular sheath of muscle that invests the ampulla (sphincter of Oddi). A
- 16 **Biliary glands.** Gl. biliaires. Mucous glands in the wall of the biliary excretory ducts.
- 17 **RESPIRATORY SYSTEM.** Apparatus respiratorius (systema respiratorium).
- 18 **EXTERNAL NOSE.** Nasus externus. E
- 19 **Root of nose.** Radix nasi (nasalis). Upper portion of the nose which lies between the two orbits. D E
- 20 **Dorsum (bridge) of nose.** Dorsum nasi. E
- 21 **Tip of nose.** Apex nasi. E
- 22 **Alae (wings) of nose.** Alae nasi. Winglike structures forming the lateral borders of the nares. E
- 23 **Nasal cartilages.** Cartilagine nasii (nasalis). Pieces of cartilage which form the non-osseous supporting skeleton of the nose. C
- 24 **Lateral nasal cartilage.** [Cartilago nasi lateralis]. No longer classified as independent left and right plates of cartilage, but as part of the nasal septum with which each is partially fused. C
- 25 **Greater alar cartilage.** Cartilago alaris major. Hook-shaped cartilage surrounding the nares and forming the tip of the nose. C
- 26 **Medial crus.** Crus mediale. The part of the greater alar cartilage that forms the anterior and lower part of the nasal septum. C D
- 27 **Lateral crus.** Crus laterale. The part of the greater alar cartilage that curves laterally around the nares. C
- 28 **Lesser alar cartilages.** Cartilagine alares minores. Single, small plates of cartilage which supplement the greater alar cartilage. C
- 29 **Accessory nasal cartilages.** Cartilagine nasales accessoriae. Small pieces of cartilage occasionally present between the cartilaginous nasal septum and greater alar cartilage that supplement the cartilaginous nasal skeleton.
- 30 **Cartilaginous nasal septum.** Cartilago septi nasi. Large independent piece of cartilage in the wall of the nasal septum between the perpendicular plate of the ethmoid and the vomer. D
- 30a **Lateral process.** Processus lateralis. Dorsolateral cartilaginous ridge of the nasal septum fused above with the lateral nasal cartilage. D
- 31 **Posterior process.** Processus posterior (sphenoidalis). Variably long process between the vomer and the perpendicular plate; it can extend as far as the sphenoid. D
- 32 **Vomer nasal cartilage.** Cartilago vomeronasalis [[Jacobson's cartilage]]. Narrow strip of cartilage on the lower end of the nasal septum between the cartilaginous nasal septum and the vomer. D
- 33 **Mobile part of nasal septum.** [[Pars mobilis septi nasi]]. Anteroinferior, very mobile part of the nasal septum which contains the medial crus of the greater alar cartilage.



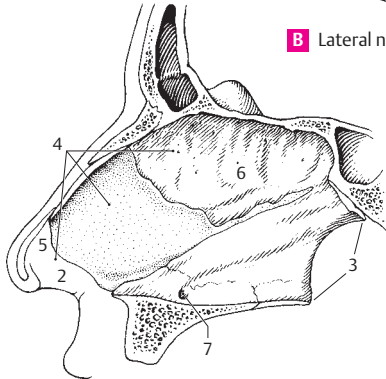
- 1 **NASAL CAVITY.** Cavitas nasalis. A B C
- 2 **Nasal openings (nostrils).** Nares. They are surrounded by the nasal alae and nasal septum. B C
- 3 **Choanae.** Posterior openings of nasal cavity. C
- 4 **Nasal septum.** Septum nasale. Nasal partition comprised of bony, cartilaginous and membranous parts. C
- 5 **Membranous part.** Pars membranacea. Connective tissue portion of nasal septum at the tip of the nose. C
- 5a **Cartilaginous part.** Pars cartilagina. Portion of the nasal septum situated between the membranous and bony parts.
- 6 **Bony part of nasal septum.** Pars ossea. Perpendicular plate of ethmoid and vomer. C
- 7 **Vomeronasal (Jacobson's) organ.** Organum vomeronasale. Blind sac occasionally present above the incisive canal. It is a vestige of an earlier phylogenetic accessory organ of smell. A C
- 8 **Vestibule of nose.** Vestibulum nasi (nasale). Anterior segment of nasal cavity extending up to the limen nasi. It is covered by squamous epithelium which changes to ciliary epithelium at the limen. A B
- 9 **Limen nasi.** Ridge at the end of the vestibule produced by the margin of the alar cartilage. A B
- 10 **Olfactory sulcus.** Sulcus olfactorius. Groove on the olfactory area passing between the roof of the middle nasal concha and the bridge of the nose. A B
- 11 **Superior nasal concha (turbinate).** Concha nasalis superior. Small, upper concha situated in front of the sphenoidal sinus. A B
- 12 **Middle nasal concha (turbinate).** Concha nasalis media. Most of the openings of the paranasal sinuses lie below it. A B
- 13 **Inferior nasal concha (turbinate).** Concha nasalis inferior. Lowest and longest of the nasal conchae. It covers the opening of the nasolacrimal duct. A B
- 14 **[[Tunica mucosa nasi]].** Nasal mucous membrane consisting primarily of pseudostratified ciliated columnar epithelium with goblet cells.
- 15 **Respiratory region.** Regio respiratoria. Part of the nasal mucosa with ciliated epithelium. It begins in the vestibule and lines the entire nasal cavity except for the olfactory region.
- 16 **Olfactory region.** Regio olfactoria. Area about the size of a nickel containing olfactory cells; it is located superiorly on the nasal septum and on the lateral nasal wall below the cribriform plate. A
- 16a **Nasal (olfactory) glands.** Glandulae nasales. Predominantly serous, tubular glands. Their thin secretions cleanse the olfactory epithelium and can enhance odorous substances.
- 17 **Cavernous plexus of concha.** Plexus cavernosi concharum. Venous plexuses especially prevalent in the region of the inferior concha and posterior nasal cavity.
- 18 **Agger nasi.** Ridge-like elevations comprising the remains of an earlier accessory concha directly in front of the middle nasal concha. A
- 19 **Sphenoethmoidal recess.** Recessus sphenoethmoidalis. Recess above the superior nasal concha between the anterior wall of the sphenoidal sinus and the roof of the nasal cavity. A
- 20 **Superior nasal meatus.** Meatus nasi superior. Nasal passage above the middle nasal concha. A
- 21 **Middle nasal meatus.** Meatus nasi medius. Nasal passage between the middle and inferior nasal concha. A
- 22 **Atrium of middle meatus.** Atrium meatus medii. Area at the beginning of the middle meatus in front of the middle and above the inferior concha. A
- 23 **Inferior nasal meatus.** Meatus nasi inferior. Lower nasal passage between the inferior nasal concha and the floor of the nasal cavity. A
- 23a **Aperture of nasolacrimal duct.** Apertum ductus nasolacrimalis. Opening of the nasolacrimal duct provided with a flap-like mucosal fold. See p. 364.23
- 24 **Nasopharyngeal meatus.** Meatus nasopharyngeus. Junction of the three nasal passages behind the conchae. A
- 25 **Incisive duct.** [Ductus incisivus]. Blind sac occasionally present on the floor of the nasal cavity near the septum, about 2 cm behind the external nasal opening. A



A Lateral nasal wall with sphenoidal sinus

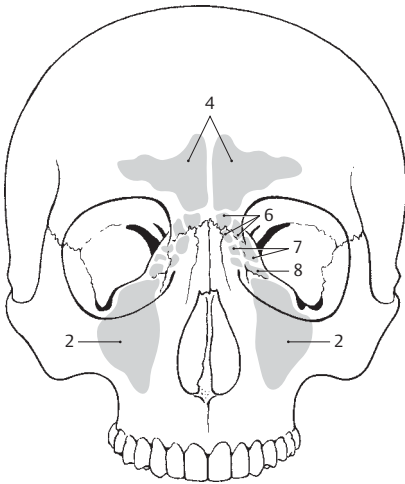


B Lateral nasal wall

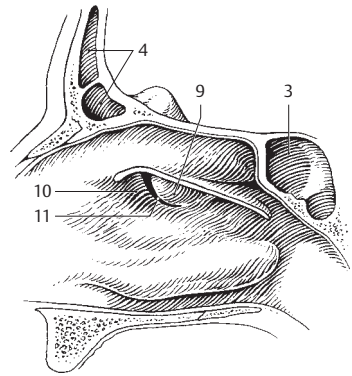


C Nasal septum

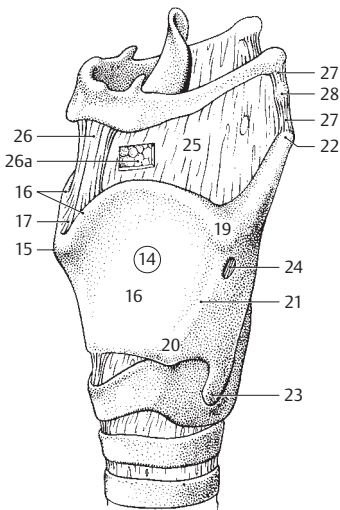
- 1 **Paranasal sinuses.** Sinus paranasales. A B
- 2 **Maxillary sinus.** Sinus maxillaris. Situated below the orbit and lateral to the nose, it opens below the middle nasal concha. A
- 3 **Sphenoidal sinus.** Sinus sphenoidalis. Paired sinus within the sphenoid bone behind the sphenothmoidal recess and above the nasopharyngeal cavity; it opens into the sphenothmoidal recess. B
- 4 **Frontal sinus.** [[Cellulae ethmoidales]]. Sinus frontalis. Sinus in the squama of the frontal bone and often also in the orbital part, it opens below the middle concha. A B
- 5 **Ethmoidal sinuses.** Sinus ethmoidales. System of cavities with pea-sized air cells between the nasal cavity and orbit. It is divided into the following parts. A
- 6 **Anterior sinus.** Sinus anteriores. Anterior group of ethmoidal air cells which opens below the middle nasal concha. A
- 7 **Middle sinus.** Sinus medii. Middle group of ethmoidal air cells which opens below the middle nasal concha. A
- 8 **Posterior sinus.** Sinus posteriores. Posterior group of ethmoidal air cells which opens below the superior nasal concha. A
- 9 **Ethmoidal bulla.** Bulla ethmoidalis. Rudimentary nasal concha in the form of a vesicular, bulging ethmoidal air cell located below the middle nasal concha. B
- 10 **Infundibulum ethmoidale.** Recess in front of the ethmoidal bulla in the middle nasal meatus. It receives the openings of the maxillary and frontal sinuses. B
- 11 **Hiatus semilunaris.** Semilunar fissure between the ethmoidal bulla and the uncinate process. B
- 12 **LARYNX.** It lies between the pharynx and trachea. C
- 13 **LARYNGEAL CARTILAGES AND JOINTS.** Cartilagine et articulationes laryngeales.
- 14 **Thyroid cartilage.** Cartilago thyroidea. Largest laryngeal cartilage that partially encloses the others. C D
- 15 **Laryngeal prominence.** Prominentia laryngea. Prominence in the midline of the neck produced by the thyroid cartilage. It is more pronounced in males (Adam's apple). C D
- 16 **Right/left lamina.** Lamina dextra/sinistra. Lateral plates of the thyroid cartilage meeting in the midline like the bow of a ship. C D
- 17 **Superior thyroid notch.** Incisura thyroidea superior. Deep, median notch in the upper portion of the thyroid cartilage, between the right and left thyroid laminae. C D
- 18 **Inferior thyroid notch.** Incisura thyroidea inferior. Shallow median notch at the lower margin of the thyroid cartilage. D
- 19 **Superior thyroid tubercle.** Tuberculum thyroideum superior. Small lateral prominence on the outside of the thyroid lamina at the upper end of the oblique line. C D
- 20 **Inferior thyroid tubercle.** Tuberculum thyroideum inferius. Small lateral prominence at the lower end of the oblique line. C D
- 21 **Oblique line.** Linea obliqua. Oblique ridge on the outside of the thyroid cartilage for the attachment of the sternothyroid and thyrohyoid muscles and the inferior constrictor muscle of the pharynx. C D
- 22 **Superior horn (cornu).** Cornu superius. Superior process of thyroid cartilage. It serves for the attachment of the thyrohyoid ligament. C D
- 23 **Inferior horn (cornu).** Cornu inferius. Inferior process of posterior margin of thyroid cartilage for articular connection with the cricoid cartilage. C D
- 24 **Thyroid foramen.** [Foramen thyroideum]. Hole occasionally present laterally below the superior tubercle for passage of the superior laryngeal artery and vein. C
- 25 **Thyrohyoid membrane.** Membrana thyrohyoidea. Membrane rich in elastic fibers between the upper posterior margin of the hyoid bone and the thyroid cartilage. C
- 26 **Median thyrohyoid membrane.** Lig. thyrohyoideum medianum. Median reinforcement of the thyrohyoid membrane with abundant elastic fibers. C
- 26a **Pre-epiglottic fat body.** Corpus adiposum prae-epiglotticum. Space-filling adipose body between epiglottis, thyrohyoid membrane and hyo-epiglottic ligament. C See 143 C
- 27 **Lateral thyrohyoid ligament.** Ligamentum thyrohyoideum laterale. Ligament extending from the superior horn to the posterior end of the greater horn of the hyoid bone. It provides lateral reinforcement for the thyrohyoid membrane. C
- 28 **Cartilago triticea.** Elastic cartilage, the size of a grain of wheat, in the thyrohyoid ligament. C



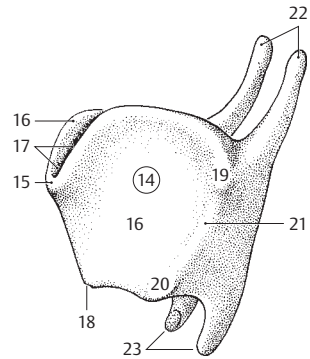
A Paranasal sinuses without sphenoidal sinus



B Lateral nasal wall without middle nasal concha

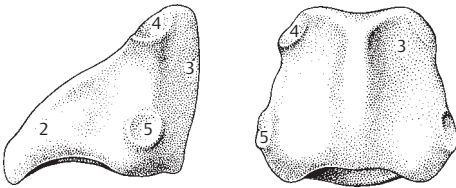


C Larynx

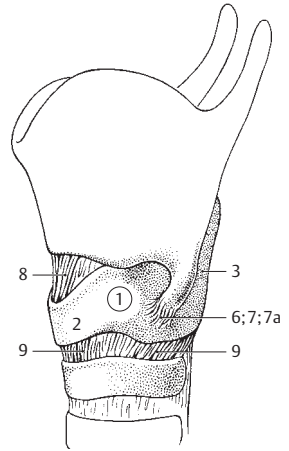


D Thyroid cartilage

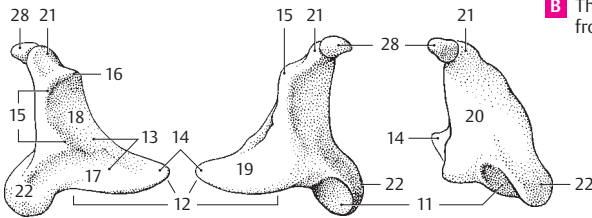
- 1 **Cricoid cartilage.** Cartilago cricoidea. Ring of cartilage lying at the upper end of the trachea that articulates with the thyroid cartilage. A B D
- 2 **Arch of cricoid cartilage.** Arcus cartilaginis cricoideae. Anterior and lateral parts of cricoid cartilage. A B
- 3 **Lamina of cricoid cartilage.** Lamina cartilaginis cricoideae. Tall posterior plate of the cricoid cartilage. A B
- 4 **Articular surface for arytenoid cartilage.** Facies articularis arytenoidea. Oblique, oval articular facet for the arytenoid cartilage located laterally at the upper margin of the cricoid lamina. A
- 5 **Articular surface for thyroid cartilage.** Facies articularis thyroidea. Somewhat prominent articular facet for the thyroid cartilage situated inferiorly on the lateral margin of the lamina. A
- 6 **Cricothyroid joint.** Articulatio cricothyroidea. Articulation between the thyroid and cricoid cartilages. It permits tilting movements as well as horizontal and vertical gliding movements. B
- 7 **Cricothyroid joint capsule.** Capsula articularis cricothyroidea. Thin articular capsule. B
- 7a **Ceratocricoid ligament.** Lig. ceratocricoidaeum. Capsular reinforcement for limitation of shearing movements. B
- 8 **Median cricothyroid ligament.** Lig. cricothyroideum medianum. Strong vertical ligament in the midline between the thyroid and cricoid cartilages. B D
- 9 **Cricotracheal ligament.** Lig. cricotracheale. Elastic membrane between the cricoid cartilage and the first tracheal cartilage. B D
- 10 **Arytenoid cartilage.** Cartilago arytenoidea. Pyramid-like cartilage on the cricoid cartilage. C D
- 11 **Articular surface.** Facies articularis. Cylindrical, concave joint surface below the muscular process for articulation with the cricoid. C
- 12 **Base of arytenoid.** Basis cartilaginis arytenoideae. Undersurface of arytenoid cartilage. C
- 13 **Anterolateral surface.** Facies anterolateralis. Surface directed anterolaterally for muscular insertion and origin. C
- 14 **Vocal process.** Processus vocalis. Anteriorly directed process for attachment of the vocal ligament. C
- 15 **Arcuate crest.** Crista arcuata. Cartilaginous ridge which begins between the oblong and triangular foveae, arches around the triangular fovea and ends at the colliculus. C
- 16 **Colliculus.** Small projection at the end of the arcuate crest. C D
- 17 **Oblong fovea.** Fovea oblonga. Depression on the anteroinferior surface of the arytenoid cartilage for attachment of the thyroarytenoid muscle. C
- 18 **Triangular fovea.** Fovea triangularis. Gland-filled depression above the oblong fovea. C
- 19 **Medial surface.** Facies medialis. C
- 20 **Posterior surface.** Facies posterior. C
- 21 **Apex of arytenoid cartilage.** Apex cartilaginis arytenoideae. It arches posteriorly from the arytenoid cartilage. C D
- 22 **Muscular process.** Processus muscularis. Short process that projects posterolaterally from the arytenoid cartilage for attachment of the posterior and lateral cricoarytenoid muscles. C
- 23 **Cricoarytenoid joint.** Articulatio cricoarytenoidea. Cylindrical joint between the cricoid and arytenoid cartilages. It permits oscillating movements around an obliquely placed cylindrical axis and gliding movements parallel to the axis. D
- 24 **Articular capsule of cricoarytenoid joint.** Capsula articularis cricoarytenoidea. Thin-walled, flaccid capsule of joint between cricoid and arytenoid cartilages. D
- 25 **Cricoarytenoid ligament.** Lig. cricoarytenoideum. Important elastic ligament for the closure of the rima glottidis. It passes posteriorly from the cricoid lamina to the medial part of the arytenoid. D
- 26 **Cricopharyngeal ligament.** Lig. cricopharyngeum. Fiber tract beginning at the corniculate cartilage. After attachment to the posterior side of the cricoid, it passes beneath the overlying pharyngeal mucosa. D
- 27 **Sesamoid cartilage.** [Cartilago sesamoidea]. Piece of elastic cartilage occasionally present in the anterior end of the vocal ligament and near the arytenoid cartilage. D
- 28 **Corniculate cartilage.** Cartilago corniculata [[Santorini]]. Small elastic cartilage at the apex of the arytenoid cartilage. It produces the corniculate tubercle. C D
- 29 **Corniculate tubercle.** Tuberculum conicatum. Mucosa-covered prominence over the corniculate cartilage directly above the apex of the arytenoid cartilage. See page 142.9



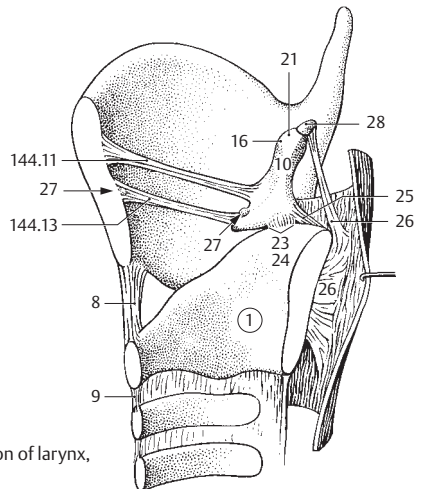
A Cricoid cartilage, left and posterior view



B Thyroid and cricoid cartilages from left

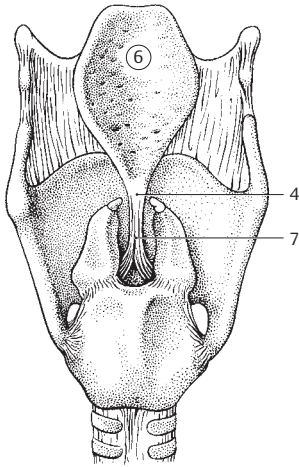


C Right arytenoid cartilage, lateral, medial and posterior views

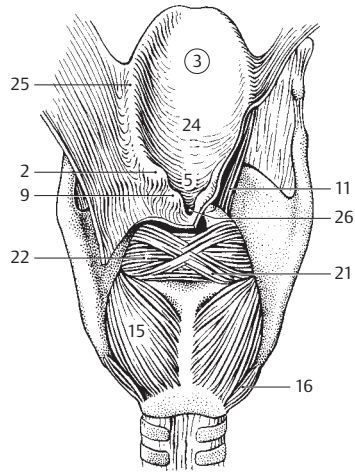


D Sagittal section of larynx, medial view

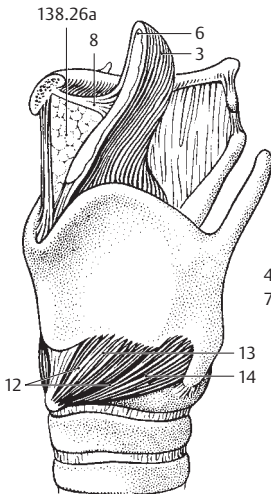
- 1 **Cuneiform cartilage.** Cartilago cuneiformis. Variably small cartilage beneath a small group of glands in the aryepiglottic fold. D
- 2 **Cuneiform tubercle.** Tuberculum cuneiforme. Prominence in the aryepiglottic fold caused by the cuneiform cartilage. If the cartilage is absent, it can also be produced by glands. B D
- 3 **Epiglottis.** Elastic cartilage shaped like a shoe-horn. B C E
- 4 **Stalk of epiglottis.** Petiolus epiglottidis. Downward pointing end of the epiglottic cartilage that is attached to the thyroid cartilage by connective tissue. A D
- 5 **Epiglottic tubercle.** Tuberculum epiglotticum. Small prominence at the posterior surface of the mucosa above the stalk. B
- 6 **Epiglottic cartilage.** Cartilago epiglottica. Skeleton of epiglottis consisting of elastic cartilage. A C D
- 7 **Thyroepiglottic ligament.** Lig. thyroepiglotticum. Ligament attaching the stalk of the epiglottis to the posterior surface of the thyroid cartilage. A D
- 8 **Hyoepiglottic ligament.** Lig. hyoepiglotticum. Ligament between the hyoid and epiglottis. C
- 9 **Corniculate tubercle.** Tuberculum corniculatum. Mucosa-covered prominence over the corniculate cartilage just above the apex of the arytenoid cartilage. B D
- 10 **Laryngeal musculature.** Musculi laryngis. B C D E
- 11 **[[M. aryepiglotticus]].** Now the aryepiglottic part of the arytenoid muscle. See p. 21 a. B D
- 12 **M. cricothyroideus.** o: Anterolateral aspect of cricoid cartilage. i: Interiorly at outer and inner surfaces of the thyroid cartilage lamina. A: Tenses vocal ligament by lifting the cricoid cartilage forward and tilting back the lamina and the arytenoid cartilage. I: Superior laryngeal nerve (different innervation than other intrinsic laryngeal muscles). C E
- 13 **Straight part.** Pars recta. Anterior, somewhat more steeply coursing fibers. C
- 14 **Oblique part.** Pars obliqua. Posterior, more horizontally coursing fibers. C
- 15 **Posterior cricoarytenoid muscle.** M. cricoarytenoideus posterior. o: Posterior surface of cricoid cartilage. i: Muscular process of arytenoid cartilage. A: By swinging the vocal process upward and outward, it opens the rima glottidis. It is the only abductor of the vocal folds. I: Recurrent laryngeal nerve. B D
- 16 **Ceratocricoid muscle.** [M. ceratocricoides]. Anatomic variant. o: Inferior horn of thyroid cartilage. i: Inferior margin of cricoid cartilage. I: Recurrent laryngeal nerve. B
- 17 **Lateral cricoarytenoid muscle.** M. cricoarytenoideus lateralis. o: Upper lateral margin of cricoid cartilage. i: Anteriorly at muscular process of arytenoid cartilage and adjacent area. A: Synergist in closing of rima glottidis. I: Recurrent laryngeal nerve. D
- 18 **M. vocalis.** o: Inner surface of thyroid cartilage near the midline. i: Vocal process and oblong fovea of arytenoid cartilage. A: By its tension it alters the intrinsic vibrations of the vocal cord. I: Recurrent laryngeal nerve. E
- 19 **Thyroepiglottic muscle.** [[M. thyroepiglotticus]]. Now the thyroepiglottic part of the thyroarytenoid muscle. See p. 20 D
- 20 **Thyroarytenoid muscle.** M. thyroarytenoideus. o: Anterior inner surface of thyroid cartilage. i: Muscular process and lateral surface of arytenoid cartilage. A: Synergist in closure of rima glottidis. I: Recurrent laryngeal nerve. D E
- 20a **Thyroepiglottic part.** Pars thyroepiglottica. o: Anterior, inner surface of thyroid cartilage. i: Epiglottis and quadrangular membrane. I: Recurrent laryngeal nerve. D See p. 19.
- 21 **Oblique arytenoid muscle.** M. arytenoideus obliquus. o: Posterior surface of muscular process. i: Apex of contralateral arytenoid cartilage. A: Draws the arytenoid cartilages closer together. Synergist in closure of rima glottidis. I: Recurrent laryngeal nerve. B
- 21a **Aryepiglottic part.** Pars aryepiglottica. o: Apex of arytenoid cartilage. i: Margin of epiglottis. Foundation of aryepiglottic fold. A: Depresses the epiglottis. See 11.
- 22 **Transverse arytenoid muscle.** M. arytenoideus transversus. o: Posterior surface of arytenoid cartilage. i: Same surface of contralateral arytenoid cartilage. A: Approximates arytenoid cartilages. Synergist in closure of rima glottidis. I: Recurrent laryngeal nerve. B
- 23 **Laryngeal cavity.** Cavitas laryngis. E
- 24 **Laryngeal inlet (aditus).** Aditus laryngis. Entrance into larynx between the epiglottis, aryepiglottic folds and interarytenoid notch. B E
- 25 **Aryepiglottic fold.** Plica aryepiglottica. Mucosal fold over the aryepiglottic muscle. It extends from the apex of the arytenoid cartilage to the lateral margin of the epiglottis. B D
- 26 **Interarytenoid notch.** Incisura interarytenoidea. Mucosa-covered slit between the two apices of the arytenoids. B
- 27 **Vestibule of larynx.** Vestibulum laryngis. Upper part of laryngeal cavity extending as far as the vestibular [ventricular] folds. E
- 28 **Rima vestibuli.** Interval between the two vestibular folds. E
- 29 **Vestibular (ventricular) fold.** Plica vestibularis [ventricularis]. Fold produced by the vestibular ligament. It lies between the laryngeal ventricle and vestibule. E
- 29a **Intermediate laryngeal cavity.** Cavitas laryngis intermedia. Space between the vestibular and vocal folds.



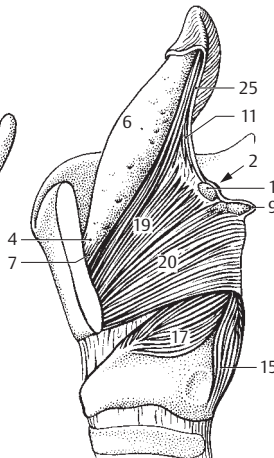
A Laryngeal cartilages, posterior view



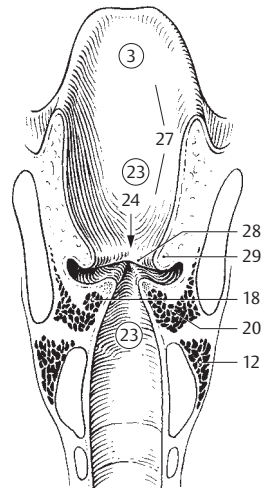
B Laryngeal musculature, posterior view



C Larynx, anterolateral view

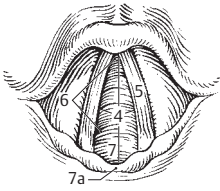


D Larynx, left lamina of thyroid cartilage removed

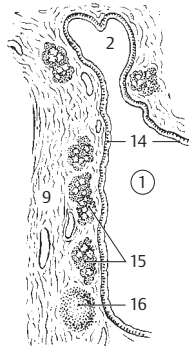


E Larynx, frontal section, posterior view

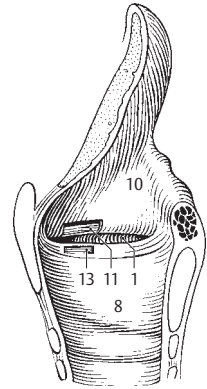
- 1 **Ventricle of larynx.** Ventriculus laryngis [[Morgagni]]. Lateral outpocketings between the vocal and vestibular folds. B C D
- 2 **Sacculæ (appendix) of larynx.** Sacculus laryngis [[appendix ventriculi laryngis]]. Small blind sac directed upward from the ventricle. B
- 3 **Glottis.** Voice-producing part of the larynx consisting of the two vocal folds and the interval (Rima glottidis) between them. A
- 4 **Rima glottidis.** Space between the two arytenoid cartilages and the vocal cords. A
- 5 **Vocal fold.** Plica vocalis. Mucosal fold supported by the underlying vocal ligament and laterally by the vocalis muscle. A
- 6 **Intermembranacea part.** Pars intermembranacea. Portion of the rima glottidis extending from the thyroid cartilage to the apex of the vocal process. A
- 7 **Intercartilaginous part.** Pars intercartilaginea. Portion of rima glottidis between the arytenoid cartilages. A
- 7a **Interarytenoid fold.** Plica interarytenoidea. Mucosal fold between the arytenoid cartilages. A
- 8 **Infraglottic cavity.** Cavitas infraglottica. Lowest portion of laryngeal cavity. It is enclosed by the conus elasticus and extends from the rima glottidis to the trachea. C
- 9 **Fibroelastic membrane of larynx.** Membrana fibroelastica laryngis [[membrana elastica laryngis]]. Submucosa of laryngeal wall provided with abundant elastic fibers. It begins at the quadrangular membrane and ends at the lower margin of the conus elasticus. B
- 10 **Quadrangular membrane.** Membrana quadrangularis. Membrane spread out between the epiglottis, aryepiglottic fold and vestibular fold. C D
- 11 **Vestibular ligament.** Lig. vestibulare. It strengthens the lower margin of the quadrangular membrane. C
- 12 **Conus elasticus (membrana cricovocalis).** Reinforced fibroelastic membrane between the vocal ligament and cricoid. D
- 13 **Vocal ligament.** Lig. vocale. It lies between the vocal process of the arytenoid cartilage and the thyroid cartilage and forms the upper end of the conus elasticus. C
- 14 **Tunica mucosa.** Laryngeal mucous membrane provided with nonkeratinized, stratified squamous epithelium only on the upper part of the posterior surface of the epiglottis and on the vocal folds; the rest of the larynx is lined with pseudostratified, ciliated columnar epithelium with goblet cells. B
- 15 **Laryngeal glands.** Gl. laryngeales. Mixed glands occupying the submucosa of the laryngeal wall. B
- 16 **Lymph nodes of larynx.** [[Nodi lymphatici laryngis]]. Lymphatic nodules are abundant in the submucosa of the ventricle. B
- 17 **TRACHEA.** Airway characterized by its cartilage-containing wall and its branches, the bronchi. E
- 18 **Cervical part.** Pars cervicalis. The cervical segment of the trachea extending from C6 to C7.
- 19 **Thoracic part.** Pars thoracica. The thoracic segment extending from T1 to T4.
- 20 **Tracheal cartilages.** Cartilagines tracheales. Horseshoe-shaped cartilages of the tracheal wall. E F H
- 21 **Tracheal muscle.** Musculus trachealis. Smooth muscle between the free ends of the horseshoe-shaped tracheal cartilages. H
- 22 **Annular ligaments of trachea.** Ligg. anularia tracheae, Ligg. trachealia. Connective tissue bridges between the tracheal cartilages. E F
- 23 **Membranous wall.** Parietes membranaceus. Posterior wall of trachea. F
- 24 **Bifurcation of trachea.** Bifurcatio tracheae [[trachealis]]. Asymmetrical division of trachea at level of T4. E G
- 25 **Carina tracheae.** Ridge projecting into the lumen of the trachea at its bifurcation and providing an aerodynamic effect. G
- 26 **Tunica mucosa.** Tracheal mucosa lined by pseudostratified ciliated columnar epithelium with goblet cells. H
- 27 **Tracheal glands.** Gl. tracheales. Mixed glands in the submucosa. H
- 28 **BRONCHI.** Branches of trachea.
- 29 **Bronchial tree.** Arbor bronchialis. The entire branching system of the bronchi.
- 30 **MAIN BRONCHUS (RIGHT AND LEFT).** Bronchus principalis (dexter et sinister). Right and left stem bronchi arising directly from the trachea. E



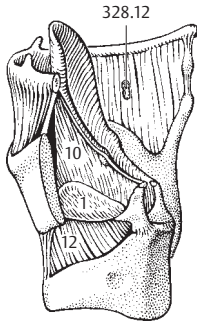
A Entrance to larynx from above



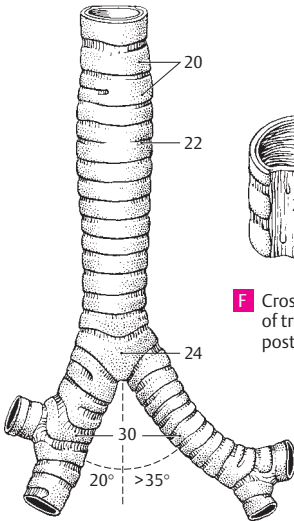
B Laryngeal ventricle



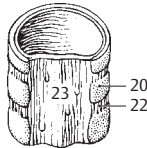
C Sagittal section of larynx



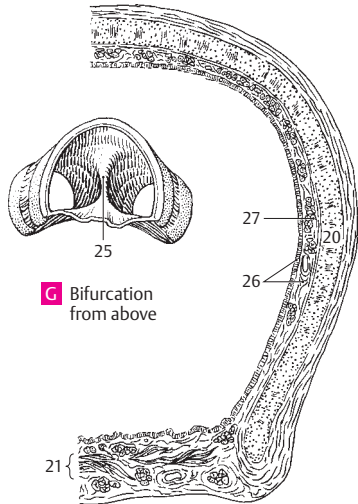
D Larynx, posterolateral view, left lamina of thyroid cartilage removed



E Trachea and bronchi from front



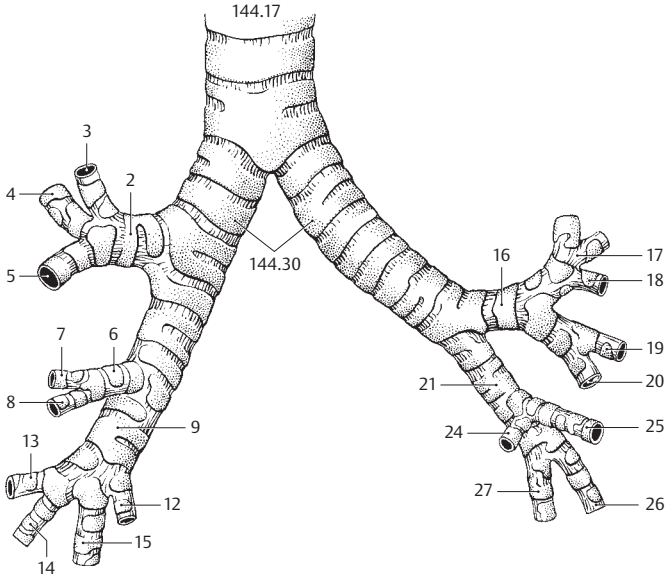
F Cross section of trachea, posterior view



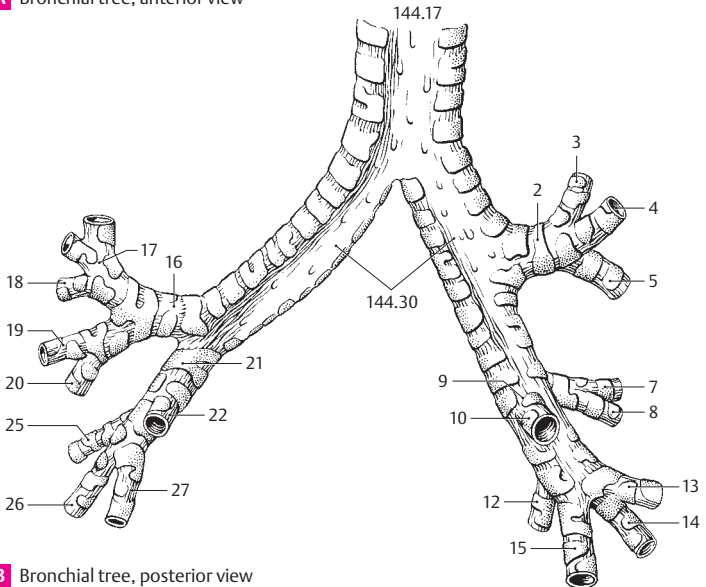
G Bifurcation from above

H Cross section of trachea, histologic section

- 1 **Lobar and segmental bronchi.** Bronchi lobares et segmentales. Bronchi for the five lobes of the lung and their 20 segments. A B
- 2 **Right superior lobar bronchus.** Bronchus lobaris superior dexter. Bronchus for the superior lobe of the right lung. It arises just after the tracheal bifurcation. A B
- 3 **Apical segmental bronchus (B I).** Bronchus segmentalis apicalis. Bronchus for the apical segment extending inferiorly as far as the 3rd rib. A B
- 4 **Posterior segmental bronchus (B II).** Bronchus segmentalis posterior. Bronchus for the posterior segment extending forward about as far as the midaxillary line. A B
- 5 **Anterior segmental bronchus (B III).** Bronchus segmentalis anterior. Bronchus for the anterior segment extending backward about as far as the midaxillary line. A B
- 6 **Right middle lobar bronchus.** Bronchus lobaris medius dexter. Lobar bronchus for the middle lobe of the right lung. A
- 7 **Lateral segmental bronchus (B IV).** Bronchus segmentalis lateralis. Bronchus for the lateral segment located on the dorsal surface of the middle lobe. A B
- 8 **Medial segmental bronchus (B V).** Bronchus segmentalis medialis. Segmental bronchus arising anteromedially from the middle lobe. A B
- 9 **Right inferior lobar bronchus.** Bronchus lobaris inferior dexter. Lobar bronchus for the right inferior lobe extending posteriorly up to the 4th rib. A B
- 10 **Superior segmental bronchus (B VI).** Bronchus segmentalis superior. Bronchus for the apical segment which borders only on the upper lobe. B
- 11 **Subapical segmental bronchus.** [[Bronchus segmentalis subapicalis]]. Occasionally present accessory bronchus.
- 12 **Medial basal segmental bronchus (B VII).** Bronchus segmentalis basalis medialis (cardiacus). Bronchus for the medial segment that does not reach the external surface of the lower lobe. A B
- 13 **Anterior basal segmental bronchus (B VIII).** Bronchus segmentalis basalis anterior. Bronchus for the wedge-shaped anterior end of the lower lobe. A B
- 14 **Lateral basal segmental bronchus (B IX).** Bronchus segmentalis basalis lateralis. Bronchus for the small lateral segment situated between the anterior and posterior segments. A B
- 15 **Posterior basal segment bronchus (B X).** Bronchus segmentalis basalis posterior. Bronchus for the segment extending posteriorly up to the vertebral column. A B
- 16 **Left inferior lobar bronchus.** Bronchus lobaris superior sinister. Lobar bronchus for the left upper lobe. A B
- 17 **Apicoposterior segmental bronchus (B I + II).** Bronchus segmentalis apicoposterior. Bronchus for the left apical segment located posterosuperiorly. A B
- 18 **Anterior segmental bronchus (B III).** Bronchus segmentalis anterior. Bronchus for the anterior segment of the left upper lobe situated in front of the apical segment. A B
- 19 **Superior lingular bronchus (B IV).** Bronchus lingularis superior. Bronchus for the second lowest segment of the left upper lobe extending posteriorly as far as the border of the lower lobe. A B
- 20 **Inferior lingular bronchus (B V).** Bronchus lingularis inferior. Bronchus for the mainly anterior lowest segment of the upper lobe. A B
- 21 **Left inferior lobar bronchus.** Bronchus lobaris inferior sinister. Lobar bronchus for the left lower lobe extending dorsally up to the 4th thoracic vertebra. A B
- 22 **Superior segmental bronchus (B VI).** Bronchus segmentalis superior. Bronchus for the apical segment located posterosuperiorly in the lower lobe. B
- 23 **Subapical segmental bronchus.** [[Bronchus segmentalis subapicalis]]. Bronchus for an occasionally present accessory segment.
- 24 **Medial basal segmental bronchus (B VII).** Bronchus segmentalis basalis medialis (cardiacus). Bronchus for the medial basal segment which does not reach the lateral lung surface. A
- 25 **Anterior basal segmental bronchus (B VIII).** Bronchus segmentalis basalis anterior. Bronchus for the anterior basal segment adjoining the lower anterior border. A B
- 26 **Lateral basal segmental bronchus (B IX).** Bronchus segmentalis basalis lateralis. Bronchus for the basal middle segment located between the anterior and posterior basal segments. A B
- 27 **Bronchus segmentalis basalis posterior (B X).** Bronchus for the posterior basal segment of the lower lobe situated below the apical segment. A B

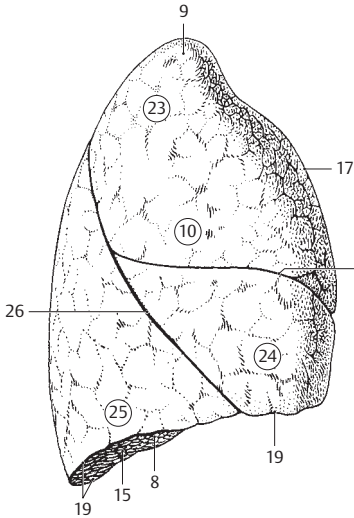


A Bronchial tree, anterior view

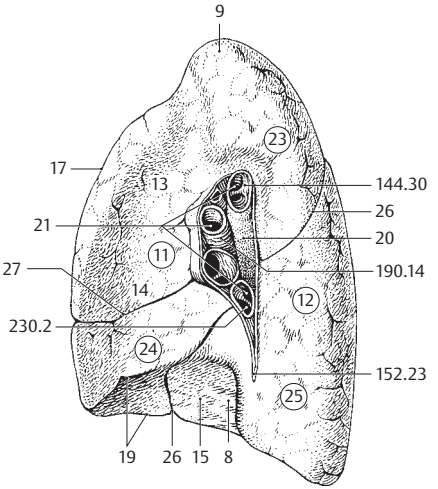


B Bronchial tree, posterior view

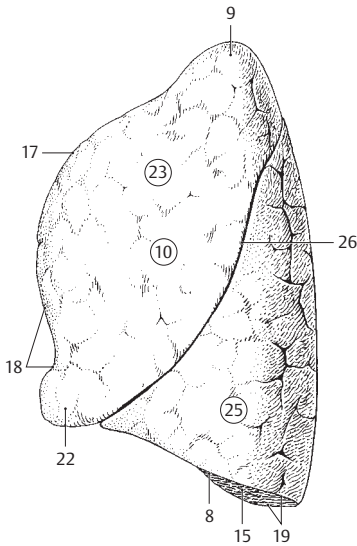
- 1 **Segmental bronchial branches.** Rami bronchiales segmentorum. Branches of individual segmental bronchi.
- 2 **Tunica muscularis.** Muscle layer in the wall of the bronchus.
- 3 **Tela submucosa.** Connective tissue layer beneath the bronchial mucosa.
- 4 **Tunica mucosa.** Mucous membrane of the bronchi lined by ciliated columnar epithelium.
- 5 **Bronchial glands.** Gll. bronchiales. Mixed glands located below the mucosa.
- 6 **LUNGS.** Pulmones. They occupy the greater portion of the thoracic space. A B C D
- 7 **RIGHT/LEFT LUNGS.** Pulmo dexter/sinister. Right lobes are larger; left lobes smaller (10%). A B C D
- 8 **Base of lung.** Basis pulmonis (pulmonalis). Lower lung segment bordering on the diaphragm. A B C D
- 9 **Apex of lung.** Apex pulmonis (pulmonalis). Apical portion of the lung partially occupying the superior thoracic aperture. A B C D
- 10 **Costal surface.** [[Facies costalis]]. Lung surface bordering the ribs. A C
- 11 **Medial surface.** [[Facies medialis]]. Medial lung surface facing the mediastinum. B D
- 12 **Vertebral part.** Pars vertebralis. Dorsal portion of medial surface of each lung adjacent to the vertebral column. B D
- 13 **Mediastinal surface.** Facies mediastinalis. Lung surface bordering the mediastinum and lying in front of the vertebral part. B D
- 14 **Cardiac impression of lung.** Impressio cardiaca. Indentation on the medial surface of both lungs produced by the heart. B D
- 15 **Diaphragmatic surface.** Facies diaphragmatica. Concave inferior surface of the lung facing the diaphragm. A B C D
- 16 **Interlobar surface.** Facies interlobaris. Surface of lung tissue found in the spaces between the lobes.
- 17 **Anterior margin.** Margo anterior. Sharp anterior border at the junction of the medial and costal surfaces of the lung. A B C D
- 18 **Cardiac notch.** Incisura cardiaca [pulmonis sinistri]. Notch on the anterior margin of the left upper lobe produced by the cardiac impression. C D
- 19 **Margo inferior.** Inferior margin of lung. Sharp border at the junction of the costal and diaphragmatic surfaces. The margin is less sharp at the transition of the diaphragmatic surface to the medial surface. A B C D
- 20 **Hilum of lung.** Hilum pulmonis. Site of entry of bronchi and vessels on the medial surface. Essentially, the bronchi lie posteriorly, the pulmonary artery cranial and the pulmonary veins caudad. B D
- 21 **Root of lung.** Radix [pediculus] pulmonis. It consists of the main bronchus, blood vessels, lymph vessels/nodes and autonomic plexuses. B
- 22 **Lingula of left lung.** Lingula pulmonis sinistri. Portion of the upper lobe of the left lung between the cardiac notch and the oblique fissure. C D
- 22a **Culmen of left lung.** Culmen pulmonis sinistri. Upper lobe without lingula.
- 23 **Upper lobe.** Lobus superior. Extends posteriorly as far as the 4th rib. On the right side its lower border runs anteriorly somewhat along the 4th rib. On the left side it passes as far as the cartilage-bone border of the 6th rib. A B C D
- 24 **Middle lobe.** Lobus medius (pulmonis dextri). Present only in the right lung, it lies in front of the midaxillary line between the 4th and 6th ribs. A B
- 25 **Lower lobe.** Lobus inferior. It extends mainly dorsal. Its superior border courses obliquely posterosuperior to anteroinferior. It begins paravertebrally at the 4th rib and ends at the intersection of the midclavicular line and the 6th rib. A B C D
- 26 **Oblique fissure.** Fissura obliqua. Oblique fissure between the lower and upper lobes of the left lung, between the lower and upper lobes, as well as the middle lobe, of the right lung. Accordingly, it passes paravertebrally from the 4th rib up to the 6th rib in the midclavicular line. A B C D
- 27 **Horizontal fissure of right lung.** Fissura horizontalis (pulmonis dextri). Fissure separating the middle and upper lobes at the level of the 4th rib. A B



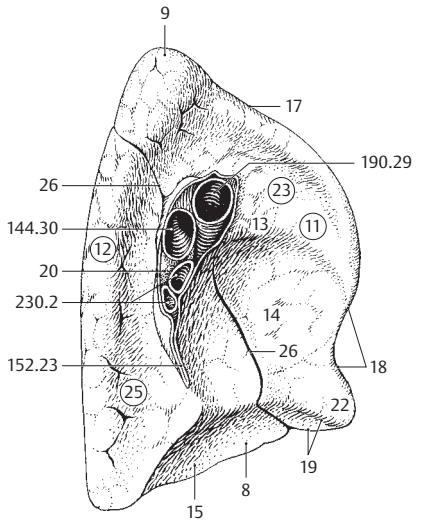
A Right lung, lateral view



B Right lung, medial view

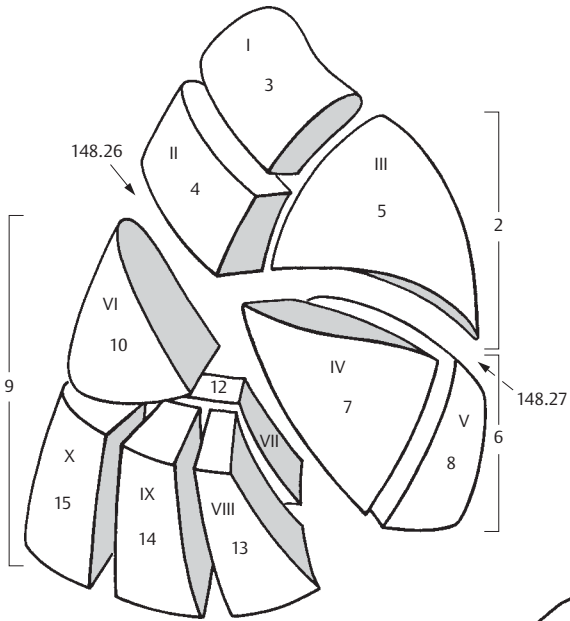


C Left lung, lateral view

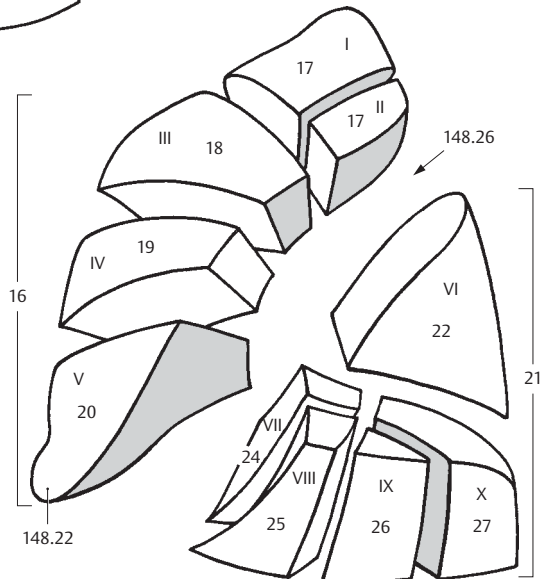


D Left lung, medial view

- 1 **BRONCHOPULMONARY SEGMENTS.** Segmenta bronchopulmonalia. Lung segments supplied by individual bronchi and arteries and separated by veins and connective tissue septa. A B
- 2 **Upper lobe of right lung.** (According to Dordland's lobus superior pulmonis dextri). Pulmo dexter, lobus superior. A
- 3 **Apical segment of upper lobe of right lung.** Segmentum apicale (S I). It is inserted like a wedge between the anterior and posterior segments. A
- 4 **Posterior segment of upper lobe of right lung.** Segmentum posterius (S II). It lies between the apical segment and the lower lobe. A
- 5 **Anterior segment of upper lobe of right lung.** Segmentum anterius (S III). It lies between the apical segment and the middle lobe. A
- 6 **Middle lobe of right lung.** (Lobus medius pulmonis dextri). Pulmo dexter, lobus medius. A
- 7 **Lateral segment of middle lobe.** Segmentum laterale (S IV). It occupies the dorsal portion of the middle lobe and does not reach the hilum. A
- 8 **Medial segment of middle lobe.** Segmentum mediale (S V). It forms the medial and diaphragmatic surfaces of the middle lobe. A
- 9 **Lower lobe of right lung.** (Lobus inferior pulmonis dextri). Pulmo dexter, lobus inferior. A
- 10 **Superior segment.** Segmentum superius (S VI). Posterosuperiorly situated apical portion of lower lobe. A
- 11 **Subapical segment.** [[Segmentum subapicale]]. An accessory segment occasionally present below the superior segment.
- 12 **Medial basal (cardiac) segment (S VII).** Segmentum basale mediale (cardiacum). It does not reach the lateral surface of the lung and is only seen from the medial and inferior surfaces. A
- 13 **Anterior basal segment (S VIII).** Segmentum basale anterius. It lies between the middle lobe and diaphragm. A
- 14 **Lateral basal segment (S IX).** Segmentum basale laterale. It lies between the posterior and anterior basal segments. A
- 15 **Posterior basal segment (S X).** Segmentum basale posterius. Located between the vertebral column and lateral basal segment. A
- 16 **Upper lobe of left lung.** (Lobus superior pulmonis sinistri). Pulmo sinister, lobus superior. B
- 17 **Apicoposterior segment (S I + II).** Segmentum apicoposterius. It comprises two wedge-shaped segments (apical and posterior) which lie between the oblique fissure and the anterior segment of the upper lobe. B
- 18 **Anterior segment (S III) of upper lobe.** Segmentum anterius. It lies between the superior lingular and apicoposterior segments. B
- 19 **Superior lingular segment (S IV).** Segmentum lingulare superius. It lies predominantly on the inferior lingular segment. B
- 20 **Inferior lingular segment (S V).** Segmentum lingulare inferius. It lies between the superior lingular segment and the oblique fissure. B
- 21 **Lower lobe of left lung.** (Lobus inferior pulmonis sinistri). Pulmo sinister, lobus inferior. B
- 22 **Superior segment (S VI).** Segmentum superius. Apical portion of lower lobe situated posterosuperiorly near the vertebral column. B
- 23 **Subapical segment.** [[Segmentum subapicale]]. Accessory segment occasionally present below the superior segment of the lower lobe.
- 24 **Medial basal (cardiac) segment (S VII).** Segmentum basale mediale (cardiacum). It is often an inseparable part of the anterior basal segment. B
- 25 **Anterior basal segment (S VIII).** Segmentum basale anterius. It lies between the oblique fissure and the lateral basal segment. B
- 26 **Lateral basal segment (S IX).** Segmentum basale laterale. It lies between the anterior and posterior basal segments. B
- 27 **Posterior basal segment (S X).** Segmentum basale posterius. It lies beside the vertebral column below the superior segment of the lower lobe. B

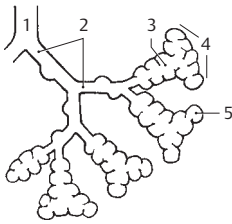


A Segments of the right lung

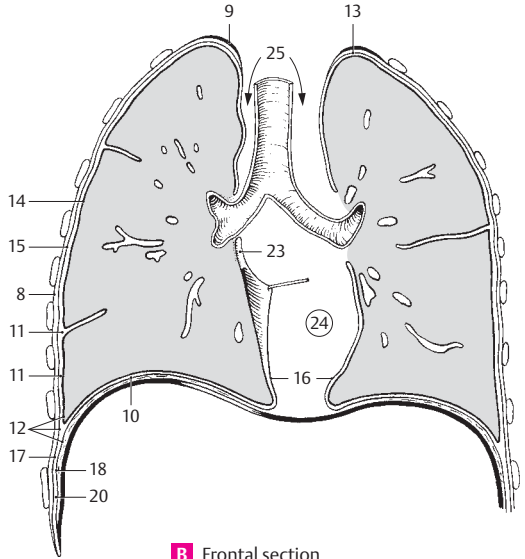


B Segments of the left lung

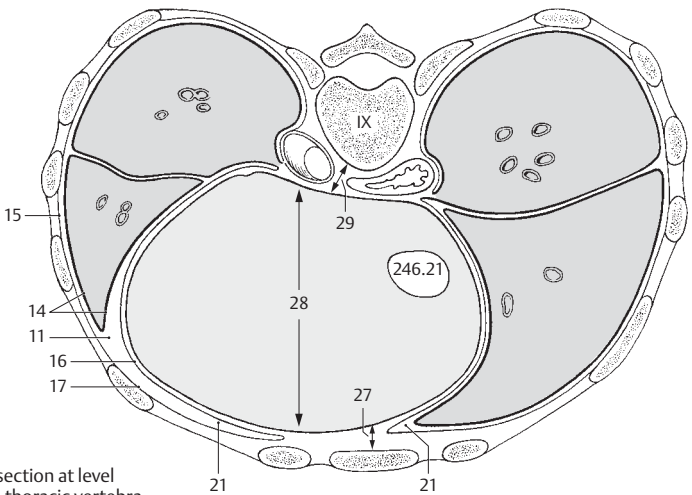
- 1 **Bronchioles.** Bronchioli. Noncartilaginous segments of the respiratory tree directly following the bronchi. They are lined initially by pseudostratified, ciliated, columnar epithelium which is subsequently replaced by simple cuboidal epithelium. A
- 2 **Respiratory bronchioles.** Bronchioli respiratorii. Last bronchiolar segment the wall of which already consists partially of alveoli. A
- 3 **Alveolar ducts.** Ductuli alveolares. Terminal branches of the respiratory bronchioles the walls of which contain only alveoli. A
- 4 **Alveolar sacs.** Sacculi alveolares. Blind, expanded ends of the alveolar ducts. A
- 5 **Pulmonary alveoli.** Alveoli pulmonis. Smallest outpocketings, 0.1–0.9 mm, in diameter, the thin walls of which permit the exchange of gases. A
- 6 **THORACIC CAVITY.** Cavitas thoracis (thoracica). Internal thoracic space enclosed by the ribs and limited inferiorly by the diaphragm. B C
- 7 **Pleuropulmonary regions.** Regiones pleuropulmonales. Regions connecting the pleura and lungs.
- 8 **Endothoracic fascia.** Fascia endothoracica. Displaceable layer of loose connective tissue between the parietal pleura and chest wall. B
- 9 **Suprapleural membrane.** Membrana suprapleuralis [[Sibson]]. Thickened portion of the endothoracic fascia in the region of the pleural cupola. B
- 10 **Phrenicopleural fascia.** Fascia phrenicopleuralis. Portion of the endothoracic fascia which connects the parietal pleura with the diaphragm. B
- 11 **Pleural cavity.** Cavitas pleuralis. Capillary fissure-like space between the parietal and visceral pleura containing a small amount of serous fluid. B C
- 12 **Pleura.** Serous membrane consisting of simple squamous epithelium and underlying connective tissue. It comprises two portions (visceral and parietal pleura) which become continuous at the hilum. The visceral (pulmonary) pleura covers the lungs whereas the parietal pleura lines the chest wall, diaphragm and mediastinum. B
- 13 **Cupula (dome) of pleura.** Cupula pleurae. It covers the apex of the lung at the superior thoracic aperture and forms the boundary between the neck and thorax. B
- 14 **Visceral (pulmonary) pleura.** Pleura visceralis (pulmonalis). Portion of the pleura that envelops the lung and passes into the interlobar spaces. B C
- 15 **Parietal pleura.** Pleura parietalis. Serous lining of the space in which the lungs lodge. B C
- 16 **Mediastinal part of parietal pleura (mediastinal pleura).** Pars mediastinalis. Portion of the parietal pleura lining the mediastinum. B C
- 17 **Costal part of parietal pleura (costal pleura).** Pars costalis. It lines the ribs. B C
- 18 **Diaphragmatic part of parietal pleura (diaphragmatic pleura).** Pars diaphragmatica. It covers the diaphragm. B
- 19 **Pleural recesses.** Recessus pleurales. Fissure-shaped spaces formed by the parietal pleura for reception of the lungs during inspiration.
- 20 **Costodiaphragmatic recess.** Recessus costodiaphragmaticus. Pleural recess between the descending sides of the diaphragm and the lateral wall of the thorax. B
- 21 **Costomediastinal recess.** Recessus costomediastinalis. Anterior pleural space between the costal and mediastinal pleura; it is more extensive on the left than on the right. C
- 22 **Phrenicomediastinal recess.** Recessus phrenicomediastinalis. Pleural recess situated dorsally between the diaphragm and the mediastinum.
- 23 **Pulmonary ligament.** Lig. pulmonale. Double fold extending from the right and left sides of the hilum, connecting the visceral and mediastinal pleura. Between both folds the lung abuts against the mediastinal connective tissue free of pleura. B. See also p. 149 B D
- 24 **Mediastinum.** Thoracic area between both pleural sacs. It extends from the anterior surface of the vertebral column to the posterior surface of the sternum and from the upper thoracic aperture to the diaphragm. B
- 25 **Superior mediastinum.** Mediastinum superius. Portion of the mediastinum above the heart. It contains the arch of the aorta together with its branches, as well as the brachiocephalic veins, superior vena cava, trachea, esophagus, vagus nerves, thoracic duct, thymus, etc. B
- 26 **Inferior mediastinum.** Mediastinum inferius. Collective term for the following three divisions.
- 27 **Anterior mediastinum.** Mediastinum anterius. Area between the pericardium and sternum. C
- 28 **Middle mediastinum.** Mediastinum medium. Area occupied by the heart, pericardium and phrenic nerves with their accompanying vessels. C
- 29 **Posterior mediastinum.** Mediastinum posterius. Area between the pericardium and the vertebral column. It contains the esophagus, vagus nerves, descending aorta, thoracic duct and the azygos and hemiazygos veins. C



A Bronchiole and alveolar ducts

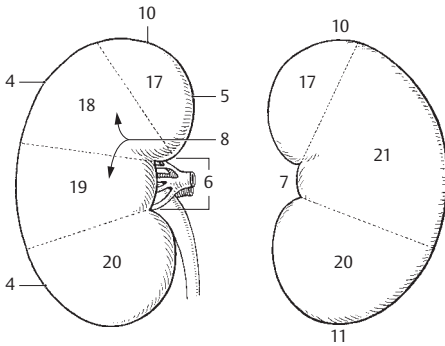


B Frontal section through both lungs



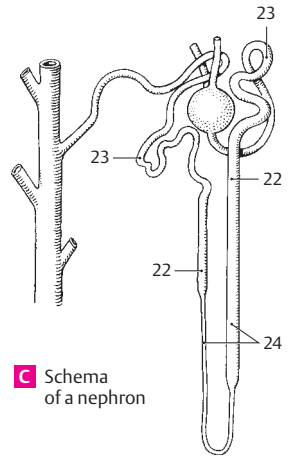
C Horizontal section at level of the ninth thoracic vertebra. View from below

- 1 **UROGENITAL SYSTEM.** Apparatus urogenitalis (systema urogenitale). Urinary and genital organs.
- 2 **URINARY ORGANS.** Organa urinaria.
- 3 **KIDNEY.** Ren (nephros). A B F
- 4 **Lateral margin.** Margo lateralis. Convex lateral border of kidney. A
- 5 **Medial margin.** Margo medialis. Border of the kidney which becomes concave at the hilum. A
- 6 **Renal hilum.** Hilum renale. Site of entry and exit of renal blood vessels and ureter. A
- 7 **Renal sinus.** Sinus renalis. Very concave cavity at the medial border for the renal hilum. B D
- 8 **Anterior surface.** Facies anterior. Curved anterior surface of the kidney. A D
- 9 **Posterior surface.** Facies posterior. Nearly flat posterior surface of the kidney. D
- 10 **Upper pole of kidney.** Extremitas superior. A B
- 11 **Lower pole of kidney.** Extremitas inferior. B
- 12 **Renal fascia.** Fascia renalis. Fibrous sheath that separates the adipose capsule from the perirenal fat. D
- 13 **Pararenal fatty body.** Corpus adiposum pararenale. Fat pad between the posterior layer of the renal fascia and the transversalis fascia. D
- 14 **Fatty capsule.** Capsula adiposa. Fatty capsule of the kidney, more prominent posteriorly and medially. D
- 15 **Fibrous capsule.** Capsula fibrosa. Tough organ capsule fused with the surface of the kidney, but removable. D F
- 16 **Renal segments.** Segmenta renalia. Five segments of the kidney corresponding to the blood supply regions of the branches of the renal artery.
- 17 **Superior segment.** Segm. superius. Upper segment extending up to the posterior surface. A B
- 18 **Upper anterior segment.** Segm. anterius superius. A
- 19 **Lower anterior segment.** Segm. anterius inferius. A
- 20 **Inferior segment.** Segm. inferius. It reaches as far as the posterior and anterior surfaces. A B
- 21 **Posterior segment.** Segm. posterius. B
- 22 **Renal (uriniferous) tubule (nephron).** Tubulus renalis. Tubular system representing the structural unit of the kidney in which filtration and selective reabsorption take place. C
- 23 **Convoluted uriniferous tubules.** [[Tubuli renales contorti]]. Tortuous parts of the renal tubules. C
- 24 **Straight segments of renal tubules.** [[Tubuli renales recti]]. C
- 25 **Renal lobes.** Lobi renales. Still preserved in the newborn, they correspond to renal pyramids with cortical caps.
- 26 **Renal cortex.** Cortex renalis. About 6 mm thick, it consists of glomeruli and predominantly convoluted uriniferous tubules. With the renal columns, it extends up to the wall of the renal pelvis. F
- 27 **Convoluted part (cortical labyrinth).** Pars convoluta. Cortical region consisting of glomeruli and convoluted uriniferous tubules. F
- 28 **Radiating part (medullary rays).** Pars radiata. Collecting tubules coursing radially into the cortex from the medulla. F
- 29 **Cortical lobules.** Lobuli corticales. Areas delimited by interlobular arteries.
- 29a **Medullary rays.** Radii medullares. Consisting of pale collecting tubules which project into the cortex. F
- 30 **Renal medulla.** Medulla renalis. Medullary tissue in the shape of renal pyramids and consisting of the straight portions of the uriniferous tubules and the collecting ducts. F
- 31 **Renal pyramids.** Pyramides renales. Six to 20 pyramidal areas separated by renal columns. They form the medullary substance. F
- 32 **Base of pyramid.** Basis pyramidis. It lies at the corticomedullary border. F
- 33 **Renal papillae.** Papillae renales. Rounded apical portion of the renal pyramid projecting into the renal calyx. F
- 34 **Area cribrosa.** Surface of renal papillae with sieve-like perforations created by the openings of the uriniferous tubules. F
- 35 **Papillary foramina.** Foramina papillaria. Holes in the area cribrosa produced by the openings of the uriniferous tubules.
- 36 **Renal columns.** Columnae renales. Cortical substance which extends toward the hilum between the renal pyramids. F
- 37 **Renal corpuscle.** Corpusculum renale. Composed of a glomerulus and its capsule; it lies in the convoluted part of the cortex. E
- 38 **Glomerulus.** Capillary tuft within a renal corpuscle. E
- 39 **Glomerular [[Bowman's]] capsule.** Capsula glomerularis [[Bowman's]]. The capsule around a capillary tuft (glomerulus) of a renal corpuscle. It is continuous with a convoluted tubule. E



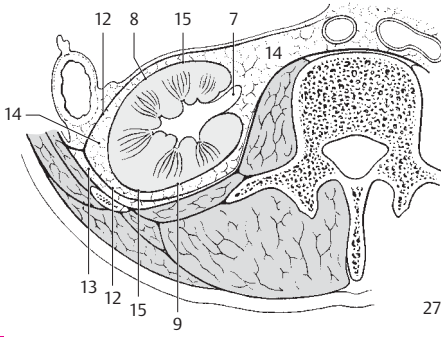
A Kidney segments, anterior view

B Kidney segments, posterior view

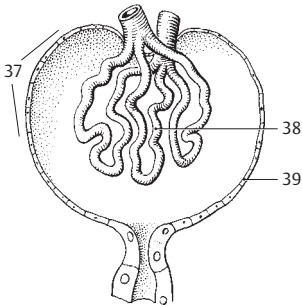


C Schema of a nephron

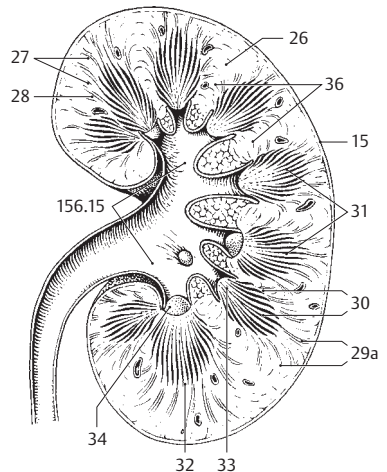
7



D Cross-section through kidney in situ

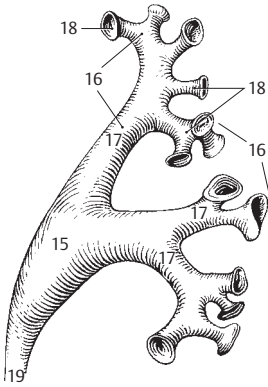


E Glomerulus, semischematic

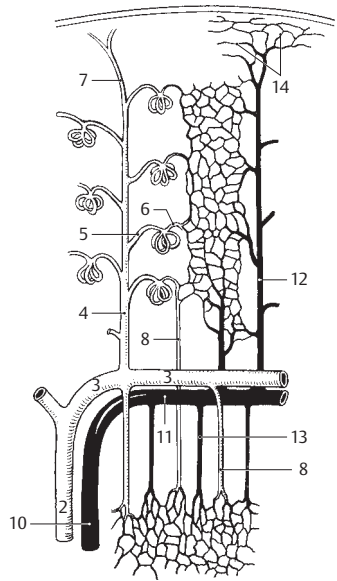


F Section of left kidney

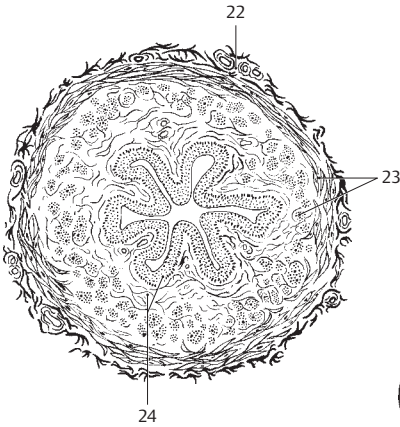
- 1 **Renal arteries.** Arteriae renales.
- 2 **Interlobar arteries.** Arteriae interlobares. Arteries that run between the pyramids. B
- 3 **Arcuate arteries.** Arteriae arcuatae. Arising from the interlobar arteries, they take an arched course along the medullo-cortical border. B
- 4 **Interlobular arteries.** Arteriae interlobulares. Radially oriented branches of the arcuate arteries lying between two medullary rays. B
- 5 **Afferent glomerular arteriole.** Arteriola glomerularis afferens (vas afferens). Arteriole arising from an interlobular artery and entering a renal corpuscle where it subdivides to form the capillary tuft (glomerulus). B
- 6 **Efferent glomerular arteriole.** Arteriola glomerularis efferens (vas efferens). Arteriole leaving the glomerulus and forming a capillary network between the convoluted tubules. B
- 7 **Capsular branches.** Rami capsulares. Small arteries passing from the cortex to the capsule. B
- 8 **Straight arterioles.** Arteriolae rectae (vasa recta). Straight vessels coursing from the efferent glomerular arterioles to the capillary network of the tubules or coming from the arcuate arteries into the medulla. B
- 9 **Renal veins.** Venae renales.
- 10 **Interlobar veins.** Venae interlobares. Veins coming from the periphery between the renal pyramids. B
- 11 **Arcuate veins.** Venae arcuatae. Veins that run an arched course along the corticomedullary border. B
- 12 **Interlobular veins.** Venae interlobulares. Lobular veins corresponding to the interlobular arteries. B
- 13 **Straight venules.** Venulae rectae. Fine veins in the medullary substance which open into the arcuate veins. B
- 14 **Stellate venules.** Venulae stellatae. Veins forming a stellate network beneath the capsule and emptying into the interlobular veins. B
- 15 **Renal pelvis.** Pelvis renalis. Funnel-shaped beginning of the ureter occupying the renal hilum. A
- 16 **Renal calices.** Calices renales. More or less long tubular processes of the renal pelvis that drain the renal papillae. A
- 17 **Major calices of kidney.** Calices renales majores. Two to three primary tubular diverticula of the renal pelvis. A
- 18 **Minor calices of kidney.** Calices renales minores. Seven to 13 calices formed by further division of the major calices. Each receives a renal papilla. A
- 19 **Ureter.** Excretory duct of the kidney situated retroperitoneally. It connects the renal pelvis with the urinary bladder. A C
- 20 **Abdominal part of ureter.** Pars abdominalis. Part of ureter that extends from the renal pelvis to the terminal line of the pelvis.
- 21 **Pelvic part of ureter.** Pars pelvica. Part of ureter that extends from the terminal line to the urinary bladder.
- 22 **Tunica adventitia.** Superficial connective tissue which unites the ureter with the surrounding tissues and permits ureteral mobility. C
- 23 **Tunica muscularis.** Muscular layer in the wall of the ureter. C
- 24 **Tunica mucosa.** Mucous membrane lined by transitional epithelium with underlying connective tissue. C
- 25 **Urinary bladder.** Vesica urinaria. Receptacle that holds about 350–500 ml or more of urine. D
- 26 **Apex of urinary bladder.** Apex vesicae (vesicalis). Anterosuperiorly directed apical portion of urinary bladder. D
- 27 **Body of urinary bladder.** Corpus vesicae. Portion of the urinary bladder situated between the fundus and apex. D
- 28 **Fundus of urinary bladder.** Fundus vesicae. Posterior wall of the urinary bladder lying opposite to the apex, specifically in its lower segment between the ureters. D
- 29 **Cervix (neck) or urinary bladder.** Cervix vesicae. The urethra arises from it. D
- 30 **Median umbilical ligament.** Lig. umbilicale medianum. Fibrous cord derived from the urachus; it extends from the apex of the bladder to the umbilicus. D
- 31 **Urachus.** Connecting passage between the cloaca and allantois present only during embryonic development.



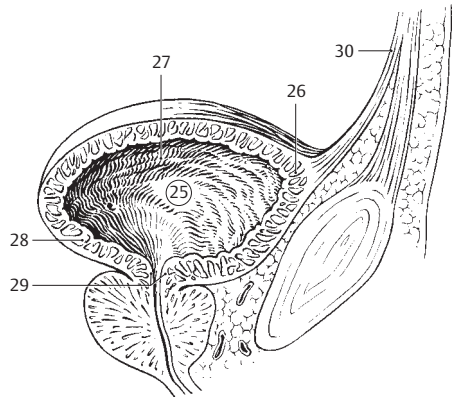
A Left renal pelvis, frontal view



B Renal vessels, schematic



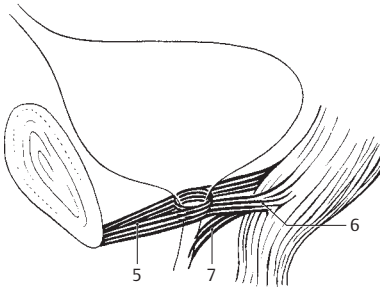
C Cross section of ureter



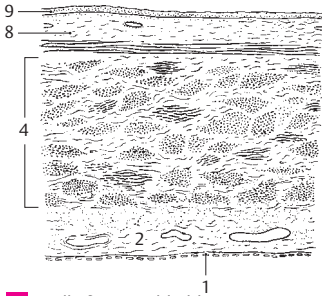
D Urinary bladder, sagittal section

7

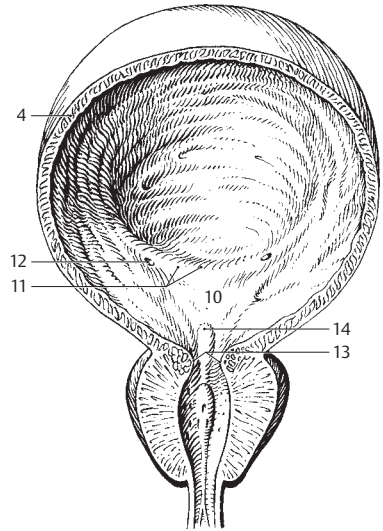
- 7
- 1 **Tunica serosa.** Peritoneal covering of the urinary bladder. C
 - 2 **Tela subserosa.** Connective tissue layer beneath the serosa of the urinary bladder. C
 - 3 **Tunica muscularis.** Entire musculature of the urinary bladder with the following four parts.
 - 4 **Detrusor muscle of bladder.** *Musculus detrusor vesicae.* True musculature of the wall of the bladder. It consists of an inner and outer longitudinal layer as well as a middle circular layer. B C
 - 5 ***M. pubovesicalis.*** Smooth muscle extending from the lower portion of the pubic symphysis to the neck of the bladder. A
 - 6 ***M. rectovesicalis.*** Smooth muscle passing from the longitudinal musculature of the rectum to the lateral base (fundus) of the bladder. A
 - 7 ***M. rectourethralis.*** Smooth muscle extending from the longitudinal muscles of the rectum to the urethra in males. See p. 126.22 A
 - 8 **Tela submucosa.** Connective tissue layer beneath the mucosa of the bladder. It is absent in the trigone. C
 - 9 **Tunica mucosa.** Mucous membrane of the urinary bladder. It is lined by transitional epithelium. C
 - 10 **Trigone of bladder.** *Trigonum vesicae.* Triangular region between the openings of the ureters and the exit site of the urethra. Here the mucosa is firmly united with the muscularis and consequently there are no folds. B
 - 11 **Interureteric ridge.** *Plica interureterica.* Transverse mucosal fold between the two ureteric openings. B
 - 12 **Ostium ureteris.** Slit-like opening of the ureter. B
 - 13 **Ostium urethrae internum.** Initial portion of the urethra at the anterior apex of the trigone. B
 - 14 **Uvula of bladder.** *Uvula vesicae.* Sagittal ridge located behind the urethral opening and above the middle lobe of the prostate. B
 - 15 **INTERNAL MALE GENITALIA:** *Organa genitalia masculina interna.*
 - 16 **Testis (Orchis).** It measures about 5 cm in length. D E
 - 17 **Superior end of testis.** *Extremitas superior.* D
 - 18 **Inferior end of testis.** *Extremitas inferior.* D
 - 19 **Lateral, flattened surface of testis.** *Facies lateralis.* D
 - 20 **Medial, flattened surface of testis.** *Facies medialis.* D
 - 21 **Anterior, free margin of testis.** *Margo anterior.* D
 - 22 **Posterior margin of testis.** *Margo posterior,* attached to a serous reflected fold. D
 - 23 **Tunica vaginalis testis.** Serous covering of the testis formed developmentally by the vaginal process of the peritoneum. See also p. 162.1–6
 - 24 **Tunica albuginea.** Tough connective tissue capsule of the testis. D
 - 25 **Mediastinum testis.** Connective tissue mass projecting into the interior of the testis from the posterior margin of the tunica albuginea. D
 - 26 **Septa of testis.** *Septula testis.* Connective tissue partitions radiating out from the mediastinum to the tunica albuginea. D E
 - 27 **Lobules of testis.** *Lobuli testis.* Compartmentalized lobules of testicular parenchyma formed by the septa. D E
 - 28 **Parenchyma testis.** Specific testicular tissue made up of seminiferous tubules. D
 - 29 **Convoluted seminiferous tubules.** *Tubuli seminiferi contorti.* Tortuous testicular tubules which occupy the lobules of the testis. E
 - 30 **Straight seminiferous tubules.** *Tubuli seminiferi recti.* Short straight tubules extending from the convoluted seminiferous tubules to the rete testis. E
 - 31 **Rete testis.** Network of canals within the mediastinum testis. Lined by simple cuboidal epithelium, they connect the straight seminiferous tubules with the efferent ductules. E
 - 32 **Efferent ductules of testis.** *Ductuli efferentes testis.* 10–12 ductulus between the rete testis and the duct of the epididymis. D E



A Muscles of neck of urinary bladder

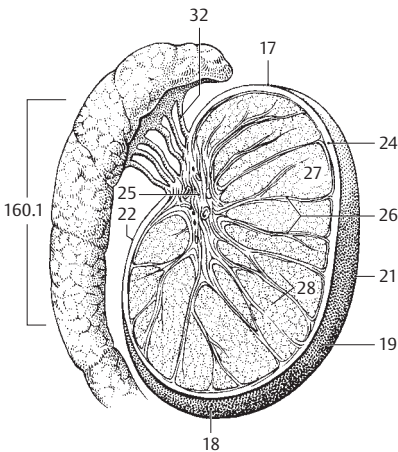


C Wall of urinary bladder

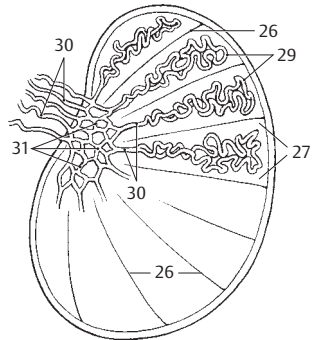


7

B Urinary bladder and prostate, opened, frontal view

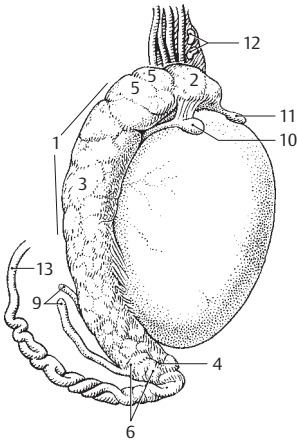


D Testicle and epididymis

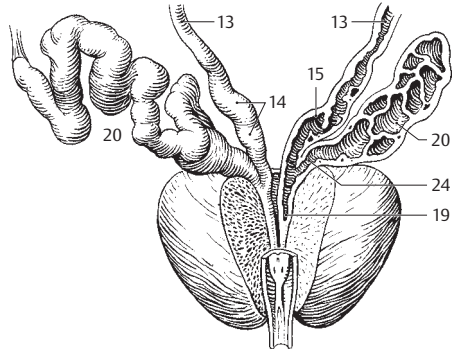


E Testicle, schematic

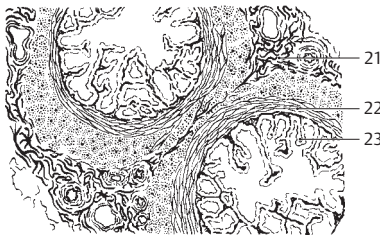
- 1 **Epididymis.** Lying on the posteromedial surface of the testis, it serves as a storage receptacle for sperm. A
- 2 **Head of epididymis.** Caput epididymidis. It is occupied by the efferent ductules. A
- 3 **Body of epididymis.** Corpus epididymidis. Middle segment of the epididymis consisting of the convolutions of the duct of the epididymis. A
- 4 **Tail of epididymis.** Cauda epididymidis. Inferior, terminal portion of the epididymis consisting of the convolutions of the duct of the epididymis. A
- 5 **Lobules (cones) of epididymis.** Lobuli coni epididymidis. Wedge-shaped lobules in the head of the epididymis separated by connective tissue and formed by one or two efferent ductules. A
- 6 **Duct of epididymis.** Ductus epididymidis. Coiled duct, 5–6 meters long, beginning at the end of the head of the epididymis where it receives the efferent ductules. It terminates at the end of the tail where it is continuous with the ductus deferens. A
- 7 **Aberrant ductules.** Ductuli aberrantes. Blind branches of the efferent ductules and duct of the epididymis representing vestiges of the caudal mesonephric tubules.
- 8 [*Ductulus aberrans superior*]. Superior aberrant ductule in the head of the epididymis.
- 9 [*Ductulus aberrans inferior*]. Inferior aberrant ductule in the tail of the epididymis. A
- 10 **Appendix testis.** Vesicular appendage superior to the testis (vestige of the paramesonephric duct). A
- 11 [*Appendix epididymidis*]. Appendix of epididymis. Pedunculate appendage at the head of the epididymis (vestige of the mesonephros). A
- 12 **Paradidymis.** Bilateral blind ductules superior to the head of the epididymis and in front of the spermatic cord (remnant of mesonephric tubules). A
- 13 **Ductus deferens.** Spermatic duct, about 60 cm long, between the epididymis and the seminal vesicle. It is initially coiled and then becomes straight. A B D E
- 14 **Ampulla of ductus deferens.** Ampulla ductus deferentis. Oval enlargement of ductus deferens just prior to joining the duct of the seminal vesicle. B
- 15 **Diverticula of ampulla.** Diverticula ampullae. Lateral sacculations in the wall of the ampulla of the ductus deferens. B
- 16 **Tunica adventitia.** Connective tissue covering of the ductus deferens. E
- 17 **Tunica muscularis.** Relatively very thick muscle layer of the ductus deferens. E
- 18 **Tunica mucosa.** Mucous membrane of ductus deferens lined by pseudostratified, stereociliated, columnar epithelium. E
- 19 **Ejaculatory duct.** Ductus ejaculatorius. Spermatic duct formed by the union of the ductus deferens and the duct of the seminal vesicle. It traverses the prostate and empties into the prostatic urethra. B
- 20 **Seminal vesicle.** Vesicula seminalis. Erroneously designated as a receptacle for sperm, this organ is a vesicular gland which consists of a coiled tube, about 12 cm in length. B C
- 21 **Tunica adventitia.** Connective tissue covering of the seminal vesicle. C
- 22 **Tunica muscularis.** Muscular layer in the wall of the seminal vesicle. C
- 23 **Tunica mucosa.** Multilocular mucous membrane of the seminal vesicle lined by a simple secretory epithelium. C
- 24 **Excretory duct.** Ductus excretorius. Efferent duct of the seminal vesicle. It unites with the ductus deferens to form the ejaculatory duct. B
- 25 **Spermatic cord.** [[Funiculus spermaticus]]. It consists of the ductus deferens, accompanying vessels, nerves and connective tissue, together with its coverings. D
- 26 **Tunicae funiculi spermatici.** Coverings of the spermatic cord and the testis, described below. D
- 27 **External spermatic fascia.** Fascie spermatica externa. Outer covering of the spermatic cord, which is continuous with the fascia of the external oblique m. of the abdomen. It also envelops the testis together with its remaining coverings. D
- 28 **M. cremaster.** Elevator of the testis. It is derived mainly from internal abdominal oblique muscle. D
- 29 **Cremasteric fascia.** Fascia cremasterica. Connective tissue on and between the cremaster muscle fibers. D
- 30 **Internal spermatic fascia.** Fascia spermatica interna [tunica vaginalis communis]. The finger-like inner covering of the spermatic cord, which is derived from the transverse fascia. It lies beneath the cremaster muscle and surrounds the testis, epididymis and ductus deferens together with blood vessels and nerves. D
- 31 **Vestige of vaginal process.** [Vestigium processus vaginalis]. Remnant of the not completely obliterated embryological vaginal process of the peritoneum. D



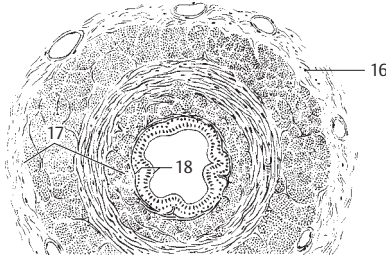
A Testicle and epididymis



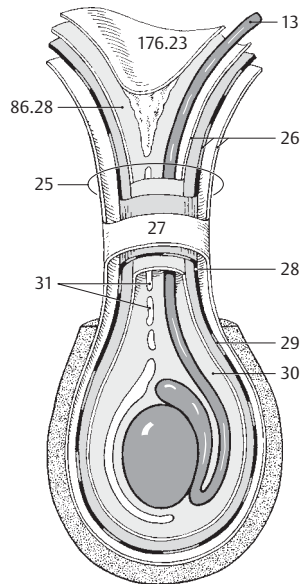
B Postate and seminal vesicle, opened, frontal view



C Seminal vesicle, histological section

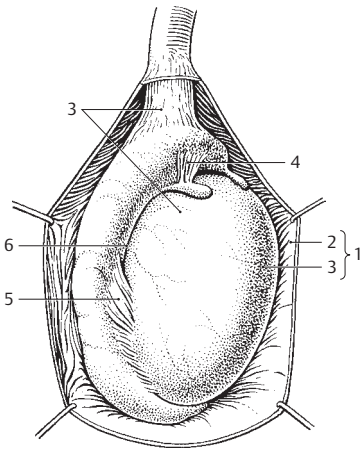


E Sperm duct (ductus deferens), cross section

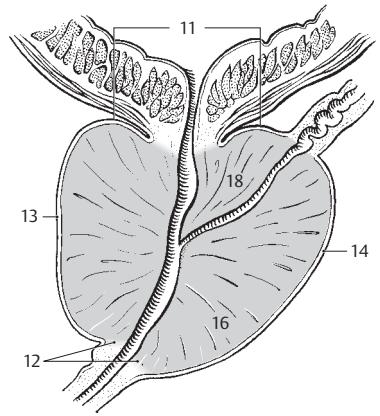


D Coverings of the spermatic cord and the testis

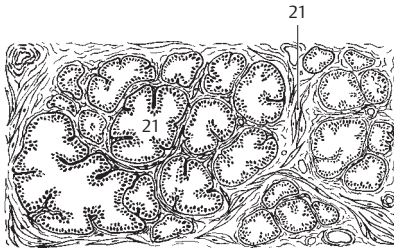
- 1 **Tunica vaginalis testis.** Double-layered serous covering of the testis, a remnant of the vaginal process of the peritoneum. A
- 2 **Parietal layer.** Lamina parietalis [[periorchium]]. External layer of the serous tunica vaginalis testis. A
- 3 **Visceral layer.** Lamina visceralis [[eporchium]]. Layer of the tunica vaginalis testis that attaches superiorly to the testis. A
- 4 **Superior ligament of epididymis.** Lig. epididymidis superius. Reflected fold of the tunica vaginalis testis located superiorly at the head of the epididymis. A
- 5 **Inferior ligament of epididymis.** Lig. epididymidis inferius. Reflected fold of the tunica vaginalis testis situated inferiorly at the tail of the epididymis. A
- 6 **Sinus of epididymis.** Sinus epididymidis. Serous cleft between the testis and epididymis. It is accessible laterally and is bordered above and below by the superior and inferior ligaments of the epididymis. A
- 7 **Descent of testis.** [[Descensus testis]]. Downward migration of the fetal testis during the last weeks of pregnancy. It descends from the peritoneal cavity into the scrotal sac via the inguinal canal.
- 8 **[[Gubernaculum testis]].** Fetal connective tissue band which arises from the caudal gonadal fold and guides the testis during its descent.
- 9 **Genitoinguinal ligament.** [[Lig. genitoinguinale]]. Embryonic precursor of the gubernaculum testis.
- 10 **Prostate.** Prostata (glandula prostatica). Chestnut-sized organ consisting of 30–50 tubulo-alveolar glands. Situated below the urinary bladder, it is penetrated by the urethra. B C D
- 11 **Base of prostate.** Basis prostatae. Part of the prostate fused with the urinary bladder. B
- 12 **Apex of prostate.** Apex prostatae. Portion of prostate directed downward and forward and containing the urethra. B
- 13 **Anterior surface.** Facies anterior. Surface of the prostate facing the symphysis. B D
- 14 **Posterior surface.** Facies posterior. Surface of the prostate facing the rectum. B
- 15 **Inferolateral surface.** Facies inferolateralis. Surface of the prostate directed downward and lateral. D
- 16 **Right/left lobe.** Lobus (dexter/sinister). Part of the prostate arising from the caudal anlage. B D
- 17 **Isthmus of prostate.** Isthmus prostatae. Median part of the prostate located in front of the urethra and connecting the right and left lobes. It is devoid of glands and possesses a fibromuscular stroma. D
- 18 **Middle lobe.** [Lobus medius]. Prostatic lobe situated between the ejaculatory duct and the urethra. It tends to undergo hormone-induced hypertrophy in the elderly, thus closing the urethral canal like a valve. B D
- 19 **Capsule of prostate.** Capsula prostatica. Provided with smooth muscle fibers, it is firmly fused to the prostate. D
- 20 **Parenchyma.** Glandular component of the prostate.
- 21 **Prostatic ductules.** Ductuli prostatici. 15–30 glandular excretory ductules which open into the prostatic urethra. C
- 22 **Substantia muscularis.** Smooth muscle situated between the glandular alveoli. C
- 23 **M. puboprostaticus.** Tracts of smooth muscle contained within the puboprostatic (pubovesical) ligament extending from the pubic symphysis to the prostate.
- 24 **Bulbourethral [[Cowper's] gland.** Glandula bulbourethralis [[Cowper's]]. Pea-sized mucous gland located in the urogenital diaphragm. E
- 25 **Duct of bulbourethral gland.** Ductus gl. bulbourethralis. Excretory duct of the bulbourethral gland, 3–4 cm long. E
- 26 **EXTERNAL MALE GENITALIA.** Organa genitalia masculina externa. E
- 27 **Penis.** Male copulatory organ consisting of cavernous bodies and the urethra. E
- 28 **Root of penis.** Radix penis. Portion of the penis attached to the pubis. E
- 29 **Body (shaft) of penis.** Corpus penis. Portion of the penis situated between the root and the glans. E
- 30 **Crus penis.** Cavernous body attached to the inferior ramus of the pubis. E
- 31 **Dorsum penis.** Flattened upper surface of penis.
- 32 **Urethral surface.** Facies urethralis. Underside of penis. It bears the urethra within the corpus spongiosum. E



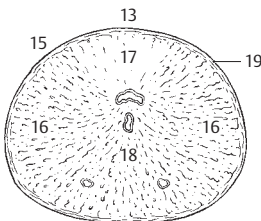
A Right testicle with epididymis and investing layers, lateral view



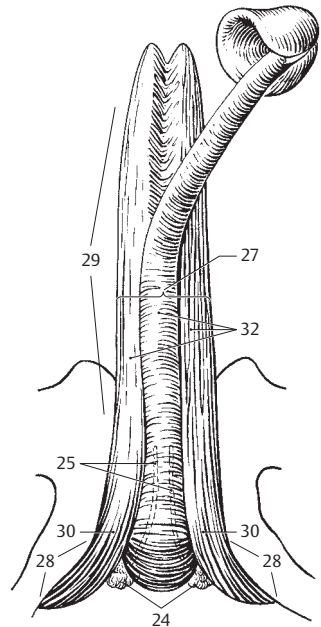
B Prostate, sagittal section



C Prostate, histologic view



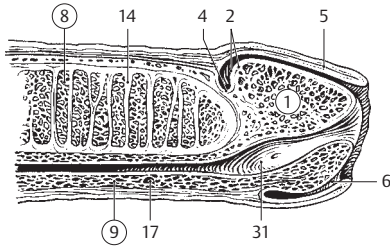
D Prostate, horizontal section



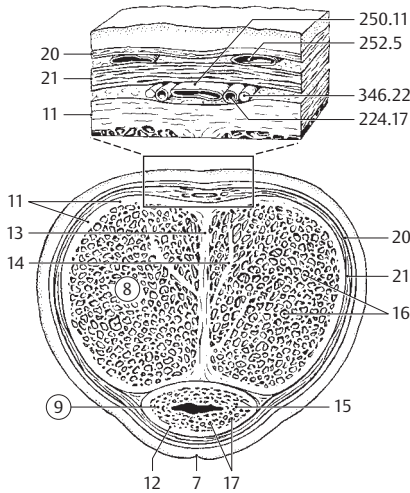
E Penis from below

7

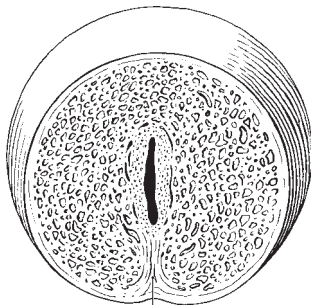
- 7
- 1 **Glans penis.** Expanded end of the corpus spongiosum penis. A D
 - 2 **Corona glandis.** Raised posterior margin of the glans. A D
 - 3 **Septum glandis.** Median partition in the glans. C
 - 4 **Collum glandis.** Neck of glans. Constricted portion behind the corona. A
 - 5 **Prepuce (foreskin) of penis.** Preputium penis. Double layer of skin over the glans. A
 - 6 **Frenulum of prepuce.** Frenulum preputii. Reflected fold passing from the prepuce to the underside of the glans. A
 - 7 **Raphe penis.** Seam on the skin on the underside of the penis that forms during development. B
 - 8 **Corpus cavernosum penis.** Cavernous body divided into two halves by the septum of the penis. A B D
 - 9 **Corpus spongiosum penis.** Cavernous body surrounding the urethra. A B D
 - 10 **Bulb of penis.** Bulbus penis. Posterior thickened end of the corpus spongiosum. D
 - 11 **Tunica albuginea of corpora cavernosa.** Tunica albuginea corporum cavernosorum. Tough connective tissue covering of the corpora cavernosa. B
 - 12 **Tunica albuginea of corpus spongiosum.** Tunica albuginea corporis spongiosi. Less firm connective tissue covering of the corpus spongiosum. B
 - 13 **Septum of penis.** Septum penis [septum pectiniforme]. Pectinate partition between the right and left corpus cavernosum. Gaps are present. B
 - 14 **Trabeculae corporum cavernosorum.** Connective tissue tracts within the corpora cavernosa interspersed with smooth muscle. A B D
 - 15 **Trabeculae corporis spongiosi.** Connective tissue tracts within the corpus spongiosum interspersed with smooth muscle. B
 - 16 **Cavernae corporum cavernosorum.** Wide-meshed, blood-filled spaces within the corpora cavernosa. B D
 - 17 **Cavernae corporis spongiosi.** Blood-filled, finely meshed spongy network within the corpus spongiosum. A B
 - 18 **Helicine arteries.** Arteriae helicinae. Coiled branches of the deep artery of the penis. D
 - 19 **Cavernous veins.** Vena cavernosae. Dilated veins in the cavernous bodies.
 - 20 **Superficial fascia of penis.** Fascia penis superficialis. Delicate subcutaneous fascia with individual smooth muscle fibers, continuous with the tunica dartos of the scrotum. B
 - 21 **Deep fascia of penis.** Fascia penis profunda. Deeper, somewhat tougher fascia surrounding the three cavernous bodies. B
 - 22 **Preputial glands.** Gll. preputiales. Sebaceous glands, mainly on the corona of the glans.
 - 23 **Male urethra.** Urethra masculina. D
 - 24 **Prostatic part of urethra.** Pars prostatica. Portion of male urethra passing through the prostate. D
 - 25 **Urethral crest.** Crista urethralis. Mucosal fold in the dorsal wall of the prostatic urethra continuous with the uvula of the urinary bladder. D
 - 26 **Colliculus seminalis.** Elevated portion (verumontanum) of the urethral crest containing the openings of the ejaculatory duct. D
 - 27 **Prostatic utricle.** Utriculus prostaticus. Blind sac in the colliculus seminalis measuring up to 1 cm in length and representing a rudiment of the paramesonephric duct. D
 - 28 **Prostatic sinus.** Sinus prostaticus. Furrow on both sides of the colliculus seminalis containing the openings of the prostatic ductules. D
 - 29 **Membranous part of urethra.** Pars membranacea. Portion of the male urethra passing through the urogenital diaphragm. D
 - 30 **Spongy part of urethra.** Pars spongiosa. Portion of male urethra surrounded by the corpus spongiosum. D
 - 31 **Navicular fossa of urethra.** Fossa navicularis urethrae. Oval dilatation of the male urethra before its external opening. A D
 - 32 **Valve of navicular fossa.** [Valvula fossae navicularis]. Mucosal fold on the upper wall of the navicular fossa.
 - 33 **External urethral orifice.** Ostium urethrae externum. D
 - 34 **Urethral lacunae.** Lacunae urethrales. Numerous outpocketings in the urethral mucosa with the openings of the urethral glands. D
 - 35 **Urethral glands.** Gll. urethrales. Small mucous glands opening into the urethral lacunae.
 - 36 **Ductus (canales) paraurethrales.** Inconstant paraurethral ducts that drain the urethral glands. They open in the vicinity of the external urethral orifice.



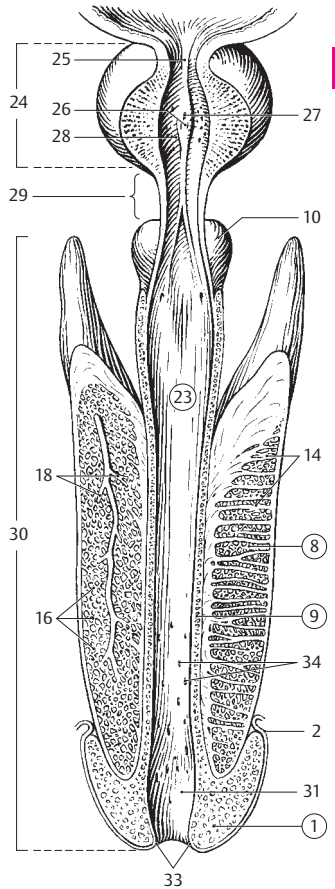
A End of penis, longitudinal section



B Penis, cross section

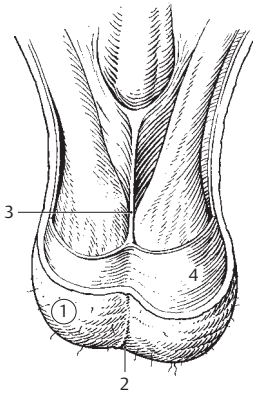


C Glans, cross-section

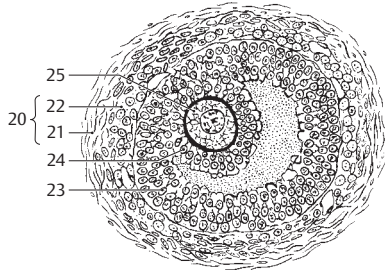


D Penis with prostate and base of bladder opened from dorsal up to the urethra

- 7
- 1 **Scrotum.** The scrotal sac containing the two testes. A
 - 2 **Raphe of scrotum.** Raphe scroti (scrotalis). Developmental median skin suture on the scrotum. A
 - 3 **Septum of scrotum.** Septum scroti (scrotale). Median connective tissue partition in the scrotum. A
 - 4 **Dartos muscle.** Tunica [musculus] dartos. Layer of subcutaneous smooth muscle fibers that wrinkle the skin of the scrotum. A
 - 5 **INTERNAL FEMALE GENITALIA.** Organa genitalia feminina interna. B C D
 - 6 **Ovary.** Ovarium. Intraperitoneal, almond-shaped gonad, about 2.5–4.5 cm long and 0.5–1 cm thick. C D
 - 7 **Hilum of ovary.** Hilum ovarii. Place of entry and exit of the ovarian vessels and attachment site of the mesovarium. C
 - 8 **Medial surface.** Facies medialis. Surface of the ovary directed medial to the intrapelvic space. D
 - 9 **Lateral surface.** Facies lateralis. Surface of the ovary adjoining the wall of the pelvis. D
 - 10 **Free margin.** Margo liber. Free margin of the ovary lying opposite the hilum of the ovary. C D
 - 11 **Mesovarian border.** Margo mesovarius. Margin of attachment of the mesovarium lying opposite the free margin. D
 - 12 **Tubal extremity.** Extremitas tubaria (tubalis). Upper pole of the ovary that faces the uterine tube. D
 - 13 **Uterine extremity.** Extremitas uterina. Lower pole of the ovary facing the uterus. D
 - 14 **Tunica albuginea.** Thin organ capsule beneath the epithelial covering of the ovary, sometimes called the "germinal epithelium." C
 - 15 **Stroma of ovary.** Stroma ovarii. Highly nucleated connective tissue framework of the ovary. C
 - 16 **Cortex of ovary.** Cortex ovarii. Cortical region of the ovary with follicles of variable maturity. C
 - 17 **Medulla of ovary.** Medulla ovarii. Tissue and mass of blood vessels that form the central area of the ovary. C
 - 18 **Primary ovarian follicles.** Folliculi ovarici primarii. Immature ovarian follicles, each consisting of an ovum surrounded by a single layer of follicular epithelial cells without a lumen. C
 - 19 **Vesicular ovarian [Graafian] follicles.** Folliculi ovarici vesiculosi. Maturing ovarian follicles, each with a fluid-filled cavity (antrum). B C
 - 20 **[Thecae folliculi].** Specific connective tissue investments of the follicles. B
 - 21 **Theca externa.** External, fibrous layer of the theca folliculi. B
 - 22 **Theca interna.** Internal cell and vessel-rich layer of the theca folliculi. It produces estradiol when the follicle is mature. B
 - 23 **Follicular epithelium.** Epithelium folliculare (stratum granulosum). Granular, stratified layer of follicular epithelial cells. B
 - 24 **Cumulus oophorus (ovifer).** Mass of follicular epithelial cells projecting into the antrum of the follicle. It surrounds the ovum. B C
 - 25 **Ovum (oocyte).** Ovocyclus. B
 - 26 **Corpus luteum.** Endocrine gland arising from the follicular and thecal cells of the ruptured follicle. C
 - 27 **Corpus albicans.** Connective tissue replacement of the degenerated corpus luteum. C
 - 28 **Ovarian ligament.** Lig. ovarii proprium [[chorda utero-ovarica]]. Ligament between the uterine extremity of the ovary and the tubal angle. It arises from the caudal gonadal fold. D
 - 29 **Uterine (Fallopian) tube, oviduct.** Tuba uterina (salpinx). Thin connection tube, about 10 cm in length, extending from the region of the ovary to the uterus. D
 - 30 **Abdominal opening of uterine tube.** Ostium abdominale tubae uterinae. Opening at the base of the infundibulum which communicates with the peritoneal cavity. D
 - 31 **Infundibulum of uterine tube.** Infundibulum tubae uterinae. Funnel-shaped beginning of the uterine tube at the ovary. D
 - 32 **Fimbriae of uterine tube.** Fimbriae tubae. Fringe-like processes of the infundibulum. D
 - 33 **Ovarian fimbria.** Fimbria ovarica. An especially long fimbria projecting from the base of the infundibulum to the ovary where it is attached. D
 - 34 **Ampulla of uterine tube.** Ampulla tubae uterinae. Lateral 2/3 of the tube. Its lumen tapers toward the isthmus. D
 - 35 **Isthmus of uterine tube.** Isthmus tubae uterinae. Narrow medial 1/3 of the tube. D
 - 36 **Uterine part of uterine tube.** Pars uterina. Portion of the tube within the wall of the uterus. D
 - 37 **Uterine opening of uterine tube.** Ostium uterinum tubae. Opening of the tube into the uterine cavity. D

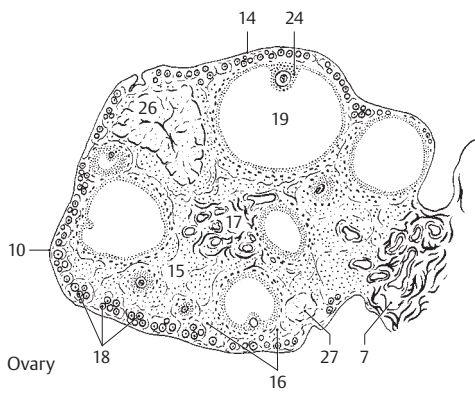


A Scrotum, frontal view

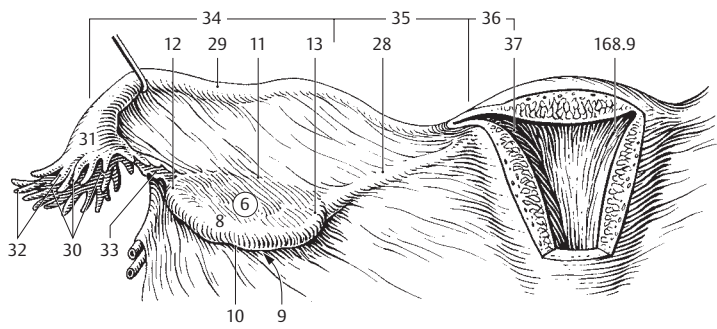


B Ripening follicle

7

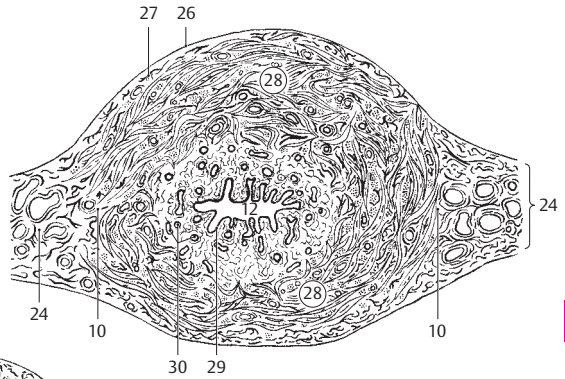


C Ovary

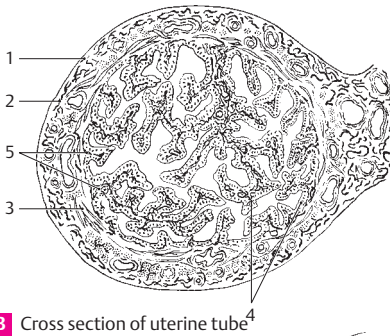


D Uterine tube, ovary and uterus, posterior view

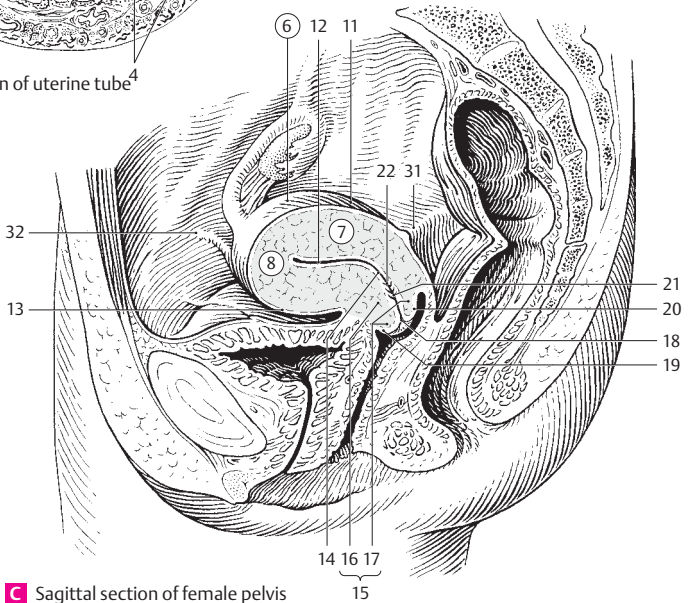
- 7
- 1 **Tunica serosa.** Peritoneal covering of the uterine tube. B
 - 2 **Tela subserosa.** Connective tissue layer beneath the peritoneal covering of the uterine tube. B
 - 3 **Tunica muscularis.** Layer of muscle in the wall of the uterine tube. B
 - 4 **Tunica mucosa.** Mucous membrane lined by ciliated columnar epithelium with glandular cells forming abundantly branched folds. B
 - 5 **Tubal folds.** Plicae tubariae (tubales). Extensively branched mucosal folds which in some areas fill up the entire lumen of the uterine tube. B
 - 6 **Uterus [[Metra]].** It measures about 7.5 cm in length. A C
 - 7 **Body of uterus.** Corpus uteri. Portion of the uterus situated between the cervix and fundus. Its lumen is flattened from anterior to posterior. C
 - 8 **Fundus of uterus.** Fundus uteri. Dome of the uterus lying above the entrance of the uterine tube. C
 - 9 **Right/left horn of uterus.** Cornu uteri dextrum/sinistrum. Pointed extension of the uterus at the entrance of the uterine tube owing to the incomplete union of both paramesonephric ducts. See p. 167 D
 - 10 **Right/left margin of uterus.** Margo uteri dexter/sinister. Blunt lateral margins of the uterus to which the broad ligament of the uterus is attached. A
 - 11 **Intestinal surface.** Facies intestinalis. Surface of uterus facing posterosuperiorly and bordering on the intestine. C
 - 12 **Cavity of uterus.** Cavitas uteri. It is lined by mucosa. A C
 - 13 **Vesical surface.** Facies vesicalis. Uterine surface directed anteroinferiorly and facing the urinary bladder. C
 - 14 **Isthmus uteri.** Portion of the uterus between the body and cervix. It is about 1 cm long. C
 - 15 **Cervix uteri.** More tubular lower third of the uterus adjacent to the isthmus and about 2.5 cm long. C
 - 16 **Supravaginal part of cervix.** Portio supravaginalis cervicis. Portion of the cervix surrounded on all sides by connective tissue. C
 - 17 **Vaginal part of cervix.** Portio vaginalis cervicis. Cone-shaped portion of the cervix that projects into the vagina and is covered on all sides by vaginal epithelium. C
 - 18 **External os of uterus.** Ostium uteri. Opening of the uterine lumen into the vagina. It is pit-like in nullipara and becomes slit-like after childbirth. C
 - 19 **Anterior lip.** Labium anterius. Anterior border of the uterine ostium. C
 - 20 **Posterior lip.** Labium posterius. Posterior border of uterine ostium. C
 - 21 **Cervical canal.** Canalis cervicis uteri. Tube-shaped canal of the cervix. C
 - 22 **Palmate folds.** Plicae palmatae. Mucosal folds in the cervix organized like leaves of a palm tree. C
 - 23 **Cervical glands** Gll. cervicalis (uteri). Branched, tubular mucous glands in the mucosa of the cervix.
 - 24 **Parametrium.** Connective tissue between the two layers of the broad ligament. A
 - 25 **Paracervix.** Continuation of the parametrium into the cervical region.
 - 26 **Tunica serosa (perimetrium).** Peritoneal covering of the uterus. A
 - 27 **Tela subserosa.** Connective tissue layer beneath the peritoneal covering of the uterus. A
 - 28 **Tunica muscularis (myometrium).** Very thick muscular layer of the wall of the uterus. Its fibers are arranged in a spiral system. A
 - 29 **Tunica mucosa (endometrium).** Mucous membrane of uterus lined by simple columnar epithelium and glands. It undergoes changes corresponding to the menstrual cycle. A
 - 30 **Uterine glands.** Gll. uterinae. Simple, branched, tubular glands within the endometrium. A
 - 31 **M. recto-uterinus.** Smooth muscle within the rectouterine fold. C
 - 32 **Round ligament of uterus.** Lig. teres uteri. Derived from the caudal gonadal fold, it extends from the tube angle to the labium majus by way of the broad ligament and the inguinal canal. C
 - 33 **[[Processus vaginalis peritonei]].** Transient developmental diverticulum of the peritoneum extending through the inguinal canal. In rare cases it is the site of a congenital inguinal hernia in the female.



A Cross section of uterus

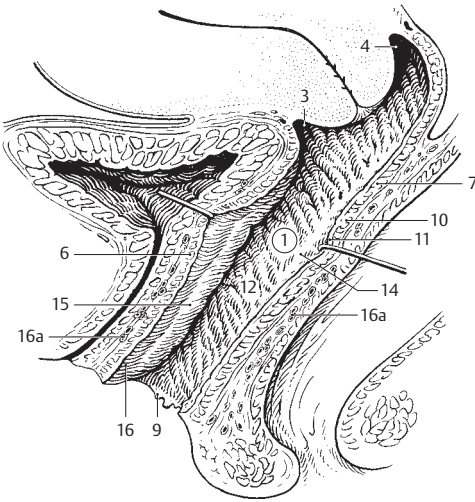


B Cross section of uterine tube

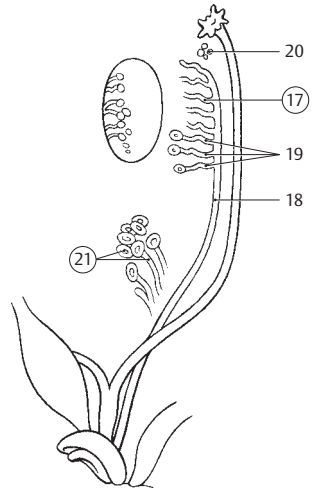


C Sagittal section of female pelvis

- 1 **Vagina.** Flat canal, about 10 cm long, leading into the uterus. A
- 2 **Fornix vaginae.** Recess between the vaginal part of the cervix and the wall of the vagina. A
- 3 **Anterior part.** Pars anterior. Anterior, shallower fornix of the vagina. A
- 4 **Posterior part.** Pars posterior. Posterior fornix of the vagina with its clinically very significant relationship to the peritoneal cavity. A
- 5 **Lateral part.** Pars lateralis. Lateral connection between the anterior and posterior parts of the fornix vaginae.
- 6 **Anterior wall of vagina.** Paries anterior. A
- 7 **Posterior wall of vagina.** Paries posterior. A
- 8 **Hymen.** Cutaneous fold emanating especially from the posterior wall of the vagina and, as a virginal membrane, partially closing off the entrance (introitus) to the vagina. C
- 9 **Hymenal caruncle.** Carunculae hymenales. Fleeshy remains of the hymen in the wall of the vagina after childbirth. A D
- 10 **Tunica muscularis.** Relatively thin layer of muscle in the vagina. A
- 11 **Tunica mucosa.** Mucous membrane of the vagina lined by glycogen-rich, stratified, nonkeratinized squamous epithelium. A
- 12 **Rugae vaginales.** Transverse folds (rugae) in the vaginal mucosa. A
- 13 **Columns of rugae.** Columnae rugarum. Two longitudinal ridges in the anterior and posterior walls of the vagina produced by underlying venous plexuses.
- 14 **Posterior column of rugae.** Columna rugarum posterior. It lies in the posterior wall of the vagina. A D
- 15 **Anterior column of rugae.** Columna rugarum anterior. It lies in the anterior wall of the vagina. A D
- 16 **Urethral carina of vagina.** Carina urethralis vaginae. Longitudinal ridge produced by the urethra in the lower part of the anterior column of the rugae. A C D
- 16a **Tunica spongiosa.** Layer of spongy vascular plexuses outside of the tunica muscularis. A
- 17 **Epoöphoron.** Developmental derivative of the mesonephros within the mesosalpinx. B
- 18 **Duct of epoöphoron.** Ductus epoöphorontis longitudinalis. Remnant of the mesonephric duct and some of its tubules. It lies in the mesosalpinx. B
- 19 **Transverse ductules of epoöphoron.** Ductuli transversi epoöphorontis. Remains of 10–20 transversely coursing mesonephric tubules which open into the duct of the epoöphoron. B
- 20 **Appendices vesiculosae.** Dispersed remains of mesonephric tubules in the vicinity of the infundibulum of the uterine tube. They terminate in vesicles. B
- 21 **Paroöphoron.** Tubules derived from the caudal part of the mesonephros and situated between the lowermost branches of the ovarian artery. B
- 22 **Vestigial ductus deferens.** [Ductus deferens vestigialis]. Remains of the embryonic mesonephric duct in the female.
- 23 **FEMALE EXTERNAL SEX ORGANS.** Organa genitalia feminina externa. C D
- 24 **Female pudendum.** Pudendum femininum. External female genitalia. C D
- 25 **Mons pubis.** Pad of fat situated in front of and above the pubic symphysis. C
- 26 **Labium majus pudendi.** Greater lip of the pudendum. A fold of skin the outer surface of which is covered with hair. The internal surface is smooth and hairless, resembling mucosa. C
- 27 **Anterior labial commissure.** Commissura labiorum anterior. Anterior right and left labia majora. C
- 28 **Posterior labial commissure.** Commissura labiorum posterior. Posterior junction of the labia majora. C
- 29 **Pudental fissure.** Rima pudendi. Fissure between the labia majora. C
- 30 **Labium minus pudendi.** Thinner fold of skin devoid of hair and provided with abundant sebaceous glands. C
- 31 **Frenulum of pudental labia.** Frenulum labiorum pudendi. Sharp-edged fold in front of the posterior labial commissure where the labia minora meet. C
- 32 **Vestibule of vagina.** Vestibulum vaginae. Space enclosed by the labia minora. C
- 33 **Fossa of vestibule of vagina.** Fossa vestibuli vaginae. Part of the vestibule between the frenulum and the vaginal opening. C
- 34 **Bulb of vestibule.** Bulbus vestibuli. Body of erectile tissue corresponding to the male corpus spongiosum, found primarily at the root of the labia majora. C
- 35 **Intermediate part of bulb of vestibule.** Pars intermedia [commissura] bulborum. Bridge uniting right and left bulbi vestibuli at the clitoris.

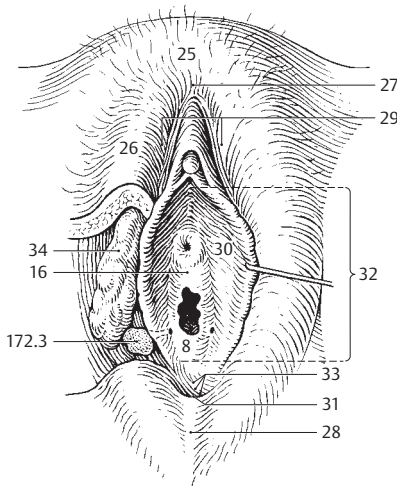


A Urinary bladder, urethra, vagina, uterus and rectum, sagittal section

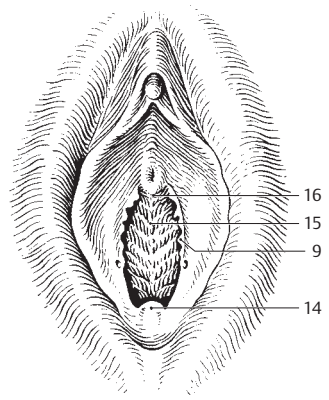


B Development of the female urogenital system

7

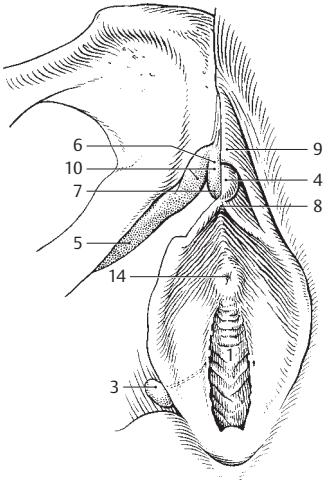


C External female virginal genitalia

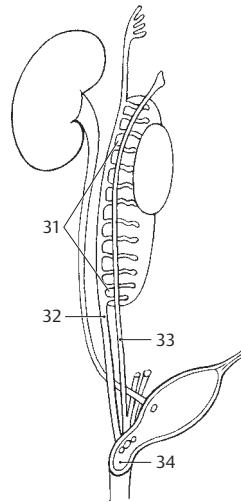


D External female genitalia

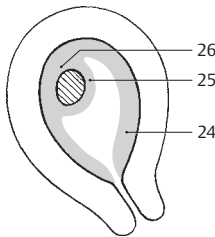
- 1 **Orifice (introitus) of vagina.** Ostium vaginae. Opening of vagina into vestibule. A
- 2 **Lesser vestibular glands.** Gll. vestibulares minores. Simple, tubular mucosal glands near the urethra.
- 3 **Greater vestibular [[Bartholin's] gland.** Gl. vestibularis major [[Bartholini]]. Pea-sized mucous gland situated posteriorly in the urogenital diaphragm. It opens into the lower third of the vestibule between the labium minus and hymen or hymenal caruncle. A
- 4 **Clitoris.** Erectile portion of the female pudendum. Its two cavernous bodies unite at the anterior ends of the labia minora to form the glans clitoridis. A
- 5 **Crus of clitoris.** Crus clitoridis. Portion of the clitoris attached to the inferior pubic ramus. A
- 6 **Body of clitoris.** Corpus clitoridis. Shaft of clitoris formed by the two cavernous bodies. A
- 7 **Glans of clitoris.** Glans clitoridis. Acorn-shaped cap of the clitoris connected with the bulb of the vestibule by a thin cord. A
- 8 **Frenulum of clitoris.** Frenulum clitoridis. Double fold approaching the clitoris inferiorly from the labia minora. A
- 9 **Prepuce of clitoris.** Preputium clitoridis. Fold formed by the union of the two folds of the labia minora above the clitoris. A
- 10 **CORPUS CAVERNOSUM OF CLITORIS.** Corpus cavernosum clitoridis (dextrum/sinistrum). Right and left cavernous bodies that join to form the body of the clitoris. A
- 11 **Septum of corpus cavernosum.** Septum corporum cavernosorum. Incomplete connective tissue partition between the right and left corpora cavernosa.
- 12 **Fascia clitoridis.** Connective tissue layer covering the clitoris.
- 13 **Urethra feminina.** Female urethra. Canal for passage of urine in females, about 2.5 to 4 cm long. D
- 14 **External opening of female urethra.** Ostium urethrae externum femininae. It is situated 2–3 cm below the clitoris. A
- 15 **Tunica muscularis.** Layer of female urethra consisting primarily of circular smooth muscle fibers. D
- 16 **Tunica spongiosa.** Submucosal layer of erectile tissue containing a plexus of veins. D
- 17 **Tunica mucosa.** Mucous coat of the female urethra. The part leaving the bladder is lined with transitional epithelium, the more distal part by stratified columnar epithelium. D
- 18 **Urethral glands.** Gll. urethrales. Small mucous glands opening into the urethra. D
- 19 **Urethral lacunae.** Lacunae urethrales. Small pits in the urethral mucosa into which the urethral glands open. D
- 20 **Paraurethral duct.** [Ductus paraurethrales]. Glandular duct, 1–2 cm long, which opens into the female urethra near the urethral orifice. D
- 21 **Urethral crest.** Crista urethralis. A thick longitudinal fold in the posterior wall of the female urethra. D
- 22 **EMBRYOLOGICAL TERMINOLOGY.** Nomina ontogenetica.
- 23 **Decidual membranes.** [[Membranae deciduae]]. Mucous membranes of the pregnant uterus. C
- 24 **Decidua parietalis.** Mucosal lining of the part of the uterine wall not occupied by the embryo. C
- 25 **Decidua capsularis.** Uterine mucosa between the embryo and the uterine cavity. C
- 26 **Decidua basalis.** Mucous membrane between the embryo and the uterine wall. C
- 27 **Placenta.** Organ of metabolic interchange between mother and fetus. It consists of trophoblast and uterine mucosa (endometrium). E
- 28 **Uterine part.** [[Pars uterina]]. Part of the placenta consisting of the basal plate (decidua basalis) and placental septa. E
- 29 **Fetal part.** [[Pars fetalis]]. Part of the placenta consisting of the chorion and amnion. E
- 30 **Umbilical cord.** Funiculus umbilicalis. Cord derived from the embryological connecting stalk. E
- 31 **Primordial kidney.** Mesonephros. Develops subsequent to the pronephros and is involved in the development of the permanent metanephros. B
- 32 **Mesonephric [Wolffian] duct.** Ductus mesonephricus. Excretory duct formed by the pronephros. It forms the ductus deferens in the male. B
- 33 **Paramesonephric [[Müllerian]] duct.** Ductus paramesonephricus. Duct formed by an epithelial invagination lateral to the mesonephric duct. It gives rise to the uterus, uterine tube and a part of the vagina. B
- 34 **Primitive urogenital sinus.** Sinus urogenitalis primitivus. Anterior portion of the cloaca separated by the embryonic urorectal septum. It gives rise to the inferior pole of the urinary bladder, urethra and vestibule of the vagina. B



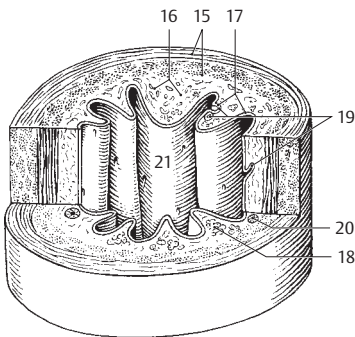
A External female genitalia, with pubic bone



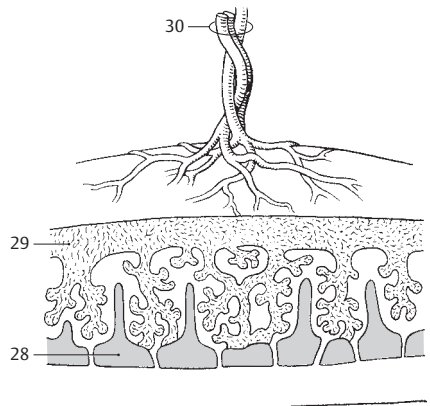
B Development of the female urogenital system



C Gravid uterus, schematic

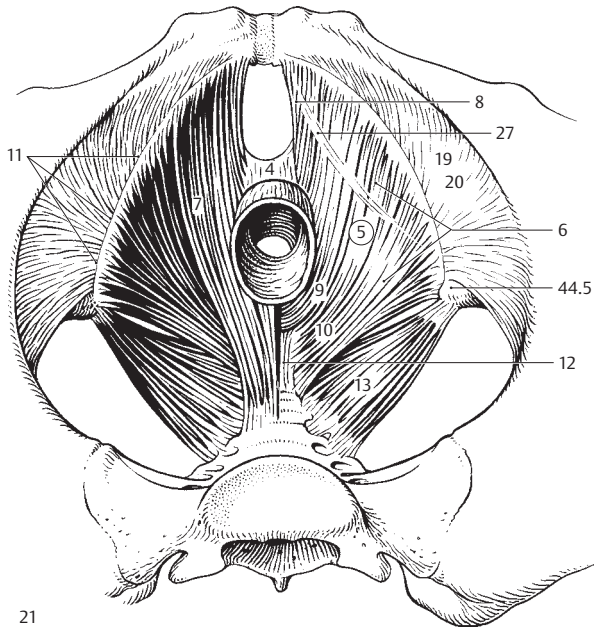


D Female urethra

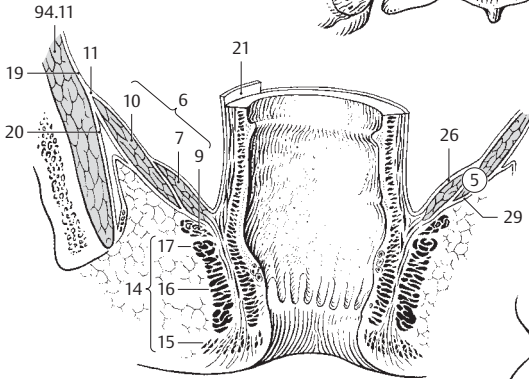


E Placenta, schematic

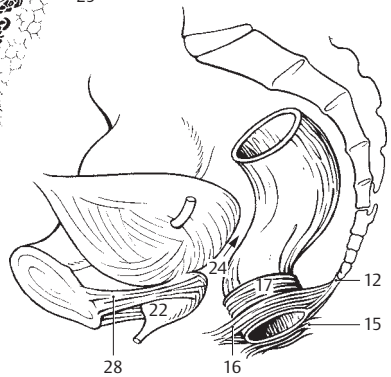
- 1 **PERINEUM.** Segment between anus and genitalia.
- 2 **Perineal raphe.** Raphe perinealis. Raphe along the medial line of the perineum; it is continuous with the scrotal raphe.
- 3 **Perineal muscles.** Musculi perinei (perineales).
- 4 **Perineal body.** Central tendon of perineum. Centrum tendineum perinei. Tough fibromuscular mass in the median plane of the perineum where the perineal muscles unite between the rectum and vagina or urethra. A
- 5 **PELVIC DIAPHRAGM.** Diaphragma pelvis. Muscular floor of pelvis formed mainly by the levator ani muscle. A B
- 6 **M. levator ani.** Funnel-shaped muscle extending from the pubis and obturator foria to the anus and the anococcygeal ligament. I: Pudendal nerve and S3–4. A B
- 7 **M. pubococcygeus.** Fibers of the levator ani passing from the pubis to the perineal body, sphincter ani muscle and coccyx. A B
- 8 **M. levator prostatae (m. pubovaginalis).** Fibers of the pubococcygeus muscle radiating into the fascia of the prostate or the wall of the vagina. A
- 9 **M. puborectalis.** Muscle running posteriorly from the pubis and looping around the perineal flexure of the rectum. A
- 10 **M. iliococcygeus.** Muscle passing from the tendinous arch of the levator ani to the coccyx and the anococcygeal ligament. A B
- 11 **Tendinous arch of levator ani muscle.** [Arcus tendineus m. levatoris ani]. Arched tendinous thickening of the obturator fascia at the origin of the levator ani. A B
- 12 **Anococcygeal ligament.** Lig. anococcygeum. Tough connective tissue tract between the anus and coccyx. A C
- 13 **M. coccygeus.** Fan-shaped muscle fibers passing from the ischial spine to the lateral surfaces of the sacrum and coccyx. They are fused with the sacrospinous ligament. I: S4–5. A
- 14 **M. sphincter ani externus.** External anal sphincter. Skeletal muscle that consists of the three parts listed below. I: Pudendal nerve. B C
- 15 **Subcutaneous part.** Pars subcutanea. More superficial portion of the external anal sphincter radiating into the dermis in front of and behind the anus. B C See p. 177 B
- 16 **Superficial part.** Pars superficialis. Fibers of external anal sphincter which spread out between the perineal body and the anococcygeal ligament. B C
- 17 **Deep part.** Pars profunda. Purely circular portion of the external anal sphincter which attains a height of 3–4 cm. B C
- 18 **Pelvic fascia.** Fascia pelvis. Connective tissue covering of the pelvic viscera and the pelvic wall. It is the caudal continuation of the transversalis fascia.
- 19 **Parietal pelvic fascia.** Fascia pelvis parietalis. Portion of the pelvic fascia lining the pelvic wall. A B
- 20 **Obturator fascia.** Fascia obturatoria. Especially strong portion of the pelvic fascia situated on the obturator internus muscle. A B
- 21 **Visceral pelvic (endopelvic) fascia.** Fascia pelvis visceralis [[f. endopelvicina]]. Portion of the pelvic fascia that invests the pelvic viscera. B
- 22 **Prostatic fascia.** Fascia prostatae. Fascia of prostate which fuses with the surrounding tissues. C
- 23 **Peritoneoperineal fascia.** Fascie peritoneoperinealis. Collective term for 24 and 25.
- 24 **Rectovesical septum.** Septum rectovesicale. Connective tissue partition between the rectum and urinary bladder. It is a part of the pelvic and prostatic fascia. C
- 25 **Rectovaginal septum.** Septum rectovaginale. Connective tissue partition between the rectum and vagina. It is a part of the pelvic fascia.
- 26 **Superior fascia of pelvic diaphragm.** Fascia diaphragmatis pelvis superior. Fascial covering on the superior surface of the pelvic diaphragm (facing the pelvis). B
- 27 **Tendinous arch of pelvic fascia.** Arcus tendineus fasciae pelvis. Tendinous reinforcement of the pelvic fascia that arches from the symphysis downward to the ischial spine. It corresponds to the band where the visceral vessels and nerves leave the lateral wall of the pelvis and where the pelvic connective tissue is especially firmly united with the pelvic wall. A
- 28 **Puboprostatic (pubovesical) ligament.** Lig. puboprostaticum (pubovesicale). Reinforced connective tissue permeated with smooth muscle passing from the pubic symphysis to the prostate (to the neck of the bladder in females). C
- 29 **Inferior fascia of pelvic diaphragm.** Fascia diaphragmatis pelvis inferior. Fascia covering the levator ani muscle on the side of the ischioanal fossa. B



A Pelvic floor from above

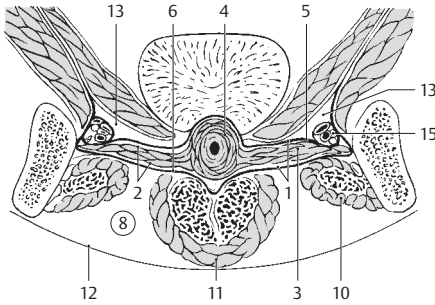


B Frontal section through the true pelvis (pelvis minor)

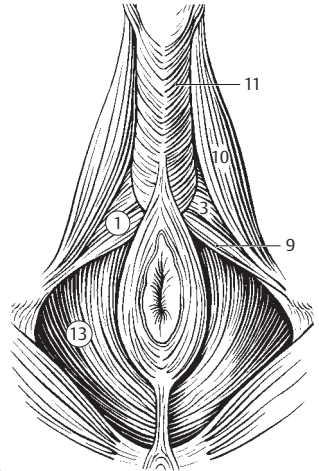


C Male pelvic viscera

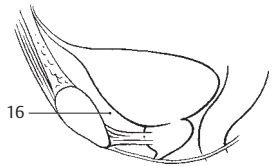
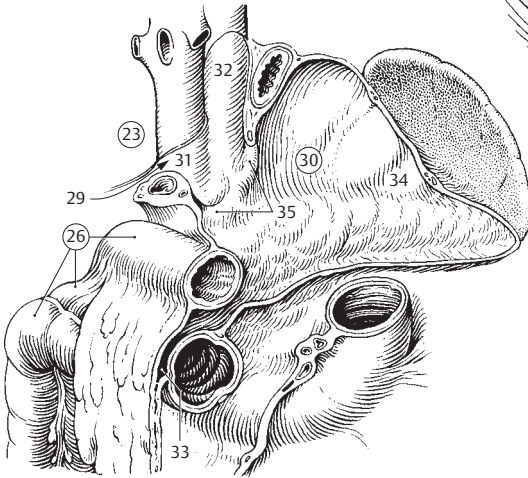
- 1 **Urogenital diaphragm.** [[Diaphragm urogenitale]]. Fibromuscular wall spread out between the right and left inferior rami of the pubis. A B E
- 2 **Deep perineal space.** Spatium perinei profundum. Space between the inferior and superior fascia of the urogenital diaphragm. Contents: Deep transversus perinei and sphincter urethrae muscles; bulbo-urethral glands; nerves and vessels for the penis. A
- 3 **M. transversus perinei profundus.** Trapezoid-shaped muscular plate stretched out in the pubic arch. I: Pudendal nerve. A B E F
- 4 **M. sphincter urethrae.** Muscular fibers surrounding the membranous part of the urethra. I: Pudendal nerve. A E F
- 4a **M. compressor urethrae.** Muscle fibers that extend distally from the m. sphincter urethrae to the ramus of the ischium. F
- 4b **M. sphincter urethrovaginalis.** Muscle fibers that extend distally from the m. compressor urethrae to the bulb of the vestibule. F
- 5 **Superior fascia of urogenital diaphragm.** Fascia diaphragmatis urogenitalis superior. Fascia of the deep transverse perinei muscle located on the side of the ischio-anal fossa. A
- 6 **Perineal membrane [inferior fascia of urogenital diaphragm].** Membrana perinei [fascia diaphragmatis urogenitalis inferior]. Fascia on the anteroinferior surface of the deep transverse perinei muscle.
- 7 **Transverse perineal ligament.** Lig. transversum perinei. Thickened fusion of both fasciae of the urogenital diaphragm at the anterior, upper margin of the deep transverse perinei muscle. E
- 8 **Superficial perineal space.** Spatium perinei superficialis. Space between the superficial perineal fascia and the inferior fascia of the urogenital diaphragm. It contains the root of the penis. A
- 9 **M. transversus perinei superficialis.** Inconstant separated portion of the deep transverse perineal muscle. It radiates out into the perineal body. I: Pudendal nerve. B
- 10 **M. ischiocavernosus.** Muscle that arises from the ramus of the ischium, lies on the crus of the penis and attaches to its tunica albuginea. I: Pudendal nerve. A B
- 11 **M. bulbospongiosus [m. bulbocavernosus].** Muscle that arises from the perineal body and the median raphe of the corpus spongiosum, then passes lateral to them and extends to the inferior perineal membrane and the dorsum of the penis. In the female it follows the course of the bulb of the vestibule. I: Pudendal nerve. A B; see also page 225 D
- 12 **Superficial perineal fascia.** Fascia perinei superficialis. Fascia forming the anteroinferior border of the superficial perineal space. A
- 13 **ISCHIOANAL FOSSA.** Fossa ischioanal. Space between the levator ani and obturator internus muscles. It is bordered anteroinferiorly by the urogenital diaphragm. A B
- 14 **Fat body of ischioanal fossa.** Corpus adiposum fossae ischioanal. A pad of fat in the ischioanal fossa.
- 15 **Pudendal [Alcock's] canal.** Canalis pudendalis [Alcock]. Splitting of obturator fascia in lateral wall of ischioanal fossa to form a tunnel for passage of the pudendal vessels and nerves. A
- 16 **Retropubic space.** Spatium retropubicum [spatium praevesiciale; cavum Retzii]. Space between the urinary bladder and the pubis filled with loose connective tissue and bounded inferiorly by the puboprostatic ligament. C
- 17 **PERITONEUM.** Serous membrane that lines the peritoneal cavity.
- 18 **Abdominal cavity.** [[Cavitas abdominalis]].
- 19 **Peritoneal cavity.** Cavitas peritonealis. Space in abdominal cavity enclosed by peritoneum.
- 19a **Extraperitoneal space.** Spatium extraperitoneale. Space in connective tissue with no relationship to the peritoneum.
- 20 **Retroperitoneal space.** Spatium retroperitoneale. Space between the peritoneum and the transversalis fascia.
- 21 **Extraperitoneal fascia.** Fascia extraperitonealis. Connective tissue layer of varying thickness beneath the peritoneum.
- 22 **Extraperitoneal organ.** Organum extraperitoneale. Organ in extraperitoneal space.
- 23 **Parietal peritoneum.** Peritoneum parietale. Peritoneum of abdominal wall. D
- 24 **Tunica serosa.** Serous membrane lined by smooth, simple peritoneal epithelium.
- 25 **Tela subserosa.** Connective tissue layer beneath the serosa.
- 26 **Visceral peritoneum.** Peritoneum viscerale. Peritoneum covering the abdominal viscera. D
- 27 **Tunica serosa.** See 24.
- 28 **Tela subserosa.** See 25.
- 29 **Epiploic foramen [of Winslow].** Foramen omentale (epiploicum). Opening into the lesser sac behind the hepatoduodenal ligament. D
- 30 **Omental bursa [lesser sac of peritoneum].** Bursa omental. A peritoneal cavity situated mainly behind the stomach. D
- 31 **Vestibule of omental bursa.** Vestibulum bursae omentalis. Portion of the omental bursa situated near the caudate lobe of the liver and bounded by the gastropancreatic folds on the left. D
- 32 **Upper omental recess.** Recessus superior omentalis. Upwardly directed recess between the inferior vena cava and the esophagus. D
- 33 **Lower omental recess.** Recessus inferior omentalis. Lower portion of the omental bursa located between the stomach and transverse colon, or, in some cases, between the anterior and posterior layers of the greater omentum. D
- 34 **Splenic recess.** Recessus splenicus (lienalis). Left portion of lower omental recess bounded by splenic ligaments. D
- 35 **Gastropancreatic folds.** Plicae gastropancreaticae. Folds in the posterior wall of the lesser sac formed by the left gastric and common hepatic arteries. D
- 35a **Hepatopancreatic fold.** Plica hepatopancreatica. Also called plica gastropancreatica dextra. Peritoneal fold that encloses the common hepatic artery.



A Frontal section of male pelvis

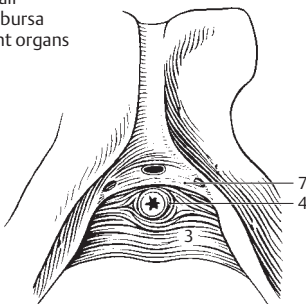


B Male perineal musculature from below

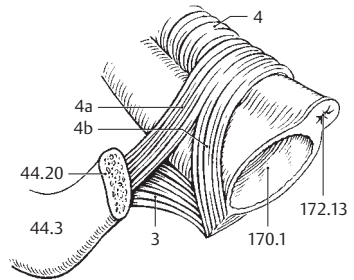


C Urinary bladder, lateral view

D Posterior wall of omental bursa and adjacent organs

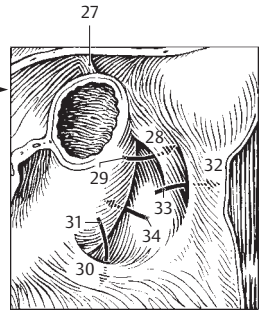
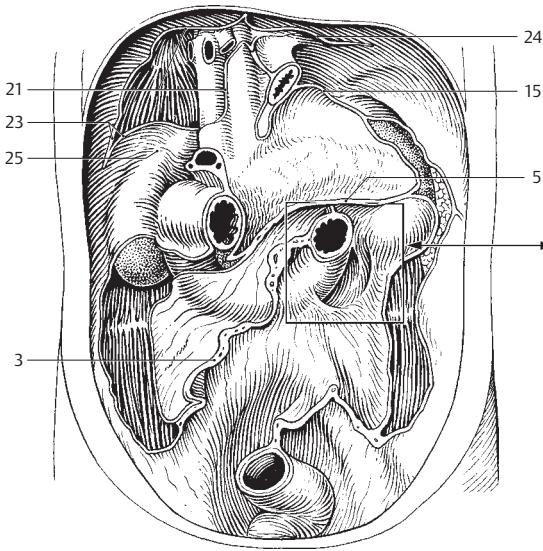


E Urogenital diaphragm



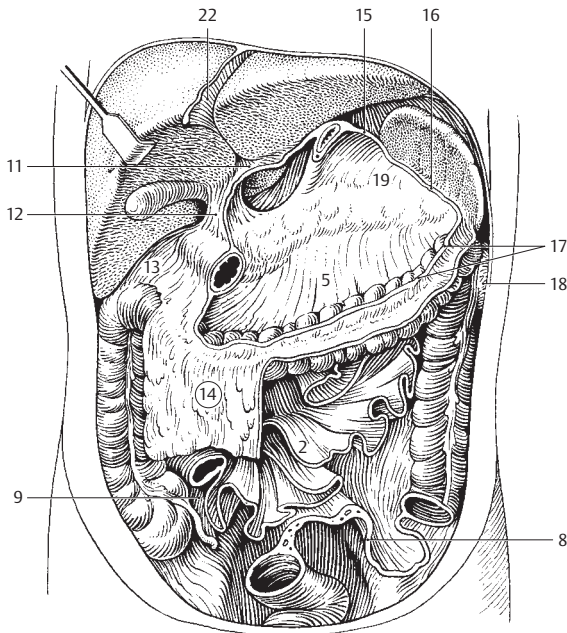
F Female urogenital sphincter according to Oelrich

- 1 **Dorsal mesentery.** [[Mesenterium dorsale commune]]. Embryologically original, common, dorsal suspensory ligament of the still undifferentiated intestinal tube.
- 2 **Mesentery.** Mesenterium. Dorsal peritoneal fold for the fixation of the intraperitoneal small intestine. It transports blood vessels and nerves. B
- 3 **Root of mesentery.** Radix mesenterii. Line of attachment that extends from the posterior wall of the abdominal cavity near the second lumbar vertebra to the right iliac fossa. A
- 4 **Mesocolon.** Peritoneal fold bearing vessels and nerves; it attaches and supplies the colon.
- 5 **Transverse mesocolon.** Mesocolon transversum. Suspensory ligament of the transverse colon. A B
- 6 **Mesocolon of ascending colon.** Mesocolon ascendens. It fuses with the posterior abdominal wall in the 4th embryonic month.
- 7 **Mesocolon of descending colon.** Mesocolon descendens. It fuses with the posterior abdominal wall in the 4th embryonic month.
- 8 **Sigmoid mesocolon.** Mesocolon sigmoideum. Suspensory ligament of sigmoid colon. B
- 9 **Mes-*o*appendix** [[mesenteriolium]]. Suspensory ligament of vermiform appendix. B
- 10 **Lesser omentum.** Omentum minus. Peritoneal sheet extending mainly between the stomach and liver.
- 11 **Hepatogastric ligament.** Lig. hepatogastricum. Part of the lesser omentum between the stomach and liver. B
- 12 **Hepatoduodenal ligament.** Lig. hepatoduodenale. Part of lesser omentum between the duodenum and liver. It contains the hepatic artery proper, bile duct and the portal vein. B
- 13 **Hepatocolic ligament.** [Lig. hepatocolicum]. Inconstant continuation of the hepatoduodenal ligament toward the right at the right colic flexure or near the transverse colon. B
- 14 **Greater omentum.** Omentum majus. Doubled peritoneal apron hanging down from the stomach and transverse colon; it contains variable amounts of fat. B
- 15 **Gastrophrenic ligament.** Lig. gastrophrenicum. Upper continuation of the phrenicosplenic and gastrosplenic ligaments between the stomach and diaphragm. A B
- 16 **Gastrosplenic (gastrolial) ligament.** Lig. gastrosplenicum (gastrolialene). Peritoneal connection from the lesser curvature of the stomach to the hilum of the spleen. B
- 17 **Gastrocolic ligament.** Lig. gastrocolicum. Peritoneal connection between the lesser curvature of the stomach and the omental tenia of the transverse colon. It is attached to the gastrosplenic ligament. B
- 18 **Phrenicocolic ligament.** Lig. phrenicocolicum. Peritoneal fold on the left side of the body, between the diaphragm and the descending colon. B
- 19 **Splenorenal (lienorenal, phrenicosplenic) ligament.** Lig. splenorenale (lienorenale, phrenicosplenicum). Peritoneal fold that extends from the diaphragm, kidney and pancreas to the hilum of the spleen; on the right, it is continuous with the transverse mesocolon. B
- 20 **Hepatic ligaments.** Ligg. hepatis.
- 21 **Coronary ligament.** Lig. coronarium. The line or reflection of the parietal peritoneum that extends from the diaphragmatic surface to the visceral peritoneum of the liver at the margin of the bare area. A
- 22 **Falciform ligament of liver.** Lig. falciforme (hepatis). Peritoneal fold from the anterior and inferior sides of the liver to the anterior abdominal wall. B
- 23 **Right triangular ligament.** Lig. triangulare dextrum. Triangular peritoneal fold between the right lobe of the liver and the diaphragm. It forms the right end of the coronary ligament. A
- 24 **Left triangular ligament.** Lig. triangulare sinisterum. Triangular peritoneal fold between the liver and diaphragm. It forms the left end of the coronary ligament. A
- 25 **Hepatorenal ligament.** Lig. hepatorenale. Continuation of the coronary ligament attached to the right kidney. A
- 26 **Folds and recesses.** Plicae et fossae (recessus).
- 27 **Fascia retinens rostralis.** Band passing upward at the duodenojejunal flexure, in some cases together with the suspensory muscle of the duodenum. See 124.10. A
- 28 **Superior duodenal fold (duodenojejunal fold).** Plica duodenalis superior (plica duodenojejunalis). Peritoneal fold on the left side of the duodenojejunal flexures and in front of the superior duodenal recess. It contains the inferior mesenteric vein. A
- 29 **Superior duodenal recess.** Recessus duodenalis superior. Peritoneal recess behind the superior duodenal fold. A
- 30 **Inferior duodenal fold (duodenumesocolic fold).** Plica duodenalis inferior (plica duodenumesocolica). Peritoneal fold just in front of duodenojejunal flexure. A
- 31 **Inferior duodenal recess.** Recessus duodenalis inferior. Peritoneal recess behind the inferior duodenal fold. A
- 32 **Paraduodenal fold.** [Plica paraduodenalis]. Peritoneal fold located on the left side of the duodenum. A
- 33 **Paraduodenal recess.** [Recessus paraduodenalis]. Peritoneal recess behind the paraduodenal fold that opens toward the right. A
- 34 **Retroduodenal recess.** [Recessus retroduodenalis]. Peritoneal recess between the aorta and the duodenum that opens toward the left. A



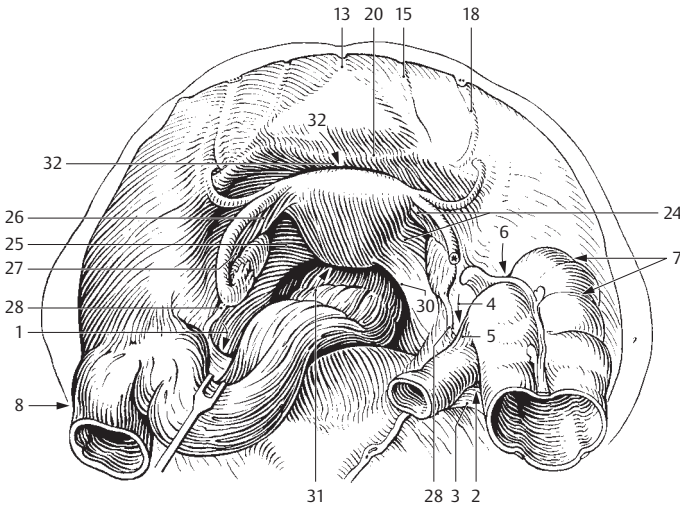
8

A Posterior abdominal wall

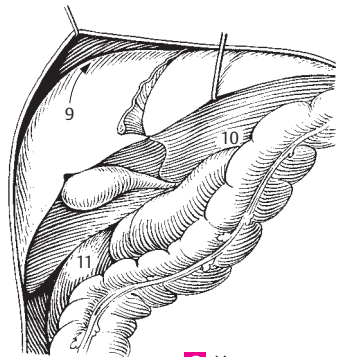


B Abdominal cavity after removal of stomach, small intestine and sigmoid colon

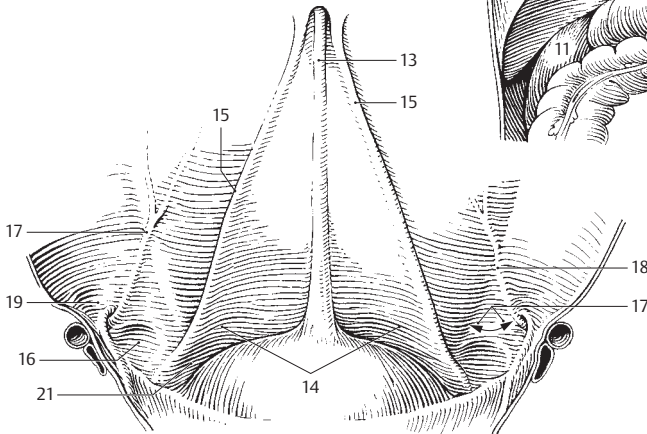
- 1 **Intersigmoid recess.** Recessus intersigmoideus. Peritoneal recess left of and below the root of the sigmoid mesocolon. A
- 2 **Superior ileocecal recess.** Recessus ileocaecalis superior. Peritoneal recess above the opening of the ileum into the cecum. A
- 3 **Vascular cecal fold.** Plica caecalis vascularis. Peritoneal fold in front of the superior ileocecal recess; it contains a branch of the ileocolic artery. A
- 4 **Inferior ileocecal recess.** Recessus ileocaecalis inferior. Peritoneal recess below the opening of the ileum into the cecum. A
- 5 **Ileocecal fold.** Plica ileocaecalis. Peritoneal fold in front of inferior ileocecal recess that extends inferiorly up to the appendix. A
- 6 **Retrocecal recess.** Recessus retrocaecalis. Peritoneal fold often present on the right side of the body behind the cecum or ascending colon. A
- 7 **Cecal folds.** Plicae caecales. Peritoneal folds outside the cecum. They correspond to the semilunar folds in the colon. A
- 8 **Paracolic sulci.** Sulci paracolici. Occasional pockets left of the descending colon. A
- 9 **Subphrenic recess.** Recessus subphrenici. Peritoneal recess between the diaphragm and both lobes of the liver, right and left of the falciform ligament; it is bounded posterosuperiorly by the coronary ligament. C
- 10 **Subhepatic recess.** Recessus subhepatici. Recess between the liver and transverse colon or adjoining viscera. C
- 11 **Hepatorenal recess.** Recessus hepatorenalis. Portion of the subhepatic recess bounded by the kidney and suprarenal gland. C
- 12 **Anterior parietal peritoneum.** Peritoneum parietale anterius.
- 13 **Median umbilical fold.** Plica umbilicalis mediana [[plica umbilicalis media]]. Fold passing from the apex of the urinary bladder to the umbilicus. It contains the remains of the urachus. A B
- 14 **Supravesical fossa.** Fossa supravesicalis. Shallow depression in front of the urinary bladder between the median and medial umbilical folds. B
- 15 **Medial umbilical fold.** Plica umbilicalis medialis [[plica umbilicalis lateralis]]. Fold corresponding to the obliterated umbilical artery. It is located in the anterior abdominal wall between the median umbilical (obliterated urachus) and lateral umbilical (inferior epigastric artery) folds. A B
- 16 **Medial inguinal fossa.** Fossa inguinalis medialis. Depression lying opposite the external inguinal ring between the medial and lateral umbilical folds. B
- 17 **Inguinal trigone.** Trigonum inguinale. Triangular area between the lateral margin of the rectus abdominis, inguinal ligament and lateral umbilical fold (inferior epigastric artery). B
- 18 **Lateral umbilical fold [epigastric fold].** Plica umbilicalis lateralis [[plica epigastrica]]. Peritoneal fold produced by the inferior epigastric artery. A B
- 19 **Lateral inguinal fossa.** Fossa inguinalis lateralis. Depression lateral to the lateral umbilical fold corresponding to the deep inguinal ring. B
- 20 **Transverse vesical fold.** Plica vesicalis transversa. Peritoneal fold extending transversely over the moderately filled bladder. It disappears when the bladder is full. A
- 21 **Paravesical fossa.** Fossa paravesicalis. Shallow depression lateral to the bladder. It is bounded laterally by the ductus deferens. B
- 22 **Urogenital peritoneum.** Peritoneum urogenitale. Peritoneum of the reproductive organs.
- 23 **Vaginal process of peritoneum.** [[Processus vaginalis peritonei]]. Finger-like diverticulum of the peritoneum that extends through the inguinal canal accompanying the descent of the testis.
- 24 **Broad ligament of uterus.** Lig. latum uteri. Peritoneal duplication between the uterus and lateral pelvic wall for transmission of vessels and nerves. A
- 25 **Mesometrium.** Portion of the broad ligament passing to the uterus. A
- 26 **Mesosalpinx.** Mesentery of uterine tube. A
- 27 **Mesovarium.** Mesentery of ovary. A
- 28 **Suspensory ligament of ovary.** Lig. suspensorium ovarii. Ligament derived from the cranial gonadal fold; it suspends the ovary superiorly and contains the ovarian vessels. A
- 29 **Ovarian fossa.** Fossa ovarica. Depression at the origin of the internal and external iliac arteries.
- 30 **Rectouterine fold.** Plica rectouterina. Peritoneal fold between the rectum and uterus. A
- 31 **Rectouterine pouch [[pouch of Douglas]].** Excavatio rectouterina. Deepest part of abdominal cavity between the rectum, uterus and the two rectouterine folds. A
- 32 **Vesicouterine pouch.** Excavatio vesicouterina. Peritoneal space between the uterus and bladder. A
- 33 **Rectovesical pouch.** Excavatio rectovesicalis. Deepest part of the abdominal cavity between the rectum and bladder in the male.



A View of the female true pelvis (pelvis minor) from above

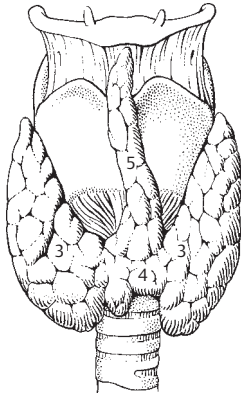


C Liver recess

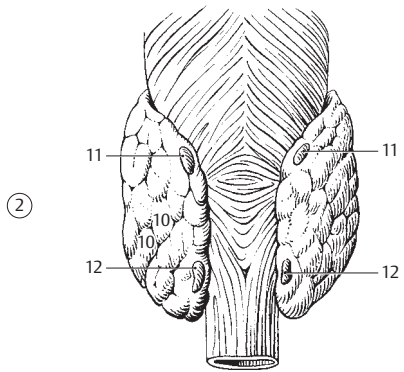


B Anterior abdominal wall, posterior view

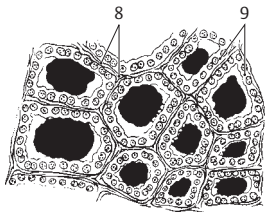
- 1 **ENDOCRINE GLANDS.** Glandulae endocrinae. Ductless glands.
- 2 **Thyroid gland.** Glandula thyroidea. Gland that produces the metabolism-stimulating hormones thyroxine and tri-iodothyronine. Pathological enlargement of the thyroid is called goiter. A B
- 3 **Right and left lobe.** Lobus glandulae thyroidea (dexter/sinister). Either of the lobes (right/left) of the thyroid situated on either side of the trachea. A
- 4 **Isthmus of thyroid gland.** Isthmus glandulae thyroidea. Band of tissue connecting the right and left lobes of the thyroid. A
- 5 **Pyramidal lobe.** [Lobus pyramidalis]. Remnant occasionally found as a median cord of thyroid tissue. A
- 6 **Accessory thyroid glands.** Glandulae thyroidea accessoriae. Dispersed islands of thyroid glandular tissue, e.g., at the base of the tongue.
- 7 **Fibrous capsule.** Capsula fibrosa. Double-layered capsule of thyroid gland.
- 8 **Stroma.** Connective tissue that forms the framework of the thyroid gland. C
- 9 **Parenchyma.** Cells essential for thyroid function. C
- 10 **Lobules.** Lobuli. Segments of thyroid parenchyma partitioned by connective tissue. B
- 11 **Superior parathyroid gland.** Glandula parathyroidea superior. Superior lentil-sized epithelial body located behind the thyroid. It produces parathormone, which regulates calcium and phosphorus metabolism. B
- 12 **Inferior parathyroid gland.** Glandula parathyroidea inferior. Inferior lentil-shaped epithelial body located behind the thyroid. It produces parathormone, which regulates calcium and phosphorus metabolism. B
- 13 **Hypophysis (pituitary gland).** Hypophysis (glandula pituitaria). Gland located within the sella turcica; it is the most versatile functioning endocrine gland. D
- 14 **Adenohypophysis (anterior lobe).** Large anterior lobe of pituitary derived from stomodeal ectoderm (Rathke's pouch). The cell types within its parenchyma are functionally and histochemically different. D
- 15 **Pars tuberalis.** Portion of adenohypophysis covering the hypophyseal stalk. D
- 16 **Pars intermedia.** Narrow middle part of the adenohypophysis containing colloidal cysts. D
- 17 **Pars distalis.** Anterior, largest segment of the adenohypophysis. D
- 18 **[[Pars pharyngea]].** Adenohypophyseal tissue that forms the remains of Rathke's pouch beneath the pharyngeal mucosa.
- 19 **Neurohypophysis (posterior lobe).** Smaller posterior portion of the pituitary gland derived from the diencephalon. It serves only as a storage depot for hormones. D
- 20 **Infundibulum.** Funnel-like stalk of the pituitary. D
- 21 **Neural lobe.** Lobus nervosus. True posterior lobe of pituitary gland. It is a hormone storage area. D
- 22 **Pineal body (gland).** Corpus pineale (glandula pinealis). Structure derived from the diencephalon; it lies above the quadrigeminal plate (lamina tecti). D
- 23 **Thymus.** Lymphatic organ situated behind the sternum. It undergoes regression at puberty. E
- 24 **Right/left lobe of thymus.** Lobus (dexter/sinister). E
- 25 **Accessory thymic nodules.** [Noduli thymici accessorii]. Scattered islands of thymic tissue.
- 26 **Thymic lobules.** Lobuli thymi. Lobules of thymus formed by connective tissue trabeculae. E
- 27 **Cortex of thymus.** Cortex thymi. Lymphocyte-rich cortical area.
- 28 **Medulla of thymus.** Medulla thymi. Lymphocyte-poor medullary region containing Hassell's (thymic) corpuscles.
- 29 **Adrenal (suprarenal) gland.** Glandula suprarenalis (adrenalis). Gland sitting like a cap medially on the upper pole of the kidney; it develops from two sources. F
- 30 **Anterior surface of adrenal gland.** Facies anterior. F
- 31 **Posterior surface of adrenal gland.** Facies posterior.
- 32 **Renal surface.** Facies renalis. Inferolaterally directed concave adrenal surface facing the kidney. F
- 33 **Superior margin.** Margo superior. Upper margin between the anterior and posterior surfaces of the adrenal gland. F
- 34 **Medial margin.** Margo medialis. Margin between the anterior and posterior surfaces of the adrenal gland. F
- 35 **Hilum.** Site of exit of central vein. It may be directed forward, downward or upward. F
- 36 **Central vein.** Vena centralis. Principal vein of the adrenal gland. It exists anterosuperiorly or anteroinferiorly. F
- 37 **Adrenal cortex.** Part of the adrenal gland that originally developed from the coelomic epithelium. It is divided into three zones. G
- 38 **Adrenal medulla.** Part of the adrenal gland that arises from the neural crest. It consists of chromaffin cells, sympathetic ganglion cells and venous sinuses. G
- 39 **Accessory suprarenal glands.** Glandulae suprarenales accessoriae. Scattered adrenal glandular tissue.



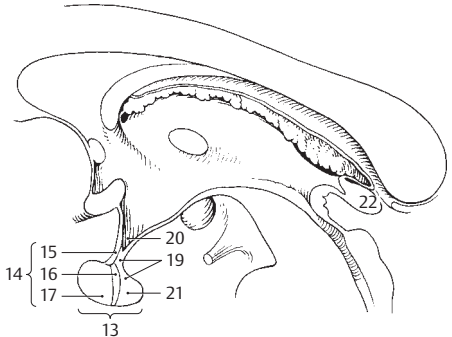
A Thyroid gland, anterior view



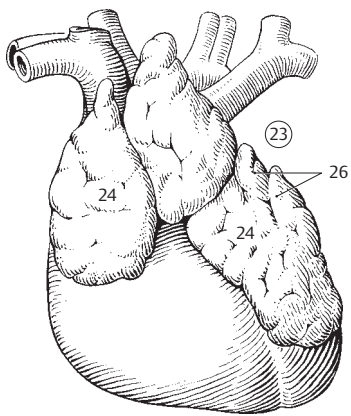
B Thyroid gland, posterior view



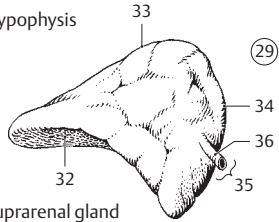
C Thyroid gland, histologic section



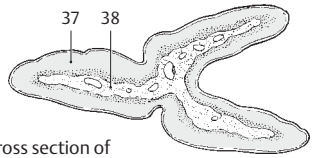
D Hypophysis



E Thymus

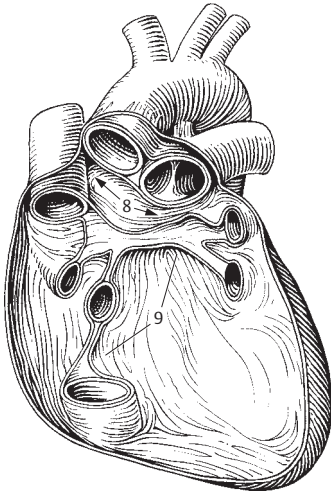


F Suprarenal gland

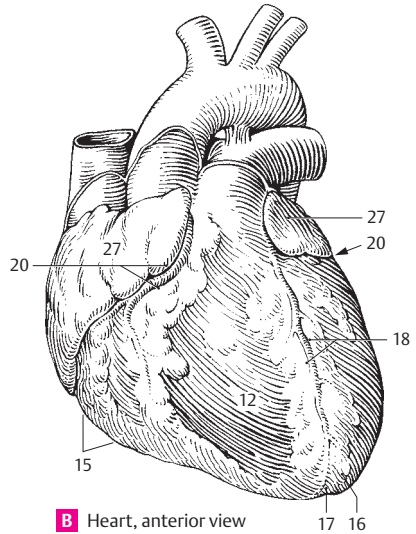


G Cross section of suprarenal gland

- SYSTEMA CARDIOVASCULARE.** Cardiovascular system.
- 1 **Pericardium.** Enveloping and gliding system of the heart comprising two layers, one of fibrous tissue and the other of bilayered serous tissue. A
 - 2 **Fibrous pericardium.** Pericardium fibrosum. Tough, external, connective tissue layer of the pericardium. It is partially fused with the diaphragm.
 - 3 **Sternopericardiac ligaments.** Ligg. sternopericardiaca. Connective tissue reinforcing the pericardium at the sternum.
 - 4 **Serous pericardium.** Pericardium serosum. Layer of simple squamous epithelium (mesothelium) which lines the fibrous pericardium (parietal layer) and covers the surface of the heart (visceral layer). Its visceral and parietal layers become continuous in the region of the great vessels.
 - 5 **Parietal layer.** Lamina parietalis. Serous layer of the pericardium. It lines the fibrous pericardium.
 - 6 **Visceral layer.** Lamina visceralis [epicardium]. Serous layer covering the surface of the heart (epicardium). It consists of mesothelium and a fibrous lamina propria.
 - 7 **Pericardial cavity.** Cavitas pericardialis. Space between the parietal and visceral layers of the serous pericardium. It contains a film of serous fluid.
 - 8 **Transverse sinus of pericardium.** Sinus transversus pericardii. Narrow passage in the pericardial space behind the aorta and pulmonary trunk and in front of the veins. A
 - 9 **Oblique sinus of pericardium.** Sinus obliquus pericardii. Recess in the pericardial space that extends between the right pulmonary veins and inferior cava and between the right and left pulmonary veins. A
 - 10 **HEART.** Cor.
 - 11 **Base of heart.** Basis cordis. Dorsally directed upper, broad surface of the nearly cone-shaped heart lying opposite to the apex. It is formed mainly by the posterior wall of the left atrium.
 - 12 **Sternocostal surface.** Facies sternocostalis [anterior]. Anteriorly directed convex surface of the heart. B D
 - 13 **Diaphragmatic surface.** Facies diaphragmatica [inferior]. Inferior surface of heart that touches the diaphragm. D
 - 14 **Pulmonary surface.** Facies pulmonalis. Lateral surface of heart that lies in contact with the lungs. D
 - 15 **Right margin.** Margo dexter. Right margin of the heart. It is often sharp-edged in the cadaver. B
 - 16 **Apex cordis.** Apex of heart directed forward, toward the left and downward. B
 - 17 **Incisure of apex of heart.** Incisura apicis cordis. Notch on the right near the apex of the heart at the site where the longitudinal interventricular grooves become continuous. B
 - 18 **Anterior interventricular groove.** Sulcus interventricularis anterior. Longitudinal groove on the anterior heart surface above the interventricular septum; it contains the anterior interventricular branch of the left coronary artery. B D
 - 19 **Posterior interventricular groove.** Sulcus interventricularis posterior. Longitudinal groove on the diaphragmatic surface of the heart marking the position of the interventricular septum; it contains the posterior interventricular branch of the right coronary artery. D
 - 20 **Coronary (atrioventricular) groove.** Sulcus coronarius. Groove that courses around the heart marking the atrioventricular boundary. B D
 - 21 **Right/left ventricle of heart.** Ventriculus [dexter/sinister] cordis. Due to functional requirements, the left ventricular wall is thicker than the right. C
 - 22 **Interventricular septum.** Septum interventriculare. Partition between the right and left ventricle marked externally by the anterior and posterior interventricular grooves.
 - 23 **Pars muscularis.** Muscular part of the interventricular septum; by far the largest and thickest part. C
 - 24 **Pars membranacea.** Membranous part of the interventricular septum. Located superiorly at the exit of the aorta. It is the shortest, thinnest and most fibrous part of the interventricular septum and arises from the endocardium. C
 - 25 **Atrioventricular septum.** Septum atrioventriculare. Portion of the membranous part of the interventricular septum between the right atrium and left ventricle above the root of the septal cusp. C
 - 26 **Right/left atrium of heart.** Atrium [dextrum/sinistrum] cordis. Thin-walled chambers. C
 - 27 **Auricle of atrium.** Auricula atrialis. Finger-like diverticulum of the right and left atrium. B C
 - 28 **Interatrial septum.** Septum interatriale. Partition between the right and left atrium.
 - 29 **Ostium atrioventriculare (dext. et sin.).** Atrioventricular opening (right/left) between the atrium and ventricle. D
 - 30 **Ostium of pulmonary trunk.** Ostium trunci pulmonalis. Opening between the right ventricle and the pulmonary trunk. D
 - 31 **Ostium of aorta.** Ostium aortae. Opening between the left ventricle and aorta. C D

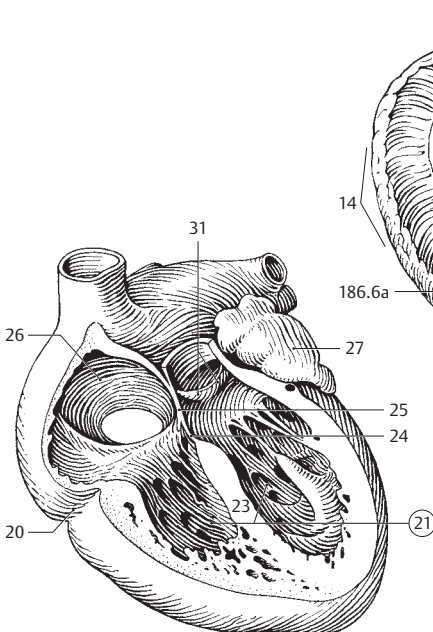


A Pericardium with great vessels

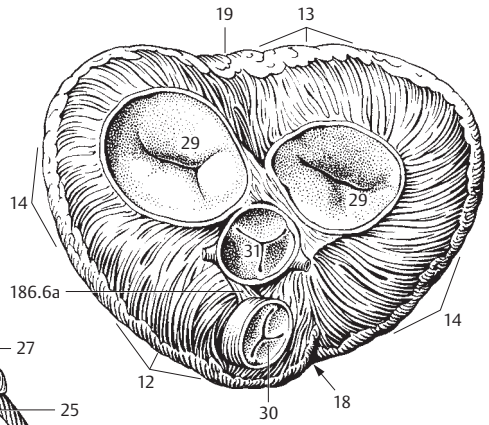


B Heart, anterior view

10



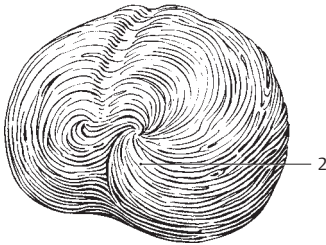
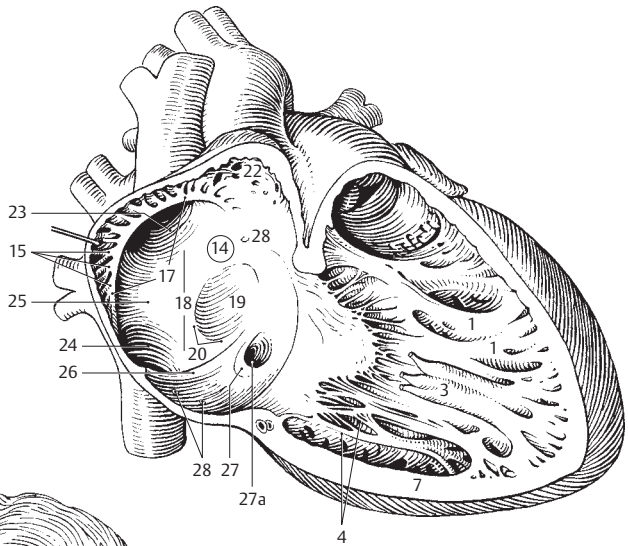
C Opened heart, left anterior view



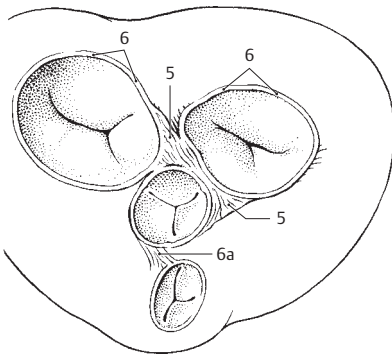
D Base of heart without atria

- 1 **Trabeculae carneae.** Muscular cords projecting into the lumen of the heart. A
- 2 **Vortex of heart.** Vortex cordis. Whorled arrangement of heart muscle cells at the apex of the heart. B
- 3 **Papillary muscles.** Musculi papillares. Cone-shaped muscles projecting into the lumen of the heart. They are connected to the valvular cusps via chordae tendineae and regulate the position of the cusps. A D
- 4 **Chordae tendineae.** Tendinous filaments between the papillary muscles and the atrioventricular valve. A D
- 5 **Right/left fibrous trigone.** Trigonum fibrosum dextrum/sinistrum. Connective tissue wedge between the aorta and the atrioventricular opening anteriorly and posteriorly. C
- 6 **Right/left fibrous ring.** Anulus fibrosus dexter/sinister. Fibrous rings between the atria and ventricles that give attachment to the atrioventricular valves. C
- 10 6a **Tendon of infundibulum.** Tendo infundibuli. Vestige of the embryonic spiral septum. C; see also page 185 D
- 7 **Myocardium.** Transversely striated heart muscle fibers with intercalated discs including the impulse-conducting system. A D
- 7a **Conducting system of heart.** Systema conduens cordis. D
- 8 **Sinoatrial (SA) node.** Nodus sinuatrialis [[Keith-Flack sinus node]]. Ribbon-like specialized cardiac muscle situated in front of the entrance of the superior vena cava. It represents the primary impulse formation center (pacemaker) which determines the rhythm of the heart. D
- 9 **Atrioventricular (AV) node.** Nodus atrioventricularis [[node of Aschoff-Tawara]]. Small complex of specialized cardiac muscle fibers in the interatrial septum below the fossa ovalis and in front of the opening of the coronary sinus. After a latency period, the impulse transmitted to it myogenically from the SA node is conducted further into the ventricle via the bundle of His and its crura. In case of SA node failure the AV node can take over the control of heart rhythm as a secondary pacemaker. D
- 10 **Atrioventricular (AV) bundle.** Fasciculus atrioventricularis. Bundle of impulse-conducting fibers between the AV node and the papillary muscles. D
- 11 **Trunk [[bundle of His]].** [[truncus]]. Initial segment of the AV bundle that extends up to the site where it divides into a right and left crus at the membranous part of the septum. D
- 12 **Crus (dextrum/sinistrum).** Right/left crus of the impulse-conducting system which extends right and left into the interventricular septum as far as the papillary muscles where they both ramify. D
- 12a **Subendocardial rami.** Rami subendocardiales. Superficial branches of the impulse-conducting system (Purkinje fibers). D
- 13 **Endocardium.** Internal serous lining of the heart containing simple squamous epithelium (endothelium).
- 14 **Right atrium.** Atrium dextrum. A D
- 15 **Pectinate muscles.** Mm. pectinati. Muscular bundle in the right atrium emanating from the terminal crest. They resemble the teeth of a comb. A
- 16 **Sulcus terminalis.** Terminal groove. Visible at the border between the embryonic sinus venosus and the atrium proper. It surrounds the opening regions of both venae cavae. D
- 17 **Terminal crest.** Crista terminalis. Curved muscular ridge in the interior of the right atrium at the border between the atrium proper and the embryonic sinus venosus. It marks the course of the sulcus terminalis. A
- 18 **Sinus venarum cavarum.** Smooth-walled space for blood from both venae cavae. It is bounded by the terminal crest. A
- 19 **Fossa ovalis.** Depression in the interatrial septum caused by the fetal foramen ovale. A
- 20 **Limbus fossae ovalis.** Slightly raised margin of the fossa ovalis. A
- 21 **[Foramen ovale].** Embryological opening in the interatrial septum that is present until birth.
- 22 **Right auricle.** Auricula dextra. Diverticulum of right atrium. A
- 23 **Opening of superior vena cava.** Ostium venae cavae superioris. A
- 24 **Opening of inferior vena cava.** Ostium venae cavae inferioris. A
- 25 **Intervenous tubercle.** Tuberculum intervenosum. Small elevation on the lateral wall of the right atrium between the openings of the venae cavae. A
- 26 **Valve of inferior vena cava.** Valvula venae cavae inferioris [[valvula Eustachii]]. Semilunar fold at the opening of the inferior vena cava. During fetal life it directs the blood into the foramen ovale. A
- 27 **Valve of coronary sinus.** Valvula sinus coronarii [[valvula Thebesii]]. Semilunar fold at the opening of the coronary sinus. A
- 27a **Opening of the coronary sinus.** Ostium sinus coronarii. A
- 28 **Foramina venarum minimarum.** Numerous openings of small veins [vv. Thebesii minimae] which convey blood from the tissues of the heart directly into the right atrium or other heart spaces. A

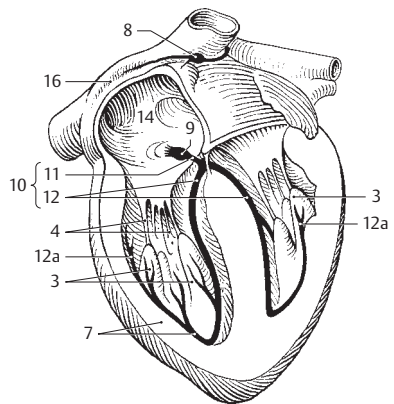
A Right atrium and ventricle opened



B Apex of the heart from below

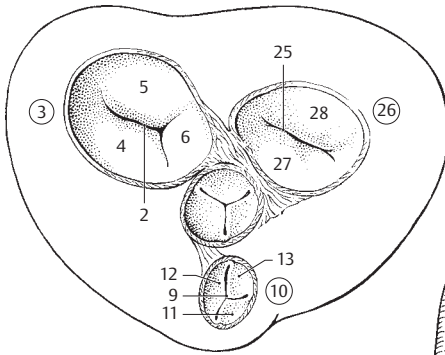


C Valves of the heart from above

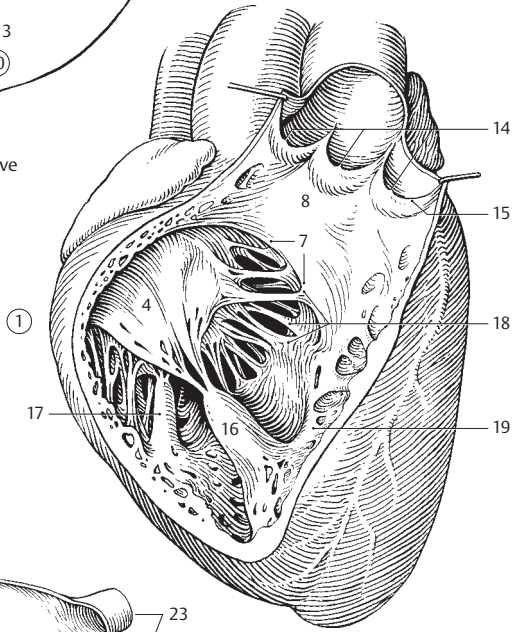


D Internal conduction system of heart

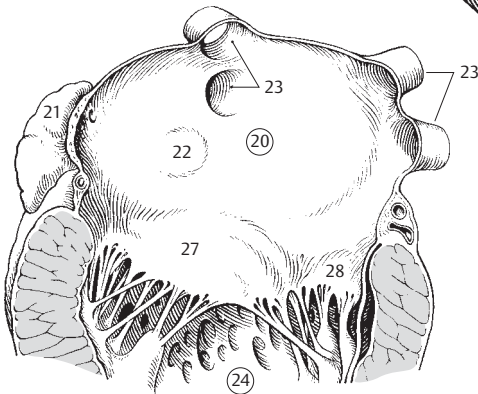
- 1 **Right ventricle.** *Ventriculus dexter.* C
- 2 **Right atrioventricular opening.** *Ostium atrioventriculare dextrum.* Opening between the right atrium and the right ventricle. A
- 3 **Right atrioventricular (tricuspid) valve.** *Valva atrioventricularis dextra (v. tricuspidalis).* Valvular apparatus between the right atrium and right ventricle comprised of three parts which arise from the fibrous ring and, by means of the chordae tendineae, are attached to the papillary muscles of the right ventricle. A
- 4 **Anterior cusp.** *Cuspis anterior.* A C
- 5 **Posterior cusp.** *Cuspis posterior.* A
- 6 **Septal cusp.** *Cuspis septalis.* It arises from the septum. A
- 7 **Supraventricular crest.** *Crista supraventricularis.* Muscular ridge which separates the conus arteriosus from the rest of the ventricle. C
- 8 **Conus arteriosus [infundibulum].** Funnel-shaped, smooth-walled outflow tract in front of the opening into the pulmonary trunk. It represents the embryonic bulbus cordis. C
- 9 **Opening of pulmonary trunk.** *Ostium trunci pulmonalis.* Beginning of the pulmonary trunk flanked by the pulmonary valve. A
- 10 **Valve of pulmonary trunk.** *Valve trunci pulmonalis.* It is made up of three parts. A
- 11 **Anterior semilunar cusp of pulmonary valve.** *Valvula semilunaris anterior.* A
- 12 **Right semilunar cusp of pulmonary valve.** *Valvula semilunaris dextra.* A
- 13 **Left semilunar cusp of pulmonary valve.** *Valvula semilunaris sinistra.* A
- 14 **Nodules of semilunar cusps.** *Noduli valvularum semilunarium.* Small thickenings in the middle of each free margin of the semilunar cusps that seal the wedge-like space between the three cusps when closed. C
- 15 **Lunules of semilunar cusps.** *Lunulae valvularum semilunarium.* Thin, crescentic area on both side of the nodules at the margin of the cusps. C
- 16 **Anterior papillary muscle.** *Musculus papillaris anterior.* Large anteriorly situated muscle. C
- 17 **Posterior papillary muscle.** *Musculus papillaris posterior.* C
- 18 **Septal papillary muscles.** [[*Musculi papillares septales*]]. Short papillary muscles sometimes found arising from the interventricular septum. C
- 19 **Septomarginal trabecula.** *Trabecula septomarginalis.* Muscular bundle extending from the interventricular septum to the base of the anterior papillary muscle and containing the right crus of the bundle of His. C
- 20 **Left atrium.** *Atrium sinistrum.* B
- 21 **Left auricle.** *Auricula sinistra.* Hollow finger-like diverticulum of the left atrium located left of the pulmonary trunk. B
- 21a **Musculi pectinati.** Muscular trabeculae in the left atrium that resemble the teeth of a comb.
- 22 **Valve of foramen ovale.** *Valvula foraminis ovalis [falx septi].* Floor of the fossa ovalis derived from the septum primum. In the fetus it is pushed into the left atrium by the flow of blood. B
- 23 **Ostia venarum pulmonalium.** Openings of pulmonary veins into the left atrium. B
- 24 **Left ventricle.** *Ventriculus sinister.* B
- 25 **Ostium atrioventriculare sinistrum.** Left atrioventricular opening between the left atrium and left ventricle. A
- 26 **Left atrioventricular (mitral) valve.** *Valva atrioventricularis sinistra (v. mitralis) [[valvula bicuspidalis]].* Valvular apparatus between the left atrium and left ventricle. It consists of two parts which arise from the fibrous ring and are united with the papillary muscles of the left ventricle by means of chordae tendineae. A
- 27 **Anterior cusp.** *Cuspis anterior.* Cusp situated anterior to the interventricular septum. A B
- 28 **Posterior cusp.** *Cuspis posterior.* Cusp situated posterior to the lateral wall. A B
- 28a **Cuspidae commissurales.**



A Valves of the heart from above

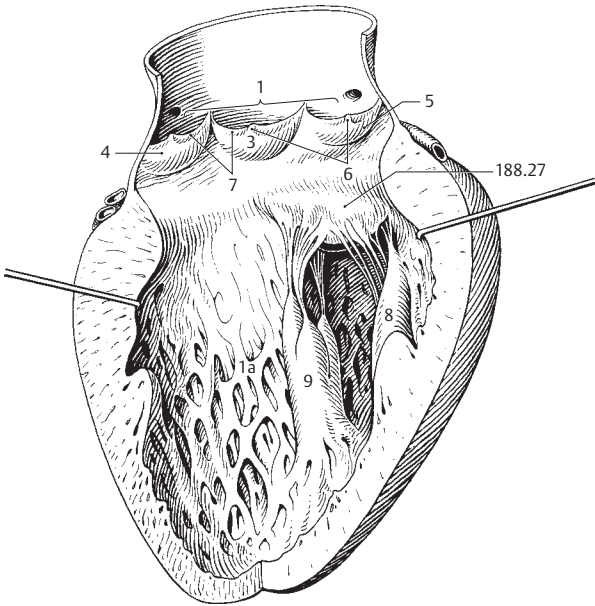


C Right ventricle opened

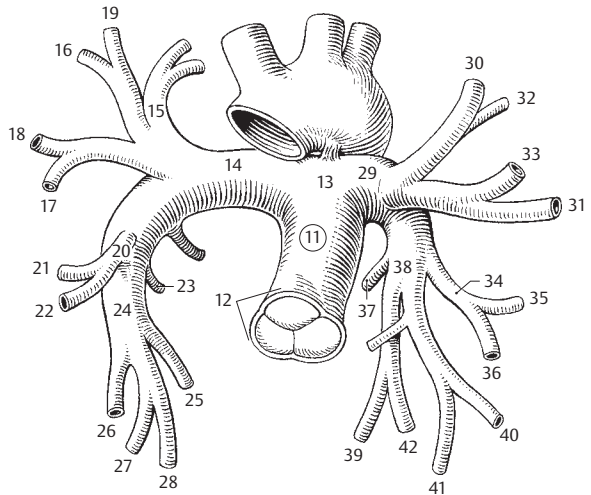


B Left atrium opened

- 1 **Ostium aortae.** Opening of left ventricle leading into the aorta. A
- 1a **Trabeculae carneae.** Muscle bundles projecting into the lumen of the heart. A
- 2 **Aortic valve.** Valva aortae. Tripartite valvular apparatus lying at the beginning of the aorta. A
- 3 **Posterior semilunar cusp of aortic valve.** Valvula semilunaris posterior. A
- 4 **Right semilunar cusp of aortic valve.** Valvula semilunaris dextra. A
- 5 **Left semilunar cusp of aortic valve.** Valvula semilunaris sinistra. A
- 6 **Nodules of semilunar cusps.** Noduli valvularum semilunarium. Thickenings in the middle of each free margin of a semilunar cusp that seals the wedge-shaped space between the three cusps when closed. A
- 7 **Lunules of semilunar cusps.** Lunulae valvularum semilunarium. Thin, crescentic areas near the margin of the semilunar cusps on either side of their nodules. A
- 8 **Anterior papillary muscle.** Musculus papillaris anterior. A
- 9 **Posterior papillary muscle.** Musculus papillaris posterior. A
- 10 **ARTERIES.** Arteria. Blood vessels which transport blood away from the heart.
- 11 **PULMONARY TRUNK.** Truncus pulmonalis. Arterial trunk between the right ventricle and the beginning of the left and right pulmonary arteries. B
- 12 **Sinuses of pulmonary trunk.** Sinus trunci pulmonalis. Three dilatations of the wall of the pulmonary trunk, each at the root of a semilunar valve. B
- 13 **Bifurcation of pulmonary trunk.** Bifurcatio trunci pulmonalis. Division of the pulmonary trunk into its two branches. B
- 14 **Right pulmonary artery.** A. pulmonalis dextra. It lies behind the ascending aorta. B
- 14a **Branches to superior lobe.** Rami lobi superioris.
- 15 **Apical branch.** Ramus apicalis. Branch to the apical segment. B
- 16 **Posterior descending branch.** Ramus posterior descendens. Branch to the lower part of the posterior segment. B
- 17 **Anterior descending branch.** Ramus anterior descendens. Branch to the lower part of the anterior segment. B
- 18 **Anterior ascending branch.** Ramus anterior ascendens. Branch to the upper part of the anterior segment. B
- 19 **Posterior ascending branch.** Ramus posterior ascendens. Branch to the upper part of the posterior segment. B
- 20 **Main branches for middle lobe.** Rami lobi medii. B
- 21 **Lateral branch.** Ramus lateralis. Branch to the lateral segment. B
- 22 **Branch to medial segment.** Ramus medialis. B
- 22a **Branches to inferior lobe.** Rami lobi inferioris.
- 23 **Superior (apical) branch to inferior lobe.** Ramus superior (apicalis) lobi inferioris. Branch to superior (apical) segment of right lower lobe. B
- 24 **Basal part.** Pars basalis. Branches supplying the basal segments of lower lobe. B
- 25 **Medial [cardiac] basal branch.** Ramus basalis medialis [[cardiacus]]. Branch to medial basal segment. B
- 26 **Anterior basal branch.** Ramus basalis anterior. Branch to anterior basal segment. B
- 27 **Lateral basal branch.** Ramus basalis lateralis. Branch to lateral basal segment. B
- 28 **Posterior basal branch.** Ramus basalis posterior. Branch to posterior basal segment. B
- 29 **Left pulmonary artery.** A. pulmonalis sinistra. B
- 29a **Branches to upper lobe.** Rami lobi superioris.
- 30 **Apical branch.** Ramus apicalis. Branch to upper part of apicoposterior segment. B
- 31 **Anterior descending branch.** Ramus anterior descendens. Branch to lower part of anterior segment. B
- 32 **Posterior branch.** Ramus posterior. Branch to lower part of apicoposterior segment. B
- 33 **Anterior ascending branch.** Ramus anterior ascendens. Branch to upper part of anterior segment. B
- 34 **Lingual branch.** Ramus lingularis. Branch supplying the two lingular segments. B
- 35 **Upper lingular branch.** Ramus lingularis superior. Branch to superior lingular segment. B
- 36 **Lower lingular branch.** Ramus lingularis inferior. Branch to inferior lingular segment. B
- 36a **Lower lobe branches.** Rami lobi inferioris.
- 37 **Upper branch to lower lobe.** Ramus superior lobi inferioris. Branch to superior segment of left lower lobe. B
- 38 **Basal part.** Pars basalis. Branches to basal part of left lower lobe. B
- 39 **Medial basal branch.** Ramus basalis medialis. Branch to medial basal segment. B
- 40 **Anterior basal branch.** Ramus basalis anterior. Branch to anterior basal segment. B
- 41 **Lateral basal branch.** Ramus basalis lateralis. Branch to lateral basal segment. B
- 42 **Posterior basal branch.** Ramus basalis posterior. Branch to posterior basal segment. B



A Left ventricle opened

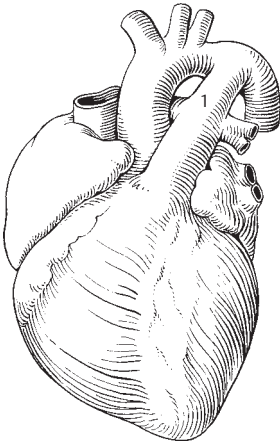


B Pulmonary arteries

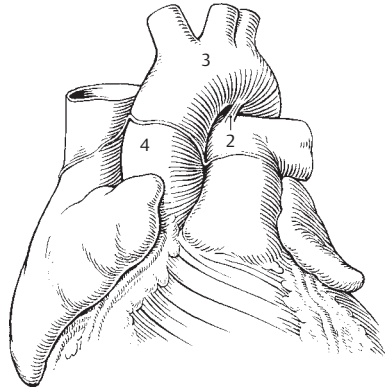
10

11

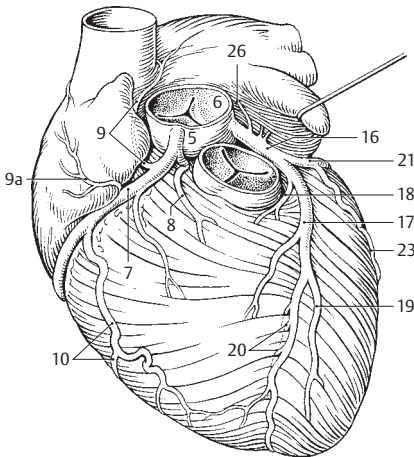
- 1 **Ductus arteriosus** [[Botalli]]. Short arterial duct in the fetus between the division of the pulmonary trunk and the arch of the aorta. It is patent until birth. A
- 2 **Ligamentum arteriosum**. Connective tissue remains of the ductus arteriosus. B
- 3 **AORTA**. Principal artery of the body. B
- 4 **ASCENDING AORTA**. Pars ascendens aortae. Proximal ascending part of the aorta up to the site where it loses its pericardium. B
- 5 **Bulb of aorta**. Bulbus aortae. Bulbous enlargement of the aorta caused by the aortic sinus. It lies distal to the root of the aorta. C
- 6 **Aortic sinus**. Sinus aortae. Dilatation of the aortic lumen at the level of each of the three aortic valvular cusps. C
- 7 **Right coronary artery**. A. coronaria dextra. It arises in the region of the right aortic sinus and courses in the right coronary groove. C D
- 7a **Atrioventricular branches**. Rami atrioventriculares. Branches that occupy the atrioventricular groove and supply the AV node D.
- 8 **Branch to conus arteriosus**. Ramus coni arteriosi. Inferior branch. C
- 9 **Branch to sinuatrial node**. Ramus nodi sinuatrialis. Most frequent branch (55%) that leads to a vascular plexus at the entrance of the superior vena cava and then to the SA node. C
- 9a **Atrial branches**. Rami atriales. Branches to right atrium. C
- 10 **Right marginal branch**. Ramus marginalis dexter. Inferior branch to outer margin of the right ventricle. C D
- 11 **Intermediate atrial branch**. Ramus atrialis intermedius. Superior branch on posterior side of right atrium. D
- 12 **Posterior interventricular branch**. Ramus interventricularis posterior. Terminal branch of right coronary artery lying in posterior interventricular groove. D
- 13 **Septal interventricular branches**. Rami interventriculares septales. Branches in interventricular septum. D
- 14 **Branch to atrioventricular node**. Ramus nodi atrioventricularis. Branch extending from the beginning of the branch of the right coronary artery to the AV node. D
- 15 **Right posterolateral branch**. [Ramus posterolateralis dexter]. Branch occasionally found at posterior wall of left ventricle. D
- 16 **Left coronary artery**. A. coronaria sinistra. Artery arising in region of left aortic sinus. C
- 17 **Anterior interventricular branch**. Ramus interventricularis anterior. Branch coursing in anterior interventricular groove. C
- 18 **Left branch to conus arteriosus**. Ramus coni arteriosi. Rare. C
- 19 **Lateral branch**. Ramus lateralis. Left branch at anterior wall of left ventricle. C
- 20 **Septal interventricular branches**. Rami interventriculares septales. Perforating branches for anterior 2/3 of interventricular septum. C
- 21 **Circumflex branch**. Ramus circumflexus. Branch coursing in left coronary groove as a continuation of left coronary artery. C D
- 22 **Anastomotic atrial branch**. Ramus atrialis anastomoticus. Branch of the circumflex branch of the LCA that supplies the atrial septum. It anastomoses with branches of the right coronary artery.
- 22a **Atrioventricular branches**. Rami atrioventriculares. Distal portion of circumflex branch in atrioventricular groove. D
- 23 **Left marginal branch**. Ramus marginalis sinister. Branch at outer margin of left ventricle. C
- 24 **Intermediate atrial branch**. Ramus atrialis intermedius. Atrial branch on posterior side. D
- 25 **Left posterior ventricular branch**. Ramus posterior ventriculi sinistri. Inconstant branch on posterior side of left ventricle. D
- 26 **Sinuatrial node branch**. [Ramus nodi sinuatrialis]. Branch that frequently (45%) extends from beginning of left coronary artery to SA node. C
- 27 **Atrioventricular node branch**. [Ramus nodi atrioventricularis]. Branch that occasionally supplies the AV node.
- 27a **Atrial branches**. Rami atriales. Branches to left atrium.



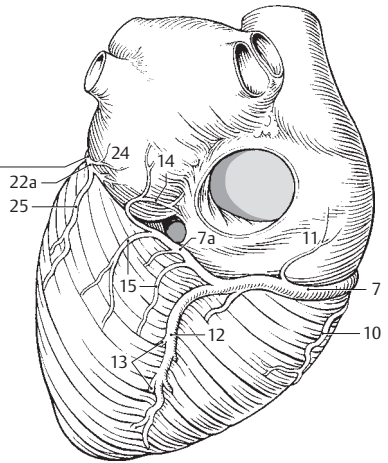
A Fetal heart



B Aorta and pulmonary trunk, anterior view

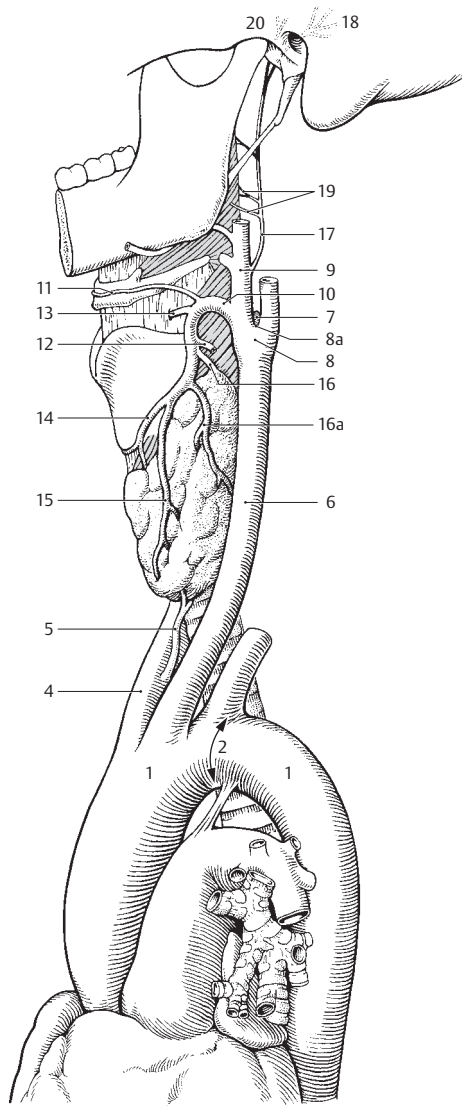


C Cardiovascular system anterior view



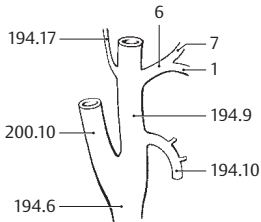
D Cardiovascular system posterior view

- 1 **ARCH OF AORTA.** Arcus aortae. Part of aorta situated between the ascending and descending parts. A
- 2 **Isthmus aortae.** Narrowing of aorta between left subclavian artery and ligamentum arteriosum. A
- 3 **Para-aortic bodies.** Corpora para-aortica. Irregular islands of chromaffin tissue scattered beside the aorta.
- 4 **Brachiocephalic trunk.** Truncus brachiocephalicus. First branch of arch of aorta. It divides into subclavian and right common carotid arteries. A
- 5 **(A. thyroidea ima).** Inconstant (10%) unpaired artery for thyroid gland arising from the brachiocephalic trunk or directly from the aorta. A
- 6 **COMMON CAROTID ARTERY.** A. carotis communis. Devoid of branches, it runs on each side of trachea and larynx below the sternocleidomastoid muscle. A
- 7 **Carotid body.** Glomus caroticum. Chemoreceptor at the bifurcation of the common carotid artery. It contains capillary tufts, epithelioid cells and abundant nerve endings. It responds predominantly to the oxygen content of the blood, less strongly to carbon dioxide changes. A
- 8 **Carotid sinus.** Sinus caroticus. Slight dilatation at the division of the common carotid artery. It contains baroreceptors. A
- 8a **Carotid bifurcation.** Bifurcatio carotica. Site of division of the common carotid artery. A
- 9 **EXTERNAL CAROTID ARTERY.** A. carotis externa. It extends from the carotid bifurcation to its terminal division into the superficial temporal and maxillary arteries at the neck of the mandible. A
- 10 **Superior thyroid artery.** A. thyroidea superior. First branch of external carotid artery. It mainly supplies parts of the larynx and the thyroid gland. A
- 11 **Infrathyoid branch.** Ramus infrahyoideus. It courses along the hyoid bone and anastomoses with the branch from the opposite side. A
- 12 **Sternocleidomastoid branch.** Ramus sternocleidomastoideus. Branch that supplies the sternocleidomastoid muscle. A
- 13 **Superior laryngeal artery.** A. laryngea superior. It penetrates the thyrohyoid membrane and lies beneath the mucosa of the piriform recess. A
- 14 **Cricothyroid branch.** Ramus cricothyroideus. Branch that supplies the cricothyroid muscle and the interior of the larynx. It anastomoses with the branch from the opposite side. A
- 15 **Anterior glandular branch.** Ramus glandularis anterior. It mainly supplies the anterior portion of the thyroid gland. A
- 16 **Posterior glandular branch.** Ramus glandularis posterior. It mainly supplies the upper portion of the thyroid gland but also the posterior portion. A
- 16a **Lateral glandular branch.** Ramus glandularis lateralis. It mainly supplies the lateral portion of the thyroid gland. A
- 17 **Ascending pharyngeal artery.** A. pharyngea ascendens. It arises from the posteroinferior aspect of the external carotid artery and passes between the pharynx and the musculature of the styloid process up to the base of the skull. A
- 18 **Posterior meningeal artery.** A. meningea posterior. Artery that lies lateral to the internal carotid artery and passes through the jugular foramen. It supplies the dura of the posterior cranial fossa. A
- 19 **Pharyngeal branches.** Rami pharyngeales. Branches that supply the wall of the pharynx. A
- 20 **Inferior tympanic artery.** A. tympanica inferior. It reaches the tympanic cavity through the tympanic canaliculus. A

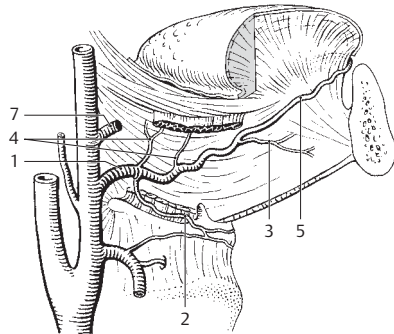


A Arch of aorta and vessels of neck

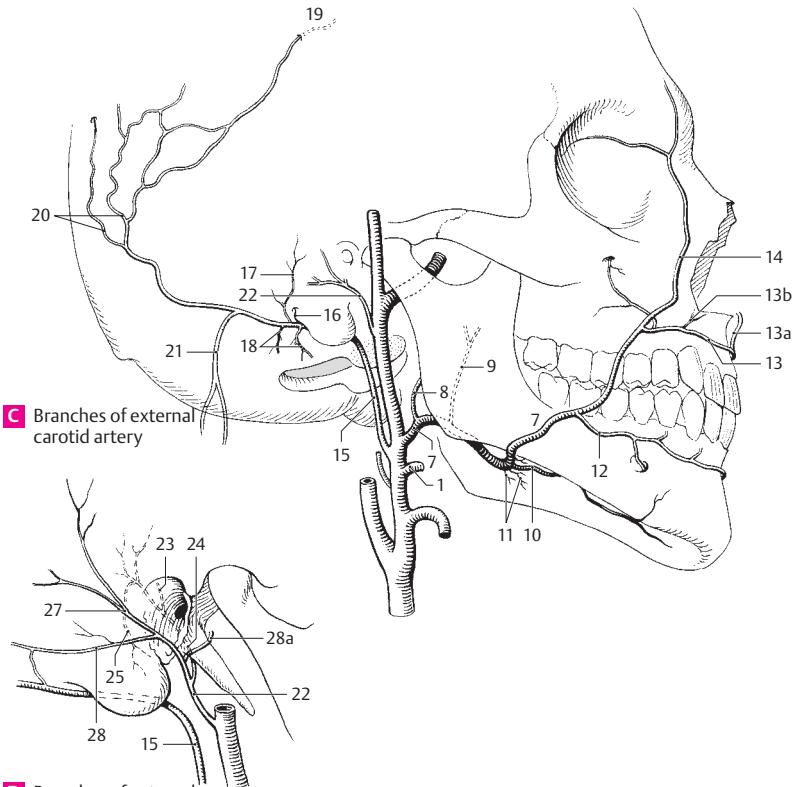
- 1 **Lingual artery.** A. lingualis. Second anterior branch of external carotid artery. It is covered by the hyoglossus muscle and passes laterally into the tongue. A B C
- 2 **Suprahyoid branch of lingual artery.** Ramus suprahyoideus. It anastomoses at the hyoid bone with the infrahyoid branch and the branch from the opposite side. B
- 3 **Sublingual artery.** A. sublingualis. Arising at the anterior margin of the hyoglossus, it passes between the mylohyoid and the sublingual gland and extends up to the gingiva. B
- 4 **Rami dorsales linguae.** Dorsal lingual branches of lingual artery that supply the base of the tongue. B
- 5 **Deep lingual artery.** A. profunda linguae. As the main branch of the lingual artery, it passes between the genioglossus and inferior longitudinal muscles of the tongue to the apex of the tongue and anastomoses with the artery from the opposite side. B
- 6 **Linguofacial trunk.** [Truncus linguofacialis]. Occasionally present common trunk of lingual and facial arteries. A
- 7 **Facial artery.** A. facialis. Third anterior branch of external carotid artery. It runs below the stylohyoid muscle, first upward, then laterad, and crosses the mandible at the anterior margin of the masseter. A B C
- 8 **Ascending palatine artery.** A. palatina ascendens. Arising from the proximal portion of the facial artery, it passes medial to the styloglossus muscle at the lateral wall of the pharynx to supply the palatal arches and adjacent musculature, often also the tonsils from above. It and the ascending pharyngeal artery can replace each other. C
- 9 **Tonsillar branch.** Ramus tonsillaris. Branch frequently arising from the ascending palatine artery and supplying the palatine tonsils. C
- 10 **Submental artery.** A. submental. It lies caudal to the mylohyoid muscle and supplies mainly this muscle and the submandibular gland. It anastomoses with the sublingual artery. C
- 11 **Glandular branches.** Rami glandulares. Direct branches for the submandibular gland. C
- 12 **Inferior labial artery.** A. labialis inferior. Artery for the lower lip situated between the muscle and the mucosa. It anastomoses with the submental and mental arteries as well as the artery of the opposite side. C
- 13 **Superior labial artery.** A. labialis superior. Artery for the upper lip situated between the muscle and mucosa. It anastomoses with the transverse facial and infra-orbital arteries as well as the artery of the opposite side. C
- 13a **Nasal septal branch.** Ramus septi nasi. It connects with the cavernous body of the septum (Kiesselbach's area). C
- 13b **Lateral nasal branch.** Ramus lateralis nasi. It supplies the base of the nasal ala. C
- 14 **Angular artery.** A. angularis. Terminal branch of facial artery. It anastomoses with the ophthalmic artery. C
- 15 **Occipital artery.** A. occipitalis. Second dorsal branch of external carotid artery. It passes medial to the mastoid process at the occiput and anastomoses with the superficial temporal, vertebral, deep cervical and posterior auricular arteries. C D
- 16 **Mastoid branch of occipital artery.** Ramus mastoideus. It passes through the mastoid foramen to the diploë and dura. It also supplies mastoid cells. C
- 17 **Auricular branch of occipital artery.** Ramus auricularis. It passes beneath the sternocleidomastoid muscle and runs obliquely behind the pinna. C
- 18 **Sternocleidomastoid branch.** Ramus sternocleidomastoidei. Small branches of occipital artery that supply the sternocleidomastoid muscle. C
- 19 **Meningeal branch.** [Ramus meningeus]. Inconstant branch of the occipital artery that occasionally passes through the parietal foramen and supplies the dura mater. C
- 20 **Occipital branches.** Rami occipitales. Usually very tortuous branches of occipital artery that penetrate the trapezius and supply the occiput. C
- 21 **Descending branch of occipital artery.** Ramus descendens. It passes beneath the splenius capitis to supply the muscles there. C
- 22 **Posterior auricular artery.** A. auricularis posterior. Third dorsal branch of external carotid artery. It lies under the parotid gland on the styloid process between the mastoid process and the ear. C D
- 23 **Stylomastoid artery.** A. stylomastoidea. Slender companion artery of facial nerve. It courses with it through the stylomastoid foramen to the hiatus of the canal for the greater petrosal nerve, and then into the middle and inner ear. D
- 24 **Posterior tympanic artery.** A. tympanica posterior. It passes with the chorda tympani from the facial canal to the tympanic membrane. D
- 25 **Mastoid branches.** Rami mastoidei. Branches of posterior tympanic artery that supply the mastoid cells. D
- 26 **Stapedial branch.** [Ramus stapedialis]. Slender branch that supplies the stapedial muscle.
- 27 **Auricular branch.** Ramus auricularis. It supplies the posterior side of the pinna with perforating branches as well as the anterior side and the small auricular muscles. D
- 28 **Occipital branch.** Ramus occipitalis. Branch that courses above the mastoid process and anastomoses with the occipital artery. D
- 28a **Parotid branch.** Ramus parotideus. It supplies the parotid gland. D



A Linguofacial trunk



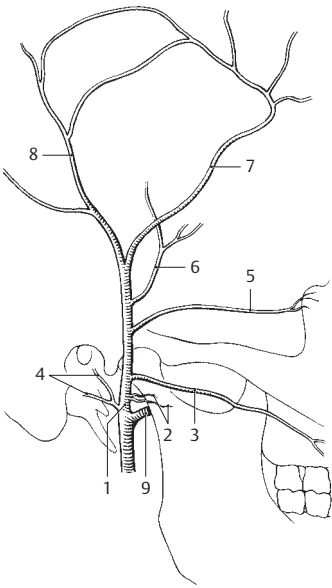
B Branches of external carotid artery



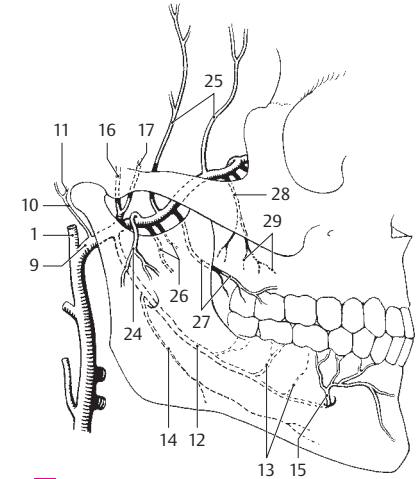
C Branches of external carotid artery

D Branches of external carotid artery

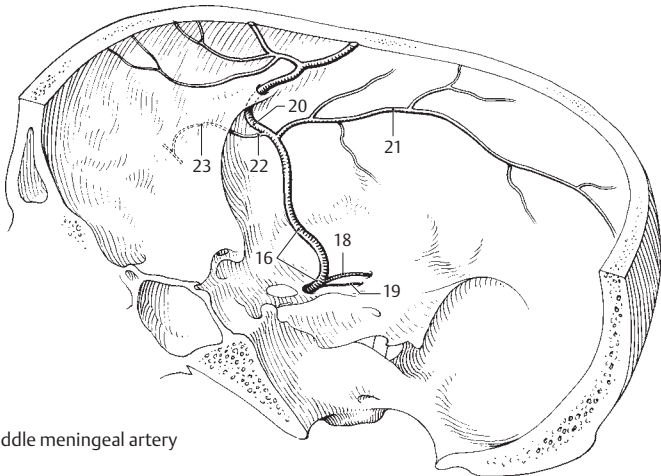
- 1 **Superficial temporal artery.** A. temporalis superficialis. One of two terminal branches of the external carotid artery. It passes upward in front of the pinna accompanied by the auriculotemporal nerve. A B
- 2 **Parotid branch.** Ramus parotideus. It supplies the parotid gland. A
- 3 **Transverse facial artery.** A. transversa faciei (facialis). Branch that is covered by the parotid gland and passes below the zygomatic arch to the cheek. A
- 4 **Anterior auricular branches.** Rami auriculares anteriores. Several small branches to the pinna and the external acoustic meatus. A
- 5 **Zygomatico-orbital artery.** A. zygomatico-orbitalis. It passes above the zygomatic arch to the lateral margin of the orbit. A
- 6 **Middle temporal artery.** A. temporalis media. It passes above the zygomatic arch beneath the temporalis muscle. A
- 7 **Frontal branch.** Ramus frontalis. Anterior branch of superficial temporal artery. It anastomoses with its counterpart from the opposite side as well as with the supra-orbital and supra-trochlear arteries from the internal carotid. A
- 8 **Parietal branch.** Ramus parietalis. Posterior branch of superficial temporal artery. It anastomoses with its counterpart from the opposite side as well as with the posterior auricular and occipital arteries. A
- 9 **Maxillary artery.** A. maxillaris. Larger terminal branch of external carotid artery. It arises beneath the temporomandibular joint, passes lateral or medial to the lateral pterygoid muscle and ramifies in the pterygopalatine fossa. A B
- 10 **Deep auricular artery.** A. auricularis profunda. It passes backward and upward to the temporomandibular joint, external acoustic meatus and tympanic membrane. B
- 11 **Anterior tympanic artery.** A. tympanica anterior. Accompanied by the chorda tympani, it passes through the petrotympanic fissure into the tympanic cavity. B
- 12 **Inferior alveolar artery.** A. alveolaris inferior. It passes between the medial pterygoid muscle and mandibular ramus into the mandibular canal up to the mental foramen. B
- 13 **Dental rami.** Rami dentales. Branches to roots of the teeth. B
- 13a **Peridental branches.** Rami peridentales.
- 14 **Mylohyoid branch.** Ramus mylohyoideus. Branch that exits in front of the mandibular canal and accompanies the mylohyoid nerve in the mylohyoid groove; it runs anteriorly beneath the mylohyoid muscle and anastomoses with the submental artery. B
- 15 **Mental branch.** Ramus mentalis. Terminal branch of inferior alveolar artery. It supplies the chin. B
- 16 **Middle meningeal artery.** A. meningea media. It passes medial to the lateral pterygoid muscle and through the foramen spinosum into the middle cranial fossa where it ramifies. B C
- 17 **Accessory ramus.** Ramus accessorius. Accessory branch from the middle meningeal artery or from the maxillary artery that extends to the adjacent muscles, the auditory tube and through the foramen ovale to the dura up to the trigeminal (semilunar) ganglion. B
- 18 **Petrosal branch.** Ramus petrosus. Small branch that arises directly after the entrance of the middle meningeal artery into the cranial cavity and anastomoses with the stylo mastoid artery via the hiatus of the canal for the greater petrosal nerve. C
- 19 **Superior tympanic artery.** A. tympanica superior. It arises close to the petrosal branch and passes into the tympanic cavity with the lesser petrosal nerve. C
- 20 **Frontal branch.** Ramus frontalis. Anterior, large terminal branch in the cranium. It lies in a bony groove often closed to form a canal. C
- 21 **Parietal branch.** Ramus parietalis. Terminal branch passing to the posterior half of the cranium. C
- 22 **Orbital branch.** Ramus orbitalis. It runs through the superior orbital fissure in the direction of the lacrimal gland. C
- 23 **Anastomotic branch connecting the orbital branch and the lacrimal artery.** Ramus anastomoticus [cum a. lacrimalis]. C
- 23a **Pterygomeningeal artery.** A. pterygomeningea. Artery that supplies the pterygoid muscles, the tensor veli palatini, and the auditory tube; it emerges from the maxillary and middle meningeal arteries and passes through the foramen ovale to the trigeminal ganglion and the dura mater.
- 24 **Masseteric artery.** A. masseterica. Artery that supplies the masseter muscle passing laterally through the mandibular notch. B
- 25 **Anterior deep temporal artery.** A. temporalis profunda anterior. Artery passing upwards into the temporalis muscle. B
- 25a **Posterior temporal artery.** A. temporalis posterior.
- 26 **Pterygoid branches.** Rami pterygoidei. Branches that supply the pterygoid muscles. B
- 27 **Buccal artery.** A. buccalis. Artery that passes downward and forward onto the buccinator muscle to supply the cheek and gingiva. B
- 28 **Posterior superior alveolar artery.** A. alveolaris superior posterior. It passes posteriorly into the maxilla and the maxillary sinus and supplies the upper molar teeth and their gingiva. B
- 29 **Dental branches.** Rami dentales. They supply the maxillary molars. B
- 29a **Peridental branches.** Rami peridentales.



A Superficial temporal artery

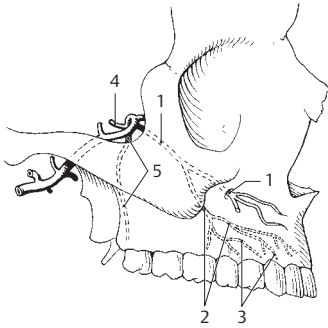


B Maxillary artery

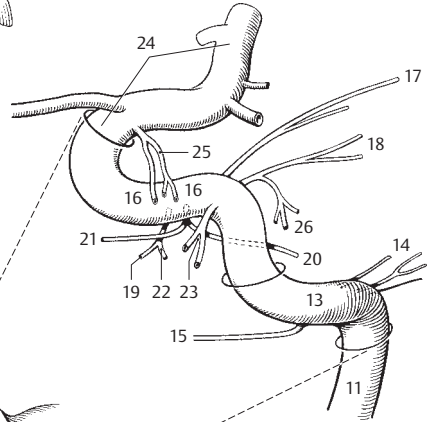


C Middle meningeal artery

- 1 **Infraorbital artery.** A. infraorbitalis. Terminal branch of maxillary artery. It passes to the face via the inferior orbital fissure, groove and canal. A
- 2 **Anterior superior alveolar arteries.** Aa. alveolares superiores anteriores. They leave the infraorbital artery in the infraorbital canal and pass through bone to the anterior teeth. A
- 3 **Dental branches.** Rami dentales. Terminal branches passing to the teeth. A
- 3a **Peridental branches.** Rami peridentales.
- 4 **Artery of pterygoid canal.** A. canalis pterygoidei. It traverses the pterygoid canal and passes posteriorly to the auditory tube and its environment. A B
- 4a **Pharyngeal branch.** Ramus pharyngeus. Branch to the pharyngeal mucosa.
- 5 **Descending palatine artery.** A. palatina descendens. It descends through the greater palatine canal. A B
- 6 **Greater palatine artery.** A. palatina major. It passes through the greater palatine foramen to the anterior palate and the neighboring gingiva. B
- 7 **Lesser palatine arteries.** Aa. palatinae minores. They leave the greater palatine artery and canal and pass through the lesser palatine foramina to the soft palate. B
- 7a **Pharyngeal branch.** Ramus pharyngeus. Branch that supplies the pharyngeal mucosa up to the level of the tonsil and gingiva.
- 8 **Sphenopalatine artery.** A. sphenopalatina. It passes through the sphenopalatine foramen into the nasal cavity. B
- 9 **Lateral posterior nasal branches.** Aa. nasales posteriores laterales. As the terminal branches of the sphenopalatine artery, they supply the nasal cavity laterally and posteriorly. B
- 9a **Posterior septal branches.** Rami septales posteriores. Branches of the sphenopalatine artery that supply the posteroinferior part of the nasal septum. B
- 10 **INTERNAL CAROTID ARTERY (ICA).** Arteria carotis interna. It extends branchless from the bifurcation of the common carotid to the base of the skull where it extends through the carotid canal up to its terminal division into the anterior and middle cerebral arteries. B C
- 11 **Cervical part of internal carotid artery.** Pars cervicalis. Branchless segment that extends up to the site where it enters the carotid canal in the petrous part of the temporal bone. B C
- 12 **Carotid sinus.** Sinus caroticus. It is occasionally displaced from the end of the common carotid artery (p. 194.8) to the beginning of the internal carotid. Site of baroreceptors. B
- 13 **Petrous part of internal carotid artery.** Pars petrosa. Segment coursing through the carotid canal in the petrous part of the temporal bone. C
- 14 **Caroticotympanic arteries.** Aa. caroticotympanicae. Slender arteries extending from the carotid canal to the tympanic cavity. C
- 15 **Pterygoid branch.** Ramus pterygoideus. Branch that accompanies the nerve of the pterygoid canal in the lateral wall of the sphenoid sinus. C
- 16 **Cavernous part of internal carotid.** Pars cavernosa. Segment in the cavernous sinus; it extends up to the vicinity of the optic canal. C
- 17 **Basal tentorial branch.** Ramus basalis tentorii. Branch of ICA that extends across the petrosal ridge to the tentorium. C
- 18 **Marginal tentorial branch.** Ramus marginalis tentorii. Branch of ICA located near the tentorial notch. C
- 19 **Meningeal branch.** Ramus meningeus. Branch of ICA that supplies the dura mater of the middle cranial fossa. C
- 20 **Branch to trigeminal ganglion.** Ramus ganglionis trigeminalis. C
- 21 **Nerve branches.** Rami nervorum.
- 22 **Cavernous sinus branch.** Ramus sinus cavernosi. Twig from the cavernous part of the ICA. C
- 23 **Inferior hypophysial artery.** A. hypophysialis inferior. It supplies the posterior lobe of the hypophysis. C
- 24 **Cerebral part of internal carotid artery.** Pars cerebrialis. As the terminal intradural segment, it extends from the exit of the ophthalmic artery at the last bend of the carotid up to the terminal branches that form the anterior and middle cerebral arteries. C
- 25 **Superior hypophysial artery.** A. hypophysialis superior. It supplies the hypophysial stalk, infundibulum and part of the lower hypophalamus. C
- 26 **Clival branch.** Ramus clivi. Branch that supplies the clivus. C

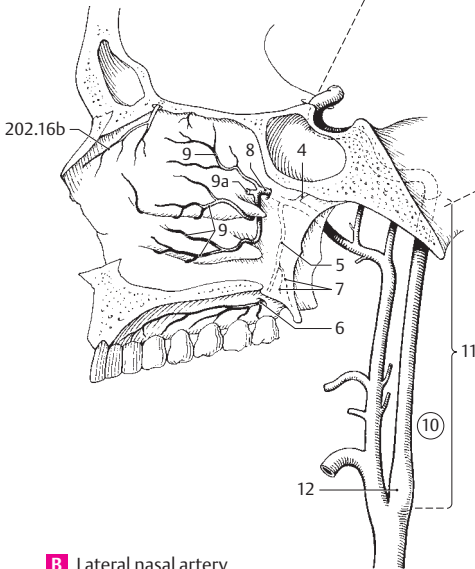


A Infraorbital artery



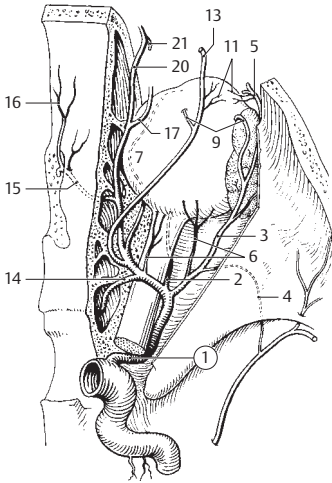
11

C Branches of internal carotid artery

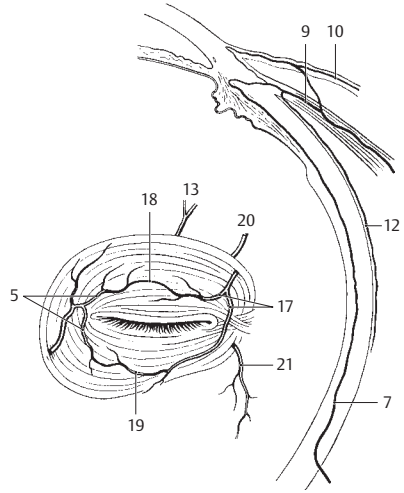


B Lateral nasal artery

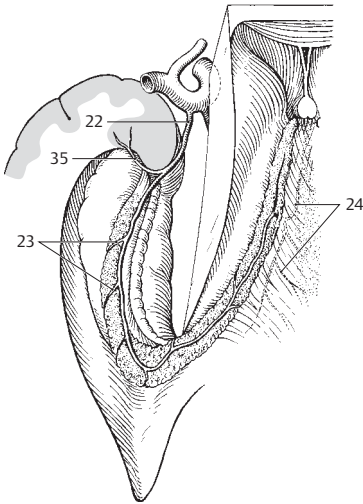
- 1 **Ophthalmic artery.** A. ophthalmica. It passes from the anterior convex arch of the internal carotid artery through the optic canal into the orbit accompanied by the optic nerve. A
- 2 **Central retinal artery.** A. centralis retinae. It passes into the optic nerve from below about 1 mm behind the eyeball. Distribution: internal layers of the retina. A
- 3 **Lacrimal artery.** A. lacrimalis. Exits lateral to the ophthalmic artery and passes to the lacrimal gland along the upper margin of the lateral rectus muscle. A
- 4 **Anastomotic branch [with middle meningeal artery].** Ramus anastomaticus [cum a. meningea media]. Branch that anastomoses with the orbital branch of the middle meningeal artery. It occasionally replaces the ophthalmic artery. A
- 5 **Lateral palpebral arteries.** Aa. palpebrales laterales. They arise from the lacrimal artery and pass lateral to the eyelids. A B
- 5a **Recurrent meningeal branch.** Ramus meningae recurrens. Branch of the lacrimal artery that runs through the superior orbital fissure into the cranial cavity. It anastomoses with the anastomotic branch.
- 6 **Short posterior ciliary arteries.** Aa. ciliares posteriores breves. 10–15 arteries which penetrate the sclera circumferentially around the optic nerve and supply the choroid. A
- 7 **Long posterior ciliary arteries.** Aa. ciliares posteriores longae. Lateral and medial arteries which pass between the sclera and choroid to the ciliary body. A B
- 8 **Muscular arteries.** Branches that supply the eye muscles.
- 9 **Anterior ciliary arteries.** Aa. ciliares anteriores. They arise from the lacrimal artery or muscular branches, penetrate the sclera and supply the choroid and ciliary body. A B
- 10 **Anterior conjunctival arteries.** Aa. conjunctivales anteriores. Branches arising from the anterior ciliary arteries and supplying the conjunctivae. B
- 11 **Posterior conjunctival arteries.** Aa. conjunctivales posteriores. They arise from the lacrimal and supraorbital arteries. A
- 12 **Episcleral arteries.** Aa. episclerales. Twigs of the anterior ciliary arteries situated on the sclera. B
- 13 **Supraorbital artery.** A. supraorbitalis [[a. frontalis lat.]]. It passes below the roof of the orbit and through the supraorbital notch to the forehead. A B
- 13a **Diploic branch.** Ramus diploicus. Branch to bone.
- 14 **Posterior ethmoidal artery.** A. ethmoidalis posterior. It passes below the superior oblique muscle and through the posterior ethmoidal foramen to the posterior ethmoidal air cells and the posterior part of the nasal cavity. A
- 15 **Anterior ethmoidal artery.** A. ethmoidalis anterior. It passes upward through the anterior ethmoidal foramen into the anterior cranial fossa and through the cribriform plate into the nasal cavity and frontal sinus as well as the anterior ethmoidal cells. A
- 16 **Anterior meningeal branch.** Ramus meningae anterior. Branch from the part of the anterior ethmoidal artery lying in the cranial fossa. It supplies the dura. A
- 16a **Anterior septal branches.** Rami septales anteriores. Branches that extend from the anterior ethmoidal artery to the upper portion of the nasal septum.
- 16b **Lateral anterior nasal branches.** Rami nasales anteriores laterales. Branches of the anterior ethmoidal artery that extend to the upper lateral wall of the nasal septum and the anterior upper ethmoidal air cells. See p. 201 B
- 17 **Medial palpebral arteries.** Aa. palpebrales mediales. Paired arteries for each eyelid, upper and lower. They arise from the ophthalmic artery and anastomose with the lateral palpebral artery via the superior and inferior palpebral arches. A B
- 18 **Superior palpebral arch.** Arcus palpebralis superior. Connects the medial and lateral palpebral arteries superiorly on the tarsal plate. B
- 19 **Inferior palpebral arch.** Arcus palpebralis inferior. Connects the medial and lateral palpebral arteries inferiorly on the tarsal plate. B
- 20 **Supratrochlear artery.** A. supratrochlearis [[a. frontalis med.]]. Terminal branch of the ophthalmic artery which passes through the frontal notch to the forehead. Anastomoses with the contralateral, supraorbital and superficial temporal arteries. A B
- 21 **Dorsal nasal artery.** A. dorsalis nasi (a. nasi externa). It penetrates the orbicularis oculi and passes downward to the bridge of the nose. Anastomoses with the facial artery. A B
- 22 **Anterior choroidal artery [[AChA]].** Arteria choroidea anterior. Usually arises from the internal carotid artery. It follows the optic tract and enters the choroid plexus of the inferior horn of the lateral ventricle, where it occasionally passes up to the interventricular foramen. C D
- 23 **Choroidal branches of lateral ventricle.** Rami choroidei ventriculi lateralis. Branches that supply the choroid plexus of the lateral ventricle. C D
- 24 **Choroidal branches to third ventricle.** Rami choroidei ventriculi tertii. Branches that supply the choroid plexus of the third ventricle. C
- 25 **Branches to anterior perforated substance.** Rami substantiae perforatae anterioris. AChA branches that supply internal capsule. D
- 26 **Branches of optic tract.** Rami tractus optici. Branches to the AchA that supply the optic tract. D
- 27 **Branches to lateral geniculate body.** Rami corporis geniculati lateralis. AChA branches that supply the lateral geniculate body. D
- 28 **Branches to internal capsule.** Rami capsulae interna. AChA branches that supply the posterior part of the internal capsule.
- 29 **Branches to globus pallidus.** Rami globi pallidi. AChA branches that supply the globus pallidus.
- 30 **Branches to tail of caudate nucleus.** Rami caudae nuclei caudati. AChA branches that supply the tail of the caudate nucleus.
- 31 **Branches to tuber cinereum.** Rami tuberculi cinerei. AChA branches that supply the tuber cinereum. D



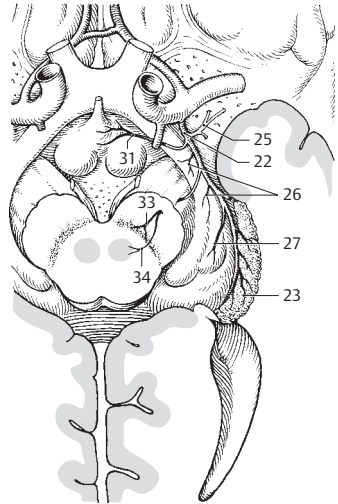
A Ophthalmic artery



B Facial branches of ophthalmic artery



C Anterior choroidal artery from above



D Anterior choroidal artery from below

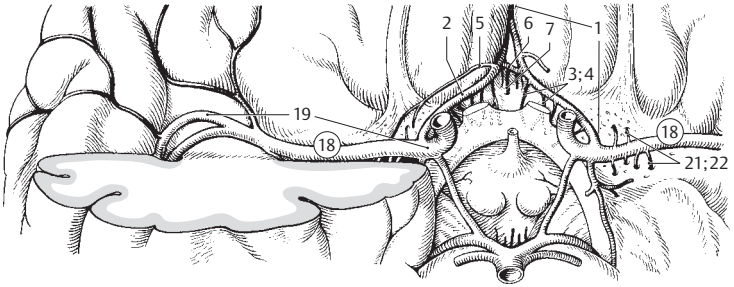
32 **Branches to hypothalamic nuclei.** Rami nucleorum hypothalamicorum. AChA branches that supply the hypothalamic nuclei.

33 **Branches to substantia nigra.** Rami substantiae nigrae. AChA branches that pass through the crus cerebri and supply the substantia nigra. D

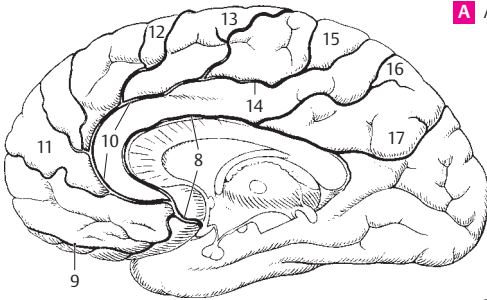
34 **Branches to red nucleus.** Rami nuclei rubri. AChA branches that pass through the crus cerebri and supply the red nucleus. D

35 **Branches to amygdaloid body.** Rami corporis amygdaloidei. Branches of the AChA that supply the medial amygdaloid nucleus. C

- 1 **Anterior cerebral artery.** A. cerebri anterior. One of the two terminal arteries of the internal carotid artery. It runs posteriorly above the corpus callosum and supplies the greater part of the medial surface of the cerebrum. A
- 2 **Precommunicating part.** Pars precommunicalis. Portion of the anterior cerebral artery proximal to the anterior communicating branch. A
- 3 **Anteromedial central arteries (anteromedial thalamostriate arteries).** Aa. centrales anteromediales (aa. thalamostriatae anteromediales). Branches arising from the anterior cerebral arteries and passing into the thalamus and corpus striatum from below. A
- 4 **Short central artery.** A. centralis brevis. Short branch of anterior cerebral artery passing into the cerebrum. A
- 5 **Long central artery (recurrent artery).** A. centralis longa (a. recurrens) [[Heubner]]. Retrograde branch that runs parallel to the anterior cerebral artery. It penetrates the anterior perforated substance and supplies the middle and lateral parts of the lentiform nucleus, the head of the caudate nucleus and the anterior limb of the internal capsule. A
- 6 **Anterior communicating artery.** A. communicans anterior. Unpaired connection between the right and left anterior cerebral arteries. A
- 7 **Anteromedial central branches.** Rami centrales anteromediales. Anteromedial central branches that penetrate uniformly into the cerebral substance. A
- 8 **Postcommunicating part of anterior cerebral artery.** Pars postcommunicalis (r. pericallosa). The part distal to the anterior communicating artery. B
- 9 **Medial frontobasal artery (medial orbitofrontalis branch).** A. frontobasalis medialis (r. orbitofrontalis medialis). Branch to the lower surface of the frontal lobe. B
- 10 **Callosomarginal artery.** A. callosomarginalis. Segment of the anterior cerebral artery located in the sulcus of the corpus callosum. B
- 11 **Anteromedial frontal branch.** Ramus frontalis anteromedialis. Branch to the lower half of the medial side of the frontal lobe. B
- 12 **Mediomedial frontal branch.** Ramus frontalis mediomedialis. Branch to the middle portion of the medial side of the frontal lobe. B
- 13 **Posteromedial frontal branch.** Ramus frontalis posteromedialis. Branch to the posterior portion of the medial surface of the frontal lobe. B
- 14 **Cingular branch.** Ramus cingularis. Branch that supplies the cingulate sulcus. B
- 15 **Paracentral artery.** A. paracentralis. Branch of the anterior cerebral artery that supplies the area behind the central sulcus. B
- 16 **Precuneal artery.** A. precunealis. It supplies the region in front of the cuneus. B
- 17 **Parieto-occipital artery.** A. parieto-occipitalis. Branch of the anterior cerebral artery that supplies the parieto-occipital sulcus. B
- 18 **Middle cerebral artery.** A. cerebri media. Second terminal branch of internal carotid artery. It lodges in the lateral sulcus between the frontal and temporal lobes and supplies the greater part of the lateral cerebral surface. A
- 19 **Sphenoidal part.** Pars sphenoidalis. First part of the middle cerebral artery. It takes a horizontal course somewhat parallel to the lesser wing of the sphenoid bone. A
- 20 **Anterolateral central arteries.** Aa. centrales anterolaterales (aa. thalamostriatae anterolaterales). Branches that penetrate the anterior perforated substance.
- 21 **Medial branches.** Rami mediales. They pass through the lentiform nucleus to the caudate nucleus and internal capsule. A
- 22 **Lateral branches.** Rami laterales. They course laterally around the lentiform nucleus to the internal capsule and caudate nucleus. A
- 23 **Insular part.** Pars insularis. Collective term for branches of the middle cerebral artery that supply the insula. D
- 24 **Insular arteries.** Aa. insulares. Branches that supply the insula. D
- 25 **Lateral frontobasal artery.** A. frontobasalis lateralis (ramus orbitofrontalis lateralis). Branch that supplies the lateroinferior frontal lobe. C D
- 26 **Anterior temporal artery.** A. temporalis anterior. Branch that supplies the frontal end of the two upper temporal gyri. C D
- 27 **Middle temporal artery.** A. temporalis media. Branch supplying the middle portion of the temporal lobe. C D
- 28 **Posterior temporal artery.** A. temporalis posterior. Branch supplying the posterior portion of the temporal lobe. C D
- 29 **Terminal part.** Pars terminalis (pars corticalis). Terminal ramifications of the middle cerebral artery.
- 30 **Artery of central sulcus.** A. sulci centralis. C D
- 31 **Artery of precentral sulcus.** A. sulci precentralis. C D
- 32 **Artery of postcentral sulcus.** A. sulci postcentralis. C D
- 33 **Anterior and posterior parietal arteries.** Aa. parietales anterior et posterior. Branches that supply the parietal lobe. C D
- 34 **Artery of angular gyrus.** A. gyri angularis. C D

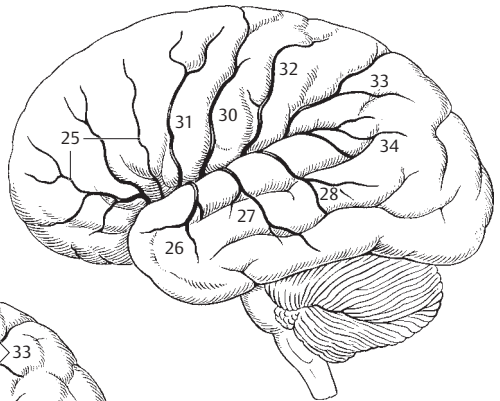


A Anterior and middle cerebral arteries

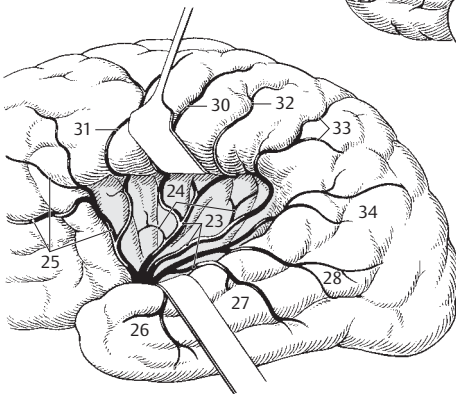


B Anterior cerebral artery

11

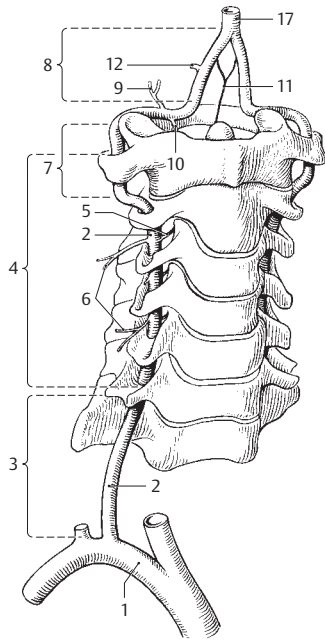


C Middle cerebral artery

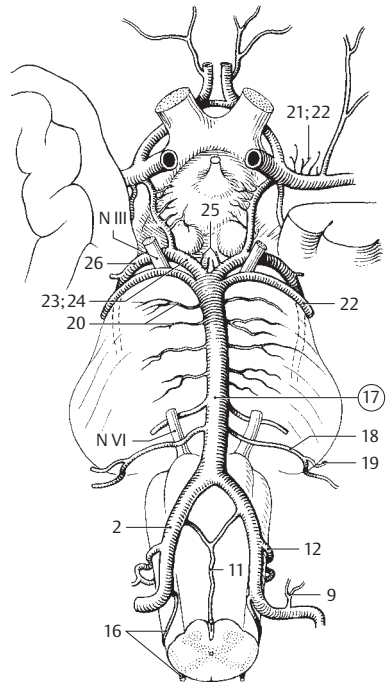


D Insular arteries

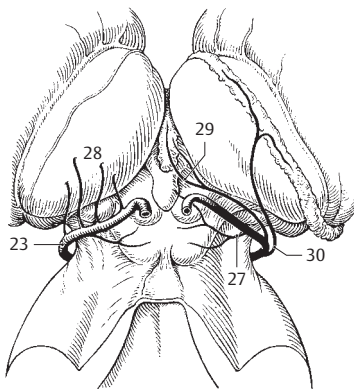
- 1 **SUBCLAVIAN ARTERY.** Arteria subclavia. It lodges between the scalenus anterior and medius in the groove for the subclavian artery on the 1st rib. At the lateral margin of the 1st rib it continues as the axillary artery. A
- 2 **Vertebral artery.** A. vertebralis. It originates behind the scalenus anterior, passes through the foramina transversaria cranially from C6–C1, and then, after proceeding over the arch of the atlas behind its lateral mass, runs anteriorly through the posterior atlanto-occipital membrane and the foramen magnum into the cranial cavity. A B D
- 3 **Prevertebral part of vertebral artery.** Pars prevertebralis. This short segment lies in front of the entrance into the foramen transversarium of C6. A
- 4 **Vertebral part of vertebral artery.** Pars transversaria (cervicalis). It ascends through the foramina transversaria of C6 to C1. A
- 5 **Spinal branches.** Rami spinales (radiculares). Branches passing with the spinal nerves to supply the spinal cord, the meningeal coverings of the spinal cord and the vertebral bodies. A
- 6 **Muscular branches.** Rami musculares. They supply the surrounding muscles. A
- 7 **Atlantal (suboccipital) part.** Pars atlantica. Portion of the vertebral artery that winds around the atlas and occupies the suboccipital triangle. A
- 8 **Intracranial part of vertebral artery.** Pars intracranialis. It lies within the cranium. A
- 9 **Anterior meningeal branch.** Ramus meningeus [anterior]. Branch at the anterior circumference of the foramen magnum. It supplies bone and dura. A
- 10 **Posterior meningeal branch.** Ramus meningeus [posterior]. Branch at the posterior circumference of the foramen magnum. It supplies bone and dura. A
- 11 **Anterior spinal artery.** A. spinalis anterior. The right and left arteries join to form an unpaired vessel in the anterior median fissure of the spinal cord. A B
- 12 **Posterior inferior cerebellar artery (PICA).** A. inferior posterior cerebelli. It mainly supplies the lower posterior portion of the cerebellum. A B D
- 13 **Choroid branch of PICA.** Ramus choroideus ventriculi quarti. It supplies the choroid plexus of the fourth ventricle.
- 14 **Tonsillar branch of PICA.** Ramus tonsillae cerebelli. Branch that supplies the tonsil of the cerebellum.
- 15 **Medial and lateral medullary branches of PICA.** Rami medullares medialis et lateralis. Branches that supply the medulla oblongata and the inferior cerebellar peduncle.
- 16 **Posterior spinal artery.** A. spinalis posterior. Slender longitudinal vessel, occasionally paired, behind the spinal cord. It arises intracranially from the posterior inferior cerebellar artery or the vertebral artery. B D
- 17 **Basilar artery.** A. basilaris. Unpaired, thick trunk that extends from the right and left vertebral arteries to its termination as the posterior cerebral arteries. A B D
- 18 **Anterior inferior cerebellar artery.** A. inferior anterior cerebelli. It supplies the anterior part of the inferior surface of the cerebellum. B D
- 19 **Labyrinthine artery.** A. labyrinthi [ramus meatus acustici interni]. Branch of the anterior inferior cerebellar artery (or basilar artery) that accompanies the vestibulocochlear nerve into the inner ear. B D
- 20 **Pontine arteries.** Aa. pontis. Branches that supply the pons. B D
- 21 **Mesencephalic arteries.** Aa. mesencephalicae.
- 22 **Superior cerebellar artery.** A. superior cerebelli. It passes around the mesencephalon and through the cisterna ambiens to the surface of the cerebellum below the tentorium. B D
- 23 **Posterior cerebral artery.** A. cerebri posterior. Terminal branch of basilar artery. It supplies the occipital lobe and 2/3 of the temporal lobe of the cerebrum. B C D
- 24 **Precommunical part of posterior cerebral artery.** Pars precommunicalis. Short trunk which extends up to the entrance of the posterior communicating artery. B
- 25 **Posteromedial central arteries.** Aa. centrales posteromediales. Branches in the posterior perforated substance that supply the thalamus, lateral wall of third ventricle and globus pallidus. B
- 26 **Postcommunical part of posterior cerebral artery.** Pars postcommunicalis. It is that portion following the posterior communicating artery. It curves around the mesencephalon and passes through the cisterna ambiens and tentorial notch to the inferior surface of the cerebrum. B
- 27 **Posterolateral central arteries.** Aa. centrales posterolaterales. Individual branches that supply the posterior portion of the thalamus, the quadrigeminal plate, pineal body and the medial geniculate body. C
- 28 **Thalamic branches.** Rami thalamici. Branches to posterior portion of thalamus. C
- 29 **Posteromedial choroid branches.** Rami choroidei posteriores mediales. Branches in the roof of the third ventricle. C
- 30 **Posterolateral choroid branches.** Rami choroidei posteriores laterales. Branches that supply the choroid plexus of the lateral ventricle. C
- 31 **Peduncular branches.** Rami pedunculares. Branches that supply the cerebral peduncles. D



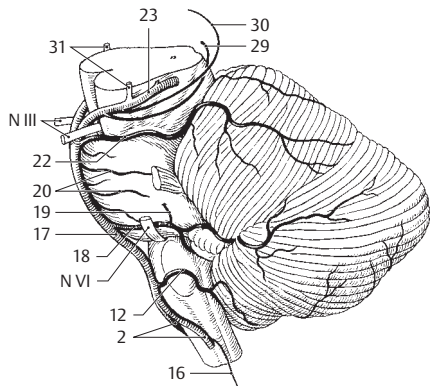
A Vertebral artery



B Arteries of base of the brain

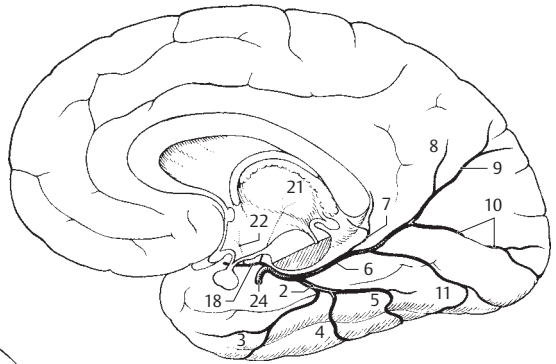


C Posterior cerebral artery

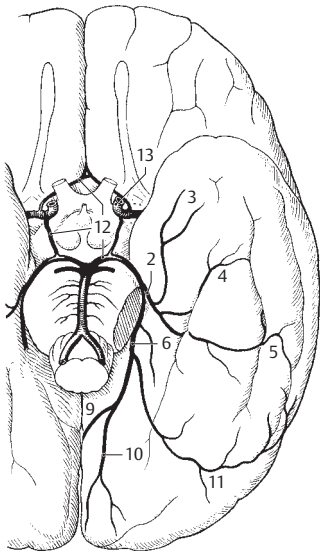


D Basilar artery

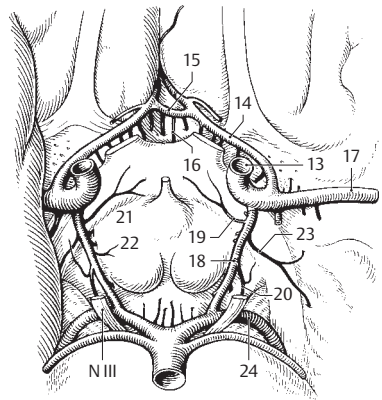
- 1 **Terminal portion of posterior cerebral artery.** Pars terminalis (corticalis). It supplies almost exclusively the posterior cerebral cortex mainly at the base of the brain.
- 2 **Lateral occipital artery.** A. occipitalis lateralis. Trunk for the three temporal lobe arteries. A B
- 3 **Anterior temporal branches.** Rami temporales anteriores. A B
- 4 **Middle temporal branches.** Rami temporales (intermedii mediales). A B
- 5 **Posterior temporal branches.** Rami temporales posteriores. A B
- 6 **Medial occipital artery.** A. occipitalis medialis. Twig for the sagittal surface of the posterior half of the cerebrum. A B
- 7 **Dorsal branch to corpus callosum.** Ramus corporis callosi dorsalis. Small, short branch to the splenium of the corpus callosum. A
- 8 **Parietal branch.** Ramus parietalis. Anterior branch to posterior portion of the parietal lobe. A
- 9 **Parieto-occipital branch.** Ramus parieto-occipitalis. It supplies the parieto-occipital sulcus. A B
- 11 **Calcarine branch.** Ramus calcarinus. It supplies the calcarine sulcus. A B
- 11 **Occipitotemporal branch.** Ramus occipitotemporalis. Lower branch extending into the temporal lobe. A B
- 12 **Cerebral arterial circle [[Circle of Willis]].** Circulus arteriosus cerebri [[Willisii]]. Anastomosing arterial circle between the main tributaries of the cerebrum, i.e., between the internal carotid and the posterior cerebral arteries. B C
- 13 **Internal carotid artery.** A. carotis interna. Main anterior tributary in the cranial cavity. B C
- 14 **Anterior cerebral artery.** A. cerebri anterior. Anterior terminal branch of internal carotid artery. It supplies chiefly the greater portion of the medial and orbital surfaces of the cerebrum. C
- 15 **Anterior communicating artery.** A. communicans anterior. Anastomosis between right and left anterior cerebral arteries. C
- 16 **Anteromedial central arteries.** Aa. centrales anteromediales. Short branches penetrating equally into the base of the brain. C
- 17 **Middle cerebral artery.** A. cerebri media. Lateral terminal branch of internal carotid artery. It frequently gives off the posterior communicating artery. C
- 18 **Posterior communicating artery.** A. communicans posterior. Paired anastomoses between the internal carotid or middle cerebral artery and the posterior cerebral artery. A C
- 19 **Chiasmatic branch.** Ramus chiasmaticus. Branch to the optic chiasm. C
- 20 **Oculomotor nerve branch.** Ramus nervi oculomotorii. C
- 21 **Thalamic branch.** Ramus thalamicus. Long branch which passes to the thalamus from below. A C
- 22 **Hypothalamic branch.** Ramus hypothalamicus. Branch to the hypothalamus. A C
- 23 **Branch to tail of caudate nucleus.** Ramus caudae nuclei caudati. It is located medial to the choroid fissure. C
- 24 **Posterior cerebral artery.** A. cerebri posterior. Paired terminal branch of basilar artery. Since the latter is formed by the union of the right and left vertebral arteries, this produces a strong anastomosis of both vertebral arteries. A C



A Posterior cerebral artery, medial view



B Posterior cerebral artery

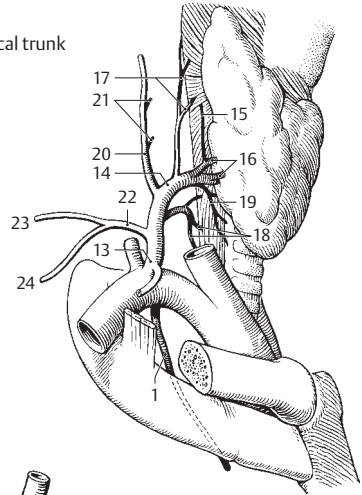


C Cerebral arterial circle

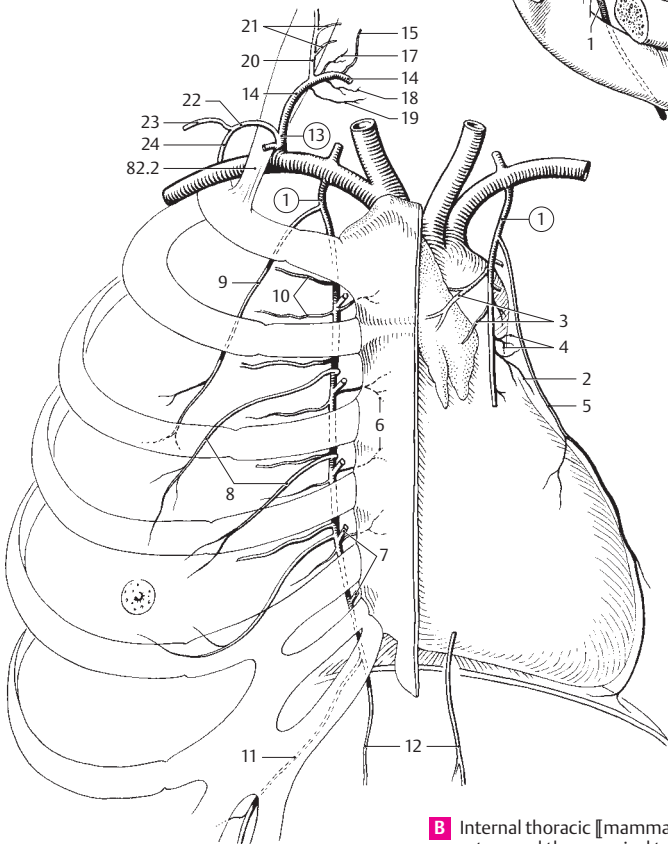
11

- 1 **Internal thoracic [[mammary]] artery.** A. thoracica interna [[a. mammaria interna]]. It arises from the subclavian artery and descends along the anterior, inner surface of the thorax as far as the diaphragm. A B
- 2 **Mediastinal branches.** Rami mediastinales. Branches that supply the mediastinum. B
- 3 **Thymic branches.** Rami thymici. Branches that supply the thymus. B
- 4 **Bronchial branches.** [Rami bronchiales]. Branches to the bronchi. B
- 4a **Tracheal branches.** [Rami tracheales]. Branches to the trachea.
- 5 **Pericardiophrenic artery.** A. pericardiophrenica. Accompanies the phrenic nerve and supplies the pericardium and the diaphragm. B
- 6 **Sternal branches.** Rami sternales. Branches that supply the sternum. B
- 7 **Perforating branches.** Rami perforantes. Vessels that extend through intercostal spaces 1–6 to the surface of the thorax. B
- 8 **Medial mammary branches.** Rami mammarii mediales. Larger perforating branches that supply the mammary gland. B
- 9 **Lateral costal branch.** [Ramus costalis lateralis]. Normal variant. Arises from the internal thoracic artery and runs lateral and parallel to it. B
- 10 **Anterior intercostal branches.** Rami intercostales anteriores. Anterior tributaries in the intercostal spaces. B
- 11 **Musculophrenic artery.** A. musculophrenica. Passing behind the costal arch, it gives off additional anterior intercostal branches from the 7th intercostal space onward. B
- 12 **Superior epigastric artery.** A. epigastrica superior. Continuation of the internal thoracic artery after entering the abdominal cavity between the sternal and costal parts of the diaphragm [[Larrey's space = sternocostal triangle]]. B
- 13 **Thyrocervical trunk.** Truncus thyrocervicalis. Variably common stem of the inferior thyroid, transverse cervical and suprascapular arteries. A B
- 14 **Inferior thyroid artery.** A. thyroidea inferior. It passes along the anterior margin of the scalenus anterior as far as the level of C6 and then behind the common carotid artery to the thyroid gland. A B
- 15 **Inferior laryngeal artery.** A. laryngealis inferior. It passes upward behind the trachea, penetrates the inferior pharyngeal constrictor and supplies part of the larynx. A B
- 16 **Glandular branches.** Rami glandulares. They supply the inferior and posterior surfaces of the thyroid gland and the parathyroids via inferior and ascending branches. A
- 17 **Pharyngeal branches.** Rami pharyngeales. They supply the wall of the pharynx. A B
- 18 **Esophageal branches.** Rami oesophageales. A B
- 19 **Tracheal branches.** Rami tracheales. A B
- 20 **Ascending cervical artery.** A. cervicalis ascendens. It lies medial to the phrenic nerve and the scalenus anterior and can reach as far as the base of the skull. A B
- 21 **Spinal branches.** Rami spinales. They pass through the intervertebral foramina to the spinal cord. A B
- 22 **Transverse cervical (colli) artery.** A. transversa cervicis (colli). The vessel may vary greatly. The second most frequent variant (25%) is represented here. Originating usually (75%) from the subclavian artery, it frequently passes through the brachial plexus, supplies the upper part of the trapezius with its branches and ramifies alongside the dorsal scapular nerve. A B
- 23 **Superficial branch.** Ramus superficialis. It arises either as a superficial ramus from the transverse cervical artery or as an independent superficial cervical artery from the thyrocervical trunk and passes beside the accessory nerve to the descending part of the trapezius and the levator scapulae and splenius muscles. A B
- 23a **Ascending branch.** Ramus ascendens.
- 23b **Descending branch.** Ramus descendens.
- 24 **Deep branch (dorsal scapular artery).** Ramus profundus (a. dorsalis scapulae). This vessel arises either as a deep branch of the transverse cervical artery or directly from the subclavian artery (67%) and accompanies the dorsal scapular nerve. It supplies the medial border of the scapula and adjacent muscles. A B
- 24a **Dorsal scapular artery.** [A. dorsalis scapulae]. Old designation for the deep branch.

A Thyrocervical trunk

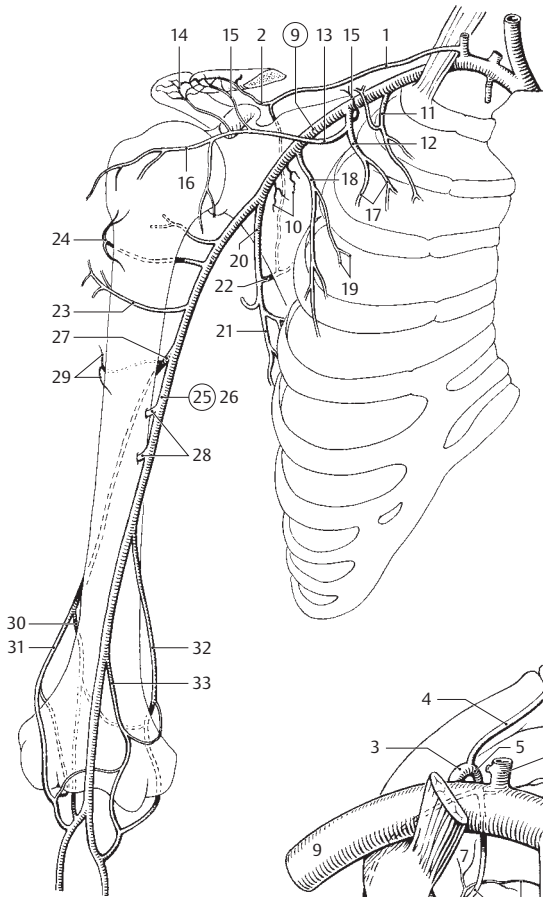


11

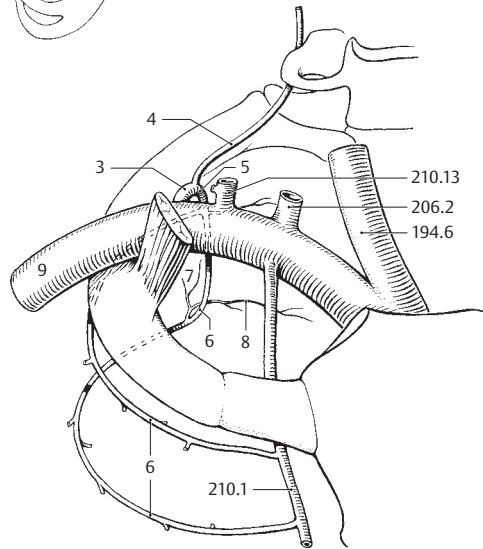


B Internal thoracic (mammary) artery and thyrocervical trunk

- 1 **Suprascapular artery.** A. suprascapularis. Generally arises from the thyrocervical trunk, crosses over the scalenus anterior, runs above the superior transverse scapular ligament into the supraspinous and infraspinous fossae and anastomoses with the circumflex scapular artery. A
- 2 **Acromial branch.** Ramus acromialis. It penetrates the attachment of the trapezius and passes to the acromion. A
- 3 **Costocervical trunk.** Truncus costocervicalis. Origin: posterior wall of subclavian artery behind the scalenus anterior. B
- 4 **Deep cervical artery.** A. cervicalis profunda. It courses posteriorly between the transverse processes of C7 and T1, then upwards on the semispinalis. It supplies the nuchal musculature. B
- 5 **Highest intercostal artery.** A. intercostalis suprema. Common trunk for the first two intercostal arteries. B
- 6 **First and second posterior intercostal arteries.** Aa. intercostalis posterior prima et secunda. They pass in the first two intercostal spaces, respectively. B
- 7 **Dorsal branches.** Rami dorsales. Branches for the muscles and skin of the back. B
- 8 **Spinal branches.** Rami spinales. Branches to the spinal cord via intervertebral foramina T1–2. B
- ARTERIES OF THE UPPER LIMB.** Arteriae membri superioris.
- 9 **Axillary Artery.** Arteria axillaris. Continuation of the subclavian artery as far as the lower margin of the pectoralis major. A B
- 10 **Subscapular branches.** Rami subscapulares. Individual branches to the subscapularis muscle. A
- 11 **Superior thoracic artery.** A. thoracica superior. Variable branch to the subclavius, intercostals 1–2 and serratus anterior muscles. A
- 12 **Thoracoacromial artery.** A. thoracoacromialis. It arises at the upper margin of the pectoralis minor and ramifies in all directions. A
- 13 **Acromial branch.** Ramus acromialis. Branch passing superolaterally through the deltoid muscle to the acromion. A
- 14 **Acromial network.** Rete acromiale. Arterial network on the acromion. A
- 15 **Clavicular branch.** Ramus clavicularis. Small branch to the clavicle and the subclavius muscle. A
- 16 **Deltoid branch.** Ramus deltoideus. Branch passing posterolaterally for the deltoid and pectoralis major muscles. A
- 17 **Pectoral branches.** Rami pectorales. Branches passing inferiorly for the serratus anterior and pectoral muscles. A
- 18 **Lateral thoracic artery.** A. thoracica lateralis. It passes downward at the lateral margin of the pectoralis minor to supply the pectoral and serratus anterior muscles. A
- 19 **Lateral mammary branches.** Rami mammarii laterales. A
- 20 **Subscapular artery.** A. subscapularis. Arises at the lateral margin of the subscapularis muscle and supplies it, the latissimus dorsi and teres major muscles. A
- 21 **Thoracodorsal artery.** A. thoracodorsalis. Branch to the latissimus dorsi and teres major. A
- 22 **Circumflex scapular artery.** A. circumflexa scapulae. It passes through the triangular space to the infraspinous fossa and anastomoses with the suprascapular artery. A
- 23 **Anterior circumflex humeral artery.** A. circumflexa anterior humeri. It arises below the latissimus dorsi at the same level or deeper than the posterior circumflex humeral artery and passes in front of the surgical neck of the humerus to the coracobrachialis and biceps. It anastomoses with the posterior circumflex humeral artery. A
- 24 **Posterior circumflex humeral artery.** A. circumflexa posterior humeri. It passes with the axillary nerve through the quadrangular space to the shoulder joint and the deltoid muscle. It anastomoses with the anterior circumflex humeral, suprascapularis and thoracoacromial arteries. A
- 25 **Brachial artery.** A. brachialis. It forms a continuation of the axillary artery from the lower margin of the pectoralis major in the medial bicipital groove up to its division into the radial and ulnar arteries. A
- 26 **Superficial brachial artery.** [A. brachialis superficialis]. Anatomic variant in which the brachial artery lies on the median nerve instead of below it. A
- 27 **Profunda brachii artery.** A. profunda brachii. Companion artery of the radial nerve in the groove for the radial nerve. A
- 28 **Nutrient arteries of humerus.** Aa. nutriciae (nutrientes) humeri. Branches to the bone marrow of the humerus. A
- 29 **Deltoid branch.** Ramus deltoideus. Branch coursing laterally behind the humerus, then superiorly and externally to the deltoid muscle. A
- 30 **Middle collateral artery.** A. collateralis media. It arises behind the humerus and descends to the articular network of the elbow. A
- 31 **Radial collateral artery.** A. collateralis radialis. It passes with the radial nerve to the articular network of the elbow and gives off an anterior branch to the radial recurrent artery. A
- 32 **Superior ulnar collateral artery.** A. collateralis ulnaris superior. Often arising near the profunda brachii artery, it passes with the ulnar nerve to the articular network of the elbow. A
- 33 **Inferior ulnar collateral artery.** A. collateralis ulnaris inferior. Originating above the medial epicondyle of the humerus, it passes on the brachialis muscle and through the intermuscular septum to the articular network of the elbow. A

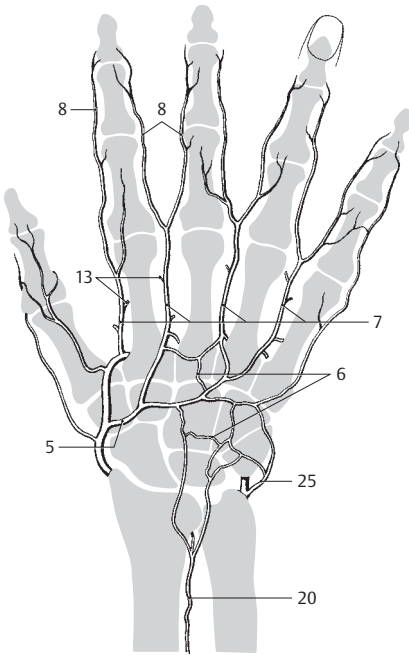


A Subclavian and brachial arteries

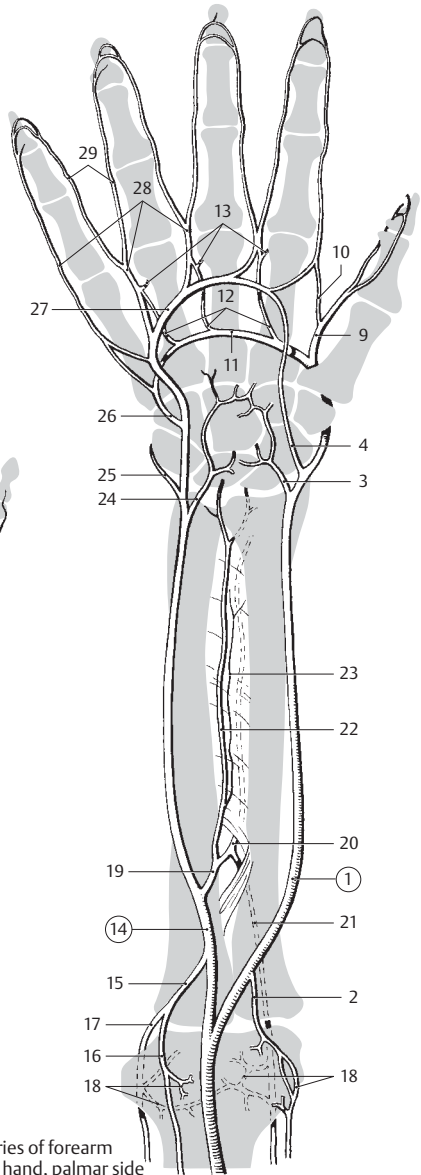


B Arteria subclavia

- 1 **Radial artery.** A. radialis. It begins at the division of the brachial artery and courses on the pronator teres, then lateral to the flexor carpi radialis (where its pulsations are readily palpable) up to the hand. B
- 2 **Radial recurrent artery.** A. recurrens radialis. Retrograde artery ascending medial to the radial nerve to anastomose with the radial collateral artery. B
- 3 **Palmar carpal branch.** Ramus carpalis palmaris. Small branch at the distal margin of the pronator quadratus. It joins the carpal network. B
- 4 **Superficial palmar branch.** Ramus palmaris superficialis. Small arterial branch coursing through the thenar eminence to the superficial palmar arch. B
- 5 **Dorsal carpal branch.** Ramus carpalis dorsalis. Branch passing transversely across the dorsum of the wrist below the long extensor tendons. A
- 6 **Dorsal carpal network.** Rete carpalae dorsale. Arterial network on the dorsum of the wrist. A
- 7 **Dorsal metacarpal arteries.** Aa. metacarpales dorsales. Four arteries arising from the dorsal carpal branch or the dorsal carpal network and passing dorsally in the direction of the interdigital spaces. A
- 8 **Dorsal digital arteries.** Aa. digitales dorsales. Two short arteries arising from each of the dorsal metacarpal arteries and supplying the dorsum of the individual fingers. A
- 9 **Princeps pollicis artery.** A. princeps pollicis. It originates from the radial artery after its entrance into the 1st dorsal interosseus muscle and divides at the flexor side of the thumb. B
- 10 **Radialis indicis artery.** A. radialis indicis. Frequent branch of the princeps pollicis artery the radial side of the index finger. B
- 11 **Deep palmar arch.** Arcus palmaris profundus. Continuation of the radial artery beneath the long flexor tendons. In anastomoses with the ulnar artery. B
- 12 **Palmar metacarpal arteries.** Aa. metacarpales palmares. Small branches of the deep palmar arch passing toward the interdigital spaces. B
- 13 **Perforating branches.** Rami perforantes. Anastomose with the dorsal metacarpal arteries at the dorsum of the hand. A B
- 14 **Ulnar artery.** A. ulnaris. Second terminal branch of brachial artery. It runs beneath the pronator teres, then accompanies the flexor carpi ulnaris to terminate as the superficial palmar arch. B
- 15 **Ulnar recurrent artery.** A. recurrens ulnaris. Retrograde branch of the ulnar (or brachial) artery with the two branches listed below. B
- 16 **Anterior branch.** Ramus anterior. It ascends medial to the brachialis muscle to anastomose with the inferior ulnar collateral artery. B
- 17 **Posterior branch.** Ramus posterior. Together with the ulnar nerve it ascends behind the medial epicondyle to anastomose with the articular network of the elbow and the superior ulnar collateral artery. B
- 18 **Articular network of elbow.** Rete articulare cubiti. Arterial plexus around the elbow joint, especially behind it. B
- 19 **Common interosseous artery.** A. interossea communis. Short segment that extends from its origin from the ulnar artery to its division into the anterior and posterior interosseous arteries. B
- 20 **Posterior interosseous artery.** A. interossea posterior. It passes between the interosseous membrane and the oblique cord to the dorsal surface and supplies the extensor muscles of the forearm. A B
- 21 **Recurrent interosseous artery.** A. interossea recurrens. It passes deep to the anconeus muscle to anastomose with the middle collateral artery. B
- 22 **Anterior interosseous artery.** A. interossea anterior. It runs on the interosseous membrane and then beneath the pronator quadratus to anastomose with the dorsal carpal network. B
- 23 **Accompanying artery of median nerve.** A. combitans nervi mediani. Long, slender vessel (median artery) which accompanies the median nerve. B
- 24 **Palmar carpal branch.** Ramus carpalis palmaris. Branch distal to the pronator quadratus that supplies the wrist. B
- 25 **Dorsal carpal branch.** Ramus carpalis dorsalis. Branch passing laterally around the wrist to the dorsal carpal network. A B
- 26 **Deep palmar branch.** Ramus palmaris profundus. Weaker ulnar contributor to the deep palmar arch arising at the level of the pisiform bone. B
- 27 **Superficial palmar arch.** Arcus palmaris superficialis. It lies between the palmar aponeurosis and the long flexor tendons with the main influx from the ulnar artery. It anastomoses with the radial artery. B
- 28 **Common palmar digital arteries.** Aa. digitales palmares communes. Three to four arteries running along the sides of the fingers, which they principally supply. B
- 29 **Proper palmar digital arteries.** Aa. digitales palmares propriae. Thick arteries on the ulnar and radial sides of each finger, palmar aspect. B

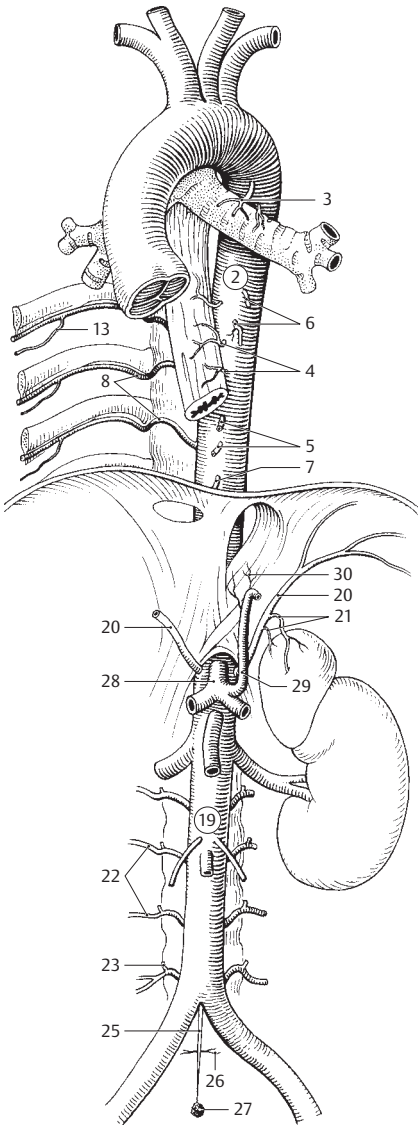


A Dorsal arteries of hand

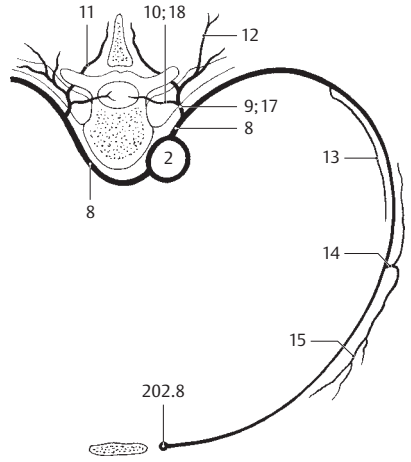


B Arteries of forearm and hand, palmar side

- 1 **DESCENDING AORTA.** Pars descendens aortae. Descending portion of the aorta beginning at the isthmus of the arch of the aorta and terminating at its bifurcation at the level of the body of L4.
- 2 **THORACIC AORTA.** Pars thoracica aortae. Part of the descending aorta extending down to its entrance into the diaphragm. A B
- 3 **Bronchial branches.** Rami bronchiales. Their origin is very variable but often at the level of the bifurcation of the trachea. They supply the airways up to the respiratory bronchioles including the interlobular connective tissue and the visceral pleura. A
- 4 **Esophageal branches.** Rami oesophageales. Small branches to the esophagus. A
- 5 **Pericardial branches.** Rami pericardiaci. Small branches to the posterior wall of the pericardium. A
- 6 **Mediastinal branches.** Rami mediastinales. Numerous fine branches to the lymph nodes and the connective tissue of the posterior mediastinum. A
- 7 **Superior phrenic arteries.** Aa. phrenicae superiores. Small branches from the lower thoracic aorta to the adjacent parts of the diaphragm. A
- 8 **Posterior intercostal arteries.** Aa. intercostales posteriores. Posterior supply of intercostal spaces 3–9. A B
- 9 **Dorsal branch.** Ramus dorsalis. Posterior branch for the supply of the muscles and skin of the back. B
- 10 **Spinal branches.** Rami spinales. Branches passing through the intervertebral foramina to supply the spinal cord and its membranes. B
- 10a **Postcentral branch.** Ramus postcentralis.
- 10b **Prelaminar branch.** Ramus praelaminaris.
- 10c **Posterior radicular artery.** A. radicularis posterior.
- 10d **Anterior radicular artery.** A. radicularis anterior.
- 10e **Segmental medullary artery.** A. medullaris segmentalis.
- 11 **Medial cutaneous branch.** Ramus cutaneus medialis. Branch that runs alongside the spinous process to the skin. B
- 12 **Lateral cutaneous branch.** Ramus cutaneus lateralis. Branch of the dorsal ramus running beneath the skin further laterally. B
- 13 **Collateral branch [supracostal branch].** Ramus collateralis [ramus supracostalis]. Branch arising in the vicinity of the costal angle and running parallel to the intercostal artery. It proceeds anteriorly along the upper margin of the next lowest rib and anastomoses with the internal thoracic artery. A B
- 14 **Lateral cutaneous branch.** Ramus cutaneus lateralis. Branch running laterally beneath the skin and ramifying both anteriorly and posteriorly. B
- 15 **Lateral mammary branches.** Rami mammarii laterales. Branches from the lateral cutaneous branches to the mammary gland. B
- 16 **Subcostal artery.** A. subcostalis. Segmental arterial branch lying below the 12th rib. It corresponds to an intercostal artery.
- 17 **Dorsal branch.** Ramus dorsalis. It passes to the muscles and skin of the back. B
- 18 **Spinal branch.** Ramus spinalis. It passes through the 12th intervertebral foramen to supply the spinal cord and its membranes. B
- 19 **ABDOMINAL AORTA.** Pars abdominalis aortae. Portion of the aorta extending from its entrance into the diaphragm to its bifurcation at the level of the body of L4. A
- 20 **Inferior phrenic artery.** A. phrenica inferior. Paired arteries that supply the diaphragm, which they enter from below. A
- 21 **Superior suprarenal arteries.** Aa. suprarenales (adrenales) superiores. Uppermost group of three suprarenal arteries. A
- 22 **Lumbar arteries.** Aa. lumbales. Four segmental arteries which correspond to the intercostal arteries. A
- 23 **Dorsal branch.** Ramus dorsalis. Branch that supplies the muscles of the back and the medial skin segments. A
- 24 **Spinal branch.** Ramus spinalis. Branch passing through the intervertebral foramen to supply the spinal cord and its membranes.
- 25 **Median sacral artery.** A. sacralis mediana. Thin median continuation of the aorta. A
- 26 **Lowest lumbar arteries.** Aa. lumbales imae. Paired lateral branches of the median sacral artery. They correspond to a 5th lumbar artery. A
- 26a **Lateral sacral branches.** Rami sacrales laterales. They anastomose with the lateral sacral arteries of the internal iliac artery.
- 27 **Coccygeal body.** Glomus coccygeum. Mass containing arteriovenous anastomoses and epithelioid cells located at the end of the median sacral artery in front of the tip of the coccyx. A
- 28 **Celiac trunk.** Truncus coeliacus. Common stem of the left gastric, common hepatic and splenic arteries at the level of T12. A
- 29 **Left gastric artery.** A. gastrica sinistra. Artery ascending in the left gastropancreatic fold to the cardiac portion of the stomach and continuing along the lesser curvature. A
- 30 **Esophageal branches.** Rami oesophageales. Small branches that supply the esophageal segment above the cardia of the stomach. A

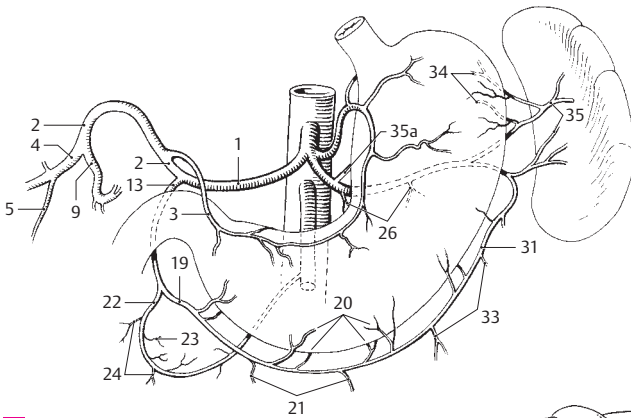


A Aorta

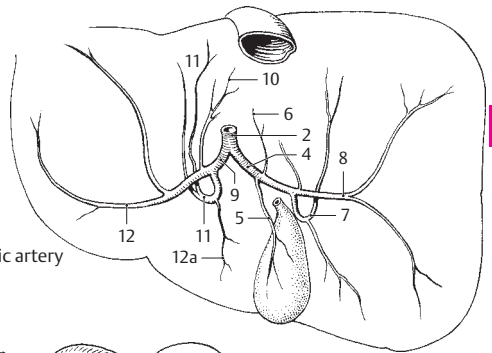


B Intercostal artery

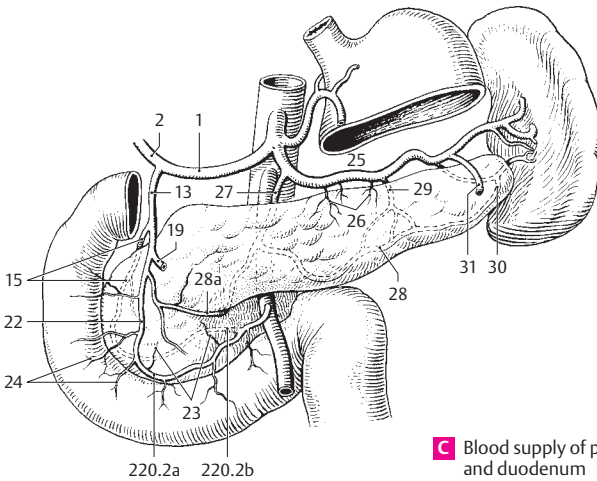
- 1 **Common hepatic artery.** A. hepatica communis. Branch of the celiac trunk (occasionally also the superior mesenteric artery) passing to the right side toward the liver and dividing into the gastroduodenal artery and the hepatic artery proper. Besides supplying the liver, it also partially supplies the stomach, duodenum and pancreas. A C
- 2 **Hepatic artery proper.** A. hepatica propria. One of the two terminal branches of the common hepatic artery. It passes into the liver. A B C
- 3 **Right gastric artery.** A. gastrica dextra. It passes to the upper margin of the pylorus, then along the lesser curvature of the stomach to anastomose with the left gastric artery. A
- 4 **Right branch of hepatic artery proper (right hepatic artery).** Ramus dexter. It passes to the right side of the hilum of the liver and supplies the right lobe. It frequently also arises from the superior mesenteric artery. A B
- 5 **Cystic artery.** A. cystica. Originating from the right branch of the hepatic artery proper, it passes to the anterior and posterior surfaces of the gallbladder. A B
- 6 **Artery to caudate lobe.** A. lobi caudati. B
- 7 **Anterior segmental artery.** A. segmenti anterioris. It supplies the anterior segment of the liver. B
- 8 **Posterior segmental artery.** A. segmenti posterioris. It supplies the posterior segment of the liver. B
- 9 **Left branch of hepatic artery proper (left hepatic artery.)** Ramus sinister. It supplies the left lobe of the liver. A B
- 10 **Artery to caudate lobe.** A. lobi caudati. B
- 11 **Medial segmental artery.** A. segmenti medialis. It supplies the medial segment of the liver. B
- 12 **Lateral segmental artery.** A. segmenti lateralis. It supplies the lateral segment of the liver. B
- 12a **Intermediate branch.** Ramus intermedius. It supplies the quadrate lobe. B
- 13 **Gastroduodenal artery.** A. gastroduodenalis. Behind the lower margin of the pylorus, it divides into an anterior supraduodenal artery and the right gastro-omental artery. A C
- 14 **Supraduodenal artery.** [A. supraduodenalis]. Inconstant first branch that supplies the anterior 2/3 and the posterior 1/3 of the duodenum.
- 15 **Posterior superior pancreaticoduodenal artery.** A. pancreaticoduodenalis superior posterior. Arising behind the pancreas it follows the duodenum somewhat and anastomoses with the inferior pancreaticoduodenal artery. C
- 16 **Pancreatic branches.** Rami pancreatici. Branches to the head of the pancreas.
- 17 **Duodenal branches.** Rami duodenales.
- 18 **Retroduodenal arteries.** Aa. retroduodenales. Branches of gastroduodenal artery that supply posterior surface of duodenum and head of pancreas. They cross over the bile duct and contribute with a small vessel to its supply.
- 19 **Right gastro-omental [[gastroepiploic]] artery.** A. gastro-omentalis dextra. It originates at the level of the inferior margin of the pylorus and, as the continuation of the gastroduodenal artery, passes in the greater omentum different distances from the greater curvature of the stomach. It anastomoses with the left gastro-omental artery. A C
- 20 **Gastric branches.** Rami gastrici. Short branches ascending to the stomach. A
- 21 **Omental branches.** Rami omentales. Long branches that supply the greater omentum. A
- 22 **Anterior superior pancreaticoduodenal artery.** A. pancreaticoduodenalis superior anterior. Terminal branch that passes inferiorly on the pancreas and anastomoses to the inferior pancreaticoduodenal artery. A C
- 23 **Pancreatic branches.** Rami pancreatici. A C
- 24 **Duodenal branches.** Rami duodenales A C
- 25 **Splenic (lineal) artery.** A. splenica (lienalis). Third branch of the celiac trunk. It runs along the upper margin of the pancreas then through the splenorenal ligament to the spleen. C
- 26 **Pancreatic branches.** Rami pancreatici. Numerous small and several large branches to pancreas. A C
- 27 **Dorsal pancreatic artery.** A. pancreatica dorsalis. Arising just at the beginning of the splenic artery, it passes downward behind the neck of the pancreas partially embedded in pancreatic tissue. C
- 28 **Inferior pancreatic artery.** A. pancreatica inferior. Branch of the dorsal pancreatic artery passing toward the left to the lower posterior surface of the body of the pancreas. C
- 28a **Prepancreatic artery.** A. prepancreatica. Anastomosis between the main branch of the dorsal pancreatic artery and the anterior superior pancreaticoduodenal artery. C
- 29 **A. pancreatica magna.** It passes from near the middle of the splenic artery downward onto the posterior surface of the pancreas, which it supplies, and anastomoses with the inferior pancreatic artery. C
- 30 **Artery to tail of pancreas.** A. caudae pancreatis. It originates from the distal end of the splenic artery or from one of its terminal branches and anastomoses with the inferior pancreatic artery in the tail of the pancreas. C
- 31 **Left gastro-omental (gastro-epiploic) artery.** A. gastro-omentalis (epiploica) sinistra. Arises from the gastrosplenic ligament, then passes in the greater omentum to anastomose with the right gastro-omental artery. A C
- 32 **Gastric branches.** Rami gastrici. Long branches to the stomach.
- 33 **Omental branches.** Rami omentales. Long branches that supply the greater omentum. A
- 34 **Short gastric arteries.** Aa. gastrici breves. Small vessels from the splenic artery or its branches that mainly supply the fundus of the stomach. A
- 35 **Splenic branches.** Rami splenici. Five to six branches of the splenic artery arising in front of the entrance into the spleen. A
- 35a **Posterior gastric artery.** A gastrica posterior. Branch to the posterior wall of the stomach. A



A Celiac trunk

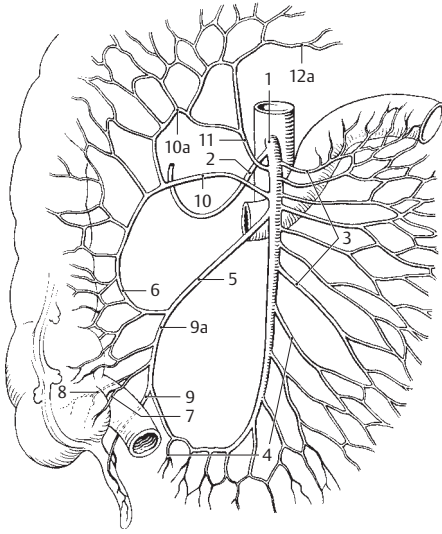


B Branches of hepatic artery

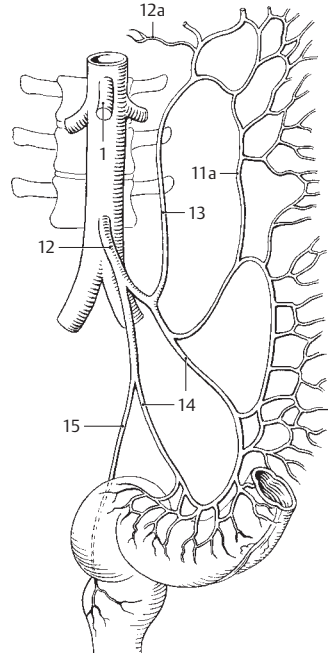


C Blood supply of pancreas and duodenum

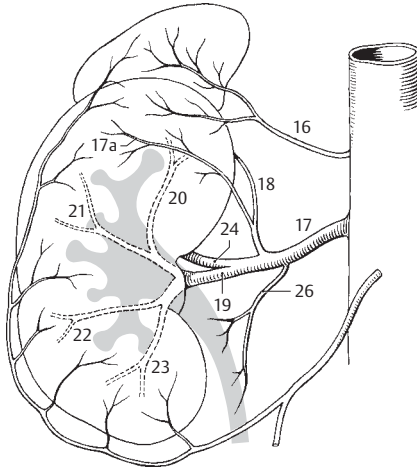
- 1 **Superior mesenteric artery.** A. mesenterica superior. Unpaired branch of the aorta arising about 1 cm below the celiac trunk. It extends from behind the pancreas to the uncinate process and passes with its branches into the mesentery and mesocolon. A B
- 2 **Inferior pancreaticoduodenal artery.** A. pancreaticoduodenalis inferior. It arises behind the pancreas and passes between the duodenum and pancreas to anastomose with the superior pancreaticoduodenal artery. A
- 2a **Anterior branch.** Ramus anterior. It anastomoses with the anterior superior pancreaticoduodenal artery. See p. 219 C
- 2b **Posterior branch.** Ramus posterior. It anastomoses with the posterior superior pancreaticoduodenal artery. See p. 219 C
- 3 **Jejunal branches.** Aa. jejunales. Branches coursing in the mesentery to supply the jejunum. A
- 4 **Ileal branches.** Aa. ileales. Branches coursing in the mesentery to supply the ileum. A
- 5 **Ileocolic artery.** A. ileocolica. It passes in the root of the mesentery downward and to the right toward the ileocecal junction. A
- 6 **Colic branch.** Ramus colicus. Ascending branch to the ascending colon. It anastomoses with the right colic artery. A
- 7 **Anterior cecal artery.** A. caecalis (cecalis) anterior. It passes in the vascular cecal fold to the anterior surface of the cecum. A
- 8 **A. caecalis (cecalis) posterior.** It courses behind the ileocecal junction to the posterior surface of the cecum. A
- 9 **Appendicular artery.** A. appendicularis. It extends from behind the ileum to the free margin of the meso-appendix. It varies greatly in its origin and is often doubled. A
- 9a **Ileal branch.** Ramus ilealis. Descending branch to the ileum. It anastomoses with the lowermost ileal artery. A
- 10 **Right colic artery.** A. colica dextra. It passes retroperitoneally to the ascending colon. Anastomoses with the a scending branch of ileocolic artery and middle colic artery. A
- 10a **Artery to right colic flexure.** A. flexura dextra. A
- 11 **Middle colic artery.** A. colica media. It passes in the mesocolon to the transverse colon. A
- 11a **Marginal colic artery** [[of Drummond]]. A. marginalis coli. Anastomosis between the left colic artery and the sigmoid arteries. B
- 12 **Inferior mesenteric artery.** A. mesenterica inferior. Arising at the level of L3–4, it passes to the left to supply the descending colon, sigmoid colon and rectum. B
- 12a **Ascending [intermesenteric] artery.** A. ascendens [A. intermesenterica]. Anastomosis between the left colic artery and the middle colic artery. A B
- 13 **Left colic artery.** A. colica sinistra. It passes retroperitoneally to the descending colon. B
- 14 **Sigmoid arteries.** Aa. sigmoidea. They pass obliquely downward to the sigmoid colon. B
- 15 **Superior rectal artery.** A. rectalis superior. It passes behind the rectum into the lesser pelvis and divides into right and left branches which, after penetrating the musculature, supply mainly the mucosa up to the anal valves. B
- 16 **Middle suprarenal artery.** A. suprarenalis (adrenalis) media. It originates directly from the aorta and supplies the suprarenal gland. C
- 17 **Renal artery.** A. renalis. It arises from the aorta in front of L1 and divides into several branches which enter the kidney. C D
- 17a **Capsular arteries.** Aa. capsulares (perirenales). C
- 18 **Inferior suprarenal artery.** A. suprarenalis inferior. Artery to the suprarenal gland. C
- 19 **Anterior branch.** Ramus anterior. It supplies the upper, anterior and lower segments of the kidney. C D
- 20 **Superior segmental artery.** A. segmenti superioris. It supplies the upper segment of the kidney as far as the posterior surface. C
- 21 **Superior anterior segmental artery.** A. segmenti anterioris superioris. It supplies the superior anterior segment of the kidney. C
- 22 **Inferior anterior segmental artery.** A. segmenti anterioris inferioris. It supplies the inferior anterior segment of the kidney. C
- 23 **Inferior segmental artery.** A. segmenti inferioris. It supplies the lower segment of the kidney extending up to the posterior surface. C
- 24 **Posterior branch.** Ramus posterior. It supplies the larger posterior segment of the kidney. C D
- 25 **Posterior segmental artery.** A. segmenti posterioris. It supplies the posterior segment of the kidney. D
- 26 **Ureteric branches.** Rami ureterici. Small branches that supply the ureter. C



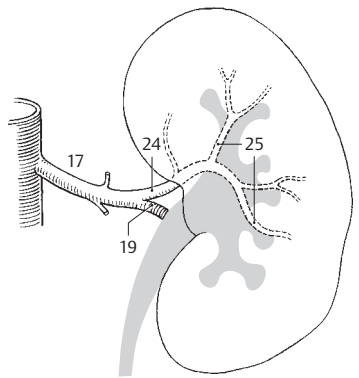
A Superior mesenteric artery



B Inferior mesenteric artery

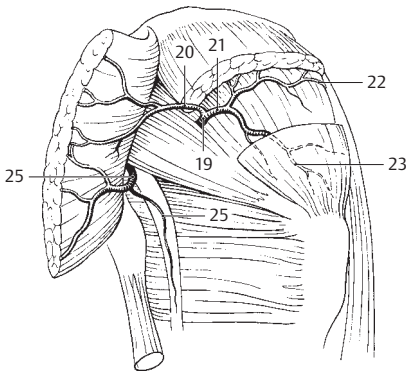


C Segmental arteries of the kidney from front

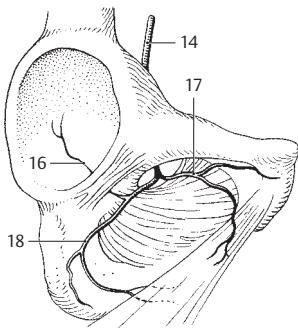


D Segmental arteries of the kidney from behind

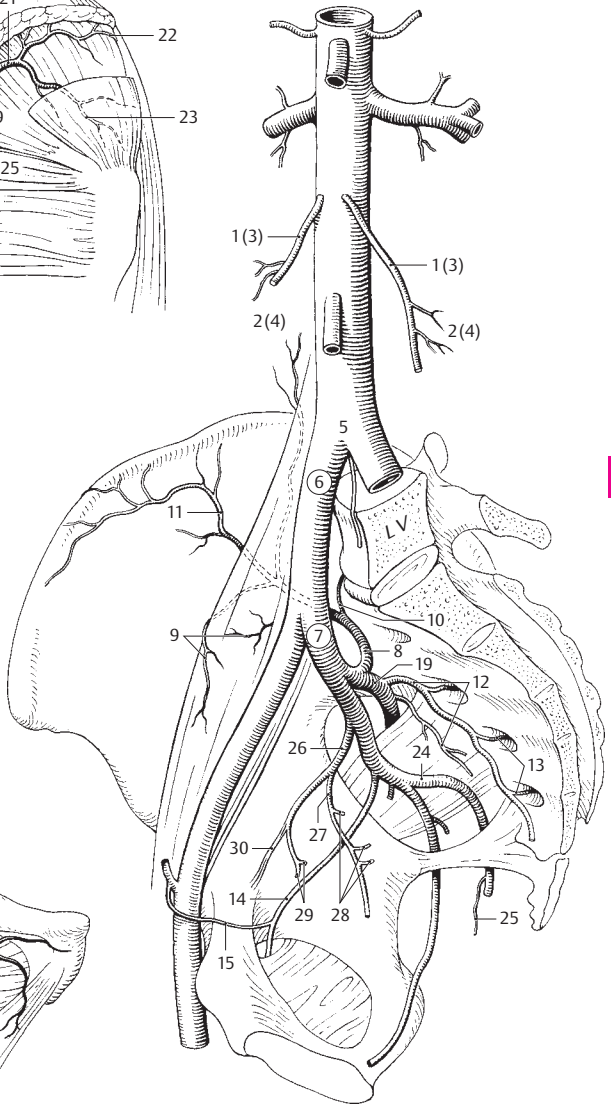
- 1 **Testicular artery.** A. testicularis. It arises from the aorta at the level of L2, crosses over the ureter and, with the ductus deferens, passes through the inguinal canal into the testis. C
- 2 **Ureteric branches.** Rami ureterici. Small branches to the ureter. C
- 2a **Epididymal branches.** Rami epididymales. Branches to the epididymis.
- 3 **Ovarian artery.** A. ovarica. It arises from the aorta at the level of L2 and passes to the ovary within its suspensory ligament. It anastomoses with the uterine artery. C
- 4 **Ureteric branches.** Rami ureterici. Small branches to the ureter. C
- 4a **Tubal branches.** Rami tubarii (tubales). Branches that supply the infundibulum of the uterine tube. They anastomose with the uterine artery. See page 225 C
- 5 **BIFURCATION OF AORTA.** Bifurcatio aortae. It occurs in front of L4, thus directly below the umbilicus. C
- 6 **COMMON ILIAC ARTERY.** A. iliaca communis. It extends from the bifurcation of the descending aorta at L4 to its division into the internal and external iliac arteries in front of the sacroiliac joint. It gives off only insignificant branches. C
- 7 **Internal iliac artery.** A. iliaca interna. It begins at the division of the common iliac artery, passes into the lesser pelvis and reaches as far as the upper margin of the greater sciatic foramen. Its branches vary greatly. C
- 8 **Iliolumbar artery.** A. iliolumbalis. It passes beneath the psoas muscle and the internal iliac artery and into the iliac fossa. C
- 9 **Lumbar branch.** Ramus lumbalis. Branch leading into the psoas and quadratus lumborum muscles. C
- 10 **Spinal branch.** Ramus spinalis. Branch passing between the sacrum and L5 to enter the vertebral canal. C
- 11 **Iliac branch.** Ramus iliacus. Branch passing to the iliacus muscle in the iliac fossa; it lies parallel to the pelvis and anastomoses with the deep circumflex iliac artery. C
- 12 **Lateral sacral arteries.** Aa. sacrales laterales. Arteries passing downward lateral to the medial sacral artery. They can also arise from the superior gluteal artery. C
- 13 **Spinal branches.** Rami spinales. Arteries traversing the pelvic sacral foramina into the sacral canal. C
- 14 **Obturator artery.** A. obturatoria. It courses in the lateral wall of the pelvis and passes through the obturator foramen to supply the adductor muscles. B C
- 15 **Pubic branch.** Ramus pubicus. It anastomoses with the obturator branch of the inferior epigastric artery [[corona mortis]]. C
- 16 **Acetabular branch.** Ramus acetabularis. It passes through the acetabular notch to the ligament for the head of the femur. B
- 17 **Anterior branch.** Ramus anterior. Located on the adductor brevis; it anastomoses with the medial circumflex femoral artery. B
- 18 **Posterior branch.** Ramus posterior. It is located beneath the adductor brevis. B
- 19 **Superior gluteal artery.** A. glutealis superior. It traverses the greater sciatic foramen above the piriformis [[suprapiriform foramen]] to enter the gluteal region. A C
- 20 **Superficial branch.** Ramus superficialis. It lies between the gluteus maximus and medius and anastomoses with the inferior gluteal artery. A
- 21 **Deep branch.** Ramus profundus. It lies between the gluteus medius and minimus. A
- 22 **Superior branch.** Ramus superior. It runs along the upper margin of the gluteus minimus as far as the tensor fasciae latae. A
- 23 **Inferior branch.** Ramus inferior. It courses in the gluteus medius as far as the greater trochanter. A
- 24 **Inferior gluteal artery.** A. glutealis inferior. Emerges through the greater sciatic foramen below the piriformis muscle [[infrapiriform foramen]]; its branches are distributed beneath the gluteus maximus. They anastomose with the superior gluteal, obturator and circumflex femoral arteries. A C
- 25 **Accompanying artery of sciatic nerve (sciatic artery).** A. comitans n. ischiadici (sciatici). Phylogenetically speaking, the major artery of the leg. It accompanies and supplies the sciatic nerve and anastomoses with the medial circumflex femoral artery and perforating branches. A C
- 26 **Umbilical artery.** A. umbilicalis. First inferior branch of the internal iliac artery. After birth, it becomes obliterated beyond the exit of the superior vesical arteries. C
- 26a **Patent part.** Pars patens. Portion of the fetal umbilical artery which does not become obliterated postnatally. It gives off the vessels listed below.
- 27 **Artery of ductus deferens.** A. ductus deferentis. It descends in the pelvis up to the base of the bladder. From there downward, it accompanies the ductus deferens to eventually anastomose with the testicular artery. C
- 28 **Ureteric branches.** Rami ureterici. Three branches that supply the ureter. C
- 29 **Superior vesical arteries.** Aa. vesicales superiores. Arteries to the upper and middle segments of the urinary bladder. C
- 29a **Occluded part.** Pars occlusa. Portion of the fetal umbilical artery which becomes obliterated postnatally and forms the medial umbilical ligament.
- 30 **Medial umbilical ligament.** Ligamentum umbilicale mediale [[laterale]]. Fibrous cord remnant of the umbilical artery occupying the medial umbilical fold. C



A Gluteal arteries

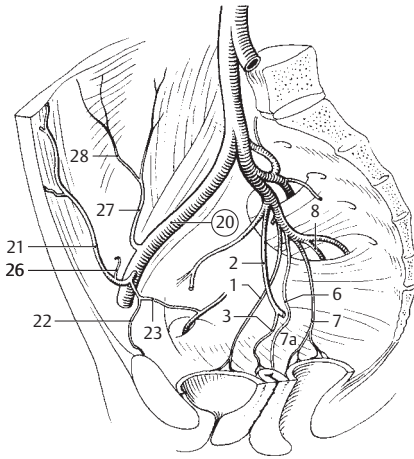


B Obturator artery

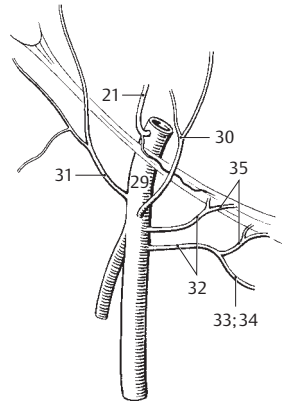


C Iliac arteries

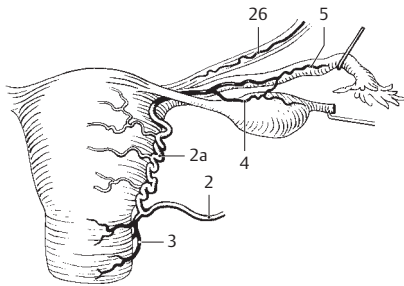
- 1 **Inferior vesical artery.** A. vesicalis inferior. It supplies the inferior part of the urinary bladder and, in males, the prostate and seminal vesicle. A
- 1a **Prostatic branches.** Rami prostatici. Branches that supply the prostate and seminal vesicle.
- 2 **Uterine artery.** A. uterina. It corresponds to the artery of the ductus deferens. It passes to the cervix within the base of the broad ligament and very tortuously ascends lateral to the uterus. A C
- 2a **Helicine branches.** Rami helisini. Corkscrewlike, coiled terminal branches of the uterine artery. C
- 3 **Vaginal branches (azygos arteries of vagina).** Rami vaginales (aa. azygosi vaginae). Branches to the cervix that anastomose with vessels on the opposite side to supply the upper part of the vagina. A C
- 4 **Ovarian branch.** Ramus ovaricus. It runs along the ovarian ligament proper and through the mesovarium to the ovary. It anastomoses with the ovarian artery and the tubal branch of the uterine artery. C
- 5 **Tubal branch.** Ramus tubarius (tubalis). It runs in the mesosalpinx of the tube to the point where it anastomoses with the ovarian artery. C
- 6 **Vaginal artery.** A. vaginalis. It arises directly from the internal iliac artery. A
- 7 **Middle rectal artery.** A. rectalis media. It crosses the floor of the pelvis to the rectum and supplies the rectal muscles. A E
- 7a **Vaginal branches.** [Rami vaginales]. Branches to the lower part of the vagina. A
- 8 **Internal pudendal artery.** A. pudenda interna. It passes through the greater sciatic foramen [[infrapiriform]] from the pelvis and through the lesser sciatic foramen to the lateral wall of the ischiorectal fossa. A D E
- 9 **Inferior rectal artery.** A. rectalis inferior. It passes transversely through the ischiorectal fossa and supplies both sphincters as well as the skin below the anal valves. D E
- 10 **Perineal artery.** A. perinealis. It arises at the posterior margin of the urogenital diaphragm and supplies the bulbospongiosus and ischio-cavernosus muscles. D E
- 11 **Posterior scrotal branches.** Rami scrotales posteriores. Branches passing to the scrotum. E
- 12 **Posterior labial branches.** Rami labiales posteriores. Branches that extend to the labium majus. D
- 13 **Urethral artery.** A. urethralis. It penetrates the corpus spongiosum at the junction of the crura of the penis and travels as far as the glans. It anastomoses with the dorsal and deep arteries of the penis. E
- 14 **Artery of bulb of penis.** A. bulbi penis. Besides the bulb of the penis, it also supplies the deep transversus perinei muscle and the bulbourethral gland. E
- 15 **Artery of bulb of vestibule.** A. bulbi vestibuli (vaginae). D
- 16 **Deep artery of penis.** A. profunda penis. It passes distally in the corpus cavernosum. E
- 17 **Dorsal artery of penis.** A. dorsalis penis. It passes beneath the fascia as far as the glans. E, p. 165 B.
- 18 **Deep artery of clitoris.** A. profunda clitoridis. See 16.
- 19 **Dorsal artery of clitoris.** A. dorsalis clitoridis. See 17.
- ARTERIES OF LOWER LIMB.** Arteriae membri inferioris.
- 20 **External iliac artery.** A. iliaca externa. Second branch of the common iliac artery; it continues as the femoral artery. A
- 21 **Inferior epigastric artery.** A. epigastrica inferior. It arises dorsal to the inguinal ligament and passes upward to the inner surface of the rectus abdominis. It produces the lateral umbilical fold and anastomoses with the superior epigastric artery. A B
- 22 **Pubic branch.** Ramus pubicus. Branch that supplies the pubis. A
- 23 **Obturator branch.** Ramus obturatorius. Branch anastomosing with the pubic branch of the obturator artery [[corona mortis]]. A
- 24 **Accessory obturator artery.** [A. obturatoria accessoria]. Obturator artery occasionally arising from the inferior epigastric artery.
- 25 **Cremasteric artery.** A. cremasterica. Branch that supplies the cremaster muscle in the spermatic cord. It corresponds to the artery of the round ligament of the uterus.
- 26 **Artery of round ligament of uterus.** A. ligamenti teretis uteri. It supplies the connective tissue and smooth muscle of the round ligament. A C
- 27 **Deep circumflex iliac artery.** A. circumflexa iliaca profunda. Branch taking a curved course posterolaterally along the iliac crest beneath the transversalis fascia. A
- 28 **Ascending branch.** Ramus ascendens. It ascends between the transversus abdominis and internal abdominal oblique muscles to McBurney's point. It anastomoses with the ilio lumbar artery. A
- 29 **Femoral artery.** A. femoralis. It extends from the inguinal ligament to the popliteal artery, with which it is continuous. B
- 30 **Superficial epigastric artery.** A. epigastrica superficialis. It arises distal to the inguinal ligament and courses on the abdominal musculature toward the umbilicus. B
- 31 **Superficial circumflex iliac artery.** A. circumflexa iliaca superficialis. It proceeds parallel to the inguinal ligament in the direction of the anterior superior iliac spine. B
- 32 **External pudendal arteries.** Aa. pudendae externae. Usually paired arteries that supply the lower abdominal wall and the external genitalia. B
- 33 **Anterior scrotal branches.** Rami scrotales anteriores. Branches that supply the scrotum. B
- 34 **Anterior labial branches.** Rami labiales anteriores. They supply the labia. B
- 35 **Inguinal branches.** Rami inguinales. Branches that supply the inguinal region. B



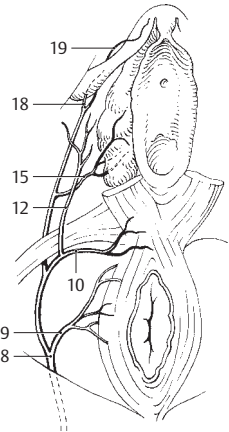
A Internal and external iliac arteries



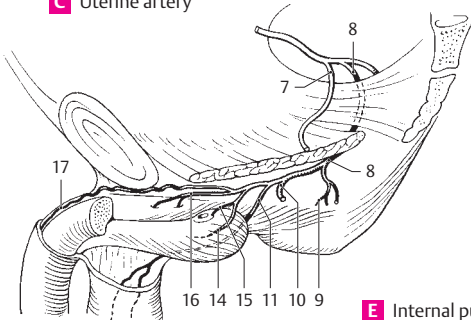
B Femoral artery



C Uterine artery

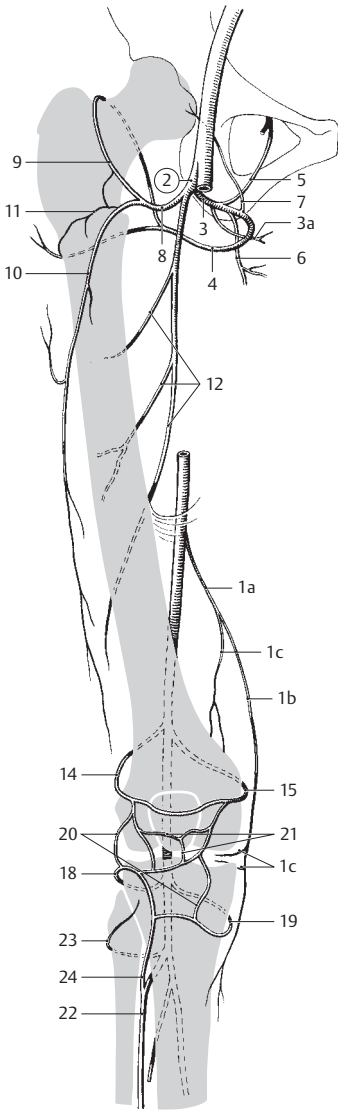


D Internal pudendal artery

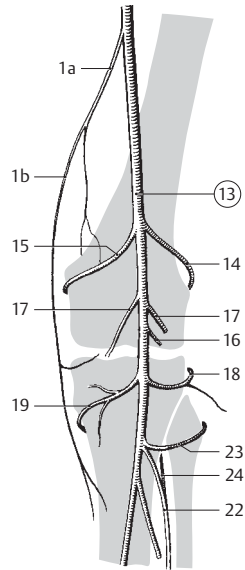


E Internal pudendal artery from below

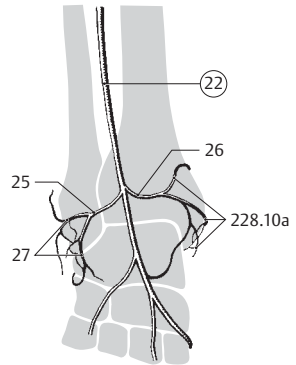
- 1 a **Descending genicular artery.** A. descendens genicularis. It arises in the adductor canal and penetrates the vasto-adductor membrane. A B
- 1 b **Saphenous branch.** Ramus saphenus. It accompanies the saphenous nerve to the leg. A B
- 1 c **Articular branch.** Ramus articularis. Anastomoses with branches running in the vastus medialis, then ends in the articular network of the knee. A
- 2 **A. profunda femoris.** Larger, deeper and above all more lateral branch of the femoral artery. It crosses under the femoral artery and gives off the branches listed below. A
- 3 **Medial circumflex femoral artery.** A circumflexa femoris medialis. It passes medially and posteriorly between the iliopsoas and pectineus muscles. A
- 3 a **Superficial branch.** Ramus superficialis. It passes between the pectineus and adductor longus muscles. A
- 4 **Deep branch.** Ramus profundus. It runs below the lesser trochanter to the quadratus femoris, adductor magnus and ischiofemoral muscles and anastomoses with the gluteal arteries. A
- 5 **Ascending branch.** Ramus ascendens. It courses in the adductor brevis, adductor magnus and obturator externus muscles and anastomoses with the obturator artery. A
- 6 **Descending branch.** Ramus descendens. It travels between the quadratus femoris and adductor magnus muscles to the ischiofemoral musculature. A
- 7 **Acetabular branch.** Ramus acetabularis. It goes through the acetabular notch into the ligament of the head of the femur and anastomoses with the obturator artery. A
- 8 **Lateral circumflex femoral artery.** A. circumflexa femoris lateralis. It passes laterally beneath the rectus femoris muscle. A
- 9 **Ascending branch.** Ramus ascendens. It ascends under the sartorius and rectus femoris and terminates underneath the tensor fasciae latae. It anastomoses with the medial circumflex femoral and gluteal arteries. A
- 10 **Descending branch.** Ramus descendens. It passes under the rectus femoris to the knee joint. A
- 11 **Transverse branch.** Ramus transversus. It penetrates the vastus lateralis and anastomoses with numerous vessels. A
- 12 **Perforating branches.** Aa. perforantes. Terminal branches of the profunda femoris artery that pass posteriorly close to the femur via slits in the adductor muscles and supply the long knee flexors. A
- 12 a **Nutrient arteries of femur.** Aa. nutrientes (nutriciae) femoris. They arise from the first and third perforating arteries.
- 13 **Popliteal artery.** A. poplitea. It extends from the end of the adductor canal to the site where it divides at the lower margin of the popliteus muscle. B
- 14 **Lateral superior genicular artery.** A. superior lateralis genuis. It passes anteriorly above the lateral femoral condyle and below the biceps tendon to join the articular network of the knee. A B
- 15 **Medial superior genicular artery.** A. superior medialis genuis. It runs anteriorly below the tendon of the adductor magnus to join the articular network of the knee. B
- 16 **Middle genicular artery.** A. media genuis. It runs directly forward to enter the knee joint posteriorly and supplies the cruciate ligaments and synovial folds. B
- 17 **Sural arteries.** Aa. surales. Branches for the calf musculature and the biceps tendon. B
- 18 **Lateral inferior genicular artery.** A. inferior lateralis genuis. It passes under the lateral head of the gastrocnemius and under the lateral collateral ligament to join the articular network of the knee. A B
- 19 **Medial inferior genicular artery.** A. inferior medialis genuis. It passes under the medial head of the gastrocnemius and the medial collateral ligament to join the articular network of the knee. A B
- 20 **Articular network of the knee.** Rete articular genuis. Arterial plexus primarily on the anterior side of the knee joint. A
- 21 **Patellar network.** Rete patellare. Specific arterial plexus on the patella. A
- 22 **Anterior tibial artery.** A. tibialis anterior. It extends from its origin at the lower margin of the popliteus muscle to the lower margin of the inferior extensor retinaculum. After penetrating the interosseous membrane, it passes between the tibialis anterior and the extensor digitorum longus, then between the tibialis anterior and the extensor hallucis longus. A B C
- 23 **Posterior tibial recurrent artery.** [A. recurrens tibialis posterior]. An inconstant branch which passes under the popliteus to the knee joint. A B
- 24 **Anterior tibial recurrent artery.** A. recurrens tibialis anterior. It passes through the tibialis anterior to join the articular network of the knee. A B
- 25 **Lateral anterior malleolar artery.** A. malleolaris anterior lateralis. It passes under the tendons of the extensor digitorum to join the lateral malleolar network. C
- 26 **Medial anterior malleolar artery.** A. malleolaris anterior medialis. It passes under the tendon of the tibialis anterior to join the medial malleolar network. C
- 27 **Lateral malleolar network.** Rete malleolare laterale. Arterial plexus over the lateral malleolus. C



A Arteries of lower limb anterior view

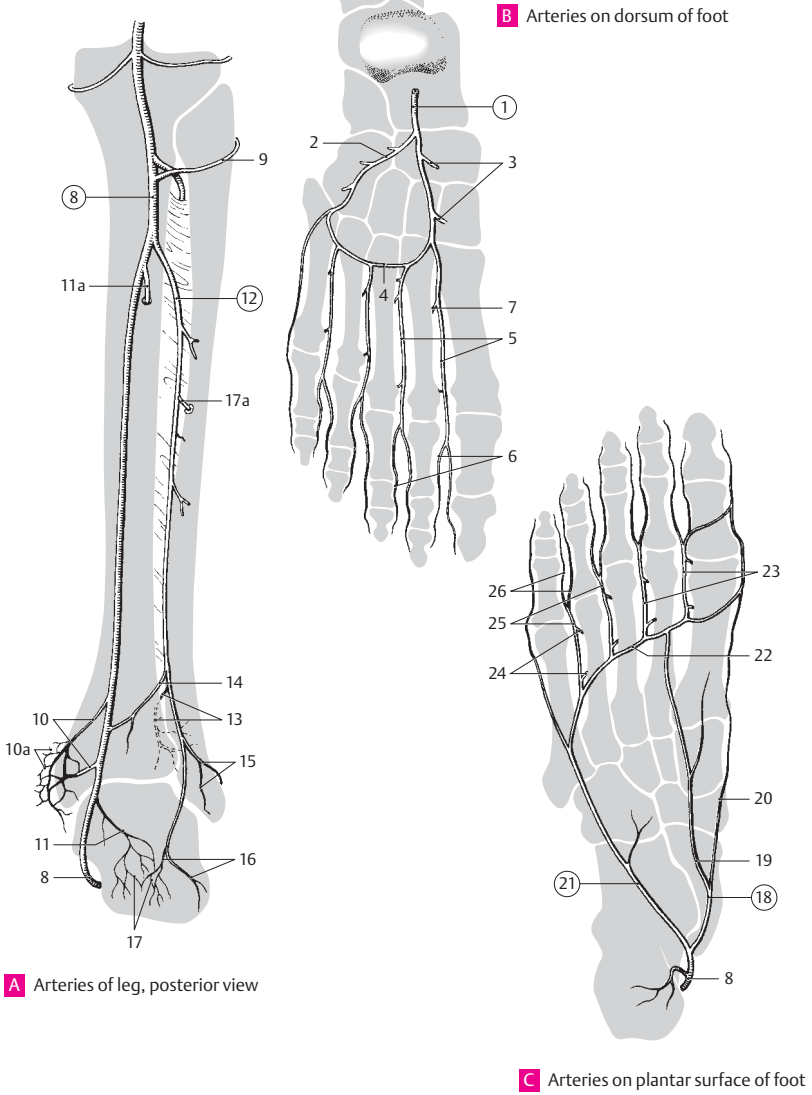


B Popliteal artery



C Ankle joint with arteries anterior view

- 11
- 1 **A. dorsalis pedis.** Continuation of anterior tibial artery on dorsum of foot. After crossing under the tendon of the extensor hallucis longus and passing the extensor retinaculum, it lies lateral to this tendon, where it is palpable. B
 - 2 **Lateral tarsal artery.** A. tarsalis lateralis. Arises at the level of the head of the talus, passes under the short extensors of the toes in the direction of the cuboid bone, and anastomoses with the arcuate artery of the foot. B
 - 3 **Medial tarsal arteries.** Aa. tarsales mediales. Several free branches to the inner margin of the foot. B
 - 4 **Arcuate artery of foot.** [A. arcuata]. It takes a curved course laterally over the base of the metatarsals below the extensor digitorum brevis. B
 - 5 **Dorsal tarsal arteries.** Aa. tarsales dorsales. Four branches which pass distally over the intermetatarsal areas, each dividing into two dorsal digital arteries. B
 - 6 **Dorsal digital arteries.** Aa. digitales dorsales. Interdigital arteries arising from the dorsal tarsal arteries. B
 - 7 **Deep plantar artery.** A. plantaris profunda. Especially large perforating branch of a dorsal tarsal artery for anastomosis with the plantar arch. B
 - 8 **Posterior tibial artery.** A. tibialis posterior. It arrives beneath the tendinous arch of the soleus muscle below the superficial flexor group and passes to the medial malleolus from behind. A C
 - 9 **Fibular circumflex branch.** Ramus circumflexus fibularis [[ramus fibularis]]. Arising near the origin of the posterior tibial artery and passes anteriorly around the fibula to join the articular network of the knee. A
 - 10 **Medial malleolar branches.** Rami malleolares mediales. They pass behind the medial malleolus and join the medial malleolar network. A
 - 10a **Medial malleolar network.** Rete melleolare mediale. Arterial plexus over medial malleolus. A
 - 11 **Calcanean branches.** Rami calcanei. Branches passing to medial surface of calcaneus. A
 - 11a **Nutrient artery of tibia.** A. nutriens (nutricia) tibialis. It courses below the soleil line of the tibia and enters the nutrient foramen. A
 - 12 **Peroneal (fibular) artery.** A. fibularis. Passes to the calcaneus covered for the most part by the flexor hallucis longus. A
 - 13 **Perforating branch.** Ramus perforans. Perforates the interosseous membrane just above the malleolus, then passes to the lateral malleolar network and dorsum of the foot. A
 - 14 **Communicating branch.** Ramus communicans. Transversely coursing anastomotic branch to the posterior tibial artery. A

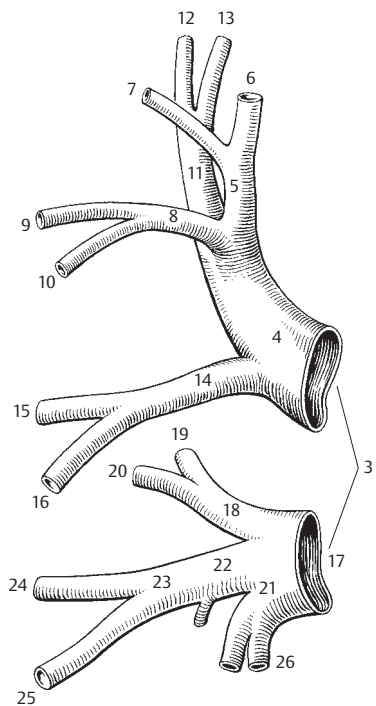


A Arteries of leg, posterior view

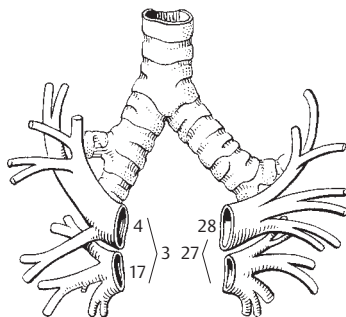
B Arteries on dorsum of foot

C Arteries on plantar surface of foot

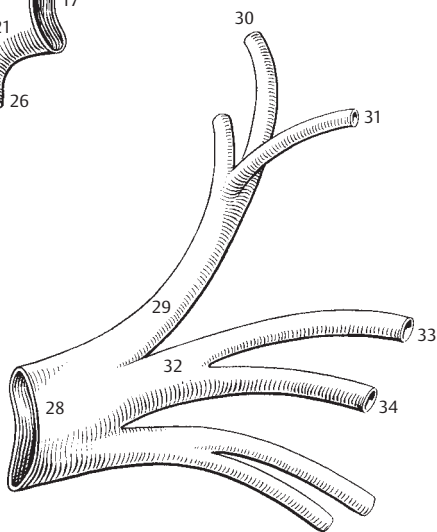
- 1 **VEINS.** Venae. Thin-walled blood vessels which return blood to the heart (atrium).
- 2 **PULMONARY VEINS.** Venae pulmonales. Veins leading from the lungs to the heart.
- 3 **The two superior right pulmonary veins.** [[Venae pulmonales dextrae]]. Occasionally unite to form a single trunk. A B
- 4 **Superior right pulmonary vein.** V. pulmonalis dextra superior. Returns blood from the upper and middle lobes. A B
- 5 **Apical branch.** Ramus apicalis. Returns blood from the apical segment of the upper lobe. A
- 6 **Intrasegmental part.** Pars intrasegmentalis. Twig from the apical segment of the upper lobe. A
- 7 **Intersegmental part.** Pars intersegmentalis. Twig situated between the apical and posterior segments of the upper lobe. A
- 8 **Anterior branch.** Ramus anterior. Branch from the anterior segment of the upper lobe.
- 9 **Intrasegmental part.** Pars intrasegmentalis. Twig from the anterior segment.
- 10 **Intersegmental part.** Pars intersegmentalis. Twig that courses between the anterior and lateral segments. A
- 11 **Posterior branch.** Ramus posterior. Branch that drains the posterior segment of upper lobe. A
- 12 **Infralobar part.** Pars infralobaris. Twig from the posterior segment. A
- 13 **Intralobar part.** Pars intralobaris [intersegmentalis]. Twig lying between the posterior segment of the upper lobe and the apical (superior) segment of the lower lobe. A
- 14 **Middle lobe branch.** Ramus lobi medii. A
- 15 **Lateral part.** Pars lateralis. Twig from the lateral segment of the middle lobe. A
- 16 **Medial part.** Pars medialis. Twig from the medial segment of the middle lobe. A
- 17 **Inferior right pulmonary vein.** V. pulmonalis dextra inferior. Returns blood from the right lower lobe. A B
- 18 **Superior branch.** Ramus superior. Returns blood from the apical (superior) segment of the lower lobe. A
- 19 **Intrasegmental part.** Pars intrasegmentalis. Drains the apical segment of the lower lobe.
- 20 **Intersegmental part.** Pars intersegmentalis. Twig between the apical and posterior basal segments of the lower lobe. A
- 21 **Common basal vein.** V. basalis communis. Common vein from the basal pulmonary segments. A
- 22 **Superior basal vein.** V. basalis superior. Vein that drains the lateral and anterior basal segments. A
- 23 **Anterior basal root.** Radix basalis anterior. Vein from the anterior and part of the lateral basal segments. A
- 24 **Intrasegmental part.** Pars intrasegmentalis. Twig from the anterior basal segment. A
- 25 **Intersegmental part.** Pars intersegmentalis. Twig between the anterior and lateral basal segments. A
- 26 **Inferior basal segment.** V. basalis inferior. Vein from the posterior basal segment. A
- 27 **Left superior pulmonary veins.** Vv. pulmonalis sinistra superior. The two left pulmonary veins that occasionally unite to form a single trunk. B
- 28 **Left superior pulmonary vein.** V. pulmonalis sinistra superior. Returns blood from the left upper lobe. B C
- 29 **Apicoposterior branch.** Ramus apicoposterior. Drains the apicoposterior segment. C
- 30 **Intrasegmental part.** Pars intrasegmentalis. Twig from the apicoposterior segment. C
- 31 **Intersegmental part.** Pars intersegmentalis. Twig between the apicoposterior and anterior segments. C
- 32 **Anterior branch.** Ramus anterior. Branch from the anterior segment. C
- 33 **Intrasegmental part.** Pars intrasegmentalis. Twig from the anterior segment. C
- 34 **Intersegmental part.** Pars intersegmentalis. Twig between the anterior and superior lingular segments. C



A Right pulmonary veins



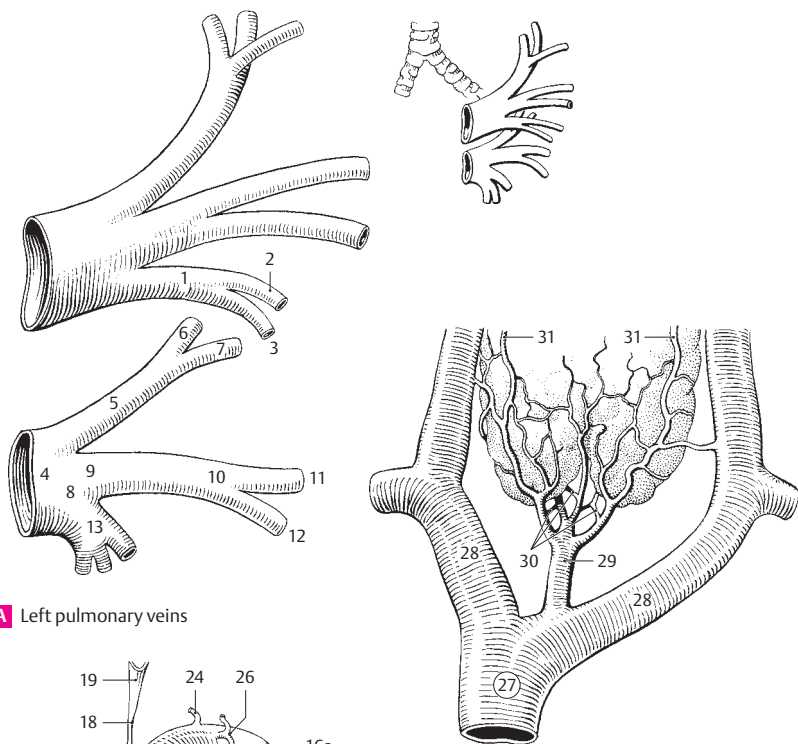
B Pulmonary veins, schematic representation



C Superior left pulmonary vein

12

- 1 **Lingular branch.** Ramus lingularis. Common branch from the two lingular segments. A
- 2 **Superior part.** Pars superior. Twig from the superior lingular segment. A
- 3 **Inferior part.** Pars inferior. Twig from the inferior lingular segment. A
- 4 **Left inferior pulmonary vein.** V. pulmonalis sinistra inferior. Returns blood from the left lower lobe. A
- 5 **Superior branch.** Ramus superior. Branch from the superior (apical) segment of the lower lobe. A
- 6 **Intrasegmental part.** Pars intrasegmentalis. Twig from the superior (apical) segment of the left lower lobe. A
- 7 **Intersegmental part.** Pars intersegmentalis. Twig lying laterally between the superior and anterior basal segments and medially between the superior and posterior basal segments. A
- 8 **Common basal vein.** V. basalis communis. Common trunk of the superior and inferior basal veins. A
- 9 **Superior basal vein.** V. basalis superior. Located between the anterior basal branch and the common basal vein. A
- 10 **Anterior basal branch.** Ramus basalis anterior. Branch from the anterior basal segment. A
- 11 **Intrasegmental part.** Pars intrasegmentalis. Twig from the anterior basal segment. A
- 12 **Intersegmental part.** Pars intersegmentalis. Twig between the medial and lateral basal segments. A
- 13 **Inferior basal vein.** V. basalis inferior. Returns blood from the posterior basal segment. A
- 14 **CARDIAC VEINS.** Venae cordis. Veins from the heart wall. B
- 15 **Coronary sinus.** Sinus coronarius. Collecting vein situated on the posterior wall of the left atrium. It begins at the opening of the oblique vein of the left atrium and ends at the site where it opens into the right atrium. B
- 16 **Anterior interventricular vein.** V. interventricularis anterior. Lodges in the anterior interventricular groove. B
- 16a **Left coronary vein.** V. coronaria sinistra. Continuation of the anterior interventricular vein in the left coronary (atrioventricular) groove. B
- 17 **Posterior vein of left ventricle.** V. ventriculi sinistri posterior. It passes upwards from the left margin of the heart to empty into the great cardiac vein or the coronary sinus. B
- 18 **Oblique vein of left atrium.** V. obliqua atrii sinistri. Small, rudimentary vein at the posterior wall of the left atrium (remains of the left duct of Cuvier). B
- 19 **Fold of left vena cava.** Plica v. cavae sinistrae. Fold of serous pericardium caused by a fibrous strand between the brachiocephalic vein and the oblique vein (vestige of embryonic left superior vena cava). It lies in front of the left pulmonary vessels and can unite them. B
- 20 **Posterior interventricular vein.** V. interventricularis posterior. It runs in the posterior interventricular groove and opens into the coronary sinus. B
- 20a **Right marginal vein.** V. marginalis dextra. It lies at the outer margin of the right ventricle. B
- 20b **Right coronary vein.** V. coronaria dextra. Accessory vein (32% of the cases) in the right coronary groove.
- 21 **Small cardiac vein.** V. cardiaca parva. Emerges from the right margin of the heart and the right coronary groove to empty into the coronary sinus. B
- 22 **Anterior vein of right ventricle.** V. ventriculi dextri anterior. One of three small veins in the right anterior wall. It opens either into the small cardiac vein or directly into the right atrium. B
- 23 **Smallest cardiac.** [[thebesian]] veins. Vv. cardiaca minima [[Thebesii]]. Small veins opening directly into the cavities of the heart, especially that of the right atrium.
- 24 **Right and left atrial veins.** Vv. atriales dextrae et sinistrae. Small branches from the atrial walls. B
- 25 **Ventricular veins.** Vv. ventriculares. Small branches from the walls of the ventricles. B
- 26 **Atrioventricular veins.** Vv. atrioventriculares. Small veins from the atrioventricular borders. B
- 27 **SUPERIOR VENA CAVA.** Vena cava superior. C
- 28 **RIGHT AND LEFT BRACHIOCEPHALIC VEINS.** Vv. brachiocephalicae [dextra at sinistra]. Formed by the union of the internal jugular and subclavian veins on each side. They, in turn, unite to form the superior vena cava. C
- 29 **Inferior thyroid veins.** Vv. thyroideae inferiores. Veins passing into the left brachiocephalic vein, sometimes also the right, from the thyroideus impar plexus located below the thyroid gland. C
- 30 **Plexus thyroideus impar.** Venous plexus in front of the trachea below the caudal margin of the thyroid gland. C
- 31 **Inferior laryngeal vein.** V. laryngea inferior. It passes from the larynx into the thyroideus impar plexus. C



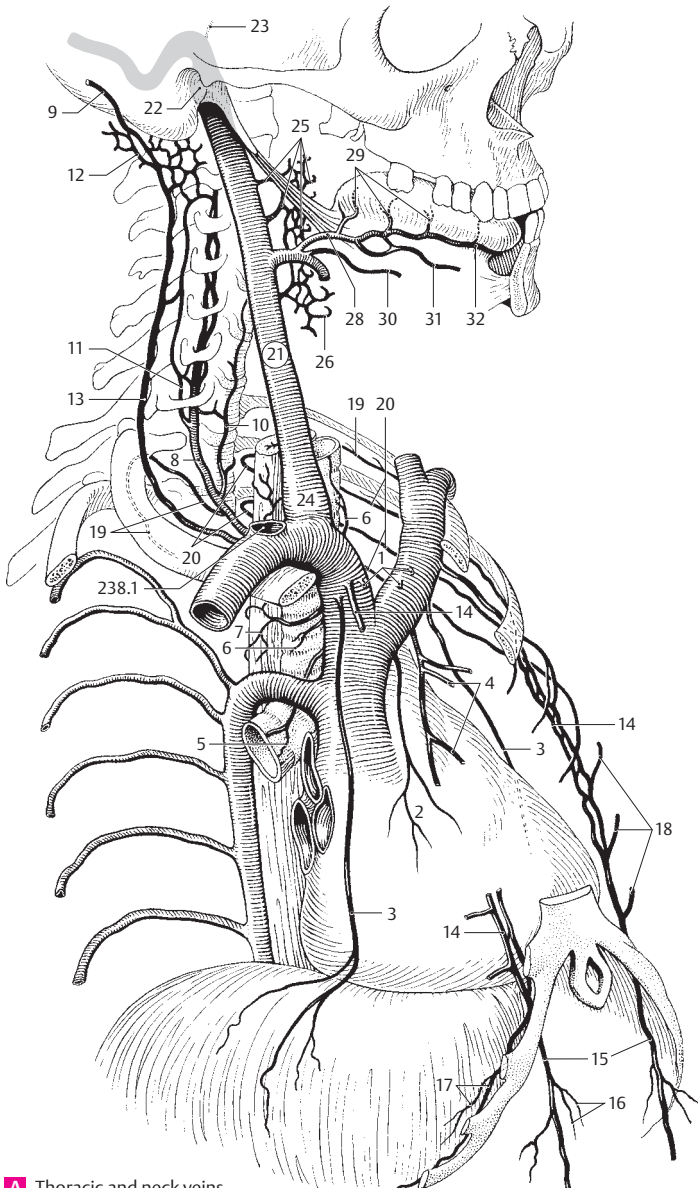
12

A Left pulmonary veins

C Right and left brachiocephalic veins

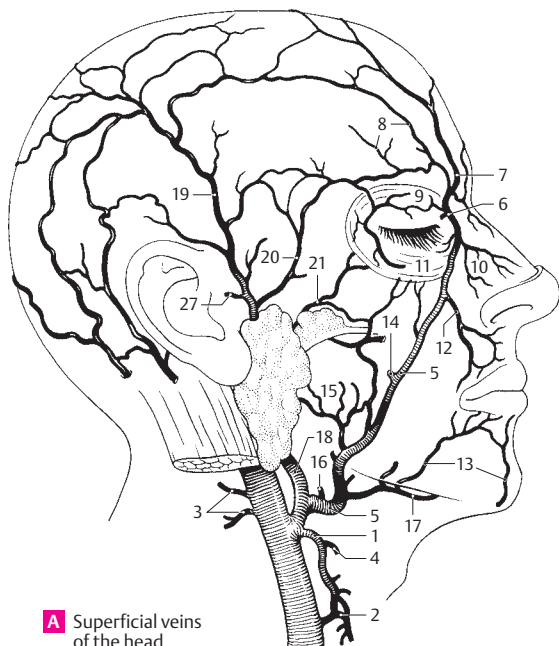B Cardiac veins

- 1 **Thymic veins.** Vv. thymicae. Small branches from the thymus. A
- 2 **Pericardiac veins.** Vv. pericardiacaе. Small branches from the pericardium. A
- 3 **Pericardiocophrenic veins.** Vv. pericardiocophrenicae. Veins accompanying the pericardiocophrenic arteries from the surface of the diaphragm and from the pericardium. A
- 4 **Mediastinal veins.** Vv. mediastinales. Small branches from the mediastinum. A
- 5 **Bronchial veins.** Vv. bronchiales. Small branches from the bronchi. A
- 6 **Tracheal veins.** Vv. tracheales. Small branches from the trachea. A
- 7 **Esophageal veins.** Vv. oesophageales. Small branches from the esophagus. A
- 8 **Vertebral vein.** V. vertebralis. Companion vein of vertebral artery; usually arises as a venous plexus. A
- 9 **Occipital vein.** V. occipitalis. Arises in the venous network of the scalp. It frequently opens into the vertebral vein, but also into the internal or external jugular veins. A
- 10 **Anterior vertebral vein.** V. vertebralis anterior. Companion vein of ascending cervical artery. It opens inferiorly into the vertebral vein. A
- 11 **Accessory vertebral vein.** [V. vertebralis accessoria]. A continuation of the venous plexus of the vertebral artery that often emerges from the foramen transversarium of C7. A
- 12 **Suboccipital venous plexus.** Plexus venosus suboccipitalis. Venous plexus between the occipital bone and atlas. A
- 13 **Deep cervical vein.** V. cervicalis profunda. Accompanies the deep cervical artery beneath the semispinalis capitis and cervicis muscles. A
- 14 **Internal thoracic veins.** Vv. thoracicae internae. Accompany the internal thoracic artery, often in twos up to the third costal cartilage, then singly from that point and medial to the artery. A
- 15 **Superior epigastric veins.** Vv. epigastricae superiores. Accompanies the superior epigastric artery. It empties parasternally into the internal thoracic veins behind the costal cartilages. A
- 16 **Subcutaneous abdominal veins.** Vv. subcutaneae abdominis. Cutaneous veins which empty into the superior epigastric veins. A
- 17 **Musculophrenic veins.** Vv. musculophrenicae. Accompany the musculophrenic arteries. A
- 18 **Anterior intercostal veins.** Vv. intercostales anteriores. Branches in the intercostal spaces. A
- 19 **Supreme intercostal vein.** V. intercostalis suprema. Carries blood from the first intercostal space to the brachiocephalic or vertebral vein. A
- 20 **Left superior intercostal vein.** V. intercostalis superior sinistra. Drains intercostal spaces 2–3(4) on the left side. It opens posteriorly into the left brachiocephalic vein. A
- 21 **INTERNAL JUGULAR VEIN.** V. jugularis interna. Main vein of the neck extending from the jugular foramen to the venous angle. A
- 22 **Superior bulb of jugular vein.** Bulbus superior venae jugularis. Dilatation of the internal jugular vein at its origin in the jugular foramen. A
- 23 **Vein of cochlear aqueduct.** V. aquaeductus cochleae. Minute accompanying vein of the perilymphatic duct. A
- 24 **Inferior bulb of jugular vein.** Bulbus inferior venae jugularis. Dilatation at the end of the internal jugular vein. It is closed cranially by a valve. A
- 25 **Pharyngeal plexus.** Plexus pharyngeus (pharyngealis). Venous plexus on the pharyngeal muscles. A
- 26 **Pharyngeal veins.** Vv. pharyngeales. Veins from the pharyngeal plexus. A
- 27 **Meningeal veins.** Vv. meningeae. Small venous branches from the dura.
- 28 **Lingual vein.** V. lingualis. It generally follows the lingual artery. A
- 29 **Dorsal lingual veins.** Vv. dorsales linguae. Numerous veins from the dorsum of the tongue. A
- 30 **Companion vein of hypoglossal nerve.** V. comitans n. hypoglossi. A
- 31 **Sublingual vein.** V. sublingualis. Larger vein situated lateral to the hypoglossal nerve. A
- 32 **Deep lingual vein.** V. profunda linguae. Accompanying vein of the deep lingual artery lateral to the genioglossus. A



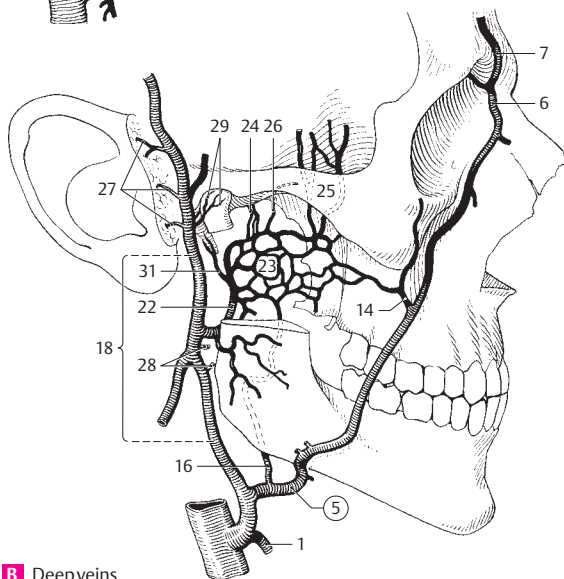
A Thoracic and neck veins

- 1 **Superior thyroid vein.** V. thyroidea superior. Accompanying vein of the superior thyroid artery. It drains into the facial or internal jugular vein. A B
- 2 **Middle thyroid veins.** Vv. thyroideae mediae. One or more thyroid veins emptying into the internal jugular vein without corresponding arteries. A
- 3 **Sternocleidomastoid vein.** V. sternocleidomastoidea. It passes from the sternocleidomastoid muscle into the internal jugular or superior thyroid vein. A
- 4 **Superior laryngeal vein.** V. laryngea superior. Accompanying vein of superior laryngeal artery that drains into the superior thyroid vein. A
- 5 **Facial vein.** V. facialis. It courses from the medial angle of the eye, behind the facial artery, the region beneath the submandibular gland. A B
- 6 **Angular vein.** V. angularis. Formed by the union of the supratrochlear and supraorbital veins; it becomes continuous with the facial vein at the medial angle of the eye and anastomoses with the ophthalmic vein. Unites via the nasofrontal vein with the superior ophthalmic vein, which is likewise devoid of valves. A B
- 7 **Supratrochlear veins.** Vv. supratrochleares [[v. frontalis]]. Begins at the coronal suture, drains the medial half of the forehead and joins the angular vein. A B
- 8 **Supra-orbital vein.** V. supraorbitalis. Emerges from the lateral part of the forehead and joins the supratrochlear veins. A
- 9 **Superior palpebral veins.** Vv. palpebrales superiores. Drain the upper eyelid. A
- 10 **External nasal veins.** Vv. nasales externae. Emerge from the external parts of the nose. A
- 11 **Inferior palpebral veins.** Vv. palpebrales inferiores. They drain the lower eyelid. A
- 12 **Superior labial vein.** V. labialis superior. Vein of upper lip. A
- 13 **Inferior labial veins.** Vv. labiales inferiores. Usually multiple veins from the lower lip. A
- 14 **Deep facial vein.** V. profunda faciei (facialis). Arises from the pterygoid plexus and passes anteriorly on the maxilla. A B
- 15 **Parotid branches.** Rami parotidei. A
- 16 **External palatine vein.** V. palatina externa. Carries blood to the facial vein from the lateral tonsillar region or the palate and the pharyngeal wall. A B
- 17 **Submental vein.** V. submentalis. Accompanying vein of submental artery. It anastomoses with the sublingual and anterior jugular veins. A
- 18 **Retromandibular vein.** V. retromandibularis. It drains into the facial vein after receiving the confluence of many branches in front of the ear. A B
- 19 **Superficial temporal veins.** Vv. temporales superficiales. They accompany the superficial temporal artery. A
- 20 **Middle temporal vein.** V. temporalis media. Arises from the temporalis muscle and opens into the superficial temporal veins. A
- 21 **Transverse facial vein.** V. transversa faciei (facialis). Accompanying vein of the transverse facial artery caudal to the zygomatic arch. A
- 22 **Maxillary veins.** Vv. maxillares. They unite the pterygoid plexus with the retromandibular vein. B
- 23 **Pterygoid plexus.** Plexus pterygoideus. Venous plexus between the temporalis and pterygoid (medial and lateral) muscles, predominantly around the lateral pterygoid muscle with the tributaries listed below. B
- 24 **Middle meningeal veins.** Vv. meningae mediae. Accompany the middle meningeal artery. B
- 25 **Deep temporal veins.** Vv. temporales profundae. Accompany the deep temporal artery. B
- 26 **Vein of pterygoid canal.** V. canalis pterygoidei. Accompanies the artery of the pterygoid canal. B
- 27 **Anterior auricular veins.** Vv. auriculares anteriores. Veins from the external acoustic meatus and pinna. A B
- 28 **Parotid veins.** Vv. parotidaeae. B
- 29 **Articular veins.** Vv. articulares. Branches from the temporomandibular joint. B
- 30 **Tympanic veins.** Vv. tympanicae. Branches from the tympanic cavity.
- 31 **Stylomastoid vein.** V. stylomastoidea. Accompanies the facial nerve as it emerges from the tympanic cavity. B



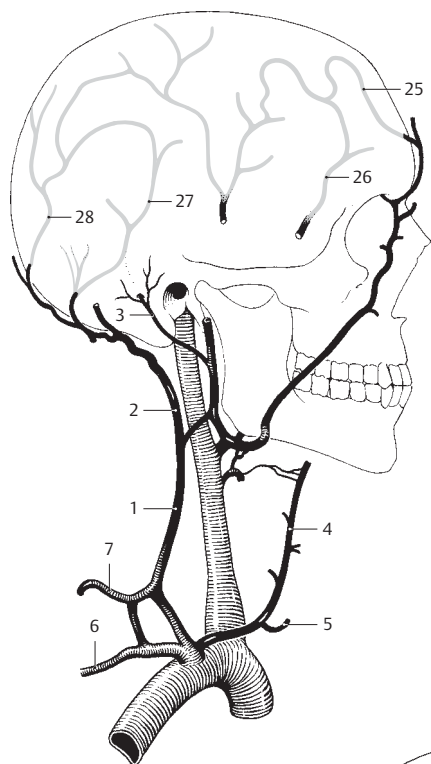
A Superficial veins of the head

12

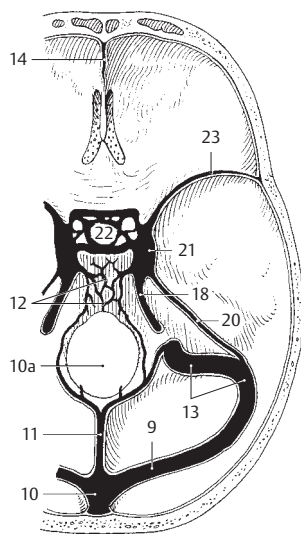


B Deep veins of the head

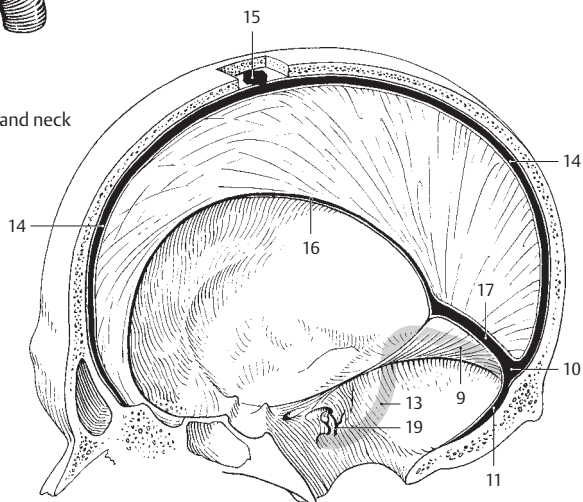
- 1 **External jugular vein.** V. jugularis externa. Arises from the union of the occipital and posterior auricular veins and courses between the platysma and superficial layer of the cervical fascia before emptying usually into the subclavian vein. A
- 2 **Occipital vein.** [[V. occipitalis]]. Accompanying vein of the occipital artery. A
- 3 **Posterior auricular vein.** V. auricularis posterior. Superficial vein located behind the ear. A
- 4 **Anterior jugular vein.** V. jugularis anterior. Begins at the level of the hyoid bone, crosses beneath the sternocleidomastoid and often opens into the external jugular vein. A
- 5 **Jugular venous arch.** Arcus venosus jugularis. Union of right and left anterior jugular veins in the suprasternal space. A
- 6 **Suprascapular vein.** V. suprascapularis. Generally two veins accompanying the subcapsular artery. A
- 7 **Transverse cervical veins.** Vv. transversae cervicis. Accompany the transverse cervical artery. A
- 8 **Dural sinuses.** Sinus durae matris. Incompressible venous conduits within the dura. They receive blood from the brain and meninges and drain into the internal jugular vein. B C
- 9 **Transverse sinus.** Sinus transversus. Dural sinus beginning at the confluence of the sinuses and continuous laterally with the sigmoid sinus. B C
- 10 **Confluence of sinuses.** Confluens sinum. Site of union of superior sagittal, straight, occipital and transverse sinuses at the internal occipital protuberance. B C
- 10a **Marginal sinus.** Sinus marginalis. Located at the entrance of the foramen magnum; it unites the venous plexus of the interior of the skull with that of the vertebral canal. B
- 11 **Occipital sinus.** Sinus occipitalis. Dural sinus beginning with a venous plexus at the foramen magnum and passing within the root of the falx cerebelli to the confluence of the sinuses. B C
- 12 **Basilar plexus.** Plexus basilaris. Venous plexus on the clivus with connections to the cavernous and petrosal sinuses as well as to the venous plexuses of the vertebral canal. B
- 13 **Sigmoid sinus.** Sinus sigmoideus. It is continuous with the transverse sinus anteriorly and takes an S-shaped turn medially to enter the jugular foramen. B C
- 14 **Superior sagittal sinus.** Sinus sagittalis superior. It lies within the root of the falx cerebri and extends from the crista galli to the confluence of the sinuses. B C
- 15 **Lateral lacunae.** Lacunae laterales. Small pits on either side of the superior sagittal sinus. C
- 16 **Inferior sagittal sinus.** Sinus sagittalis inferior. Small dural sinus at the free margin of the falx cerebri. It terminates in the straight sinus. C
- 17 **Straight sinus.** Sinus rectus. It begins at the confluence of the great cerebral vein and the inferior sagittal sinus and passes to the confluence of the sinuses via the root of the falx cerebri at its junction with the tentorium cerebelli. C
- 18 **Inferior petrosal sinus.** Sinus petrosus inferior. It runs from the cavernous sinus to the jugular foramen along the posterior, lower margin of the petrous part of the temporal bone. B
- 19 **Labyrinthine veins.** Vv. labyrinthales. Branches emanating from the internal acoustic meatus and entering the inferior petrosal sinus. C; cf. p. 374.15
- 20 **Superior petrosal sinus.** Sinus petrosus superior. It passes from the cavernous sinus to the sigmoid sinus along the upper margin of the petrous temporal. B
- 21 **Cavernous sinus.** Sinus cavernosum. Spongy venous space on both sides of the sella turcica into which the ophthalmic veins and others open. Within it lies the carotid artery and cranial nerve VI, its lateral walls housing cranial nerves III, IV and the ophthalmic and maxillary divisions of V. B
- 22 **Intercavernous sinus.** Sinus intercavernosi. Connections between the right and left cavernous sinus in front of and behind the hypophysis. B
- 23 **Sphenoparietal sinus.** Sinus sphenoparietalis. Blood channel passing beneath the lesser wing of the sphenoid to enter the cavernous sinus. B
- 24 **Diploic veins.** Vv. diploicae. Veins situated in the diploë of the calvaria. They drain the blood from the dura and roof of the skull and communicate with the dural sinuses as well as the superficial cranial veins.
- 25 **Frontal diploic vein.** V. diploica frontalis. Diploic vein running near the midline and opening into the supraorbital vein and the superior sagittal sinus. A
- 26 **Anterior temporal diploic vein.** V. diploica temporalis anterior. Anteriorly situated diploic vein opening into the deep temporal vein and the sphenoparietal sinus. A
- 27 **Posterior temporal diploic vein.** V. diploica temporalis posterior. Posteriorly situated diploic vein opening into the posterior auricular vein and the transverse sinus. A
- 28 **Occipital diploic vein.** V. diploica occipitalis. Most posterior diploic vein opening into the occipital vein and the transverse sinus. A



A Veins of the head and neck

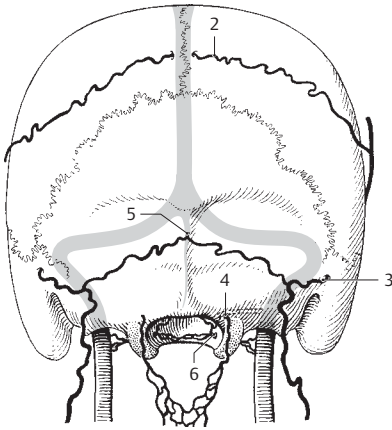


B Sinuses on the inner skull base

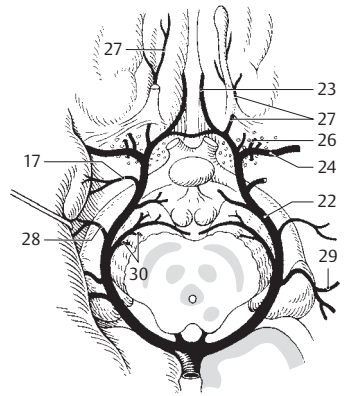


C Sinuses of right half of skull

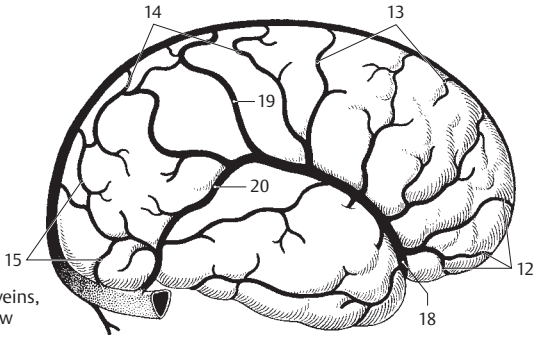
- 1 **Emissary veins.** Vv. emissariae. Venous connections between a venous sinus, diploic veins and superficial cranial veins.
- 2 **Parietal emissary vein.** V. emissaria parietalis. It connects the superior sagittal sinus with a superficial temporal vein via the parietal foramen. A
- 3 **Mastoid emissary vein.** V. emissaria mastoidea. It connects the sigmoid sinus with the occipital vein via the mastoid foramen. A
- 4 **Condylar emissary vein.** V. emissaria condylaris. It connects the sigmoid sinus with the external vertebral venous plexus via the condylar canal. A
- 5 **Occipital emissary vein.** V. emissaria occipitalis. Connection between the confluence of the sinuses and the occipital vein. A
- 6 **Venous plexus of hypoglossal canal.** Plexus venosus canalis hypoglossi. Located in the hypoglossal canal, between the foramen magnum and the internal jugular vein. A
- 7 **Venous plexus of foramen ovale.** Plexus venosus foraminis ovalis. It lies in the foramen ovale between the cavernous sinus and the pterygoid plexus. D
- 8 **Venous plexus of internal carotid.** Plexus venosus caroticus internus. It occupies the carotid canal between the cavernous sinus and the pterygoid plexus. D
- 8a **Hypophysial portal veins.** Vv. portales hypophysialis. Veins transporting blood from the arterial capillary network of the infundibulum and the adenophypophysis to the cavernous sinus. E
- 9 **CEREBRAL VEINS.** Vv. cerebri. Valveless veins situated primarily in the subarachnoid space; they carry blood primarily into the dural sinuses.
- 10 **Superficial cerebral veins.** Vv. superficiales cerebri.
- 11 **Superior cerebral veins.** Vv. superiores cerebri. Arise from the lateral, medial and anterior aspects of the inferior surface of the brain and drain into the superior sagittal sinus.
- 12 **Prefrontal veins.** Vv. praefrontales. They arise from the frontal pole and its basal surface. B
- 13 **Frontal veins.** Vv. frontales. Veins from the upper third of the frontal lobe extending up to the central sulcus. B
- 14 **Parietal veins.** Vv. parietales. Sinus veins from the parietal lobe. B
- 15 **Occipital veins.** Vv. occipitales. Sinus veins from the occipital lobe. B
- 16 **Inferior cerebral veins.** Vv. inferiores cerebri. Veins located at the base of the brain with openings into the cavernous, petrosal and transverse sinuses.
- 17 **Vein of the uncus.** V. unci. C
- 18 **Superficial middle cerebral vein.** V. media superficialis cerebri. Coming from the lower two-thirds of the hemisphere, it passes to the cavernous sinus via the lateral sulcus of the cerebrum. B
- 19 **Superior anastomotic vein.** V. anastomotica superior [[Trolard]]. Thick vein that occasionally anastomoses with the superior sagittal sinus. B
- 20 **Inferior anastomotic vein.** V. anastomotica inferior [[Labbe]]. Thick vein that occasionally anastomoses with the transverse sinus. B
- 21 **Deep cerebral veins.** Vv. profundae cerebri. Cerebral veins that are usually concealed.
- 22 **Basal vein.** V. basalis [[Rosenthal]]. It begins at the anterior perforated substance, then courses along the optic tract and passes around the brainstem dorsally to join the great cerebral vein. C
- 23 **Anterior cerebral veins.** Vv. anteriores cerebri. Companion veins of the anterior cerebral artery. C
- 24 **Deep middle cerebral vein.** V. media profunda cerebri. It begins at the insula and opens into the basal vein. C
- 25 **Insular veins.** Vv. insulares. Origin of the deep middle cerebral vein.
- 26 **Inferior thalamostriate veins.** Vv. thalamostriatae inferiores. Arise from the caudate and lentiform nuclei and the thalamus, penetrate the anterior perforated substance and open into the basal or deep middle cerebral vein. C
- 27 **Vein of olfactory gyrus.** V. gyri olfactorii. It comes from the region proximal to and in front of the olfactory trigone. C
- 28 **Inferior ventricular vein.** V. ventricularis inferior. Arises from the white matter of the temporal lobe and passes through the choroid fissure at the level of the crus cerebri. C
- 29 **Inferior choroid vein.** V. choroidea inferior. It transports blood from the hippocampus, dentate gyrus and choroid plexus into the basal vein. V
- 30 **Peduncular veins.** Vv. pedunculares. Veins from the cerebral peduncle. C



A Veins of the occipital region

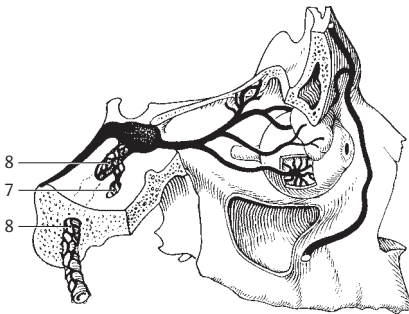


C Veins on base of brain

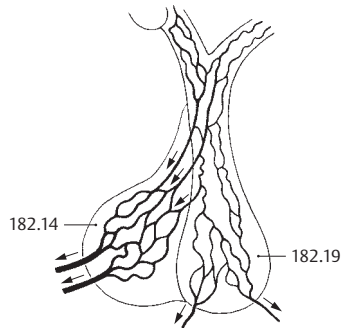


B Cerebral veins, lateral view

12

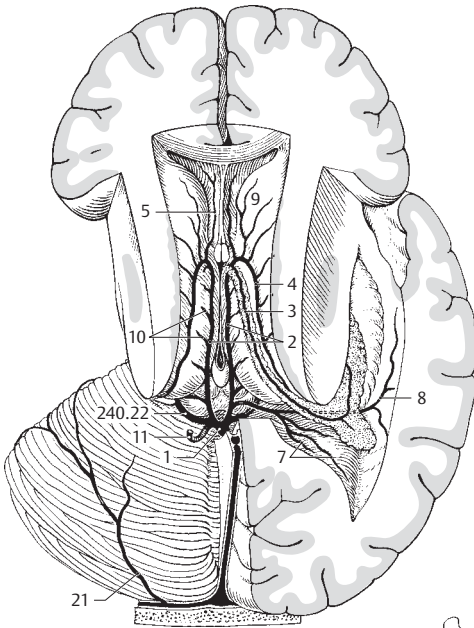


D Veins of orbit and middle cranial fossa

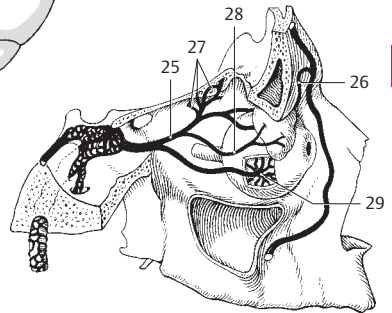


E Portal vessel of the hypophysis

- 1 **Great cerebral vein** [**vein of Galen**]. V. magna cerebri [[Galenii]]. Short vein between the union of both internal cerebral veins and the beginning of the straight sinus. A C
- 2 **Internal cerebral veins** [**right and left**]]. Vv. internae cerebri. Each runs in the transverse fissure, thus between the fornix and thalamus or the roof of the third ventricle. Both begin at the interventricular foramen and end at the site where both unite to form the great cerebral vein. A C
- 3 **Superior choroid vein**. V. choroidea superior. It extends the entire length of the choroid plexus up to the interventricular foramen and receives branches from the hippocampus, fornix and corpus callosum. A
- 4 **Superior thalamostriate vein**. V. thalamostriata superior (v. terminalis). It runs in the angle between the thalamus and caudate nucleus. It has no branches from the thalamus itself, but some from its vicinity. It ends by opening into the superior choroid vein in the interventricular foramen. A
- 5 **Anterior vein of septum pellucidum**. V. anterior septi pellucidi. From its drainage area, the medulla of the frontal lobe and the genu of the corpus callosum, it passes in the septum pellucidum to join the thalamostriate vein. A C
- 6 **Posterior vein of septum pellucidum**. V. posterior septi pellucidi. It arises from the roof of the lateral ventricle and often opens into the internal cerebral vein. C
- 7 **Medial atrial vein of lateral ventricle**. V. medialis atrii ventriculi lateralis. Arises from the medulla of the parietal and occipital lobes and passes in the medial wall of the lateral ventricle in front of the junction of the posterior horn. A
- 8 **Lateral atrial vein of lateral ventricle**. V. lateralis atrii ventriculi lateralis. Arises from the medulla of the parietal and occipital lobes and courses in the lateral wall of the lateral ventricle in front of the exit of the posterior horn. A
- 9 **Veins of caudate nucleus**. Vv. nuclei caudati. A
- 10 **Lateral direct veins**. Vv. directae laterales. Branches from the wall of the lateral ventricle opening directly into the internal cerebral vein. A
- 11 **Posterior vein of corpus callosum**. V. posterior corporis callosi. Branch coming from the end of the corpus callosum from below. A C
- 12 **Dorsal vein of corpus callosum**. V. dorsalis corporis callosi. Dorsal branch passing around the splenium. C
- 13 **Veins of brain stem**. Vv. trunci encephali.
- 14 **Anterior pontomesencephalic vein**. V. pontomesencephalica anterior. A continuation of the vein of the medulla oblongata that extends as far as the interpeduncular fossa, often draining into the petrosal vein, and sometimes into the basal vein. C
- 15 **Pontine veins**. Vv. pontis. Numerous branches from the pons which drain into the petrosal or pontomesencephalic veins, with an anastomosis between them. C
- 16 **Veins of medulla oblongata**. Vv. medullae oblongatae. Lower continuation of the pontomesencephalic vein with its branches from the medulla oblongata. C
- 17 **Vein of lateral recess of fourth ventricle**. V. recessus lateralis ventriculi quarti. Arises from the lateral recess and opens into the inferior petrosal sinus. C
- 18 **Cerebellar veins**. Vv. cerebelli.
- 19 **Superior vein of vermis**. V. superior vermis. Arises from the superior portion of the vermis and empties into the great or internal cerebral vein. C
- 20 **Inferior vein of vermis**. V. inferior vermis. Arises from the lower half of the vermis and opens into the straight sinus. C
- 21 **Superior veins of cerebellum**. Vv. superiores cerebelli. Arise mostly from the lateral hemispheres and usually open into the transverse sinus. A
- 22 **Inferior veins of cerebellum**. Vv. inferiores cerebelli. They usually arise from the inferior, lateral hemispheres and empty into the adjacent sinuses. C
- 23 **Precentral cerebellar vein**. V. praecentralis cerebelli. It originates between the lingula and central lobule and drains into the great cerebral vein. C
- 24 **Petrosal vein**. V. petrosa. It arises in the region of the flocculus, can be quite large and empties into the inferior or superior petrosal sinus. C
- 24a **ORBITAL VEINS**. Vv. orbitae.
- 25 **Superior ophthalmic vein**. V. ophthalmica superior. Begins medially above the eyeball with the nasofrontal vein and passes through the superior orbital fissure to the cavernous sinus. B
- 26 **Nasofrontal vein**. V. nasofrontalis. Connects superior ophthalmic vein and the union of the supratrochlear with the angular vein. B
- 27 **Ethmoidal veins**. Vv. ethmoidales. B
- 28 **Lacrimal vein**. V. lacrimalis. B
- 29 **Vorticosae veins (choroidal veins of eye)**. Vv. vorticosae (vv. choroideae oculi). Four or five branches from the choroid tunic of the eye. They penetrate the sclera laterally. B

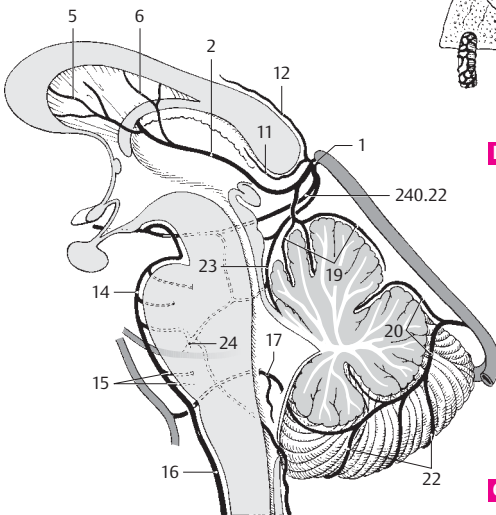


A Veins of brain from above



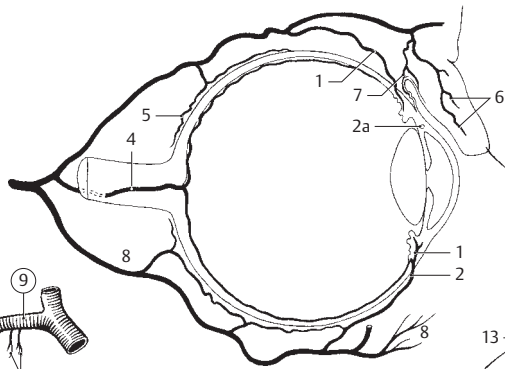
12

B Veins of orbit

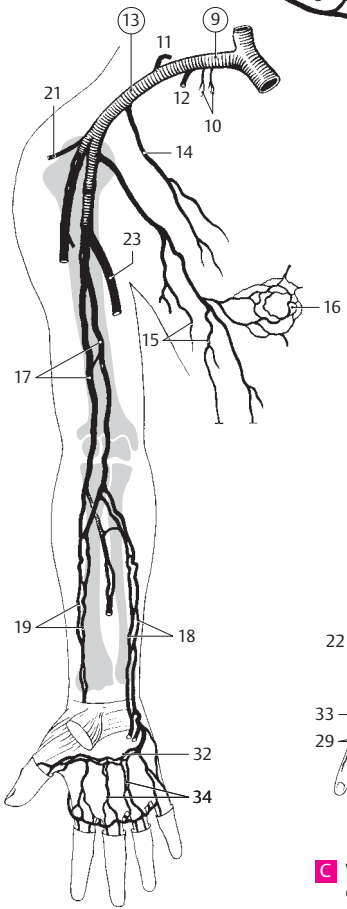


C Veins of brain sagittal section

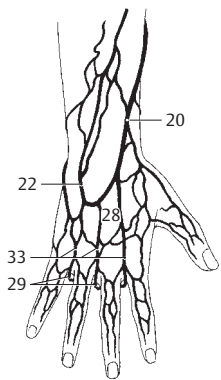
- 1 **Ciliary veins.** Vv. ciliares. Veins from the ciliary body which drain either into the veins of the ocular muscles or into the choroidal veins. A
- 2 **Anterior ciliary veins.** Vv. ciliares anteriores. Companion veins of the corresponding arteries. They transport blood from the ciliary body to the veins of the ocular muscles at their attachments. A
- 2a [*Sinus venosus sclerae*]. See p. 354.30
- 3 **Scleral veins.** Vv. sclerales. Thin veins coursing mainly in the anterior sclera.
- 4 **Central vein of retina.** V. centralis retinae. Companion vein of central artery of retina. It drains either into the superior ophthalmic vein or directly into the cavernous sinus. A
- 5 **Episcleral veins.** Vv. episclerales. Branches located on the sclera and opening into the superior ophthalmic veins. A
- 6 **Palpebral veins.** Vv. palpebrales. Branches coming from the upper eyelids. A
- 7 **Conjunctival veins.** Vv. conjunctivales. A
- 8 **Inferior ophthalmic vein.** V. ophthalmica inferior. Arises from the lower eyelid and the lacrimal gland, then unites with the superior ophthalmic vein or passes directly into the cavernous sinus and the pterygoid plexus. A
- 8a **VEINS OF UPPER LIMBS.** Venae membri superioris.
- 9 **Subclavian vein.** V. subclavia. It lies between the scalenus anterior and sternocleidomastoid muscles and extends from the internal jugular vein to the lateral margin of the first rib. B
- 10 **Pectoral veins.** Vv. pectorales. Veins passing from the area of the pectoral muscles directly into the subclavian vein. B
- 11 **Dorsal scapular vein.** V. scapularis dorsalis. Accompanying vein of the dorsal scapular artery. It frequently opens into the external jugular vein. B
- 12 **Thoracoacromial vein.** [V. thoracoacromialis]. Companion vein of the thoracoacromial artery that occasionally opens into the subclavian vein. B
- 13 **Axillary vein.** V. axillaris. Continuation of the subclavian vein extending from the lateral margin of the first rib to the lower margin of the tendon of the teres major. B D
- 13a **Subscapular, circumflex scapular, thoracodorsal, posterior circumflex scapular, anterior circumflex scapular veins.** Vv. subscapularis, circumflexa scapulae, thoracodorsalis, circumflexa posterior humeralis, circumflexa anterior humeralis. Newly named companion veins of the corresponding arteries.
- 14 **Lateral thoracic vein.** V. thoracica lateralis. Companion vein of lateral thoracic artery located on the serratus anterior muscle. B
- 15 **Thoracoepigastric veins.** Vv. thoracoepigastricae. Subcutaneous veins from the wall of the lateral trunk. They are collaterals that connect the superior and inferior venae cavae. B
- 16 **Areolar venous plexus.** Plexus venosus areolaris. Venous plexus around the nipple (areola). B
- 16a **Superficial veins of upper limbs.** Venae superficiales membri superioris.
- 16b **Deep veins of upper limbs.** Venae profundae membri superioris.
- 17 **Brachial veins.** Vv. brachiales. Companion veins of the brachial artery. B
- 18 **Ulnar veins.** Vv. ulnares. Companion veins of the ulnar artery. B
- 19 **Radial veins.** Vv. radiales. Companion veins of the radial artery. B
- 19a **Anterior interosseous veins.** Vv. interosaeae anteriores. Two companion veins, one for each anterior interosseous artery.
- 19b **Posterior interosseous veins.** Vv. interosaeae posteriores. Two companion veins, one for each posterior interosseous artery.
- 20 **Cephalic vein.** V. cephalica. Epifascial vein beginning at the root of the thumb. It runs in the lateral bicipital groove and passes between the deltoid and pectoralis major muscles [[deltoideopectoral trigone]] to enter the axillary vein. C D
- 21 **Thoracoacromial vein.** V. thoracoacromialis. Accompanying vein of the thoracoacromial artery. It drains into the axillary vein. B D
- 22 **Accessory cephalic vein.** [V. cephalica accessoria]. It runs from the extensor side of the forearm to the cephalic vein.
- 23 **Basilic vein.** V. basilica. Epifascial vein beginning above the distal ulna. It penetrates the brachial fascia in the middle of the medial bicipital groove and opens into the brachial vein. B D
- 24 **Median cubital vein.** V. mediana cubiti. Connecting branch that arises from the cephalic vein and passes obliquely upward from inferolateral to superomedial to join the basilic vein.
- 25 **Median antebrachial vein.** V. mediana antebrachii. Epifascial vein occasionally present between the cephalic and basilic veins. D
- 26 **Median cephalic vein.** V. mediana cephalica. Branch or trunk connecting the median antebrachial vein to the cephalic vein. D
- 27 **Median basilic vein.** V. mediana basilica. Branch or trunk connecting the median antebrachial vein to the basilic vein. D
- 28 **Dorsal venous plexus of hand.** Rete venosum dorsale manus. Subcutaneous venous network on the dorsum of hand. C
- 29 **Intercapital veins.** Vv. intercapitulares. Pass between the heads of the metatarsal bones and connect the dorsal and palmar veins of the hand. C D
- 30 **Superficial palmar venous arch.** Arcus venosus palmaris superficialis. Companion vein of the arterial superficial palmar arch. D
- 31 **Palmar digital veins.** Vv. digitales palmares. Veins on the flexor side of the fingers. D
- 32 **Deep palmar venous arch.** Arcus venosus palmaris profundus. Companion veins of the arterial deep palmar arch. B D
- 33 **Dorsal metacarpal veins.** Vv. metacarpales dorsales. Three veins coming from the four ulnar fingers; they open into the dorsal venous plexus of the hand. C
- 34 **Palmar metacarpal veins.** Vv. metacarpales palmares. Companion veins of the metacarpal arteries; they open into the deep palmar venous arch. B D



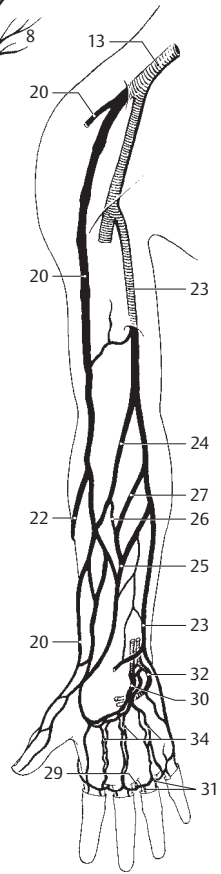
A Veins of eye



B Deep veins of arm, anterior view



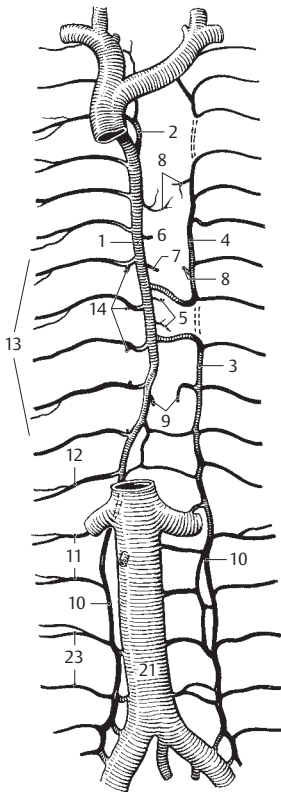
C Veins on dorsum of hand



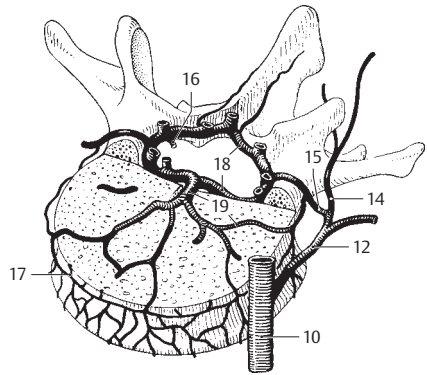
D Superficial veins of arm

12

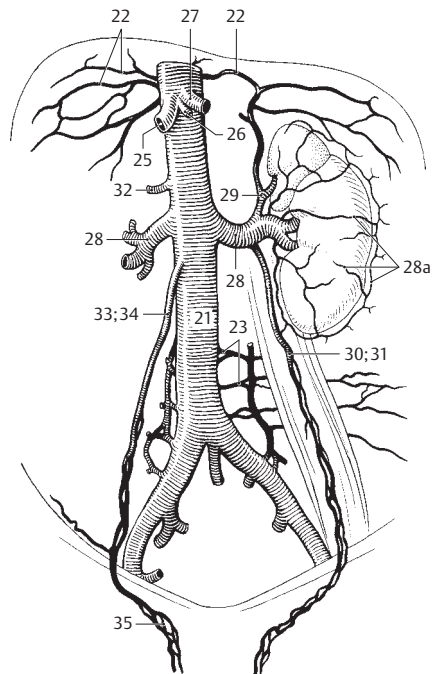
- 1 **AZYGOS VEIN.** Vena azygos. Lumbar vein that arises from the ascending lumbar vein and opens into the superior vena cava at the level of T4–5 shortly before its entrance into the pericardium. A
- 1a **Arch of azygos vein.** Arcus venae azygos. Venous arch before the site where the azygos vein enters the superior vena cava.
- 2 **Right superior intercostal vein.** V. intercostalis superior dextra. Formed by the union of 2nd and 3rd (4th) right superior intercostal veins. It opens into the azygos vein. A
- 3 **Hemiazygos vein.** V. hemiazygos. Frequently arises from the left ascending lumbar vein. It receives intercostal veins 9–11 and drains into the azygos vein usually at the level of T9–10. A
- 4 **Accessory hemiazygos vein.** V. hemiazygos accessoria. After receiving intercostal veins 4–8, it opens into the azygos vein either alone or together with the hemiazygos vein. However, it can also take up the first three intercostal veins and then anastomose with the left brachiocephalic vein. A
- 5 **Esophageal veins.** Vv. oesophageales. Veins from the esophagus draining into the azygos vein. A
- 6 **Bronchial veins.** Vv. bronchiales. Branches from the bronchi emptying into the azygos or hemiazygos veins. A
- 7 **Pericardial veins.** Vv. pericardiales. Branches from the pericardium that join the azygos vein, superior vena cava or brachiocephalic vein. A
- 8 **Mediastinal veins.** Vv. mediastinales. Small branches from the mediastinum draining partially into the superior vena cava. A
- 9 **Superior phrenic veins.** Vv. phrenicae superiores. Small veins from the surface of the diaphragm. A
- 10 **Ascending lumbar vein.** V. lumbalis ascendens. Abdominal segments of the azygos on the right and the hemiazygos on the left. Collateral vein to the inferior vena cava via the common iliac vein. A B
- 11 **Lumbar veins.** Vv. lumbales. Segmental veins 1 and 2 opening into the ascending lumbar vein. A
- 12 **Subcostal vein.** V. subcostalis. Venous segment located below the 12th rib. From this tributary onward, the right and left longitudinal venous conduits are designated as the azygos and the hemiazygos veins, respectively. A B
- 13 **Posterior intercostal veins.** Vv. intercostales posteriores. Those from 4 to 11 drain into either the azygos vein or hemiazygos vein. A
- 14 **Dorsal branch.** Ramus dorsalis. Branch from the muscles and skin of the back. A B
- 15 **Intervertebral vein.** V. intervertebralis. Branch from the intervertebral foramen. B
- 16 **Spinal branch.** Ramus spinalis. Branch from the spinal cord and its meninges. B
- 16a **Veins of the vertebral column.** Venae columnae vertebrales.
- 17 **Anterior/posterior external vertebral venous plexus.** Plexus venosus vertebralis externus anterior/posterior. Venous plexus in front of the vertebral body and behind the vertebral arch. B
- 18 **Anterior/posterior internal vertebral venous plexus.** Plexus venosus vertebralis internus anterior/posterior. Venous plexus on the anterior and posterior walls of the vertebral canal between the dura and periosteum or ligaments. B
- 19 **Basivertebral veins.** Vv. basivertebrales. Veins lying in the vertebral bodies and converging posteriorly to drain into the anterior internal vertebral venous plexus. B
- 20 **Spinal cord veins.** Vv. medullae spinalis. Venous plexus in the subarachnoid space for drainage of the spinal cord.
- 20a **Anterior spinal veins.** Vv. spinales anteriores. Unite cranially with the network of the pons and continue caudally as the terminal vein.
- 20b **Posterior spinal veins.** Vv. spinales posteriores. They terminate cranially at the rhomboid fossa, caudally at the conus medullaris.
- 21 **INFERIOR VENA CAVA.** Vena cava inferior. Beginning at the union of the right and left common iliac veins, it lies to the right of the aorta and opens into the right atrium of the heart. A C
- 22 **Inferior phrenic veins.** Vv. phrenicae inferiores. Companion veins of inferior phrenic artery. C
- 23 **Lumbar veins.** Vv. lumbales. Segmental lumbar veins 3 and 4 open directly into the inferior vena cava. A C
- 24 **Hepatic veins.** Vv. hepaticae. Short intrahepatic veins.
- 25 **Right hepatic veins.** Vv. hepaticae dextrae. Veins from right lobe of liver. C
- 26 **Intermediate hepatic veins.** Vv. hepaticae intermediae. Veins from caudate lobe of the liver. C
- 27 **Left hepatic veins.** Vv. hepaticae sinistralae. Veins from the left lobe of the liver. C
- 28 **Renal veins.** Vv. renales. Right and left veins from kidney. C
- 28a **Capsular veins.** Vv. capsulares. Form the venous network of the fatty capsule and anastomose with neighboring and stellate veins. They can form a collateral circulation. C
- 29 **Left suprarenal vein.** V. suprarenalis (adrenalis) sinistra. Vein from the left suprarenal gland. C
- 30 **Left testicular vein.** V. testicularis sinistra. Vein from left testis. C
- 31 **Left ovarian vein.** V. ovarica sinistra. Vein from left ovary. C
- 32 **Right suprarenal vein.** V. suprarenalis (adrenalis) dextra. Vein from right suprarenal gland usually opening directly into the inferior vena cava. C
- 33 **Right testicular vein.** V. testicularis (adrenalis) dextra. It opens directly into the inferior vena cava. C
- 34 **Right ovarian vein.** V. ovarica dextra. It opens directly into the inferior vena cava. C
- 35 **Pampiniform plexus.** Plexus pampiniformis. Venous plexus around the spermatic cord. C



A Veins of posterior thoracic and abdominal walls

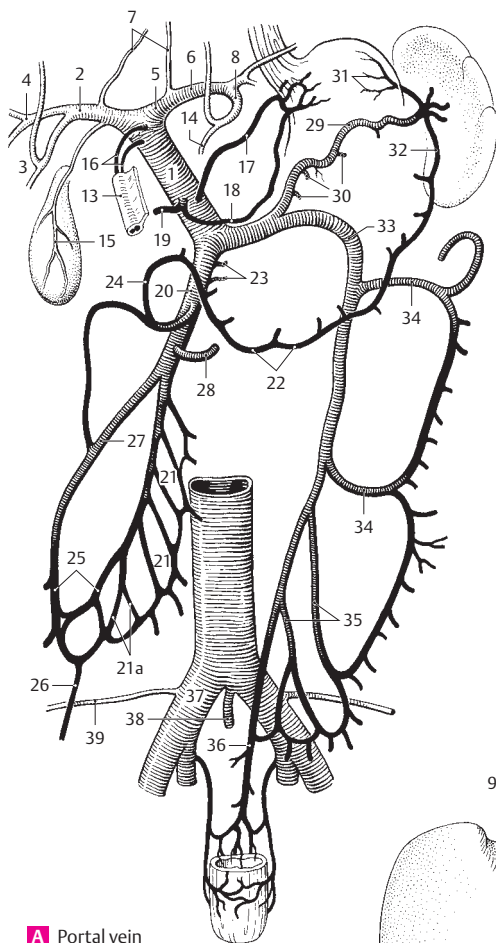


B Veins of vertebrae

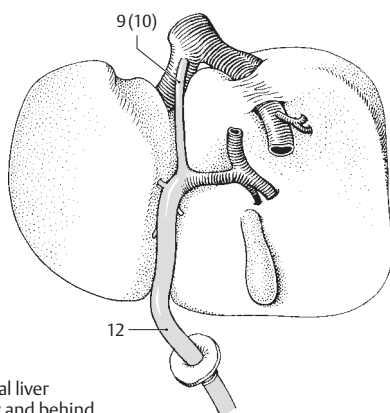


C Inferior vena cava

- 1 **PORTAL VEIN OF LIVER.** Vena portae hepatis. It brings blood from the intestinal tract to the liver. Forms important anastomoses to esophageal veins, rectal venous plexus and the superficial veins of the abdominal skin. A
- 2 **Right branch.** Ramus dexter. Strong shorter right branch of portal vein. It forms bifurcations in the right lobe of the liver that extend as far as the interlobular veins. A
- 3 **Anterior branch.** Ramus anterior. It supplies the anterior part of the right lobe. A
- 4 **Posterior branch.** Ramus posterior. It supplies the posterior part of the right lobe. A
- 5 **Left branch.** Ramus sinister. Longer and somewhat more slender branch supplying the left lobe as well as the caudate and quadrate lobes. A
- 6 **Transverse part.** Pars transversa. Initial segment of left branch coursing transversely into liver hilum. A
- 7 **Caudate branches.** Rami caudati. Twigs to caudate lobe. A
- 8 **Umbilical part.** Pars umbilicus. Sagittal continuation of the left branch into the left lobe. A
- 9 **[Ductus venosus].** Embryonic vein uniting umbilical vein and inferior vena cava. Bypasses the liver. B
- 10 **Ligamentum venosum.** Lig. venosum. Connective tissue vestige of the ductus venosus in the groove for the ligamentum venosum. B
- 11 **Lateral branches.** Rami laterales. Branches to the quadrate lobe and part of the caudate lobe.
- 12 **Left umbilical vein.** V. umbilicalis sinistra. Embryonic vein joining the portal vein in the liver. It carries cord blood to the right atrium partly via the ductus venosus and inferior vena cava. B
- 13 **Round ligament of liver.** Lig. teres hepatis. Connective tissue remains of left umbilical vein. A
- 14 **Medial branches.** Rr. mediales. Branches of the umbilical part extending to anterior portion of left lobe of liver. A
- 15 **Cystic vein.** V. cystica. Vein from gallbladder emptying into right branch of portal vein. A
- 16 **Paraumbilical veins.** Vv. paraumbilicales. Small veins around the round ligament. They form anastomoses between the left branch of the portal vein and subcutaneous abdominal veins. A
- 17 **Left gastric vein.** V. gastrica sinistra. Companion vein of left gastric artery. A
- 18 **Right gastric vein.** V. gastrica dextra. Companion vein of right gastric artery. A
- 19 **Prepyloric vein.** V. praepylorica. Branch from the anterior part of pylorus to the right gastric vein or portal vein. A
- 20 **Superior mesenteric vein.** V. mesenterica superior. Its drainage area extends from the distal half of the duodenum to the left colic flexure. It joins the splenic vein to form the portal vein. A
- 21 **Jejunal veins.** Vv. jejunales. Branches from the jejunum and ileum. A
- 21 a **Ileal branches.** Vv. ileales. A
- 22 **Right gastro-omental (gastro-epiploic) vein.** V. gastro-omentalis (epiploica) dextra. Companion vein of right gastro-omental artery. A
- 23 **Pancreatic veins.** Vv. pancreaticae. Direct branches from the pancreas. A
- 24 **Pancreaticoduodenal veins.** Vv. pancreaticoduodenales. Companion veins of pancreaticoduodenal arteries. A
- 25 **Ileocolic vein.** V. ileocolica. Branch from the ileocecal region. A
- 26 **Appendicular vein.** V. appendicularis. Vein from the vermiform appendix. A
- 27 **Right colic vein.** V. colica dextra. Vein from the ascending colon. A
- 28 **Middle colic vein.** V. colica media (intermedia). Vein of transverse colon. It can also drain into the superior and inferior mesenteric veins. A
- 29 **Splenic vein.** V. splenica. It is found in the phrenicolic ligament and behind the pancreas. It joins the superior mesenteric vein to form the portal vein. A
- 30 **Pancreatic veins.** Vv. pancreaticae. They open directly into the splenic vein. A
- 31 **Short gastric veins.** Vv. gastricae breves. They course in the gastrosplenic ligament. A
- 32 **Left gastro-omental (gastro-epiploic) vein.** V. gastro-omentalis (epiploica) sinistra. Companion vein of left gastro-omental vein. A
- 33 **Inferior mesenteric vein.** V. mesenterica inferior. Extends from the left third of the colon to the upper rectum and opens into the splenic vein. A
- 34 **Left colic vein.** V. colica sinistra. Arises from the descending colon. A
- 35 **Sigmoid veins.** Vv. sigmoideae. They drain the sigmoid colon. A
- 36 **Superior rectal vein.** V. rectalis superior. Branch from the upper rectum. A
- 37 **COMMON ILIAC VEIN.** V. iliaca communis. Venous trunk reaching from L4 to the sacroiliac joint. It unites with the contralateral vein to form the inferior vena cava. A
- 38 **Median sacral vein.** V. sacralis mediana. Unpaired branch that joins the left common iliac vein. A
- 39 **Iliolumbar vein.** V. iliolumbalis. Accompanying vein of the iliolumbar artery. It opens into the internal or common iliac vein. A



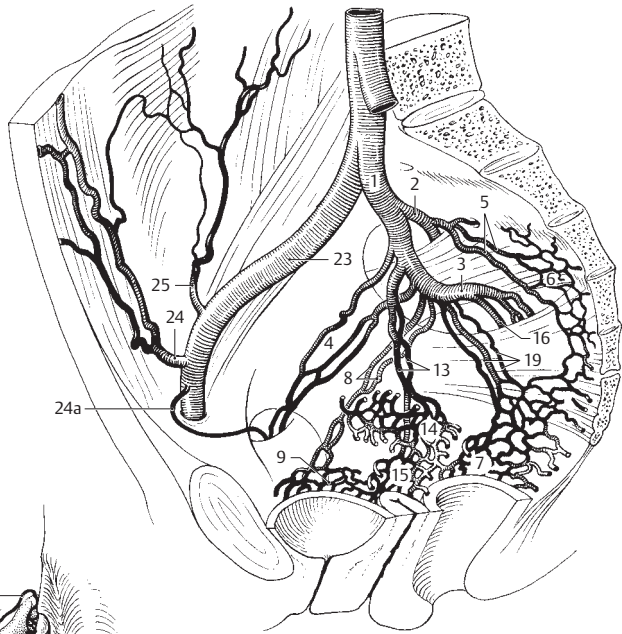
A Portal vein



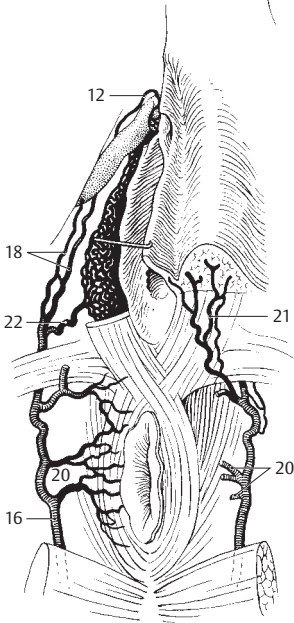
B Veins of fetal liver from below and behind

12

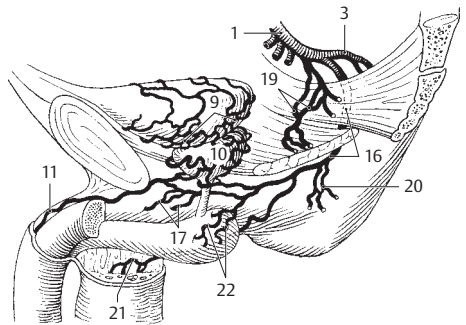
- 1 **INTERNAL ILIAC [[HYPOGASTRIC]] VEIN.** V. iliaca interna [[v. hypogastrica]]. Short trunk receiving veins from the pelvic viscera and perineum. A C
- 2 **Superior gluteal veins.** Vv. gluteales⁵ superiores. Companion veins of superior gluteal artery passing through the upper division of the greater sciatic foramen [[suprapiriform foramen]] to the pelvis. They converge to form a trunk which opens into the internal iliac vein. A
- 3 **Inferior gluteal veins.** Vv. gluteales⁵ inferiores. Companion veins of inferior gluteal artery passing through the lower division of the greater sciatic foramen [[infrapiriform foramen]] into the pelvis. They unite to form a trunk and open into the internal iliac vein. A C
- 4 **Obturator veins.** Vv. obturatoriae. They enter the pelvis via the obturator foramen and usually open into both the internal iliac and common iliac veins. A
- 5 **Lateral sacral veins.** Vv. sacrales laterales. Lateral branches from the sacral venous plexus. A
- 6 **Sacral venous plexus.** Plexus venosus sacralis. Venous network lying in front of the sacrum. A
- 7 **Rectal venous (hemorrhoidal) plexus.** Plexus venosus rectalis [[plexus haemorrhoidalis]]. Plexus surrounding the rectum. A
- 8 **Vesical veins.** Vv. vesicales. Veins from the vesical venous plexus. A
- 9 **Vesical venous plexus.** Plexus venosus vesicalis. Extends from the base of the bladder to communicate with the prostatic or vaginal venous plexus. A C
- 10 **Prostatic venous plexus.** Plexus venosus prostaticus. It surrounds the prostate and unites with the neighboring vesical venous plexus. C
- 11 **Deep dorsal vein of penis.** V. dorsalis profunda penis. Subfascial vein of the dorsum of the penis that passes below the symphysis between the arcuate ligament of the pubis and the transverse perineal ligament to enter the prostatic venous plexus. It lies between the deep fascia of the penis and the tunica albuginea and is usually not paired. C. See also p. 165 B
- 12 **Deep dorsal vein of clitoris.** V. dorsalis profunda clitoridis. Subfascial vein of dorsum of clitoris opening into vesical venous plexus. B
- 13 **Uterine veins.** Vv. uterinae. Connecting veins that join the uterine venous plexus and internal iliac vein. A
- 14 **Uterine venous plexus.** Plexus venosus uterinus. Venous network primarily at the root of the broad ligament. It communicates with the vaginal venous plexus. A
- 15 **Vaginal venous plexus.** Plexus venosus vaginalis. Venous network around the vagina with numerous connections to the surrounding venous plexus. A
- 16 **Internal pudendal vein.** V. pudenda interna. It runs in the lateral wall of the ischioanal fossa and enters the pelvis via the lower division of the greater sciatic foramen [[infrapiriform foramen]]. A B C
- 17 **Deep veins of penis.** Vv. profundae penis. They arise from the roots of the corpus cavernosum and corpus spongiosum and drain into the prostatic venous plexus via the deep dorsal vein of the penis. C
- 18 **Deep veins of clitoris.** Vv. profundae clitoridis. Equivalent to the deep veins of the penis. B
- 19 **Middle rectal veins.** Vv. rectales mediae. Branches from the rectal venous plexus located in the lesser pelvis. They anastomose with the superior rectal vein and the inferior rectal veins. A C
- 20 **Inferior rectal veins.** Vv. rectales inferiores. Arise from the anal region, join the internal pudendal vein and anastomose with the middle rectal veins and the superior rectal vein. B C
- 21 **Posterior scrotal/labial veins.** Vv. scrotales/labiales posteriores. Arise from the scrotum or labia and join the internal pudendal vein. B C
- 22 **Vein of bulb of penis/vestibule.** V. bulbi penis/ vestibuli. Arise from the bulb of the corpus spongiosum and convey blood either to the deep dorsal vein of the penis (clitoris) or into the internal pudendal vein. B C
- 23 **External iliac vein.** V. iliaca externa. Arises from the upper end of the femoral vein below the inguinal ligament and ends where it joins the internal iliac vein to form the common iliac vein. A
- 24 **Inferior epigastric vein.** V. epigastrica inferior. Arises from the posterior side of the anterior abdominal wall and extends as a companion vein of the inferior epigastric artery. A
- 24a **Pubic branch (accessory obturator vein).** R. pubicus (v. obturatoria accessoria). It anastomoses with the branch of the obturator vein at the inner surface of the pubis. A
- 25 **Deep circumflex iliac vein.** V. circumflexa iliaca profunda. Companion vein of the deep circumflex iliac artery. A



A Pelvic veins medial view

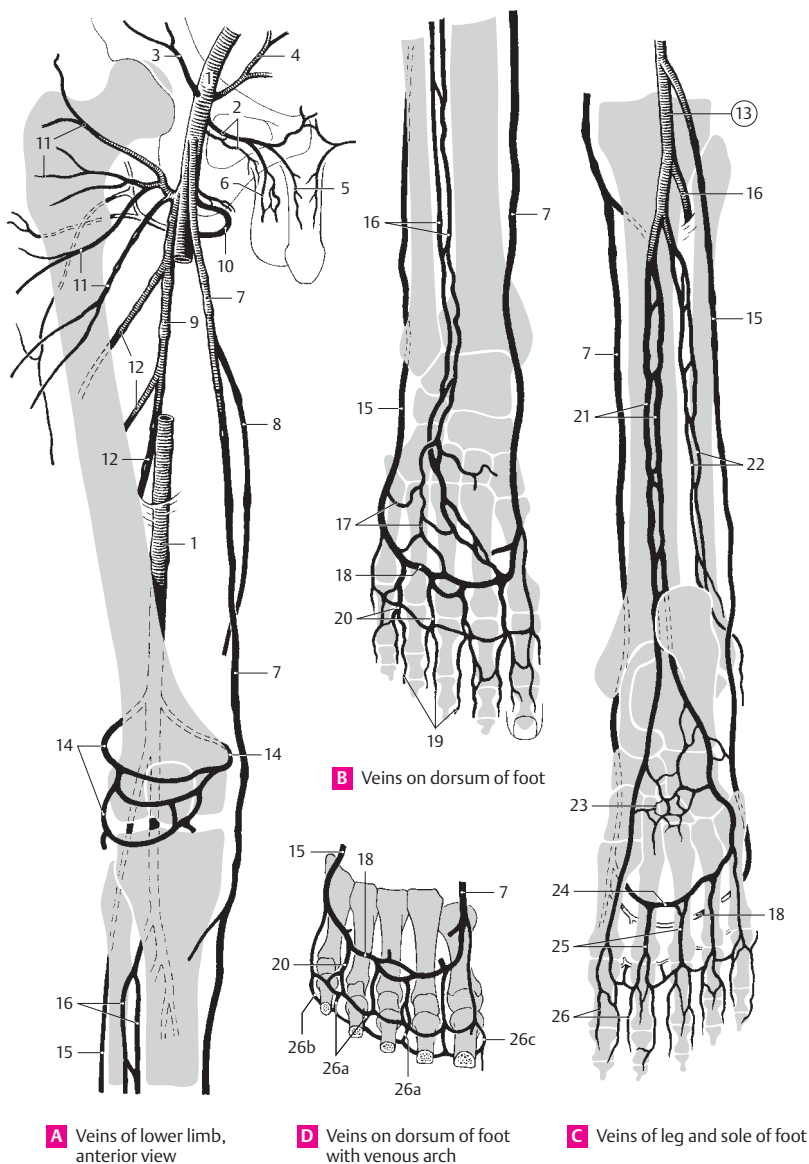


B Veins of female perineum



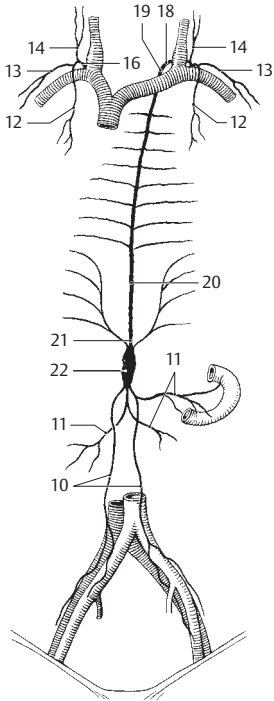
C Veins of male urogenital organs

- VEINS OF LOWER LIMBS.** Venae membri inferioris.
- 0a **Venae superficiales membri inferioris.** Superficial veins of lower limbs.
- 0b **Venae profundae membri inferioris.** Deep veins of lower limbs.
- 1 **Femoral vein.** V. femoralis. A companion vein of the femoral artery that extends from the hiatus tendineus of the adductor canal to the inguinal ligament. A
- 2 **External pudendal veins.** Vv. pudendae externae. Individual branches from the external genitalia. A
- 3 **Superficial circumflex iliac vein.** V. circumflexa iliaca superficialis. Subcutaneous companion vein of the superficial circumflex iliac artery. A
- 4 **Superficial epigastric vein.** V. epigastrica superficialis. Subcutaneous companion vein of the superficial epigastric artery. A
- 5 **Superficial dorsal veins of penis/clitoris.** Vv. dorsales superficiales penis/clitoridis. Paired epifascial veins of the penis (clitoris) that drain into the femoral vein or external pudendal veins. They run between the superficial and deep fasciae of the penis. A. See also p. 165 B
- 6 **Labial scrotal/labial veins.** Vv. scrotales/labiales anteriores. Arise from the scrotum or labia majora and open into the femoral vein or the external pudendal veins. A
- 7 **Greater saphenous vein.** V. saphena magna. Arises from the medial side of the foot and ascends medially. This vein is provided with valves and receives most of the medial superficial cutaneous veins. It drains into the femoral vein via the saphenous opening. A B C D
- 8 **Accessory saphenous vein.** V. saphena accessoria. Connecting branch that occasionally joins the small saphenous vein to the great saphenous vein. It may receive blood from the thigh except for the deep and lateral regions. It sometimes runs parallel to the great saphenous vein before entering the latter. A
- 9 **Accompanying vein of the profunda femoris artery.** V. profunda femoris. A
- 10 **Medial circumflex femoral veins.** Vv. circumflexae mediales femorales. Companion veins of the corresponding artery. A
- 11 **Lateral circumflex femoral veins.** Vv. circumflexae laterales femorales. Companion veins of the corresponding artery. A
- 12 **Perforating veins.** Vv. perforantes. Arise from the ischiofemoral musculature, penetrate the adductors and open into the profunda femoris vein. A
- 13 **Popliteal vein.** V. poplitea. From its origin between the popliteal artery and tibial nerve, it extends from the union of the anterior and posterior tibial veins to the hiatus tendineus of the adductor canal. C
- 13a **Sural veins.** Venae surales. Companion veins of the corresponding arteries.
- 14 **Genicular veins.** Vv. geniculares. Usually five veins arising from the knee. A
- 15 **Small saphenous vein.** V. saphena parva. It arises from the lateral margin of the foot, passes along the posterior side of the lower leg and drains into the popliteal vein. A B C D
- 16 **Anterior tibial veins.** Vv. tibiales anteriores. Companion veins of the anterior tibial artery. A B C
- 17 **Dorsal venous network of foot.** Rete venosum dorsale pedis. Network of veins on the dorsum of the foot that drain into the great and small saphenous veins and anterior tibial veins. B
- 18 **Dorsal venous arch of foot.** Arcus venosus dorsalis pedis. Venous arch on the dorsum of the foot receiving the dorsal metatarsal veins of the foot. It also serves as the main outlet for blood from the sole of the foot. B C D
- 19 **Dorsal digital veins of foot.** Vv. digitales dorsales pedis. Veins on the dorsum of the toes. B
- 20 **Dorsal metatarsal veins.** Vv. metatarsales dorsales. Companion veins of corresponding arteries. They arise from the dorsal digital veins of the foot. B D
- 21 **Posterior tibial veins.** Vv. tibiales posteriores. Veins accompanying the posterior tibial artery. C
- 22 **Peroneal (fibular) veins.** Vv. fibulares. Companion veins of the fibular artery found partly beneath the flexor hallucis longus. C
- 23 **Plantar venous network.** Rete venosum plantare. Dense subcutaneous network of veins on the sole of the foot. C
- 24 **Plantar venous arch.** Arcus venosus plantaris. Venous arch accompanying the arterial plantar arch. C
- 25 **Plantar metatarsal veins.** Vv. metatarsales plantares. Veins accompanying the corresponding arteries. C
- 26 **Plantar digital veins.** Vv. digitales plantares. Veins on the flexor side of the toes. C
- 26a **Intercapitular veins.** Vv. intercapitulares. Veins that connect the plantar and dorsal venous arches. D
- 26b **Lateral marginal vein.** V. marginalis lateralis. Anastomotic vein as in 26a. It drains into the small saphenous vein. D
- 26c **Medial marginal vein.** V. marginalis medialis. Anastomotic vein as in 26a. It drains into the great saphenous vein. D
- 27 **Perforating veins.** Vv. perforantes. Veins that connect the cutaneous and subfascial veins especially on the lower leg. Their valves prevent the flow of blood from the deep veins to the epifascial veins.

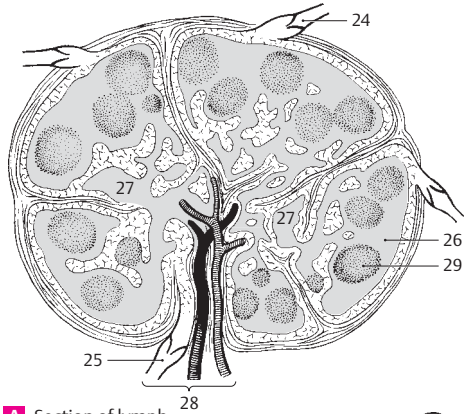


12

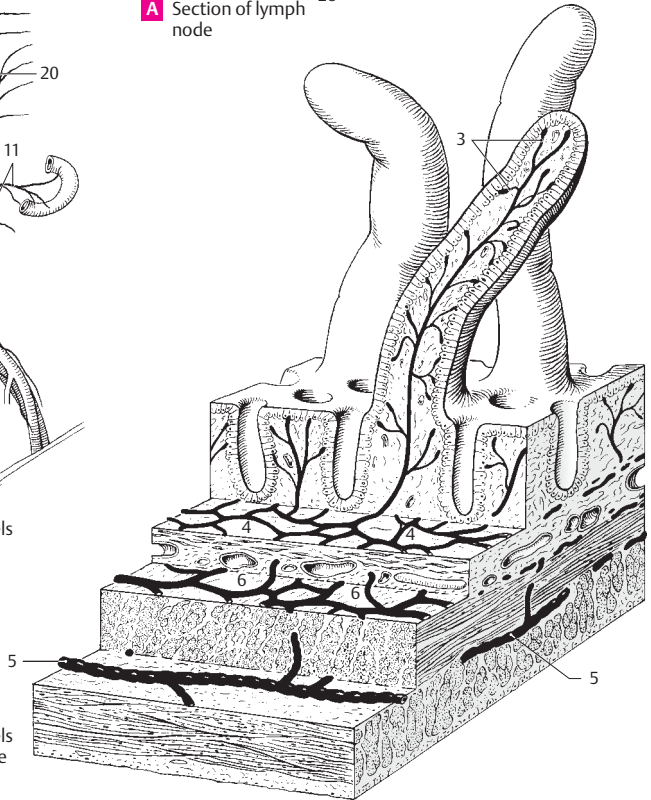
- 1 **LYMPHATIC SYSTEM.** Systema lymphaticum.
- 2 **Lymphatic vessels.** Vasa lymphatica.
- 3 **Lymphatic capillary.** Vas lymphocapillare. Any of the vessels of the lymphatic system that form closed networks and have permeable walls. C
- 4 **Lymphatic capillary network.** Rete lymphocapillare. Network of lymphocapillary veins. C
- 5 **Lymphatic vessel.** Vas lymphaticum. Any of the valvular lymphatic vessels that communicate with the lymphocapillary vessels. Their thin walls are sparsely lined with smooth muscles. C
- 6 **Lymphatic plexus.** Plexus lymphaticus. Network of lymphatic vessels lying deeper than the lymphocapillary vessels. In the outer layers of the skin, it lies within and directly below the corium. C
- 7 **Superficial lymphatic vessel.** Vas lymphaticum superficiale. It is situated superficially on the fascia of the limbs.
- 8 **Deep lymphatic vessel.** Vas lymphaticum profundum. It lies beneath the fascia of the limbs and often, but not always, accompanies blood vessels.
- 9 **Lymphatic trunks.** Trunci lymphatici. Five main lymphatic branches of the lymph-vascular system.
- 10 **Right/left lumbar trunk.** Truncus lumbaris dexter/sinister. Main branch which brings lymph to the cisterna chyli from the legs, pelvic viscera, urogenital system and parts of the abdominal wall and the abdominal viscera. B
- 11 **Intestinal trunks.** Trunci intestinales. Main conduits which transport lymph to the cisterna chyli from the supply region of the superior and inferior mesenteric arteries. B
- 12 **Right/left bronchomediastinal trunk.** Truncus bronchomediastinalis dexter/sinistra. It collects lymph from the heart, lungs and mediastinum. On the left side it opens into the thoracic duct, on the right side, the right lymphatic duct. Often, however, both may open directly into the subclavian veins. B
- 13 **Right/left subclavian trunk.** Truncus subclavialis dexter/sinister. Arises from the arm, accompanies the subclavian vein and usually opens on the right side into the right lymphatic duct and on the left side into the angle between the left subclavian vein and internal jugular vein. B
- 14 **Right/left jugular trunk.** Truncus jugularis dexter/sinister. Accompanies the internal jugular vein and passes to the angle between the internal jugular and subclavian veins (venous angle). B
- 15 **Lymphatic ducts.** Ductus lymphatici. The main drainage ducts of the lymphatic system.
- 16 **Right lymphatic duct (right thoracic duct).** Ductus lymphaticus dexter (ductus thoracicus dexter). It is formed by the union of the right jugular, subclavian and bronchomediastinal trunks. It may be absent. B
- 17 **Thoracic duct.** Ductus thoracicus. Arises from the cisterna chyli a short distance below the diaphragm, courses upward behind the aorta and opens into the venous angle, i. e., the angle between the left internal jugular and subclavian veins. B
- 18 **Arch of thoracic duct.** Arcus ductus thoracici. Arch formed by the thoracic duct before entering the venous angle. B
- 19 **Cervical part.** Pars cervicalis. Short cervical segment in front of C7. B
- 20 **Thoracic part.** Pars thoracica. It begins at the aortic hiatus and ends at the upper margin of T1. B
- 21 **Abdominal part.** Pars abdominalis. Very short segment in front of L1. B
- 22 **Cisterna chyli.** Variable dilatation at the origin of the thoracic duct. It receives the lumbar and intestinal trunks. B
- 23 **Lymph node.** Nodus lymphaticus (Lymphonodus). Lymphoreticular filtering organ, 1–25 mm in diameter, within the lymphatic vessels. Since lymph must usually traverse two lymph nodes before arriving in the blood stream at the venous angle, there is double protection against the invasion of pathogens or tumor cells into the blood stream. A
- 24 **Afferent lymphatic vessels.** Vas lymphaticum afferens. Any of the vessels that carry lymph to a lymph node; located on the convex surface of the node. A
- 25 **Efferent lymphatic vessel.** Vas lymphaticum efferens. Any of the vessels that carry lymph away from a lymph node; located on the hilum of the node. A
- 26 **Cortex.** Part of the lymphoreticular tissue proximal to the capsule. A
- 27 **Medulla.** Lymphoreticular tissue between cortex and hilum. A
- 28 **Hilum.** Somewhat retracted area where blood vessels enter and where blood and lymphatic vessels exit. A
- 29 **Lymphatic nodule.** Nodus lymphaticus (lymphonodus). Spherical condensation of lymphoreticular tissue predominantly occupying the cortex. It exhibits a lighter central area ("reaction center"). A



B Lymphatic vessels of the trunk

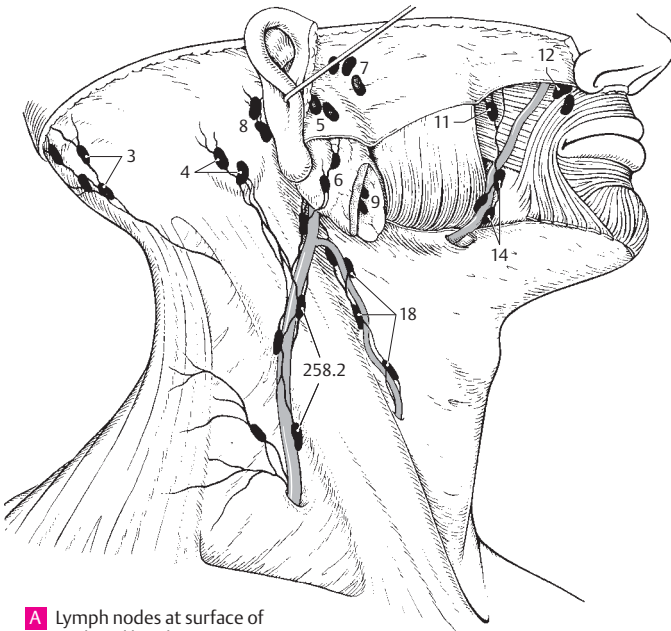


A Section of lymph node



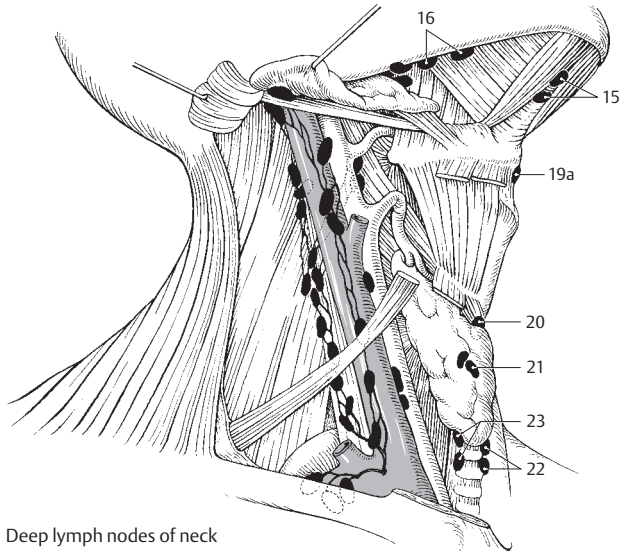
C Lymphatic vessels of small intestine

- 1 **REGIONAL LYMPH NODES.** Nodi lymphatici regionales.
- 2 **Head and neck.** Caput et collum.
- 3 **Occipital lymph nodes.** Nodi lymphatici occipitales. One to three lymph nodes lying close to the margin of the trapezius. Afferents: scalp, deep cervical muscles. Efferents: deep cervical lymph nodes. A
- 4 **Mastoid [retroauricular] lymph nodes.** Nodi lymphatici mastoidei [[retroauriculares]]. Usually two nodes on the mastoid process. Afferents: posterior surface of pinna, posterior wall of external acoustic meatus and corresponding parts of scalp. Efferents: deep cervical lymph nodes. A
- 5 **Superficial partodi lymph nodes.** Nodi lymphatici parotidei superficiales. They lie on the parotid fascia in front of the tragus. Afferents: junction of temporal region and anterior surface of pinna. Efferents: deep cervical lymph nodes. A
- 6 **Deep parotid lymph nodes.** Nodi lymphatici parotidei profundi. Group beneath the parotid fascia. Afferents: tympanic cavity, external acoustic meatus, frontotemporal region, eyelids, root of nose, and sometimes the posterior floor of the nose and nasopharyngeal cavity. Efferents: deep cervical lymph nodes. A
- 7 **Praearicular lymph nodes.** Nodi lymphatici prae-auriculares. Group located in front of the pinna. A
- 8 **Infra-auricular lymph nodes.** Nodi lymphatici infra-auriculares. Group beneath the pinna. A
- 9 **Intraglandular lymph nodes.** Nodi lymphatici intraglandulares. Group situated directly within the parotid. A
- 10 **Facial lymph nodes.** Nodi lymphatici faciales. Variable lymph nodes that receive lymph from the eyelids, nose and the rest of the face and buccal mucosa. Efferents: submandibular lymph nodes. The vessels accompany the facial artery.
- 11 **Buccinator node.** [Nodus buccinatorius]. Lymph node situated deep within the buccinator muscle. A
- 12 **Nasolabial node.** [Nodus nasolabialis]. Lymph node located below the nasolabial fold. A
- 13 **Malar node.** [Nodus malaris]. Superficial lymph node of the cheek.
- 14 **Mandibular node.** [Nodus mandibularis]. Lymph node located on the mandible. A
- 14a **Lingual lymph nodes.** Nodi lymphatici linguales. Nodes located on the hyoglossus muscle. They drain lymph from the lower surface and lateral margin to tongue as well as the medial anterior two-thirds of its dorsal surface.
- 15 **Submental lymph nodes.** Nodi lymphatici submentales. Nodes between the anterior bellies of the digastric muscles. Afferents: middle of lower lip, floor of mouth and tip of tongue. Efferents: deep cervical and submental lymph nodes. B
- 16 **Submandibular lymph nodes.** Nodi lymphatici submandibulares. Nodes between the mandible and submandibular gland that serve as first and second filter stations. Direct afferent area: inner canthus of eye, cheek, side of nose, upper lip, lateral lower lip, gingiva and anterior lateral margin of tongue. Indirect afferents: facial and submental lymph nodes. Efferents: deep cervical lymph nodes. B
- 17 **Anterior cervical lymph nodes.** Nodi lymphatici cervicales anteriores.
- 18 **Superficial (anterior jugular) lymph nodes.** Nodi lymphatici superficiales (jugulares anteriores). Nodes on the internal jugular vein. Afferent region: skin of anterior side of neck. Efferents: bilateral deep cervical lymph nodes. A
- 19 **Deep lymph nodes.** Nodi lymphatici profundi. Anterior group.
- 19a **Infrahyoid lymph nodes.** Nodi lymphatici infrahyoidei. They lie in the midline below the body of the hyoid bone. Afferent areas: laryngeal vestibule, piriform recess and adjacent hypopharynx. Efferents: deep cervical lymph nodes. B
- 20 **Prelaryngeal lymph nodes.** Nodi lymphatici praelaryngeales³. Nodes on the cricothyroid ligament. Afferent area: lower half of larynx. Efferents: deep cervical lymph nodes. B
- 21 **Thyroid lymph nodes.** Nodi lymphatici thyroidei. Nodes on the thyroid gland. Efferents: as in 20. B
- 22 **Pretracheal lymph nodes.** Nodi lymphatici pretracheales. Nodes in front of the trachea. Afferent regions: trachea and larynx. Efferents: deep cervical lymph nodes. B
- 23 **Paratracheal lymph nodes.** Nodi lymphatici paratracheales. Nodes beside the trachea. Actions similar to those of 22. B
- 23a **Retropharyngeal lymph nodes.** Nodi lymphatici retropharyngeales. Deep cervical lymph nodes in front of the arch of the atlas. See p. 258.13



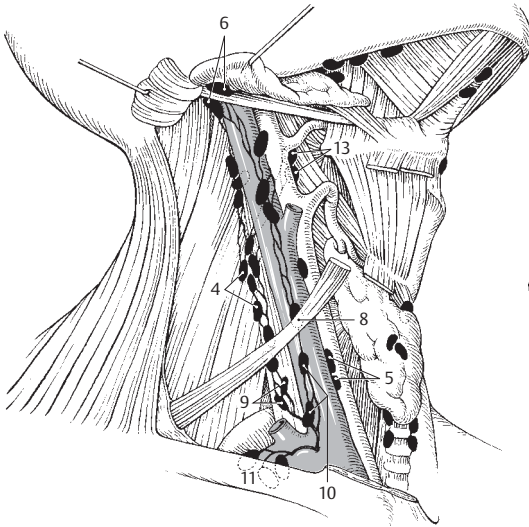
A Lymph nodes at surface of neck and head

13

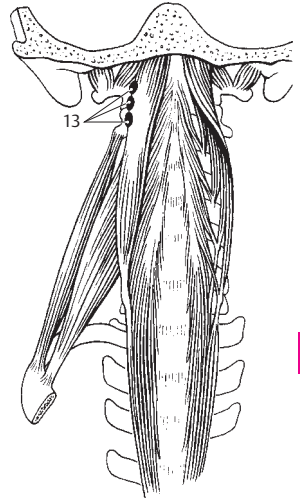


B Deep lymph nodes of neck

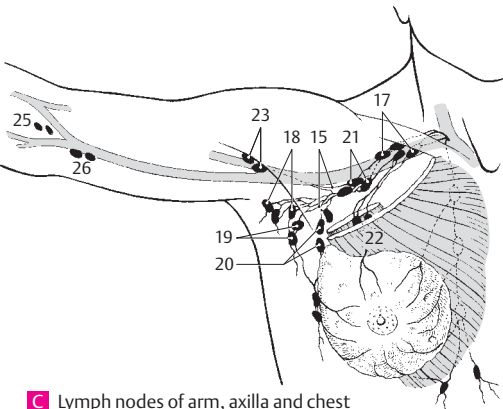
- 1 **Lateral cervical lymph nodes.** Nodi lymphatici cervicales laterales. Groups of lymph nodes lateral to the neck which are classified as follows.
- 2 **Superficial lymph nodes.** Nodi lymphatici superficiales. Nodes on the external jugular vein. Afferent regions: lower pinna and area below the parotid. Efferents: deep cervical lymph nodes. See p. 257 A
- 3 **Superior deep lymph nodes.** Nodi lymphatici profundi superiores. Nodes that form the second filter station for almost all of the head lymph nodes but also receive direct peripheral tributaries from their surroundings. Efferents: jugular trunk. A
- 4 **Lateral lymph nodes.** Nodi lymphatici laterales. They lie lateral to the internal jugular vein. A
- 5 **Anterior lymph nodes.** Nodi lymphatici anteriores. Group of lymph nodes in front of the internal jugular vein. A
- 6 **Jugulodigastric node.** Nodus jugulodigastricus. It is the most cranial of the deep cervical nodes and is palpable when the tonsil, tongue or pharynx is inflamed. A
- 7 **Inferior deep cervical lymph nodes.** Nodi lymphatici profundi inferiores. They form the second filter station for the lymph nodes of the cervical viscera and the last filter station for the lymph nodes of the head. They also receive direct tributaries. Efferents: jugular trunk.
- 8 **Jugulo-omohyoid node.** Nodus juguloomohyoideus. Node between the omohyoid muscle and internal jugular vein. Afferent area: tongue. A
- 9 **Lateral lymphatic nodes.** Nodi lymphatici laterales. They lie lateral to the internal jugular vein. A
- 10 **Anterior lymph nodes.** Nodi lymphatici anteriores. Group in front of the internal jugular vein. A
- 11 **Supraclavicular lymph nodes.** Nodi lymphatici supraclaviculares. Nodes of the same group located above the clavicle. A
- 12 **Accessory nodes.** Nodi accessorii.
- 13 **Retropharyngeal lymph nodes.** Nodi lymphatici retropharyngeales. Deep cervical lymph nodes at the level of the lateral mass of the atlas and at the lateral margin of the longus capitis muscle. A B
- 14 **Upper limb.** Membrum superius.
- 15 **Axillary lymphatic plexus.** Plexus lymphaticus axillaris. Netlike connections of 20–30 axillary lymph nodes via their lymphatic vessels. C
- 16 **Axillary lymph nodes.** Nodi lymphatici axillares. Nodes in the axilla. C
- 17 **Apical lymph nodes.** Nodi lymphatici apicales. Nodes medial to the axillary vein that extend from the upper margin of the pectoralis minor to the apex of the axilla. Afferent areas: upper lateral part of the breast and all remaining axillary lymph nodes. Efferents: (left) subclavian trunk to the thoracic duct or subclavian vein; (right) into the vein directly or after joining the jugular trunk. C
- 18 **Brachial lymph nodes.** Nodi lymphatici brachiales. Nodes along the axillary artery that drain lymph from the arm. C
- 19 **Subscapular lymph nodes.** Nodi lymphatici subscapulares. Nodes alongside the subscapular artery that drain lymph from the posterior thorax and shoulder as well as from the lower nuchal region. C
- 20 **Pectoral lymph nodes.** Nodi lymphatici pectorales. Nodes along the lateral margin of the pectoralis minor that drain lymph from the anterior and lateral wall of the trunk as far as the navel, as well as the central and lateral part of the breast. C
- 21 **Central lymph nodes.** Nodi lymphatici centrales. Nodes in the fat of the axilla that filter lymph from the brachial, subscapular and pectoral lymph nodes. C
- 22 **Interpectoral lymph nodes.** Nodi lymphatici interpectoriales. Small group of nodes situated between the pectoralis major and minor. Afferent area: mammary gland. Efferents: apical lymph nodes. C
- 23 **Deltopectoral (infraclavicular) lymph nodes.** Nodi lymphatici deltopectorales (infraclaviculares). Nodes on the cephalic vein in the deltopectoral groove that receive lymph from the arm. C
- 24 **Brachial lymph nodes.** Nodi lymphatici brachiales. Single lymph nodes along the brachial vessels.
- 25 **Cubital lymph nodes.** Nodi lymphatici cubitales. One or two lymph nodes on the brachial artery in the cubital fossa. C
- 26 **Supratrochlear lymph nodes.** Nodi lymphatici supratrochlearis. Nodes that lie medial to the basilic vein and above the elbow joint. C
- 27 **Superficial lymph nodes.** Nodi lymphatici superficiales.
- 28 **Deep lymph nodes.** Nodi lymphatici profundi. Individual lymph nodes that follow the course of the deep lymphatic vessels.



A Deep lymph nodes of neck

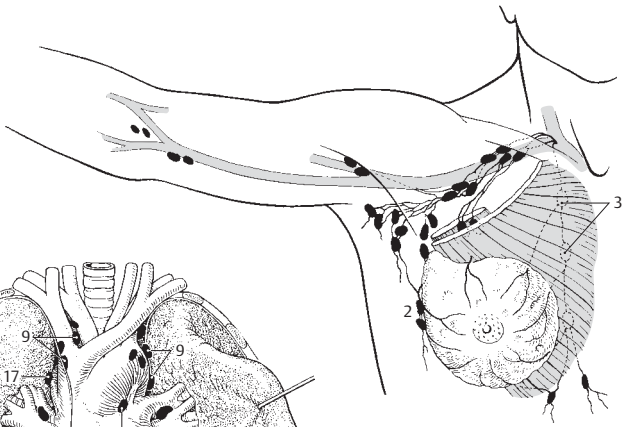


B Neck, anterior view

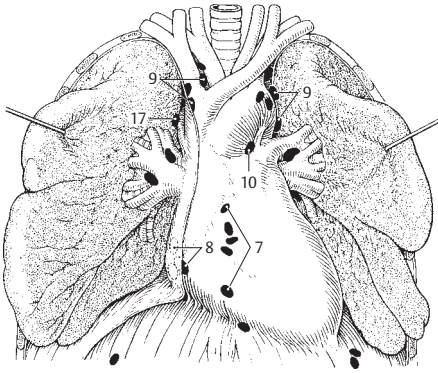


C Lymph nodes of arm, axilla and chest

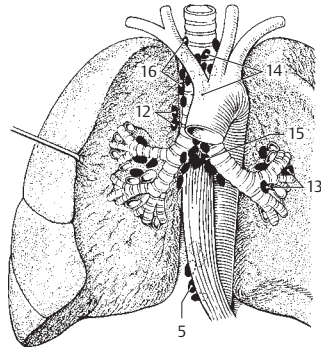
- 1 **Thorax.**
- 2 **PARAMAMMARY LYMPH NODES.** Nodi lymphatici paramammarii. Lymph nodes on the lateral margin of the mammary gland. A
- 3 **Parasternal lymph nodes.** Nodi lymphatici parasternales. Nodes located along the course of the internal thoracic vessels. Afferent regions: mammary gland, intercostal spaces, part of the liver and diaphragm. Efferents: either directly into the respective subclavian vein or internal jugular vein or into the thoracic duct or subclavian trunk. A
- 4 **Intercostal lymph nodes.** Nodi lymphatici intercostales. Nodes located in the paravertebral portion of the intercostal spaces. Afferent area: pleura and intercostal spaces. D
- 5 **Paravertebral lymph nodes.** Nodi lymphatici praevertebrales.³ Nodes located between the esophagus and vertebral column. Afferent regions: surroundings, if not drained by other vessels. C D
- 6 **Superior phrenic lymph nodes.** Nodi lymphatici phrenici superiores. Nodes situated behind the cartilage-bone boundary of the 7th rib at the site where the aorta opens into the diaphragm and along the inferior vena cava. Afferent areas: liver and diaphragm. D
- 7 **Prepericardial lymph nodes.** Nodi lymphatici prepericardiales. Nodes located between the sternum and pericardium. Afferent regions: sternum and anterior pericardium. Efferents: parasternal lymph nodes. B
- 8 **Lateral pericardial lymph nodes.** Nodi lymphatici pericardiales laterales. Nodes found between the pericardium and mediastinal pleura. B
- 9 **Anterior mediastinal lymph nodes.** Nodi lymphatici mediastinales anteriores. Nodes along the brachiocephalic veins, in front of the arch of the aorta and its branches. Afferent regions: thymus, pericardium and parasternal lymph nodes. Efferents: bronchomediastinal trunk. B
- 10 **Ligamentum arteriosum node.** [Nodus ligamenti arteriosi]. Node occasionally found along the lig. arteriosum. B
- 11 **Posterior mediastinal lymph nodes.** Nodi lymphatici mediastinales posteriores. Nodes situated in the superior and posterior mediastinum. They receive lymph from the following organs: lungs, bronchi, trachea, esophagus, pericardium, diaphragm and diaphragmatic surface of the liver. They pass efferent vessels to the thoracic and bronchomediastinal ducts. The posterior mediastinal lymph nodes are subdivided into the following groups.
- 12 **Pulmonary juxtaesophageal lymph nodes.** Nodi lymphatici juxtaesophageales pulmonales. Group situated beside the esophagus; they serve the lungs. C
- 13 **Tracheobronchial lymph nodes.** Nodi lymphatici tracheobronchiales. Group located along the bronchi at the site where they enter into the lungs. C
- 14 **Superior tracheobronchial lymph nodes.** Nodi lymphatici tracheobronchiales superiores. Group situated cranially on the stem bronchi and the trachea. C
- 15 **Inferior tracheobronchial lymph nodes.** Nodi lymphatici tracheobronchiales inferiores. Group located caudal to the tracheal bifurcation. C
- 16 **Paratracheal lymph nodes.** Nodi lymphatici paratracheales. Group situated along the trachea. C
- 17 **Node of arch of azygos vein.** [Nodus arcus venae azygos]. Lymph node occasionally present at the arch which the azygos vein forms around the hilum of the right lung before joining the superior vena cava. B



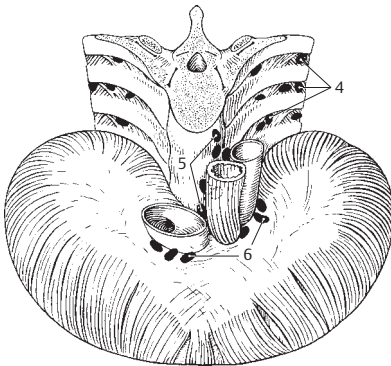
A Lymph nodes of arm, axilla and thorax



B Lymph nodes in thorax

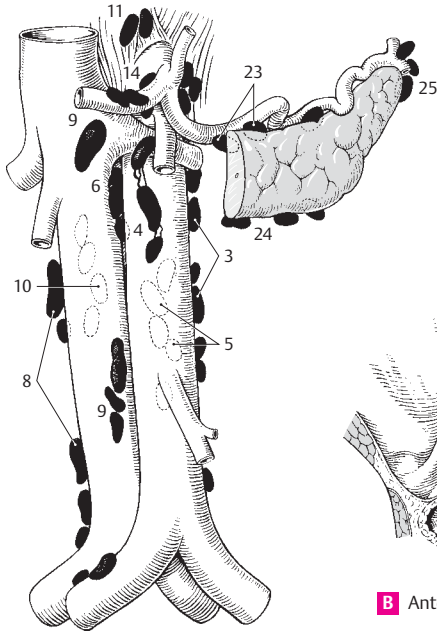

C Lymph nodes in thorax

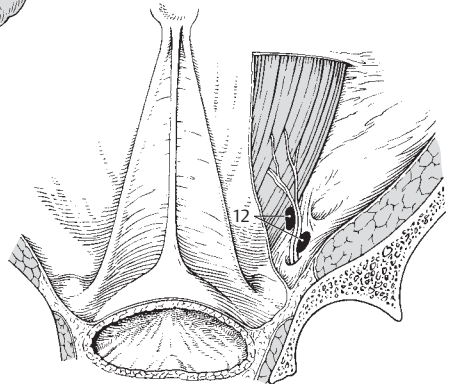


D Lymph nodes in thorax

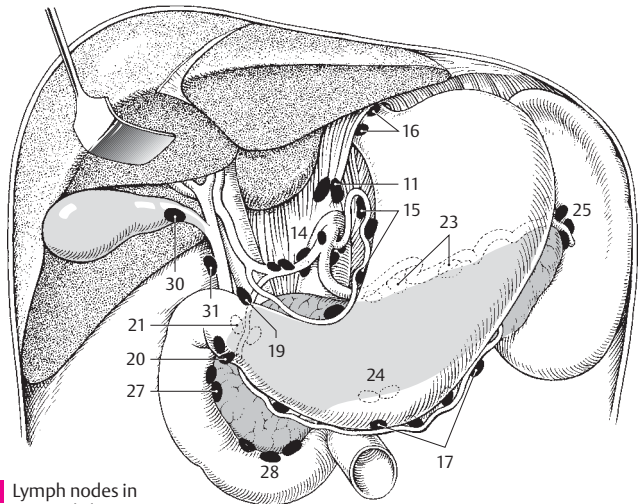
- 1 **Abdomen – parietal lymph nodes.** Nodi lymphatici parietales. Lymph nodes in the abdominal wall.
- 2 **Left lumbar lymph nodes.** Nodi lymphatici lumbales (lumbares) sinistri. Nodes situated along the abdominal aorta. They mainly serve as secondary filter stations for lymph nodes located further below, but also as primary filter stations for the suprarenal gland, kidney, ureter, testis, ovary, uterine tubes, fundus of uterus and abdominal wall. Efferents: primarily into the lumbar trunk. They can be divided into the following three groups.
- 3 **Lateral aortic lymph nodes.** Nodi lymphatici aortici laterales. Group on the left side of the aorta. A
- 4 **Pre-aortic lymph nodes.** Nodi lymphatici preaortici. Group situated in front of the aorta. A
- 5 **Postaortic lymph nodes.** Nodi lymphatici postaortici. This group lies between the aorta and vertebral column. A
- 6 **Intermediate lumbar lymph nodes.** Nodi lymphatici lumbales (lumbares) intermedii. Group situated between the aorta and inferior vena cava. They function as described in 2–A
- 7 **Right lumbar lymph nodes.** Nodi lymphatici lumbales (lumbares) dextri. Group situated along the inferior vena cava. They function as described in (2) and are subdivided into the following three groups.
- 8 **Lateral caval lymph nodes.** Nodi lymphatici cauales laterales. Nodes on the right side of the inferior vena cava. A
- 9 **Precaval lymph nodes.** Nodi lymphatici precavales. Nodes situated in front of the vena cava. A
- 10 **Postcaval lymph nodes.** Nodi lymphatici postcavales. Nodes located behind the vena cava. A
- 11 **Inferior phrenic lymph nodes.** Nodi lymphatici phrenici inferiores. Nodes situated along the inferior surface of the diaphragm near the aortic opening. A C
- 12 **Inferior epigastric lymph nodes.** Nodi lymphatici epigastrici inferiores. Three or four nodes along the inferior epigastric artery that receive lymph from its supply area. B
- 13 **Visceral nodes.** Abdomen – nodi lymphatici viscerales. Lymph nodes of the abdominal viscera.
- 14 **Celiac lymph nodes.** Nodi lymphatici coeliaci. Nodes situated the celiac trunk. They form the secondary filter station for the stomach, duodenum, liver, gallbladder, pancreas and spleen. Efferents: some form the intestinal trunk, some pass directly into the cisterna chyli. A C
- 15 **Gastric lymph nodes [right and left].** Nodi lymphatici gastrici [dextri/sinistri]. From the lesser curvature of the stomach, they follow the course of the right and left gastric arteries. Afferent region: stomach. Efferents: celiac lymph nodes. C
- 16 **[Anulus lymphaticus cardiae].** Lymphatic ring occasionally present around the cardia of the stomach. C
- 17 **Gastro-omental lymph nodes [right and left].** Nodi lymphatici gastro-omentalis [dextri/sinistri]. Nodes located along the course of the right and left gastro-omental arteries at the greater curvature of the stomach. Their afferents receive lymph from the stomach and the greater omentum and their efferents convey lymph along the right side to the lymph nodes of the liver and along the left side to the lymph nodes of the spleen and pancreas. C
- 18 **Pyloric lymph nodes.** Nodi lymphatici pylorici. Situated around the pylorus. Their efferents drain into the hepatic or celiac lymph nodes.
- 19 **Suprapyloric node.** [Nodus suprapyloricus]. Node situated above the pylorus. C
- 20 **Subpyloric nodes.** [Nodi subpylorici]. Nodes situated caudal to the pylorus. C
- 21 **Retropyloric nodes.** [Nodi retropylorici]. Group of nodes located dorsal to the pylorus. C
- 22 **Pancreatic lymph nodes.** Nodi lymphatici pancreatici. Situated along the upper and lower margins of the pancreas. Their efferent vessels convey lymph to the splenic lymph nodes, mesenteric lymph nodes and pancreaticoduodenal lymph nodes.
- 23 **Superior pancreatic lymph nodes.** Nodi lymphatici pancreatici superiores. Group of nodes located along the upper margin of the pancreas. A C
- 24 **Inferior pancreatic lymph nodes.** Nodi lymphatici pancreatici inferiores. Group of nodes located along the lower margin of the pancreas. A C
- 25 **Splenic (lienal) lymph nodes.** Nodi lymphatici splenici (lienales). Nodes near the hilum of the spleen that convey their lymph to the celiac lymph nodes. A C
- 26 **Pancreaticoduodenal lymph nodes.** Nodi lymphatici pancreaticoduodenales. Small nodes between the pancreas and duodenum. Afferent regions: duodenum and pancreas.
- 27 **Superior pancreaticoduodenal lymph nodes.** Nodi lymphatici pancreaticoduodenales superiores. Cranially situated group of nodes. Efferents: hepatic nodes. C
- 28 **Inferior pancreaticoduodenal lymph nodes.** Nodi lymphatici pancreaticoduodenales inferiores. Caudal group of lymph nodes. Efferents: mesenteric lymph nodes. C
- 29 **Hepatic lymph nodes.** Nodi lymphatici hepatici. Nodes situated near the hilum of the liver and in the hepatoduodenal ligament. Their lymph is taken partly from the liver, partly from adjacent lymph nodes and transported to the celiac lymph nodes.
- 30 **Cystic node.** Nodus cysticus. Larger lymph node near the neck of the gallbladder. C
- 31 **Foraminal node.** Nodus foraminalis. Larger lymph node near the epiploic foramen. C



A Deep lymph nodes at abdominal cavity

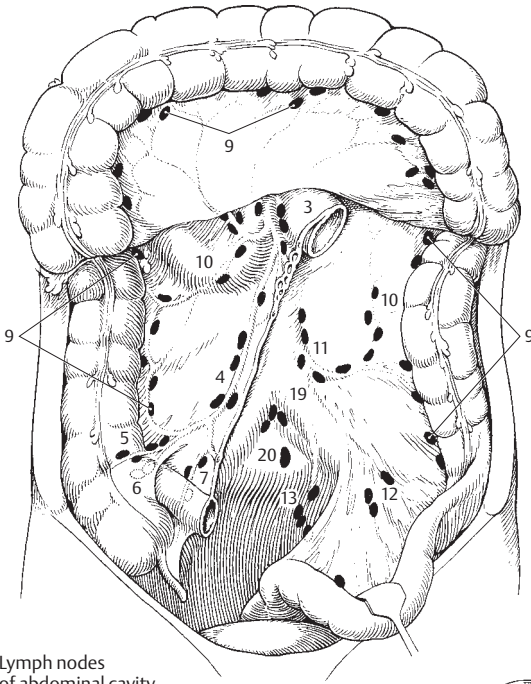


B Anterior abdominal wall from behind



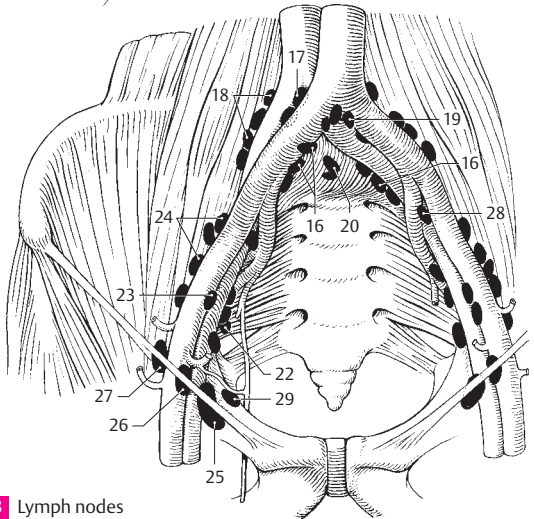
C Lymph nodes in upper abdomen

- 1 **Mesenteric lymph nodes.** Nodi lymphatici mesenterici. Numerous (100–150) lymph nodes important for the prevention of lipidemia. Their efferent vessels drain lymph via the celiac lymph nodes.
- 2 **Juxtaintestinal lymph nodes.** Nodi lymphatici juxtaintestinales. Subgroup of mesenteric lymph nodes located close to the small intestine.
- 3 **Superior [central] lymph nodes.** Nodi lymphatici superiores [centrales]. Subgroup of mesenteric lymph nodes located near the stem of the superior mesenteric artery. A
- 4 **Ileocolic lymph nodes.** Nodi lymphatici ileocolici. Group of nodes situated along the ileocolic artery. Efferents: celiac lymph nodes. A
- 5 **Prececal lymph nodes.** Nodi lymphatici precaecales. Nodes situated along the anterior cecal artery. A
- 6 **Retrocecal lymph nodes.** Nodi lymphatici retrocaecales. They situated along the posterior cecal artery. A
- 7 **Appendicular lymph nodes.** Nodi lymphatici appendiculares. Nodes situated along the appendicular artery. They are absent in 33–50% of cases. A
- 8 **Mesocolic lymph nodes.** Nodi lymphatici mesocolici. Nodes for the greater part of the colon. Predominantly located in the mesocolon. Their efferents convey lymph to the celiac lymph nodes.
- 9 **Paracolonic lymph nodes.** Nodi lymphatici paracolici. Subgroup of mesocolic lymph nodes located along the colon. A
- 10 **Right/middle/left colic lymph nodes.** Nodi lymphatici colici [dextri/medii/sinistri]. Subgroup of mesocolic lymph nodes situated along the stems of the right, middle and left colic arteries. A
- 11 **Inferior mesenteric lymph nodes.** Nodi lymphatici mesenterici inferiores. Nodes located along the inferior mesenteric artery. Afferent areas: part of the descending colon, sigmoid and part of the rectum. Efferents: pre-aortic lymph nodes at the level of the inferior mesenteric artery. A
- 12 **Sigmoid lymph nodes.** Nodi lymphatici sigmoidei. Nodes located along the sigmoid artery. They drain the sigmoid and the adjoining segment of colon. A
- 13 **Superior rectal lymph nodes.** Nodi lymphatici rectales superiores. Nodes located along the superior rectal artery for drainage of the rectum. A
- 14 **Parietal nodes of pelvis.** Pelvis – nodi lymphatici parietales. Lymph nodes along the wall of pelvis.
- 15 **Common iliac lymph nodes.** Nodi lymphatici iliaci communes. Group of nodes situated along the internal iliac vein. They serve as the second station for the lymph nodes of the pelvic organs, (= pelvic), interior pelvic wall, abdominal wall up to the navel, hip muscles, and gluteal muscles. Efferents: lumbar lymph nodes and lumbar trunk. Individually, the following subgroups are distinguished.
- 16 **Medial common iliac lymph nodes.** Nodi lymphatici iliaci communes mediales. Subgroup situated medial to the vascular cord. B
- 17 **Intermediate common iliac lymph nodes.** Nodi lymphatici iliaci communes intermedii. Subgroup situated between the medial and lateral groups behind the vascular cord. B
- 18 **Lateral common iliac lymph nodes.** Nodi lymphatici iliaci communes laterales. Subgroup located lateral to the vascular cord. B
- 19 **Subaortic common iliac lymph nodes.** Nodi lymphatici iliaci communes subaortici. Subgroup located caudal to the aortic bifurcation in front of L4. B
- 20 **Promontory common iliac lymph nodes.** Nodi lymphatici iliaci communes promontorii. Subgroup situated in front of the promontory. B
- 21 **External iliac lymph nodes.** Nodi lymphatici iliaci externi. Group of nodes located along the external iliac vessels. They are the first lymph station for a part of the urinary bladder and vagina, and second lymph station for the inguinal lymph nodes. Efferents: common iliac lymph nodes. They are divided into the following groups.
- 22 **Medial external iliac lymph nodes.** Nodi lymphatici iliaci externi mediales. Group located medial to the vascular cord. B
- 23 **Intermediate external iliac lymph nodes.** Nodi lymphatici iliaci externi intermedii. Group located between the lateral and medial groups and behind the artery. B
- 24 **Lateral external iliac lymph nodes.** Nodi lymphatici iliaci externi laterales. Group located lateral to the vascular bundle. B
- 25 **Medial lacunar node.** [Nodus lacunaris medialis]. Node situated in the vascular lacuna medial to the vascular cord. B
- 26 **Intermediate lacunar node.** [Nodus lacunaris intermedius]. When present, it lies in the middle of the vascular lacuna. B
- 27 **Lateral lacunar node.** [Nodus lacunaris lateralis]. Node situated laterally in the vascular lacuna. B
- 28 **Interiliac external iliac lymph nodes.** Nodi lymphatici iliaci externi interiliaci. Lymph nodes in the bifurcation between the internal and external iliac arteries. B
- 29 **Obturator external iliac lymph nodes.** Nodi lymphatici iliaci externi obturatorii. Group located at the obturator artery. B



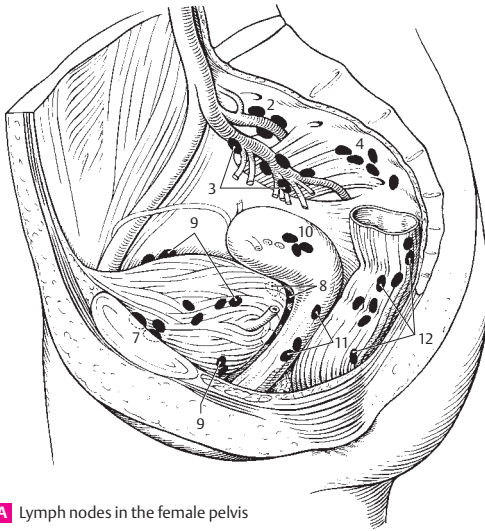
A Lymph nodes of abdominal cavity

13

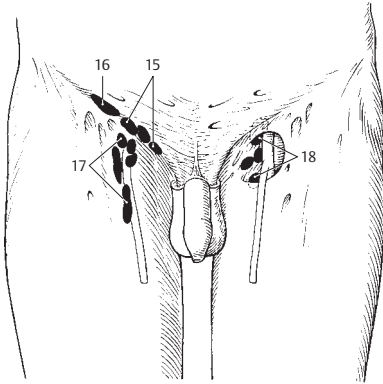


B Lymph nodes along pelvic vessels

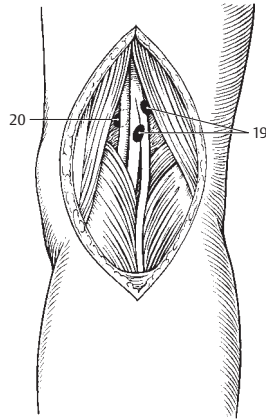
- 1 **Internal iliac lymph nodes.** Nodi lymphatici iliaci interni. Located along the internal iliac artery; they drain the pelvic organs, the deep perineal region and both the external and internal walls of the pelvis. Their efferents communicate with the common iliac lymph nodes.
- 2 **Superior gluteal lymph nodes.** Nodi lymphatici gluteales superiores. Nodes for the pelvic wall located at the superior gluteal artery. A
- 3 **Inferior gluteal lymph nodes.** Nodi lymphatici gluteales inferiores. Nodes for the prostate and proximal urethra are situated along the inferior gluteal artery. A
- 4 **Sacral lymph nodes.** Nodi lymphatici sacrales. Nodes for the prostate and cervix found along the sacrum. A
- 5 **Visceral nodes of pelvis.** Pelvis – nodi lymphatici viscerales.
- 6 **Perivesicular lymph nodes.** Nodi lymphatici paravesculares. Nodes for the urinary bladder and partly also for the prostate located along the bladder. A
- 7 **Prevesicular lymph nodes.** Nodi lymphatici prevesiculares. Subgroup located between the urinary bladder and symphysis. A
- 8 **Postvesicular lymph nodes.** Nodi lymphatici postvesiculares. Subgroup behind the urinary bladder. A
- 9 **Lateral vesicular lymph nodes.** Nodi lymphatici vesiculares laterales. Nodes situated at the lower end of the medial – formerly lateral – umbilical ligament. A
- 10 **Parauterine lymph nodes.** Nodi lymphatici parauterini. Nodes for the cervix uteri situated beside the uterus. A
- 11 **Paravaginal lymph nodes.** Nodi lymphatici paravaginales. Located beside the vagina; they drain lymph from part of this organ. A
- 12 **Pararectal (anorectal) lymph nodes.** Nodi lymphatici pararectales (anorectales). Located lateral to the musculature of the rectum; they drain this organ and a part of the vagina. A
- 13 **Lower limb.** Membrum inferius.
- 14 **Superficial inguinal lymph nodes.** Nodi lymphatici inguinales superficiales. Group of nodes located in the subcutaneous adipose tissue, thus on the fascia lata. They drain the anus, perineum, external genitalia, abdominal wall and surface of the leg. Efferents: external iliac lymph node.
- 15 **Superomedial superficial inguinal lymph nodes.** Nodi lymphatici superomediales. Medial portion of the group of nodes located along the inguinal ligament. B
- 16 **Superolateral superficial inguinal lymph nodes.** Nodi lymphatici superolaterales. Lateral portion of group located below the inguinal ligament. B
- 17 **Inferior lymph nodes.** Nodi lymphatici inferiores. Group arranged along a vertical line at the proximal end of the great saphenous vein. They drain the superficial lymphatic vessels of the leg. B
- 18 **Deep inguinal lymph nodes.** Nodi lymphatici inguinales profundi. Positioned below the fascia lata at the level of the saphenous hiatus. The uppermost node can be especially large and may occupy the femoral canal (Rosenmüller's node). Afferent region: deep lymphatic vessels of the leg. Efferents: external iliac lymph nodes. B
- 19 **Superficial popliteal lymph nodes.** Nodi lymphatici popliteales superficiales. They lie at the proximal end of the small saphenous vein and receive lymph from the lateral margin of the foot and calf. Their efferents pass anteriorly through the hiatus tendineus into the deep inguinal lymph nodes. C
- 20 **Deep popliteal lymph nodes.** Nodi lymphatici popliteales profundi. Situated between the knee joint capsule and the popliteal artery. They receive lymph from the posterior side of the lower leg and their efferents convey it anteriorly through the hiatus tendineus to the deep inguinal lymph nodes. C
- 21 **Anterior tibial node.** [Nodus tibialis anterior]. Lymph node occasionally present along the anterior tibial artery.
- 22 **Posterior tibial node.** [Nodus tibialis posterior]. Lymph node occasionally present along the posterior tibial artery.
- 23 **Fibular node.** [Nodus fibularis]. Lymph node occasionally present along the peroneal (fibular) artery.



A Lymph nodes in the female pelvis

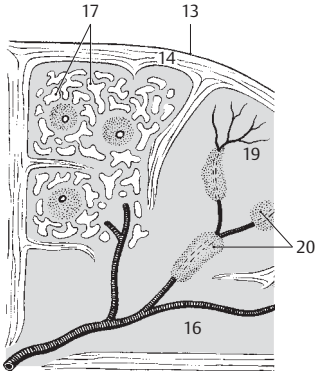


B Lymph nodes in the inguinal region

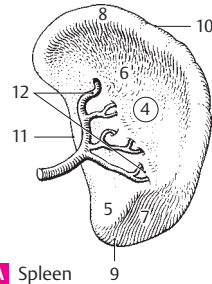


C Lymph nodes in the popliteal fossa

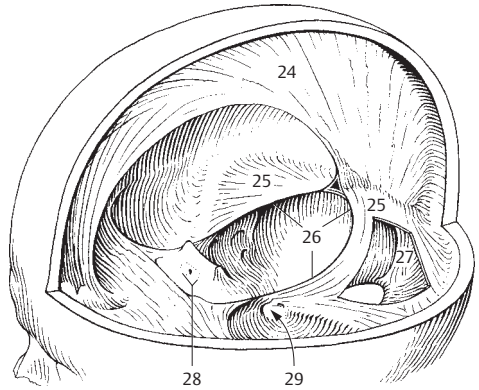
- 1 **SPLEEN.** Splen (lien). Lymphoreticular organ within the circulatory system. Actions: phagocytosis and destruction of red blood cells, lymphopoiesis, blood filtration and synthesis of antibodies. A B
- 2 **Accessory spleen.** [Splen accessorius]. Small islands of splenic tissue mostly in the greater omentum or gastrosplenic ligament.
- 3 **Diaphragmatic surface.** Facies diaphragmatica. Convex surface facing the diaphragm.
- 4 **Visceral surface.** Facies visceralis. Concave surface facing the viscera. A
- 5 **Renal surface.** Facies renalis. Lower surface in contact with the kidney. A
- 6 **Gastric surface.** Facies gastrica. Upper surface in contact with the stomach. A
- 7 **Colic surface.** Facies colica. Surface in contact with the colon. A
- 8 **Posterior end.** Extremitas posterior. A
- 9 **Anterior end.** Extremitas anterior. A
- 10 **Upper margin.** Margo superior. Border between gastric and diaphragmatic surfaces. A
- 11 **Lower margin.** Margo inferior. Border between diaphragmatic and renal surfaces. A
- 12 **Hilum of spleen.** Hilum spenicum. Entry and exit site of vessels between the gastric and renal surfaces. A
- 13 **Peritoneal covering.** Tunica serosa. B
- 14 **Connective tissue capsule of spleen.** Tunica fibrosa. B
- 15 **Trabeculae of spleen.** Trabeculae splenicae [lienales]. Connective tissue partitions penetrating into the spleen from the hilum and capsule and containing blood vessels. B
- 16 **Splenic pulp.** Pulpa splenica [lienalis]. It comprises white pulp (lymphoreticular tissue in form of arterial sheaths) and red pulp (venous sinuses with erythrocytes, reticular tissue). B
- 17 **Splenic sinus.** Sinus splenica [lienalis]. Thin-walled venous spaces with multiple anastomoses situated in the red pulp. B
- 18 **Splenic [lienal] branches.** Rami splenica [lienales]. Branches formed by the splenic artery before entering the spleen.
- 19 **Penicilli.** Brush-like arterial branches between the nodular arteries (in white pulp) and capillaries (or "sheathed capillaries"). B
- 20 **Lymphatic nodules (follicles) of spleen.** Foliculi lymphatici splenici [lienales] (lymphonoduli splenici). Spherical or cylindrical aggregations of lymphoreticular tissue around an artery (Malpighian corpuscle). They are visible to the naked eye. B
- 21 **NERVOUS SYSTEM.** Systema nervosum.
- 22 **MENINGES.** Connective tissue sheaths surrounding the central nervous system: dura mater, arachnoid and pia mater.
- 23 **Cranial dura mater [[Pachymeninx]].** Dura mater cranialis (encephali). Tough fibrous sheet forming a supporting capsule for the brain and at the same time forming the periosteum for the inner aspect of the skull. E
- 24 **Falx cerebri.** Sickle-shaped part of the dura projecting downward into the longitudinal cerebral fissure. C
- 25 **Tentorium cerebelli.** Dural sheet spreading out between the ridge of the petrous part of the temporal bone and the transverse sinus. It supports the occipital lobes. C
- 26 **Tentorial notch.** Incisura tentorii. Opening in the tentorium cerebelli for passage of the brainstem. C
- 27 **Falx cerebelli.** Small, sickle-shaped dural sheet between the right and left cerebellar hemispheres. C
- 28 **Diaphragma sellae.** Small horizontal sheet of dura spreading out between the clinoid processes above the hypophysis. C
- 29 **Cavitas trigeminalis (Cavum trigeminale).** Outpocketing of the dura enclosing the trigeminal ganglion. C
- 30 **Subdural space.** Spatium subdurale. Capillary space between the dura and arachnoid. It may be distended, for example, due to hemorrhage. E
- 31 **Spinal dura mater.** Dura mater spinalis. It is separated from the wall of the vertebral canal by an epidural space. D
- 32 **External filum terminale.** Filum terminale externum (durale). Filamentous end of the dura mater fused with the filum terminale. It extends from S2–3 to Co 2.
- 33 **Epidural space.** Spatium epidurale (peridurale). Space between the spinal dura mater and the wall of the vertebral canal. It is filled with fat and venous plexuses. D



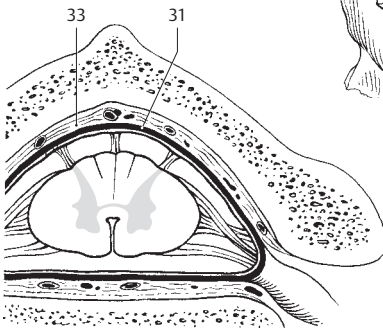
B Spleen, histologic section, schematic



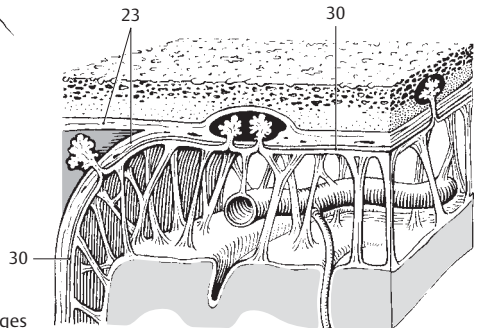
A Spleen



C Falx of cerebrum and tentorium of cerebellum



D Spinal meninges

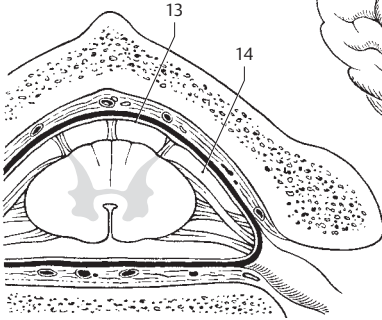


E Cranial meninges

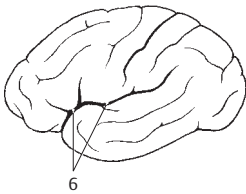
14

15

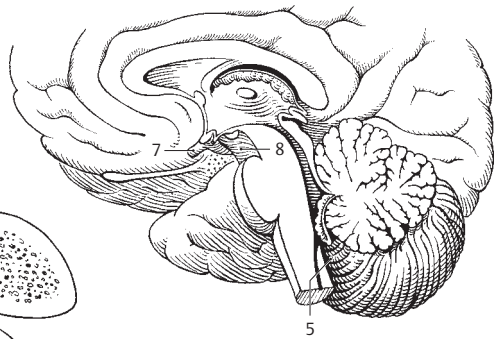
- 1 **Cranial arachnoid.** Arachnoidea mater cranialis (encephali). Thin, avascular membrane attaching to the cranial dura only by surface adhesion and communicating with the pia mater by connective tissue fibers. D
- 2 **Subarachnoid space.** Spatium sub-arachnoideum. Space between flat portion of arachnoid and pia mater. It is filled with arachnoidal connective tissue fibers and cerebrospinal fluid. D
- 3 **Cerebrospinal fluid.** Liquor cerebrospinalis. Protein-poor fluid secreted by the choroid plexus with a cell content of 2–6 per mm. It flows into the subarachnoid space through openings in the fourth ventricle.
- 4 **Subarachnoid cisterns.** Cisternae sub-arachnoideae. Expansions of the subarachnoid space containing cerebrospinal fluid.
- 5 **Cerebellomedullary cistern (cisterna magna).** Cisterna cerebellomedullaris (magna). Space between the cerebellum and medulla oblongata filled with cerebrospinal fluid. It communicates with the fourth ventricle by a median aperture. It is accessible through the foramen magnum. B
- 6 **Cisterna of lateral fossa of cerebrum.** Cisterna fossae lateralis cerebri. Space between the insula, temporal, frontal and parietal lobes. It is filled with cerebrospinal fluid and is accessible through the lateral sulcus. It contains branches of the middle cerebral and insular arteries. C
- 7 **Chiasmatic cistern.** Cisterna chiasmatica. Enlarged space around the optic chiasma filled with cerebrospinal fluid. B
- 8 **Interpeduncular cistern.** Cisterna interpeduncularis. Space situated behind the chiasmatic cistern and bordered laterally by the temporal lobe and the cerebral crura. It is filled with cerebrospinal fluid and contains the oculomotor nerve, branches of the basilar artery, the origin of the superior cerebellar artery and the posterior cerebral artery. B
- 9 **Ambient cistern.** Cisterna ambiens. Enlarged cerebrospinal fluid-filled space lateral to the cerebral crus. It contains the posterior cerebral artery, superior cerebellar artery, basal vein (Rosenthal's) and the trochlear nerve. F
- 10 **Cisterna pericallosa.** Space filled with cerebrospinal fluid along the corpus callosum. F
- 11 **Pontocerebellar cistern.** Cisterna pontocerebellaris. Expanded space in the cerebellopontine angle filled with cerebrospinal fluid. It communicates with the 4th ventricle by a lateral aperture. E
- 12 **Arachnoid granulations.** Granulationes arachnoideae. Avascular, villous-like outpocketings of the subarachnoid space into the sagittal sinus and diploic veins. They are more pronounced after the tenth year of life and are concerned in the excretion of cerebrospinal fluid. D
- 13 **Spinal arachnoid.** Arachnoidea mater spinalis. Thin avascular membrane attached to the dura mater by surface adhesion and to the pia mater by its connective tissue fibers. A
- 14 **Subarachnoid space.** Spatium sub-arachnoideum. Space between the flat part of the arachnoid and the pia mater. It is filled with arachnoidal connective tissue fibers and cerebrospinal fluid. A
- 15 **Cerebrospinal fluid.** Liquor cerebrospinalis. Fluid secreted predominantly by the choroid plexus. It is protein-poor and has a cell content of 2–6 per mm.



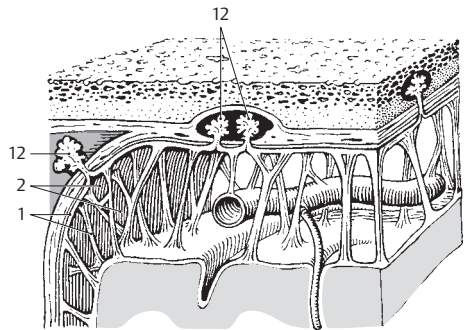
A Spinal meninges



C Cerebrum, lateral view

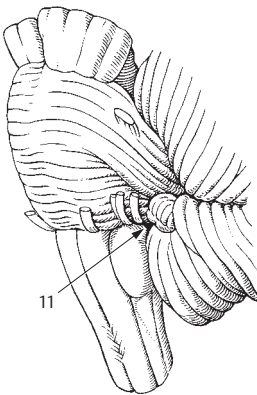


B Sagittal section with choroid plexus

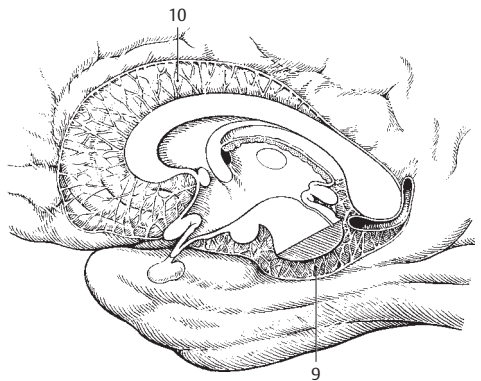


15

D Meninges

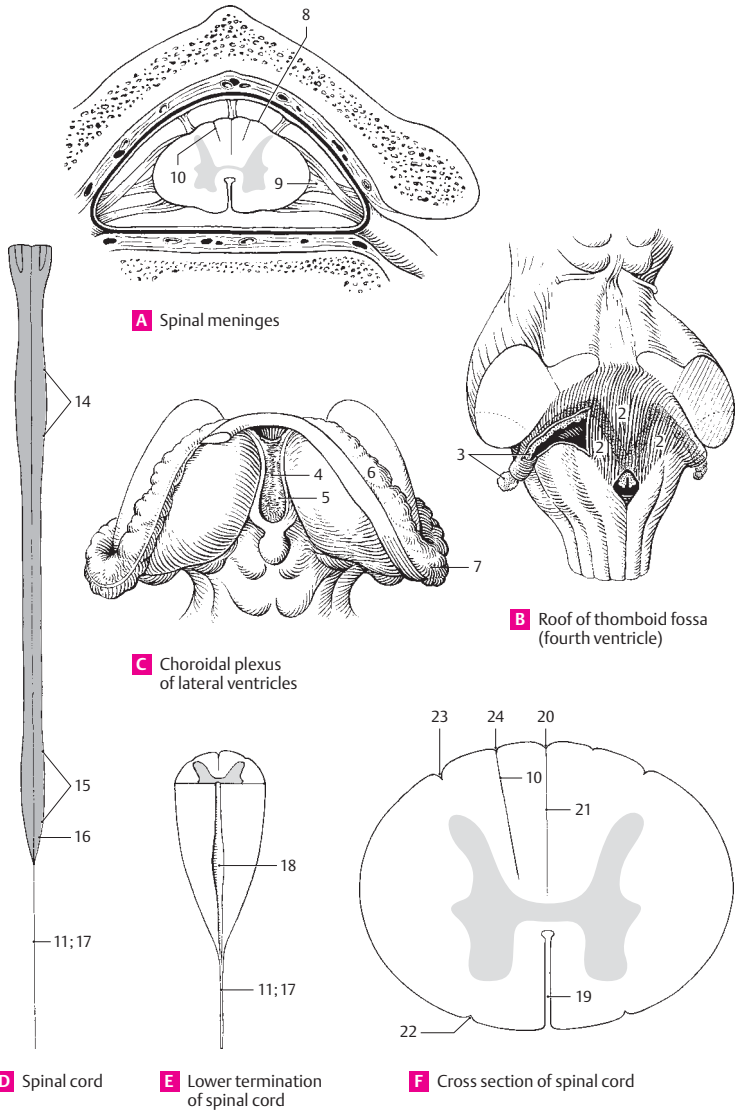


E Pontocerebellar cistern

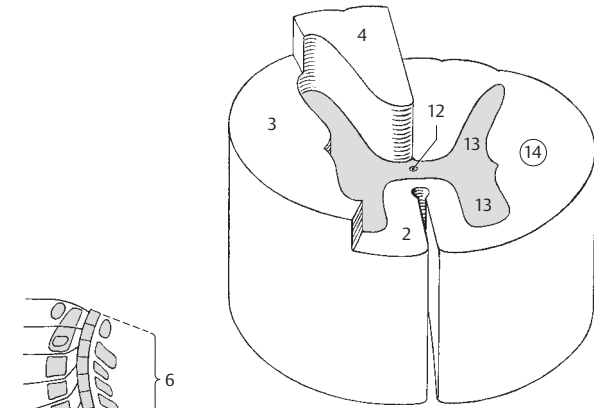


F System of cisterns in sagittal plane

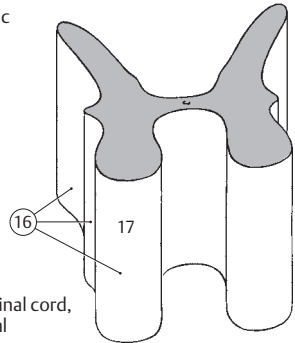
- 1 **Cranial pia mater.** Pia mater cranialis (encephali). Delicate meninx bearing blood vessels and covering the surface of the brain as well as extending into its sulci.
- 2 **Tela choroidea of fourth ventricle.** Tela choroidea ventriculi quarti. Thin membrane of pia mater and ependyma in lower part of roof of fourth ventricle. It is attached laterally to the tenia and exhibits lateral and median apertures. B
- 3 **Choroid plexus of fourth ventricle.** Plexus choroideus ventriculi quarti. Paired garland-like, ependyma-covered villous projections which extend into both lateral apertures. B
- 4 **Tela choroidea of third ventricle.** Tela choroidea ventriculi tertii. Thin, ependyma-covered membrane of pia mater between right and left teniae of thalamus. C
- 5 **Choroid plexus of third ventricle.** Plexus choroideus ventriculi tertii. Paired, highly vascularized villous formations projecting from the thin roof into the third ventricle and continuing anteriorly through the interventricular foramina into the choroid plexuses of the lateral ventricles. C
- 6 **Choroid plexus of lateral ventricle.** Plexus choroideus ventriculi lateralis. Villous, highly vascularized garland invaginated into the lateral ventricle through the choroid fissure. It extends from the interventricular foramen to the inferior horn. C
- 7 **Choroid glomus.** Glomus choroideum. Enlargement of the choroid plexus in the region of the collateral trigone at the root of the inferior horn. C
- 8 **Spinal pia mater.** Pia mater spinalis. Vascularized connective tissue membrane firmly united to the surface of the spinal cord. A
- 9 **Denticulate ligament.** Lig. denticulatum. Frontally situated connective tissue membrane connecting the spinal cord with the spinal dura mater. It has bow shaped recesses at the level of the spinal nerve roots. A
- 10 **Intermediate cervical septum.** Septum cervicale intermedium. Connective tissue partition in the cervical segment of the spinal cord between the gracilis and cuneatus fasciculi extending from the pia mater to the depths of the posterior funiculus. A F
- 11 **Internal filum terminale.** Filum terminale internum (piale). Filamentous, caudal extension of the spinal cord and pia mater contained in the external terminal ligament. D E
- 12 **CENTRAL NERVOUS SYSTEM.** Systema nervosum centrale. It comprises the brain and spinal cord.
- 13 **SPINAL CORD.** Medulla spinalis. Consists of the myelin-rich white matter and the myelin-poor gray matter. It extends from the caudal end of the medulla oblongata, near the exit of the first spinal nerves, to the beginning of the filum terminale at L1–2. A D
- 14 **Cervical enlargement.** Intumescentia cervicalis. Enlargement of the spinal cord from C3 to T2 owing to the larger supply region for the arms. D
- 15 **Lumbosacral enlargement.** Intumescentia lumbosacralis. Expansion of the spinal cord from T9–10 to L1–2 caused by the greater supply region for the lower limbs. D
- 16 **Conus medullaris.** Tapered termination of the spinal cord at the level of L1–2 where it becomes continuous with the filum terminale. D
- 17 **Filum terminale (spinale).** Thin terminal prolongation of spinal cord attached inferiorly to the posterior surface of the coccyx. D E
- 18 **Terminal ventricle.** Ventriculus terminalis. Enlargement of the central canal at the end of the conus medullaris. E
- 19 **Anterior median fissure.** Fissura mediana anterior. Deep longitudinal fissure along the anterior aspect of the spinal cord. F
- 20 **Posterior median sulcus.** Sulcus medianus posterior. Median longitudinal groove between the right and left posterior funiculi. F
- 21 **Posterior median septum.** Septum medianum posterius. Thickening of the subarachnoid connective tissue within the posterior median sulcus, less in the cervical region, more in the thoracic segment. F
- 22 **Anterolateral sulcus.** Sulcus anterolateralis. Shallow furrow occasionally present at the exit of the ventral root fibers. F
- 23 **Posterolateral sulcus.** Sulcus posterolateralis. Longitudinal groove external to the boundary between the lateral and posterior funiculi. It marks the site of entry of the dorsal spinal nerve roots. F
- 24 **Posterior intermediate sulcus.** Sulcus intermedius posterior. Shallow longitudinal fissure on both sides of the median sulcus. Externally it marks the boundary between the funiculi gracilis and cuneatus. F



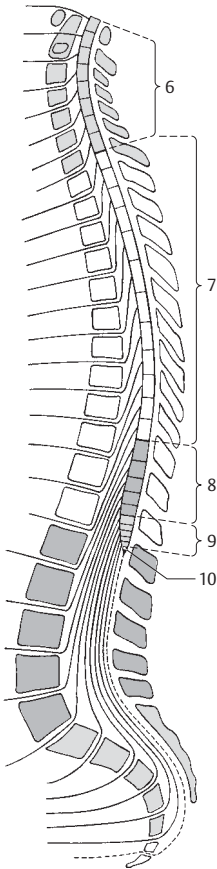
- 1 **Funiculi of spinal cord.** Funiculi medullae spinalis. Three columns of white matter segmented by the posterior and anterior horns and their root fibers.
- 2 **Anterior funiculus.** Funiculus anterior. Conduction bundle located between the anterior median fissure and the anterior horn with its root fibers. A
- 3 **Lateral funiculus.** Funiculus lateralis. Conduction bundle located lateral to the gray matter and between the posterior and anterior spinal nerve roots. A
- 4 **Posterior funiculus.** Funiculus posterior. Posterior column situated between the posterior horn with its root fibers and the posterior median septum. A
- 5 **Segments of spinal cord.** Segmenta medullae spinalis. Here, the spinal cord segments are defined as regions where root fibers pass through a specific intervertebral foramen. The boundaries are not determinable in the isolated spinal cord.
- 6 **Cervical segment.** Segmenta cervicalia [1–8] = pars cervicalis. Eight cervical segments represent the seven cervical vertebrae because the root fibers of segments 1–7 exit above the vertebrae of the same number. Root fibers of the 8th cervical segment, on the other hand, exit below C7. The cervical portion of the spinal cord extends from the atlas to the middle of C7. C
- 7 **Thoracic segment.** Segmenta thoracica [1–12] = pars thoracica. The 12 segments comprising this group extend from the middle of C7 to the middle of T11. C
- 8 **Lumbar segment.** Segmenta lumbaria [1–5] = pars lumbaris. Comprised of five segments; it extends from the middle of the body of T11 to the upper border of the body of L1. C
- 9 **Sacral segment.** Segmenta sacralia [1–5] = pars sacralis. These five sacral segments lie posterior to the body of L1. C
- 10 **Coccygeal segment.** Segmenta coccygea [1–3] = pars coccygea. Three quite small segments. C
- 11 **SPINAL CORD SECTIONS.** Sectiones medullae spinalis. These serve mostly as a foundation for description of the following parts.
- 12 **Central canal.** Canalis centralis. Obliterated remains of the embryonic neural tube lumen. It is usually located in the central intermediate substance (gray matter). A D
- 13 **Gray matter.** Substantia grisea. In transverse section, it is seen as an H-shaped column (columna grisea = gray column) consisting primarily of multipolar ganglion cells and enclosed by white matter. Sections of the spinal cord reveal that the "horns" (cornua) which correspond to the gray column S are characteristically different in the individual segments. A
- 14 **White matter.** Substantia alba. Consists of myelinated nerves and is organized into three cords (funiculi) which contain the nerve pathways. A
- 15 **Substantia gelatinosa centralis.** A narrow zone around the central canal with processes from ependymal cells.
- 16 **GRAY COLUMNS.** Columnae griseae. Three ridge-like columns of gray matter. B
- 17 **Anterior column.** Columna anterior. It is comprised predominantly of motor neurons (anterior horn cells). B
- 18 **Anterior horn.** Cornu anterius. Hook-shaped structure seen in transverse section of the spinal cord. D
- 19 **Anterolateral nucleus.** Nucleus anterolateralis. Situated anterolaterally in the anterior horn, it is localized in segments C4–8 and L2–S1 and innervates the muscles of the limbs. D
- 20 **Anteromedial nucleus.** Nucleus anteromedialis. From its anteromedial position in the anterior horn, it extends the entire length of the spinal cord. D
- 21 **Posterolateral nucleus.** Nucleus posterolateralis. It lies posterior to the anterolateral nucleus in segments C5–T1 and L2–S2 and innervates the muscles of the limbs. D
- 22 **Retroposterolateral nucleus.** Nucleus retroposterolateralis. It lies posterior to the posterolateral nucleus in segments C8–T1 and S1–3. D
- 23 **Posteromedial nucleus.** Nucleus posteromedialis. From the vicinity of the white matter, it extends over segments T1–L3 and probably innervates the trunk musculature. D
- 24 **Central nucleus.** Nucleus centralis. A less prominent group in several cervical and lumbar segments. D
- 25 **Nucleus of accessory nerve.** Nucleus nervi accessorii (nuc. accessorius). It lies in segments C1–6 in the area of the anterolateral nucleus and provides the root fibers of the spinal portion of the accessory nerve. D
- 26 **Nucleus of phrenic nerve.** Nucleus nervi phrenici (nuc. phrenicus). It lies in the middle of the anterior horn and extends from segments C4–C7. D



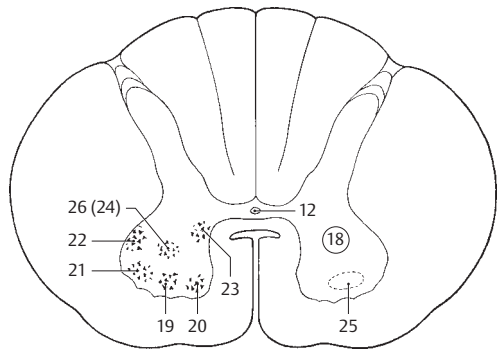
A Spinal cord, schematic



B Gray matter of spinal cord, three-dimensional



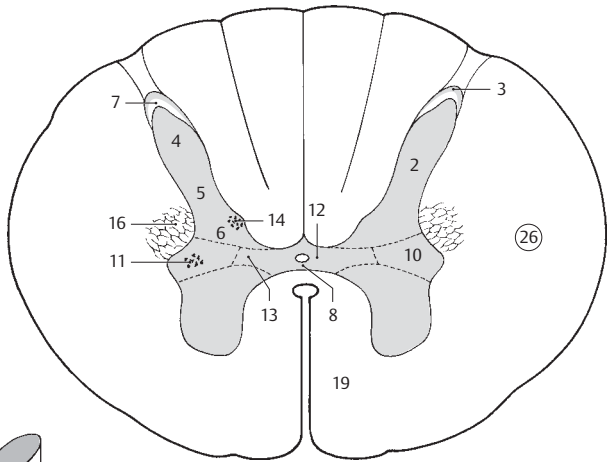
C Segments of spinal cord



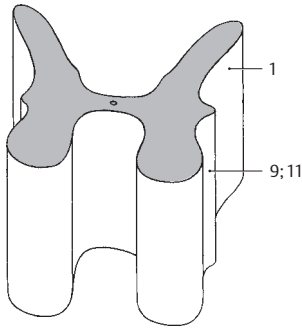
D Nuclei of spinal cord in anterior horn

16

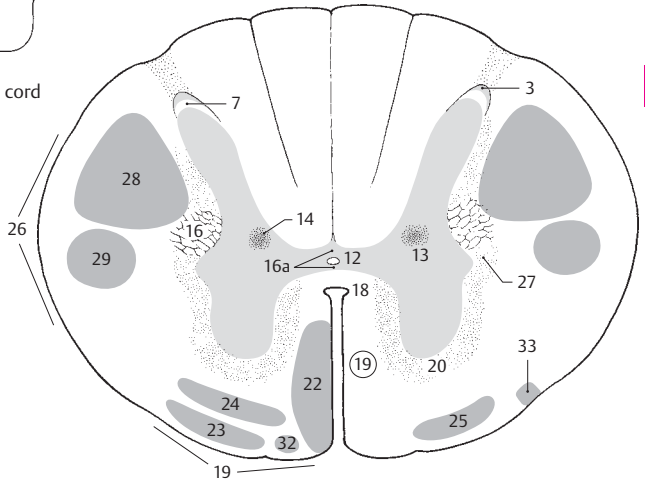
- 1 **Posterior column.** Columna posterior. It is composed primarily of sensory neurons. B
- 2 **Posterior horn.** Cornu posterius. Hook-shaped structure seen in transverse section of the spinal cord. A
- 3 **Apex.** Apical cap of posterior horn consisting of large nerve cells ventral to the substantia gelatinosa. A C
- 4 **Head.** Caput. Thickened middle part of posterior horn in the lower cervical and thoracic spinal cord. A
- 5 **Cervix.** Thinner segment of posterior horn between the head and base. A
- 6 **Base.** Basis. Broadened attachment of the posterior horn to the middle part of the gray matter. A
- 7 **Substantia gelatinosa.** Mobile, slightly glassy substance above the apex of the posterior horn. It consists primarily of glia and small ganglion cells. A C
- 8 **Secondary visceral substance.** Substantia visceralis secundaria. Small field of autonomic ganglion cells anterior to the central intermediate substance. A
- 9 **Lateral column.** Columna lateralis. Gray matter between the anterior and posterior horns. B
- 10 **Lateral horn.** Cornu laterale. Lateral prominence of gray matter. A
- 11 **Intermediolateral (autonomic) column.** Columna intermediolateralis (autonomica). Structure seen as the lateral horn in transverse section. It contains cells of the sympathetic nervous system and extends from T1–L2. A B
- 12 **Central intermediate gray matter.** Substantia [grisea] intermedia centralis. Ganglion cells at the central canal. A C
- 13 **Lateral intermediate gray matter.** Substantia [grisea] intermedia lateralis. Part of the sympathetic nervous system in the lateral horn. It extends from T1–L2. A C
- 14 **Thoracic column.** Columna thoracica (nuc. thoracicus) [[Stilling-Clarke]]. It lies at the base of the posterior horn and usually extends from C8–L2. It belongs partly to the posterior spinocerebellar tract. A C
- 15 **Sacral parasympathetic nuclei.** Nuclei parasympathici sacrales. Cells of the sacral parasympathetic nervous system in segments S2–4 situated between the anterior and posterior horns.
- 16 **Reticular formation.** Formatio reticularis. Net-like mixture of gray and white matter in the angle between the lateral and posterior horns. A C
- 16a **Anterior/posterior gray commissure.** Commissura grisea anterior/posterior. Gray matter situated in front of and behind the central canal. C
- 17 **WHITE MATTER.** Substantia alba. It consists primarily of myelinated nerve fibers.
- 18 **Anterior white commissure.** Commissura alba anterior. White matter with fibers crossing between the central intermediate gray matter and the anterior median commissure. C
- 18a **Posterior white commissure.** Commissura alba posterior. Individual fibers crossing into the posterior gray commissure.
- 19 **Anterior funiculus.** Funiculus anterior. Mass of white matter between anterior root fibers, anterior horn and anterior median fissure. A C
- 20 **Anterior fasciculi proprii.** Fasciculi proprii anteriores. Lying directly on the gray matter, these bundles comprise longer and shorter fibers involved in connecting individual segments of the spinal cord with one another. Reflex apparatus. C
- 21 **Sulcomarginal fasciculus.** Fasciculus sulcomarginalis. Fibers of the reflex apparatus located at the anterior median fissure.
- 22 **Anterior corticospinal (pyramidal) tract.** Tractus corticospinalis (pyramidalis) anterior. Uncrossed portion of pyramidal tract lateral to the anterior median fissure. C
- 23 **Vestibulospinal tract.** Tractus vestibulospinalis. Fibers in the anterior funiculus for impulses from the vestibular organ. C
- 24 **Reticulospinal tract.** Tractus reticulospinalis. Arising from the reticular formation of the brain stem, it forms a nondefinable tract in the middle of the anterior funiculus and ends in the anterior horn. C
- 25 **Anterior spinothalamic tract.** Tractus spinothalamicus anterior. Fibers ascending to the thalamus for pressure and tactile sensation. C
- 26 **Lateral funiculus.** Funiculus lateralis. It lies between the anterior and posterior horns together with their root fibers. A C
- 27 **Lateral fasciculi proprii.** Fasciculi proprii laterales. Shorter fibers on the gray matter for connection with individual spinal cord segments. C
- 28 **Lateral corticospinal (pyramidal) tract.** Tractus corticospinalis [pyramidalis] lateralis. Situated in front of the posterior horn. It transmits conscious motor impulses. C
- 29 **Rubrospinal tract.** Tractus rubrospinalis [[Monakow]]. It passes from the red nucleus to the anterior horn cells and lies in front of the lateral corticospinal tract. C
- 30 **Bulboreticulospinal tract.** Tractus bulboreticulospinalis. A tract the existence of which is controversial in man.
- 31 **Pontoreticulospinal tract.** Tractus pontoreticulospinalis. Likewise, a controversial tract in man.
- 32 **Tectospinal tract.** Tractus tectospinalis. Fibers in the anterolateral region of the anterior funiculus from the tectal lamina. They cross into the brain stem and terminate in the anterior horns. C
- 33 **Olivospinal tract.** Tractus olivospinalis. Present only in the cervical cord, its fibers pass from the olive region to the anterior root fibers. C



A Cross section of spinal cord



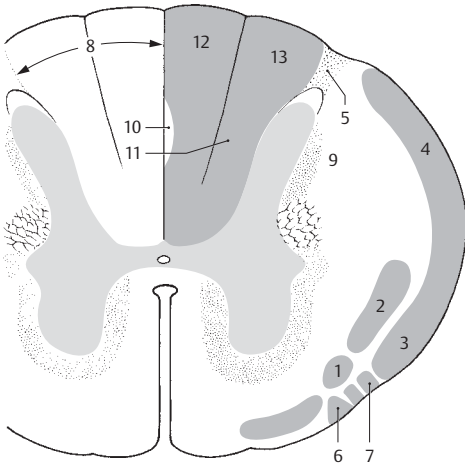
B Columns of spinal cord



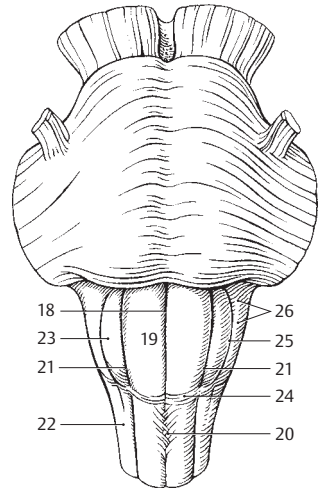
C Cross section of spinal cord with tracts

16

- 1 **Spinotectal tract.** Tractus spinotectalis. Its fibers arise from the posterior horn of the opposite side, run in the lateral spinothalamic tract and end in the tectal lamina. A
- 2 **Spinothalamic tract.** Tractus spinothalamicus. Lies in the lateral funicular and arises primarily from the opposite side. Its fibers transmit pain and temperature sensations. A
- 3 **Anterior spinocerebellar tract.** Tractus spinocerebellaris anterior [[Gowers]]. It extends partly from the opposite side and transmits to the cerebellum information necessary for the coordination of movements concerning muscle extension and limb position. A
- 4 **Posterior spinocerebellar tract.** Tractus spinocerebellaris posterior [[Flechsig]]. Its fibers are uncrossed and function similar to those of the anterior spinocerebellar tract. A
- 5 **Dorsolateral tract.** Tractus dorsolateralis [[Lissauer]]. Bundle of fine myelinated and nonmyelinated fibers between the apex of the posterior horn and the surface. The fibers are short and some form lateral branches of posterior root fibers. A
- 6 **Spino-olivary tract.** Tractus spino-olivaris [[Hellweg]]. Predominantly crossed fibers to the olive. They lie by the anterior root fibers together with the olivospinal tract. A
- 7 **Spinoreticular tract.** Tractus spinoreticularis. Its fibers lie beside the spino-olivary tract and end in the reticular substance of the medulla oblongata. A
- 8 **Posterior funiculus.** Funiculus posterior. White matter between the posterior horns. A
- 9 **Posterior fasciculi proprii.** Fasciculi proprii posteriores. They lie directly on the gray matter and unite individual spinal cord segments for coordinated activity.
- 10 **Septomarginal fasciculus.** Fasciculus septomarginalis. Bundle of mostly descending fibers situated along the posterior median septum in the lower half of the thoracic spinal cord. A
- 11 **Interfascicular fasciculus.** Fasciculus interfascicularis. Bundle of mostly descending fibers [comma tract of Schultze] located chiefly in the upper half of the thoracic spinal cord between the fasciculi gracilis and cuneatus. A
- 12 **Fasciculus gracilis** [[Goll]]. Medial fasciculus that contains fibers from the lower half of the spinal cord which function in the transmission of tactile and proprioceptive sensory information. A
- 13 **Fasciculus cuneatus** [[Burdach]]. It begins with the upper half of the thoracic cord and likewise contains fibers for transmission of tactile and proprioceptive impulses. A
- 14 **BRAIN.** Encephalon.
- 15 **BRAINSTEM.** Truncus encephali. It extends from the medulla oblongata to the midbrain. According to some, the diencephalon and insula likewise belong to the brainstem.
- 16 **HINDBRAIN.** Rhombencephalon. It includes the brain substance around the rhomboid fossa, thus the cerebellum, pons with dorsally attached substance and medulla oblongata. B
- 17 **MEDULLA OBLONGATA (BULBUS).** Beginning at the lower margin of the pons, it extends up to the root fibers of C1. In the rhomboid fossa it arises from the medullary striae of the 4th ventricle. B
- 18 **Anterior median fissure.** Fissura mediana anterior. Anterior groove continuous with that of the spinal cord. The pyramidal decussation crosses over it. C
- 19 **Pyramid.** Pyramis [medullae oblongatae]. Longitudinal elevation of pyramidal tract fibers to the right and left of the anterior median fissure. It ends with the pyramidal decussation. C
- 20 **Pyramidal decussation.** Decussatio pyramidum (dec. pyramidalis anterior motoria). 3–5 bundles of lateral pyramidal tract fibers crossing to the opposite side at the end of the medulla. C
- 21 **Anterolateral sulcus.** Sulcus anterolateralis. Furrow lateral to the pyramid for transmission of the hypoglossal nerve. C
- 22 **Lateral funiculus.** Funiculus lateralis. Continuation of the lateral funiculus of the spinal cord up to the olive. C
- 23 **Olive.** Oliva. Bean-shaped prominence about 1.5 cm long between the roots of cranial nerves X and XII. It is produced by the nuclei lying beneath it. C
- 24 **Anterior external arcuate fibers.** Fibrae arcuatae externae anteriores. Fibers from the arcuate nucleus coursing over the caudal end of the olive to the caudal cerebellar peduncle. Part of the pontocerebellar tract. C
- 25 **Retro-olivary sulcus.** Sulcus retro-olivaris. Furrow behind the olive. C
- 26 **Retro-olivary area.** Area retro-olivaris. Area behind the olive. C



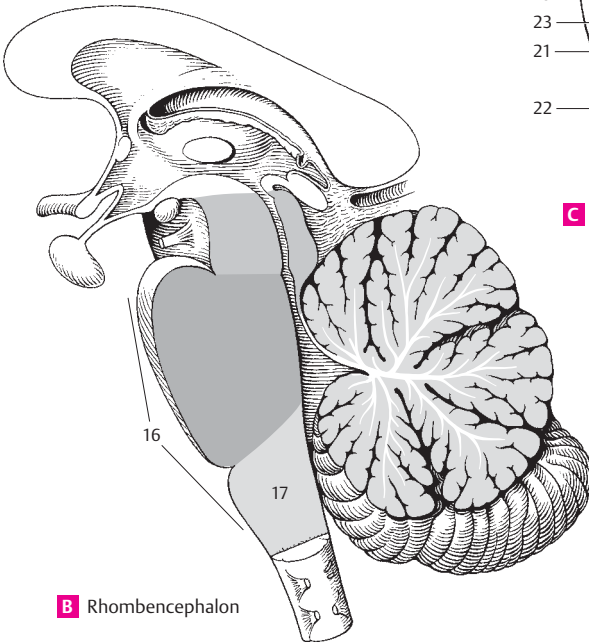
A Cross section of spinal cord



C Medulla oblongata from above

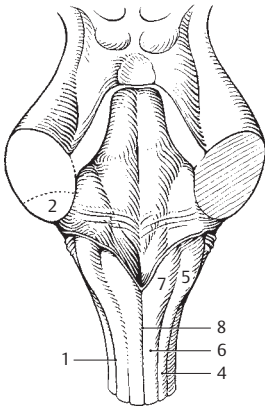
16

17

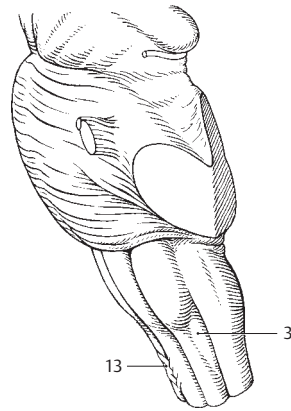


B Rhombencephalon

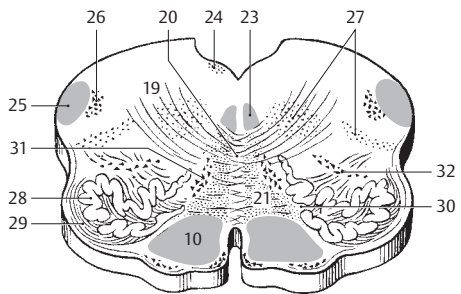
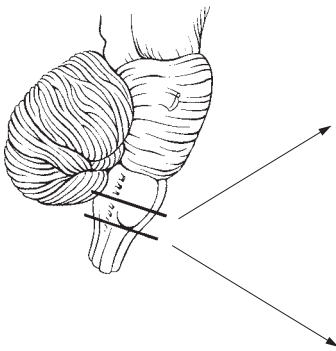
- 1 **Posterolateral sulcus.** Sulcus posterolateralis. Furrow reaching up to the lateral recess of the 4th ventricle. Site of exit of cranial nerves IX, X and XI. A
- 2 **Inferior cerebellar peduncle.** Pedunculus cerebellaris inferior. Inferior connection to the cerebellum with fibers of the posterior spinocerebellar tract and olive. A
- 3 **Trigeminal tubercle (tuber cinereum).** Tuberculum trigeminale. Low lateral elevation above the spinal tract of the trigeminal nerve. B
- 4 **Cuneate fasciculus.** Fasciculus cuneatus. Lateral part of posterior funiculus coming from the upper half of the body. A
- 5 **Cuneate tubercle.** Tuberculum cuneatum. Oblong prominence at the end of the cuneate fasciculus produced by the nucleus cuneatus. A
- 6 **Fasciculus gracilis.** Medial part of posterior funiculus coming from the lower half of the body. A
- 7 **Gracile tubercle (clava).** Tuberculum gracile. Oblong bulge over the nucleus gracilis. A
- 8 **Posterior median sulcus.** Sulcus medianus posterior. Posterior furrow continued from the spinal cord and closed above by a medullary lamella (obex). A
- 9 **Sections through the medulla oblongata.** Sectiones medullae oblongatae.
- 10 **Pyramidal fasciculus (tract).** Fasciculus pyramidalis. Nerve tract for the transmission of impulses concerned with conscious movements. C D
- 11 **Corticospinal fibers.** Fibrae corticospinales. Fibers from the precentral gyrus of the cortex to the anterior horn cells of the spinal cord.
- 12 **Corticonuclear fibers.** Fibrae corticonucleares. Fibers from the precentral gyrus of the cortex to the motor nuclei of cranial nerves.
- 13 **Decussation of the pyramids.** Decussatio pyramidum (dec. motoria). Fibers of the lateral pyramidal tract with 3–5 bundles crossing at the end of the medulla oblongata. B
- 14 **Fasciculus gracilis.** Medial part of posterior funiculus coming from the lower half of the body.
- 15 **Nucleus gracilis.** Nucleus of fasciculus gracilis medial to cuneate nucleus. D
- 16 **Cuneate fasciculus.** Fasciculus cuneatus. Lateral part of posterior funiculus coming from the upper half of the body.
- 17 **Cuneate nucleus.** Nucleus cuneatus. Nucleus of fasciculus cuneatus lateral to the nucleus gracilis. D
- 18 **Accessory cuneate nucleus.** Nucleus cuneatus accessorius. Gray matter lateral to the upper part of cuneate nucleus. Origin of external arcuate fibers which pass to the cerebellum. D
- 19 **Internal arcuate fibers.** Fibrae arcuatae internae. Fiber component of the medial lemniscus arising from the nucleus of the posterior funiculus. C
- 20 **Decussation of medial lemniscus.** Decussatio lemniscorum medialium (d. sensoria). Formed by fibers of nuclei gracilis and cuneatus, second order neurons of posterior funiculus. C D
- 21 **Medial lemniscus.** Lemniscus medialis. Continuation of second order neuron of posterior funiculus after decussation of lemniscus [bulbothalamic tract]. D
- 22 **Tectospinal tract.** Tractus tectospinalis. Decussated connection between the quadrigeminal plate and the spinal cord. It lies between the facial and trigeminal nuclei. D
- 23 **Medial longitudinal fasciculus.** Fasciculus longitudinalis medialis. Nerve fiber bundle for reciprocal connection to the motor nuclei of ocular muscles, as well as vestibular, accessory and cervical muscle nuclei. C
- 24 **Posterior longitudinal fasciculus.** Fasciculus longitudinalis posterior [Schütz]. Connection between the hypothalamus, III, VII, XII cranial nerve nuclei, nucleus ambiguus, tractus solitarius and tractus salvatorius in the floor of the rhomboid fossa. C
- 25 **Spinal tract of trigeminal nerve.** Tractus spinalis nervi trigeminalis. Descending fibers of the trigeminal nerve for transmission of pain and temperature stimuli. C D
- 26 **Spinal nucleus of trigeminal nerve.** Nucleus spinalis nervi trigeminalis. Continuous with the substantia gelatinosa in the spinal cord; this nucleus receives the fibers of the spinal tract of the trigeminal nerve. C D
- 27 **Reticular formation (substance).** Formatio (substantia) reticularis. Cells lying scattered in the tegmentum in the vicinity of the vagus, vestibular and facial nuclei with a regulatory effect on the muscles of the pharyngeal arch and other muscles of the body. It extends cranially and caudally. C
- 28 **Inferior olivary nucleus.** Nucleus olivaris inferior. Main olivary nucleus lying below the olive. It is shaped like a thick-walled pouch that opens medially and is connected with the spinal cord and cerebellum. C
- 29 **Amiculum of the olive.** Amiculum olivare. Fibrous sheath that surrounds and contains afferent and efferent fibers of the olivary nucleus. C
- 30 **Hilum of inferior olivary nucleus.** Hilum nuclei olivaris inferioris. Opening of the medially oriented pouch-like olivary nucleus. C
- 31 **Medial accessory olivary nucleus.** Nucleus olivaris accessorius medialis. It is located in front of the hilum of the olivary nucleus. C
- 32 **Posterior accessory olivary nucleus.** Nucleus olivaris accessorius posterior. It is situated between the olive and reticular formation. C



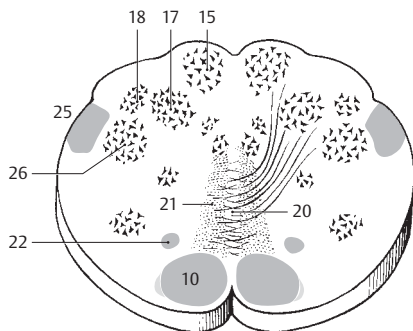
A Rhomboid fossa



B Pons and medulla oblongata

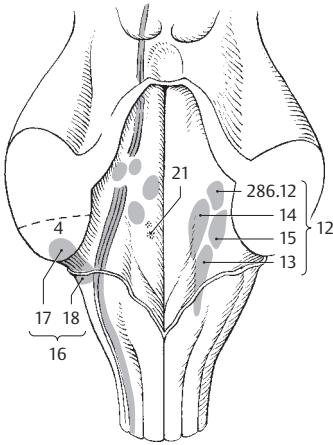


C Section through medulla oblongata

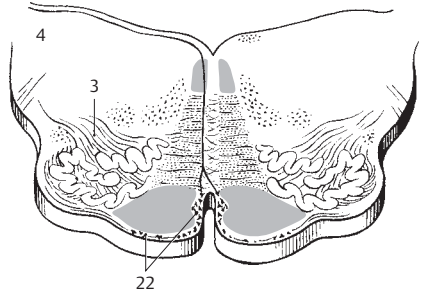


D Section through medulla oblongata

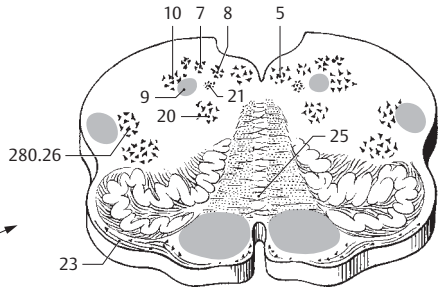
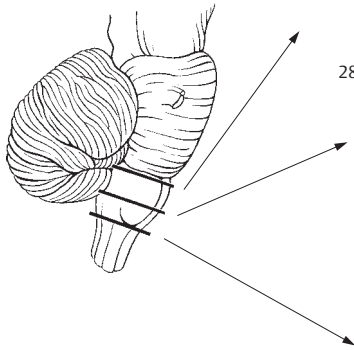
- 1 **Olivospinal tract.** Tractus olivospinalis. Extrapyramidal tract limited to the cervical cord. It influences head and hand movements. D
- 2 **Spino-olivary tract.** Tractus spino-olivaris. Tract that extends throughout the entire spinal cord and provides information for the olive, partly for its own needs, partly for those of the cerebellum. D
- 3 **Olivocerebellar tract.** Tractus olivocerebellaris. It passes through the inferior cerebellar peduncle from the olive to the cerebellum. B
- 4 **Inferior cerebellar peduncle.** Pedunculus cerebellaris inferior. Inferior connection to the cerebellum without a sharply defined boundary from the middle cerebellar peduncle. It contains fibers primarily from the spinocerebellar tract and olive. A B
- 5 **Nucleus of hypoglossal nerve (hypoglossal nucleus).** Nucleus nerve hypoglossi (nucleus hypoglossalis). It is located below the floor of the lower rhomboid fossa. C D
- 6 **Posterior paramedian nucleus.** Nucleus paramedianus posterior. Cell group in the vicinity of the hypoglossal nucleus that communicate with the reticular formation.
- 7 **Dorsal nucleus of vagus nerve (dorsal vagal nucleus).** Nucleus dorsalis nervi vagi (nucleus vagalis dorsalis). Autonomic and sensory cell group located lateral and caudal to the hypoglossal nucleus. C D
- 8 **Nucleus intercalatus.** Nuclear group of unknown function situated between the nucleus of the hypoglossal nerve and the dorsal nucleus of the vagus. C
- 9 **Tractus solitarius.** Taste fibers of cranial nerves V, VII, IX and X for the nucleus of the tractus solitarius. C
- 10 **Nucleus solitarius.** Row of cells for the tractus solitarius extending from the middle of the rhomboid fossa to the decussation of the pyramids. C
- 11 **Nucleus parasolitarius.** Dispersed cells ventrolateral to the nucleus solitarius with no known function.
- 12 **Vestibular nuclei.** Nuclei vestibulares. Four terminal nuclei of the vestibular division. They have projections to the spinal cord, cerebellum and medial longitudinal fasciculus. A
- 13 **Inferior vestibular nucleus.** Nucleus vestibularis inferior. Oblong nuclear group lying laterally beneath the medial nucleus with projections to the cerebellum and medial longitudinal fasciculus. A
- 14 **Medial vestibular nucleus.** Nucleus vestibularis medialis. Group of nuclei lateral to the limiting sulcus with fibers of origin for the medial longitudinal fasciculus of both sides. A
- 15 **Lateral vestibular nucleus.** Nucleus vestibularis lateralis. Smaller group of nuclei located toward the lateral recess with projections to the anterior horn of the spinal cord. A
- 16 **Cochlear nuclei.** Nuclei cochleares. Mass of nerve cells situated below the lateral recess of the 4th ventricle, where it may form a slight elevation, the tuberculum acusticum. A
- 17 **Anterior cochlear nucleus.** Nucleus cochlearis anterior. Its fibers pass to the opposite side primarily via the trapezoid body and join the lateral lemniscus. A
- 18 **Posterior cochlear nucleus.** Nucleus cochlearis posterior. Its fibers pass mostly to the midline just beneath the floor of the rhomboid fossa, where they penetrate deeply in order to join the trapezoid body. A
- 19 **Commissural nucleus.** Nucleus commissuralis. Little-known nucleus in the medulla oblongata.
- 20 **Nucleus ambiguus.** Nucleus of origin for cranial nerves IX and X as well as the cranial portion of XI. It is located behind the olive. C D
- 21 **Inferior salivary nucleus.** Nucleus salivarius inferior. Autonomic nucleus for the parasympathetic fibers of the glossopharyngeal nerve. A C
- 22 **Arculate nucleus.** Nucleus arcuati. Located in front of and medial to the pyramidal tract. This group of nuclear cells gives origin to the external arcuate fibers. It corresponds to caudally displaced pontine nuclei. B
- 23 **Anterior external arcuate fibers.** Fibrae arcuatae externae anteriores. Fibers from the arcuate nucleus which pass externally around and transversely across the olive into the cerebellar peduncles. C
- 24 **Posterior external arcuate fibers.** Fibrae arcuatae externae posteriores. Fibers which pass uncrossed from the lateral part of the arcuate nucleus to the inferior cerebellar peduncle. They replace the posterior spinocerebellar tract for the region above C8. The thoracic nucleus is absent here. D
- 25 **Raphe of medulla oblongata.** Raphe medullae oblongatae. Median line in the decussation of the lemniscus. C
- 26 **Nuclei raphae.** Cells of the reticular structure located near the median plane.



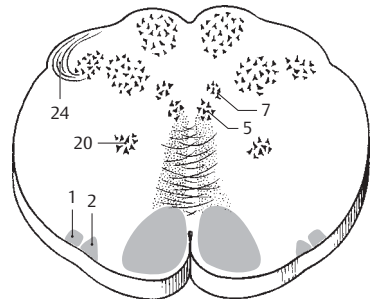
A Nuclei of thombencephalon from behind



B Section through medulla oblongata

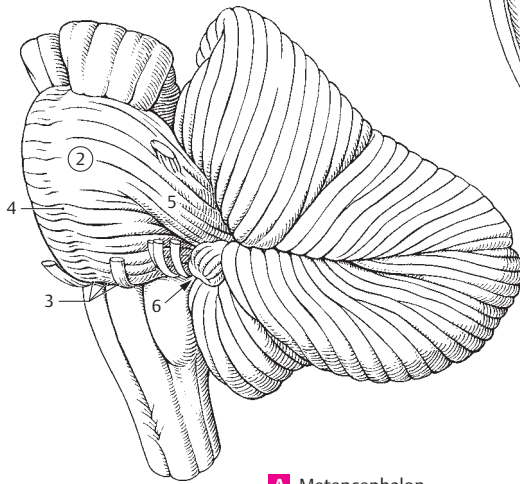


C Section through medulla oblongata

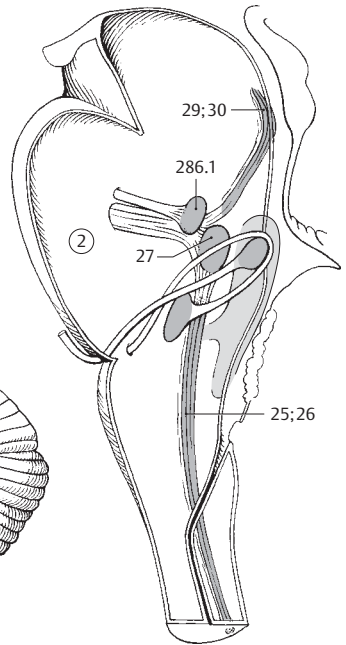


D Section through medulla oblongata

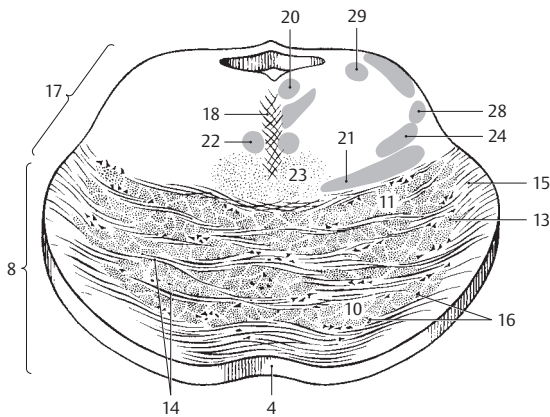
- 1 **METENCEPHALON.** Part of the rhombencephalon consisting of the pons, cerebellum and tegmentum.
- 2 **PONS.** Located between the interpeduncular fossa and pyramids. It consists mostly of crossing fibers and cells of the cerebral, pontine and cerebellar tracts. A B
- 3 **Bulbopontine (pontobulbar) sulcus.** Sulcus bulbopontines. Limiting furrow between the inferior margins of the medulla oblongata and pons. Site of exit of cranial nerves VI, VII and VIII. A
- 4 **Basilar sulcus of pons.** Sulcus basilaris. Median groove produced by the pyramidal tract fibers situated to the right and left of the midline. It is occupied by the basilar artery. A C
- 5 **Middle (pontine) cerebellar peduncle.** Pedunculus cerebellaris medius (pontinus). Thick middle peduncle containing the pontocerebellar tract. A
- 6 **Pontocerebellar trigone.** Trigonum pontocerebellare. Clinically important angle between the pons, medulla oblongata and cerebellum. A
- 7 **SECTIONS OF PONS.** Secciones pontis.
- 8 **Anterior (basilar) part of pons.** Pars anterior (basilaris) pontis. Portion of pons consisting mainly of fibers of the cerebropontocerebellar tract. C
- 9 **Longitudinal pontine fibers.** Fibrae pontis longitudinales. Longitudinally coursing tracts of fibers described below.
- 10 **Corticospinal fibers.** Fibrae corticospinales. Part of the pyramidal tract passing into the spinal cord. C
- 11 **Corticonuclear (corticobulbar) fibers.** Fibrae corticonucleares. Fibers of the pyramidal tract passing to the motor nuclei of cranial nerves. C
- 12 **Corticoreticular fibers.** Fibrae corticoreticulares. Fibers passing from the cerebral cortex to the reticular formation.
- 13 **Corticopontine fibers.** Fibrae corticopontinae. Fibers extending to the pontine nuclei from the frontal, occipital and temporal lobes. C
- 14 **Transverse pontine fibers.** Fibrae pontis transversae. Transversely coursing fibers of the cerebropontocerebellar tract. C
- 15 **Pontocerebellar fibers.** Fibrae pontocerebellares. Fibers of the pontocerebellar tract passing from the pons to the cerebellum. C
- 16 **Pontine nuclei.** Nuclei pontis. Intercalary cells of the cerebropontocerebellar tract situated in the ventral part of the pons. C
- 17 **Posterior part of pons (tegmentum of pons).** Pars posterior pontis (tegmentum pontis). Part of pons situated between the 4th ventricle and the transverse pontine fibers. C
- 18 **Pontine raphe.** Raphe pontis. Fibers from the trigeminal nucleus forming the midline of the pons. C
- 19 **Medial longitudinal fasciculus.** Fasciculus longitudinalis medialis. Tract that connects the nuclei of the ocular and neck muscles on one side and the vestibular organ on the other. C
- 20 **Posterior longitudinal fasciculus.** Fasciculus longitudinalis posterior [Schütz]. Reciprocal connections between the hypothalamus and the nuclei of cranial nerves III, V, VII, X; XII, the nucleus ambiguus, and the tractus solitarius and salivatorius in the mesencephalic central gray region. C
- 21 **Medial lemniscus.** Lemniscus medialis. Decussating connection between the nuclei of the posterior funiculus and the thalamus located mainly medially but also laterally. C
- 22 **Tectospinal (spinotectal) tract.** Tractus tectospinalis. It begins in the superior colliculus, crosses the opposite side and then lies ventral to the medial longitudinal fasciculus. It is concerned with optic reflexes. C
- 23 **Reticular formation.** Formatio reticularis. Located in the posterior part of the pons; this long group of cells is permeated by nerve fibers and continues anterosuperiorly and caudally. It is concerned with the integration of visceral and muscular functions. C
- 24 **Spinal lemniscus.** Lemniscus spinalis. Cranial continuation of the lateral and anterior spinothalamic tracts. C
- 25 **Spinal tract of trigeminal nerve.** Tractus spinalis nervi trigeminalis. Trigeminal fibers descending as far as C4 to join the nucleus of the spinal tract of the trigeminal nerve. B
- 26 **Spinal (inferior) nucleus of trigeminal nerve.** Nucleus spinalis (inferior) nervi trigeminalis. Nucleus belonging to the spinal tract of the trigeminal nerve. B
- 27 **Pontine nucleus of trigeminal nerve.** Nucleus pontinus nervi trigeminalis. Main nucleus of trigeminal serving primarily for the sense of touch. B
- 28 **Trigeminal lemniscus (trigeminohalamic tract).** Lemniscus trigeminalis (tractus trigeminohalamicus). Crossed fibers of the trigeminal nucleus extending to the thalamus. C
- 29 **Mesencephalic tract of trigeminal nerve.** Tractus mesencephalicus nervi trigeminalis (tractus mesencephalicus trigeminalis). Trigeminal fibers for the nucleus of the trigeminal nerve tract located lateral to the cerebral aqueduct and in the lateral part of the arch to the 4th ventricle. B C
- 30 **Mesencephalic nucleus of trigeminal nerve.** Nucleus mesencephalicus nervi trigeminalis [nucleus mesencephalicus trigeminalis]. Upper sensory nucleus extending to the area below the tectal lamina. B



A Metencephalon

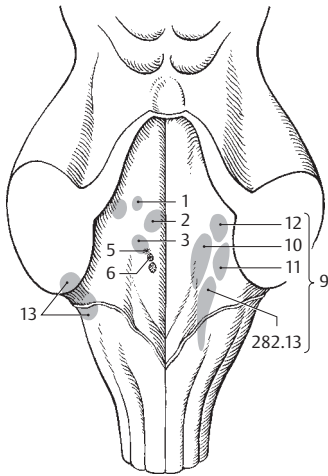


B Nuclei of rhombencephalon
medial view

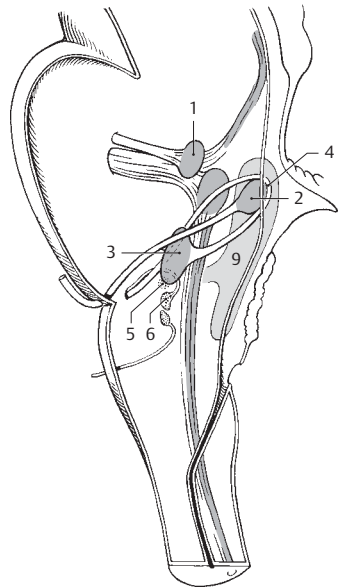


C Cross-section through pons

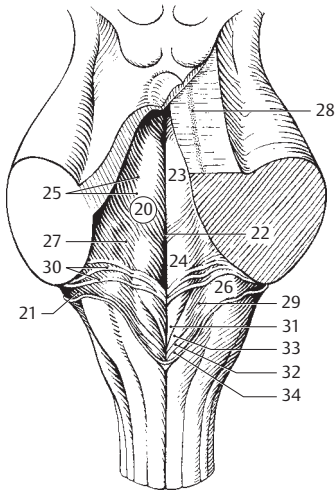
- 1 **Motor nucleus of trigeminal nerve.** Nucleus motorius nervi trigeminalis [nucleus motorius trigeminalis]. It is located near the exit of the trigeminal nerve. A B
- 2 **Nucleus of abducens nerve.** Nucleus nervi abducentis [nucleus abducens]. It is found beneath the facial colliculus. A B
- 3 **Nucleus of facial nerve.** Nucleus nervi facialis [nucleus facialis]. This motor nucleus lies laterally below the nucleus of the abducens. A B
- 4 **Genu of facial nerve.** Genu nervi facialis. Arch formed by fibers of facial nerve below the facial colliculus and above the nucleus of the abducens. B
- 5 **Superior salivary (salivatory) nucleus.** Nucleus salivarius superior. Autonomic nucleus for the parasympathetic fibers of the facial nerve. It supplies preganglionic fibers for the pterygopalatine and submandibular ganglia. A B
- 6 **Lacrimal nucleus.** Nucleus lacrimalis. Autonomic cells lying beside the superior salivary nucleus for the control of lacrimal secretion. A B
- 7 **Superior olivary nucleus.** Nucleus olivaris superioris. It lies lateral to the trapezoid body, contains fibers from the cochlear nuclei and integrates hearing via the olivocochlear tract. D
- 8 **Olivocochlear tract.** Tractus olivocochlearis. Tract from the superior olivary nucleus to the hair cells of the ear.
- 9 **Vestibular nuclei.** Nuclei vestibulares. Four terminal nuclei of the vestibular division with projections to the spinal cord, cerebellum and medial longitudinal fasciculus. A B
- 10 **Medial vestibular nucleus.** Nucleus vestibularis medialis. Nucleus of nerve cells that lies lateral to the sulcus limitans and gives attachment to the medial longitudinal fasciculus of both sides. A D
- 11 **Lateral vestibular nucleus.** Nucleus vestibularis lateralis. Smaller nucleus of nerve cells situated near the lateral recess with projections to the anterior horn of the spinal cord. A D
- 12 **Superior vestibular nucleus.** Nucleus vestibularis superior. Nucleus located above the lateral nucleus with projections to the medial longitudinal fasciculus and cerebellum. A D
- 13 **Cochlear nuclei.** Nuclei cochleares. Dorsal and ventral terminal nuclei of the cochlear division of the vestibulocochlear nerve. Both lie below the lateral recess. A D
- 14 **Trapezoid body.** Corpus trapezoideum. Mass of fibers arising from the cochlear nuclei that forms part of the auditory pathway. D
- 15 **Anterior nucleus of trapezoid body.** Nucleus corporis trapezoidei anterior. Smaller nucleus situated posterolaterally in the trapezoid body. D
- 16 **Posterior nucleus of trapezoid body.** Nucleus corporis trapezoidei posterior. It lies behind the anterior nucleus. D
- 17 **Lateral lemniscus.** Lemniscus lateralis. Ascending continuation of the trapezoid body. Part of the hearing pathway. D
- 18 **Nucleus of lateral lemniscus.** Nuclei lemnisci lateralis. Ganglion cells interspersed in the lateral lemniscus.
- 19 **Fourth ventricle.** Ventriculus quartus. Dilatation of the lumen of the embryonic neural tube in the rhombencephalon. D
- 20 **Rhomboid fossa.** Fossa rhomboidea. Floor of 4th ventricle. A C
- 21 **Lateral recess.** Recessus lateralis. Lateral corner of the 4th ventricle ending with the lateral aperture. C D
- 22 **Median sulcus.** Sulcus medianus. Median furrow passing through the rhomboid fossa. C
- 23 **Medial eminence.** Eminentia medialis. Oblong elevation located between the median sulcus and the sulcus limitans. C
- 24 **Facial colliculus.** Colliculus facialis. Prominence above the medullary striae produced by the genu of the facial nerve and the nucleus of the abducens nerve. C
- 25 **Limiting sulcus.** Sulcus limitans. Shallow furrow situated lateral to the medial eminence. C
- 26 **Vestibular area.** Area vestibularis. Field above the vestibular nuclei and lateral to the limiting sulcus at the beginning of the lateral recess. C
- 27 **Superior fovea.** Fovea superior. Pit situated lateral to the facial colliculus. C
- 28 **Locus ceruleus.** Locus caeruleus. Elongated group of bluish cells located in the lateral wall of the 4th ventricle and under it. C
- 29 **Inferior fovea.** Fovea inferior. Pit at the apex of the trigone of the vagus nerve. C
- 30 **Medullary striae.** Striae medullares. Strongly myelinated transverse nerve bundles from the arcuate nucleus to the cerebellum. C
- 31 **Trigone of hypoglossal nerve.** Trigonum nervi hypoglossi (t. hypoglossale). Triangular bulge over the nucleus of the hypoglossal nerve located between the median sulcus and the sulcus limitans. C
- 32 **Funiculus separans.** Transparent strip of ependyma between the trigone of the vagus nerve and the area postrema. C
- 33 **Trigone of vagus nerve.** Trigonum nervi vagi (t. vagale). Triangle over the dorsal nucleus of the vagus nerve caudal to the trigone of hypoglossal nerve. C
- 34 **Area postrema.** A triangular field caudal to the trigone of the vagus with highly vascularized, glia-rich tissue. C



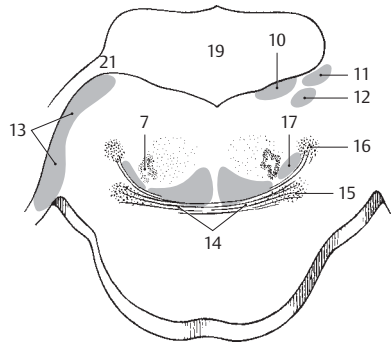
A Rhomboid fossa



B Nuclei of rhombencephalon
medial view

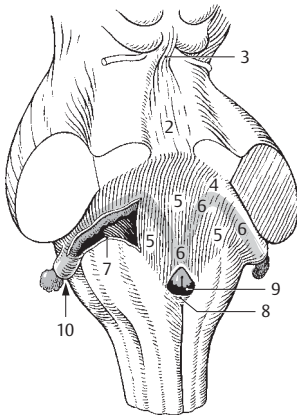


C Rhomboid fossa

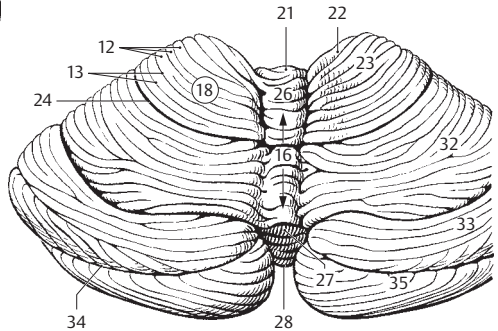


D Cross section through rhomboid fossa
at level of lateral recess

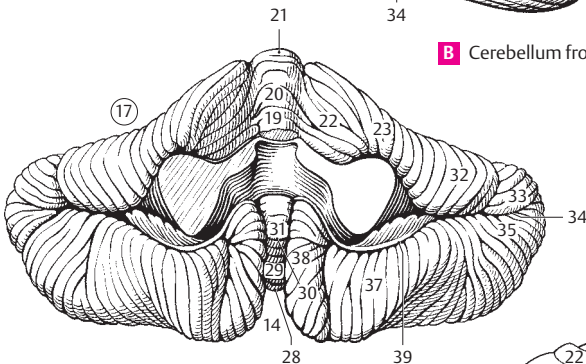
- 1 **Tegmen of fourth ventricle.** Tegmen ventriculi quarti. Roof of 4th ventricle. A
- 2 **Superior medullary velum.** Velum medullare superius. Lamina of white matter spread out between the right and left superior cerebellar peduncles. It is fused with the lingula of the cerebellum. A
- 3 **Frenulum of superior medullary velum.** Frenulum veli medullaris superioris. Band-like ridge from the superior medullary velum to the tectal lamina. A
- 4 **Inferior medullary velum.** Velum medullare inferius. Plate of white matter in the upper part of the lower roof of the rhomboid fossa. It is fused with the peduncle of the flocculus and the nodulus of the cerebellum. A
- 5 **Tela choroidea of fourth ventricle [ventriculi quarti].** Clear pia mater carrying the choroid plexus and stretched between the inferior medullary velum and tenia of the fourth ventricle. A
- 6 **Choroid plexus of fourth ventricle.** Plexus choroideus [ventriculi quarti]. Paired, garland-like ependyma-covered, highly vascularized tufted projection which extends into the two lateral apertures. A
- 7 **Tenia of fourth ventricle.** Taenia [ventriculi quarti]. Ridge on lower portion of roof of rhomboid fossa. A
- 8 **Obex.** Small bridge at lower end of rhomboid fossa. A
- 9 **Median aperture of fourth ventricle [foramen of Magendie].** Apertura mediana [ventriculi quarti] [Magendie]. Unpaired opening directly above the obex for passage of cerebrospinal fluid. A
- 10 **Lateral aperture of fourth ventricle [foramen of Luschka].** Apertura lateralis [ventriculi quarti] [[Luschkae]]. Opening for passage of cerebrospinal fluid located at the end of the right and left lateral recesses. A
- 11 **CEREBELLUM.** It is located above the rhomboid fossa.
- 12 **Folia of cerebellum.** Folia cerebelli. Delicate cerebellar convolutions (gyri) separated by fissures. B
- 13 **Cerebellar fissure.** Fissura cerebelli. Deeply branched furrow located between two cerebellar folia. B
- 14 **Vallecula.** Deep median groove located inferiorly between the right and left halves of the cerebellum. It lodges the medulla oblongata. C
- 15 **Body of cerebellum.** Corpus cerebelli. Entire cerebellum except for the flocculonodular lobe.
- 16 **Vermis of cerebellum.** Vermis cerebelli. Phylogenetically older, unpaired segment of the cerebellum. B
- 17 **Cerebellar hemisphere.** Hemisphaerium cerebelli. Either of the two halves of the cerebellum. C
- 18 **Anterior lobe of cerebellum.** Lobus anterior cerebelli. Region cranial to primary fissure. B D
- 19 **Lingula.** Unpaired part of vermis fused with the superior medullary velum. It belongs to the arched cerebellum. C D
- 20 **Central lobule.** Lobulus centralis. It lies over the lingula and is continuous on both sides with the ala of the central lobule. C D
- 21 **Culmen.** Segment of vermis between the central lobule and primary fissure. B C D
- 22 **Ala of central lobule.** Ala lobuli centralis. Lateral extension of central lobule for connection with the cerebellar hemispheres. B C D
- 23 **Quadrangular lobule.** Lobulus quadrangularis (pars anterior). Part attaching laterally to the declive. B C D
- 24 **Primary fissure.** Fissura prima. Indentation between the quadrangular and simplex lobules. B D
- 25 **Posterior lobe of cerebellum.** Lobus posterior cerebelli. Region located between the primary and dorsolateral fissures. D
- 26 **Declive.** Part of vermis declining posteriorly from the culmen. B D
- 27 **Folium of vermis.** Narrow midline connection between the left and right superior semilunar lobules. B D
- 28 **Tuber of vermis.** Median connection between the right and left inferior semilunar lobules. B C D
- 29 **Pyramid of vermis.** Pyramis vermis. Segment situated between the right and left biventral lobules. C D
- 30 **Secondary (postpyramidal) fissure.** Fissura secunda. Fissure between the pyramid and uvula of the vermis. C D
- 31 **Uvula vermis.** Part of the vermis lying between the cerebellar tonsils. C D
- 32 **Lobulus simplex (lobulus quadrangularis) (pars inferoposterior).** Portion located between the quadrangular and superior semilunar lobules. B C D
- 33 **Superior semilunar lobule.** Lobulus semilunaris superior. Part situated between the inferior semilunar lobule and lobulus simplex. B C D
- 34 **Horizontal fissure.** Fissura horizontalis. Deep groove between the superior and caudal semilunar lobules. B C D
- 35 **Inferior semilunar lobule.** Lobulus semilunaris inferior. Part of the cerebellum located between the superior semilunar and biventral lobules. B C D
- 36 **Gracile (paramedian lobule).** Lobulus gracilis (l. paramedianus). It is located between the caudal semilunar and biventral lobules. D
- 37 **Biventral lobule.** Lobulus biventer. It lies between the paramedian lobule and cerebellar tonsil. C D
- 38 **Tonsil of cerebellum.** Tonsilla cerebelli. Small bean-shaped portion of the hemisphere lateral to the uvula. C D
- 39 **Posterolateral fissure.** Fissura posterolateralis. Furrow separating the nodulus and flocculus on one side and the cerebellar tonsil and biventral lobe on the other. C D



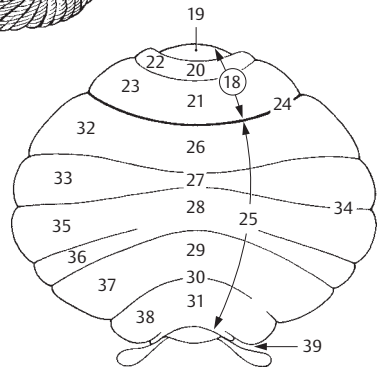
A Roof of rhomboid fossa



B Cerebellum from above

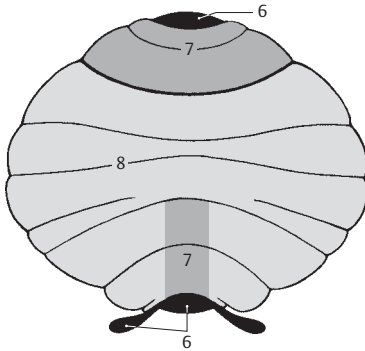


C Cerebellum from below

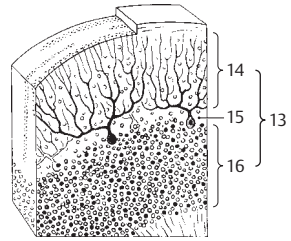


D Cerebellum, schematic

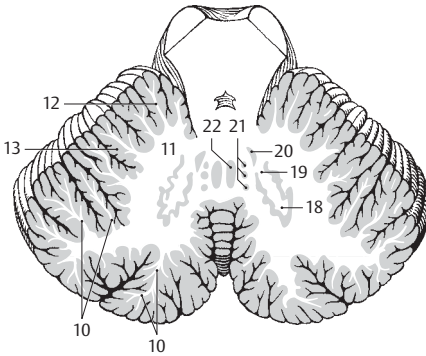
- 1 **Flocculonodular lobe.** Lobus flocculonodularis. Small archicerebellar portion of the cerebellum located caudal to the dorsolateral fissure.
- 2 **Nodulus.** Medial protuberance of the vermis united with the flocculus by the peduncles. E
- 3 **Flocculus.** Claw-like portion of the cerebellum between the inferior cerebellar peduncle and biventral lobule. E
- 4 **Peduncle of flocculus.** Pedunculus floccularis. Band of nerve fibers connecting the flocculus to the nodulus. Part of it extends into the inferior medullary velum. E
- 5 **Paraflocculus.** In humans, a small insignificant part of the caudal lobe of the cerebellum that communicates with the flocculus.
- 6 **Archicerebellum.** Archaeocerebellum. Phylogenetically the oldest part of the cerebellum; it consists of the lingula and the flocculonodular lobe. A
- 7 **Paleocerebellum.** An old part of the cerebellum consisting of the central lobule, culmen, pyramid, uvula, ala of the central lobule and quadrangular lobule. A
- 8 **Neocerebellum.** Phylogenetically young portion of the cerebellum; it comprises the declive, folium, tuber, lobulus simplex, cranial and caudal semilunar lobules, paramedian lobule and tonsil. A
- 9 **CEREBELLAR SECTIONS.** Sectiones cerebellares. Anatomical subdivisions of the cerebellum.
- 10 **Arbor vitae [cerebelli].** Treelike pattern of the white matter seen in prepared sections of the cerebellum. C
- 11 **Medullary body.** Corpus medullare. White matter consisting of myelinated fibers. C
- 12 **White laminae.** Laminae albae. White matter extending into the folia from the medullary body. C
- 13 **Cerebellar cortex.** Cortex cerebellaris. Superficial gray matter of the cerebellum, about 1 mm thick, that consists primarily of nerve cells. B C
- 14 **Molecular (plexiform) layer.** Stratum moleculare (plexiforme). External cortical layer rich in dendrites and axons, poor in cell bodies. The nuclei of the Purkinje cells are found at its border with the granular layer.
- 15 **Purkinje cell layer.** Stratum neurium piriiformum. The layer in which the perikarya of the Purkinje cells are located. B
- 16 **Stratum granulosum.** Internal nuclear layer containing numerous closely packed small neurons. B
- 17 **Nuclei of cerebellum.** Nuclei cerebellaris.
- 18 **Dentate nucleus.** Nucleus dentatus. Large cerebellar nucleus located in the medullary body and resembling a folded pouch. C
- 19 **Hilum of dentate nucleus.** Hilum nuclei dentati. Opening of dentate nucleus from which emerges most of the superior cerebellar peduncle. C
- 20 **Emboliform nucleus.** Nucleus emboliformis. It is found just in front of the hilum of the dentate nucleus. C
- 21 **Globose nucleus.** Nucleus globosus. It lies medial to the dentate nucleus. C
- 22 **Fastigial nucleus.** Nucleus fastigii. The most medial of the deep cerebellar nuclei. C
- 23 **Cerebellar peduncles.** Pedunculi cerebellares. Fibers that provide connections to and from the cerebellum.
- 24 **Inferior cerebellar peduncle (restiform body).** Pedunculus cerebellaris inferior. Inferior connection to the cerebellum formed by fibers of the posterior spinocerebellar tract and olive. E F
- 25 **Middle cerebellar peduncle (brachium pontis).** Pedunculus cerebellaris medius (pontinus). Large peduncle containing fibers originating from the pontocerebellar tract. E F
- 26 **Superior cerebellar peduncle (brachium conjunctivum).** Pedunculus cerebellaris superior. Superior, paired (right and left) connecting fibers extending from the cerebellum to the brain stem. The superior medullary velum extends between them. E F
- 27 **MIDBRAIN.** Mesencephalon. It consists of cerebral crura, tegmentum and quadrigeminal plate (tectal lamina).
- 28 **Cerebral peduncle.** Pedunculus cerebri (cerebralis). It comprises the cerebral crura and the tegmentum and extends up to cerebral aqueduct. D
- 29 **Anterior part (cerebral crus, basis pedunculi).** Part anterior (crus cerebri). It consists of the previously mentioned cerebral crura. D
- 30 **Part posterior.** Posterior part of cerebral peduncle or tegmentum. See p. 292.10 D
- 31 **Oculomotor sulcus.** Sulcus oculomotorius. Furrow on the medial surface of the cerebral crus, exit site of the oculomotor nerve. D
- 32 **Interpeduncular fossa.** Fossa interpeduncularis. Fossa situated between the cerebral crura. D
- 33 **Interpeduncular (posterior) perforated substance.** Substantia perforata interpeduncularis [posterior]. Perforated floor of interpeduncular fossa produced by openings for numerous vessels. D



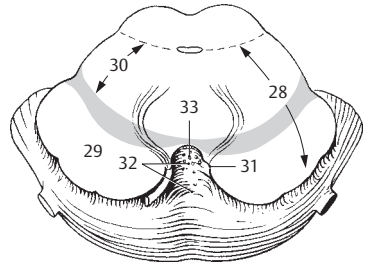
A Cerebellum, schematic



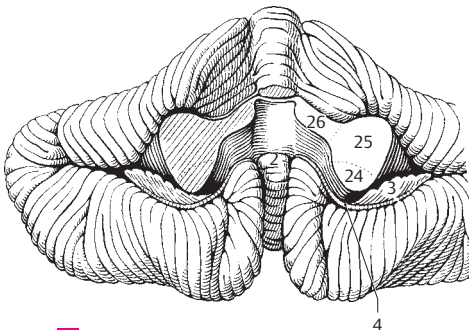
B Layers of cerebellar cortex



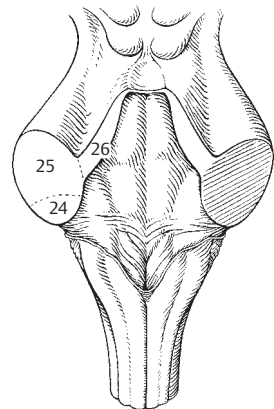
C Horizontal section through cerebellum



D Section through midbrain

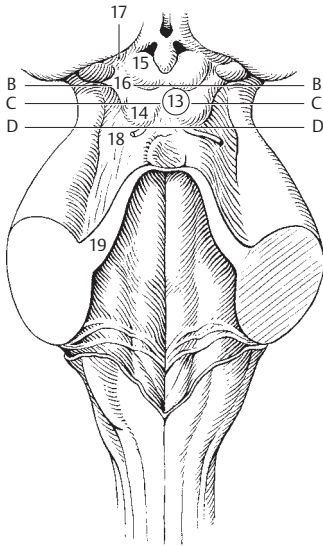


E Cerebellum from below

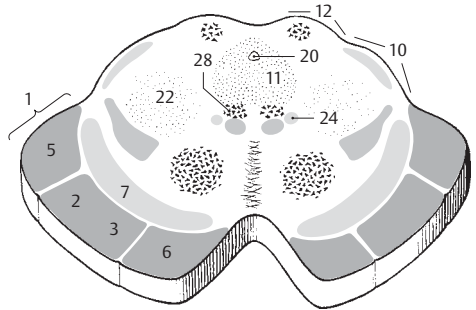


F Cerebellar peduncles

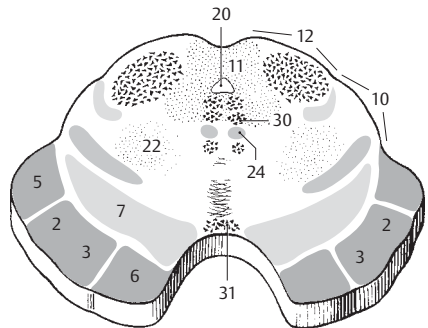
- 1 **Basis pedunculi cerebri.** Synonymous with anterior part of cerebral peduncle, the cerebral crus. B
- 2 **Corticospinal fibers.** *Fibrae corticospinales.* Fibers of the pyramidal tract leading into the spinal cord. B C
- 3 **Corticoclear (corticobulbar) fibers.** *Fibrae corticonucleares.* Pyramidal tract fibers for the cranial nerve nuclei. B C
- 4 **Corticopontine fibers.** *Fibrae corticopontinae.* Fibers of the cerebropontocerebellar tract.
- 5 **Parietotemporopontine fibers.** *Fibrae parietotemporopontinae.* Fibers of the cerebropontine tract which originate from the parietal and temporal lobes. They lie in the lateral part of the cerebral crus. B C
- 6 **Frontopontine fibers.** *Fibrae frontopontinae.* Fibers of the cerebropontine tract which arise from the frontal lobes and occupy the medial sixth of the cerebral crus. B C
- 7 **Substantia nigra.** Black nucleus lying on the cerebral crus. Its name is derived from its content of numerous pigmented ganglion cells rendering it visible with the naked eye. B C
- 8 **Compact part.** *Pars compacta.* Dense part of substantia nigra containing pigmented cells.
- 9 **Pars reticularis.** Reticular (fibrous) part of substantia nigra. It contains disaggregated pigmented fibers facing the cerebral crus. Its cells are irregularly dispersed between the fibers of the cerebral crus.
- 10 **Mesencephalic tegmentum.** *Tegmentum mesencephalicum.* It extends from the substantia nigra to an imaginary plane drawn through the cerebral aqueduct. B C
- 11 **Central gray matter.** *Substantia grisea centralis.* Gray matter around the cerebral aqueduct. B C
- 12 **Mesencephalic tectum.** *Tectum mesencephalicum.* Part of the mesencephalon located dorsal to the previously mentioned transverse plane through the cerebral aqueduct. B C
- 13 **Tectal lamina (quadrigeminal plate).** *Lamina tectalis* [[quadrigemina]]. A
- 14 **Inferior colliculus.** *Colliculus inferior.* Inferior hillock of quadrigeminal plate connected to the auditory pathway. A
- 15 **Superior colliculus.** *Colliculus superior.* Superior hillock of quadrigeminal plate connected to the visual pathway. A
- 16 **Brachium of inferior colliculus.** *Brachium colliculi inferioris.* Connecting arm between the inferior colliculus and the medial geniculate body. A
- 17 **Brachium of superior colliculus.** *Brachium colliculi superioris.* Connecting arm between the superior colliculus and the lateral geniculate body. A
- 18 **Trigone of lemniscus.** *Trigonum lemnisci.* Triangular field located laterally between the tectal lamina, superior cerebellar peduncle and cerebral crus. A
- 19 **Superior cerebellar peduncle.** *Pedunculus cerebellaris superior.* It transmits fibers mainly from the dentate nucleus to the red nucleus and thalamus. A
- 20 **Mesencephalic (cerebral) aqueduct.** *Aqueductus mesencephali (cerebri).* Narrow canal in the midbrain between the 3rd and 4th ventricle. B C D
- 21 **Sections through the mesencephalon.** *Sectiones mesencephalici.* B C D
- 22 **Reticular formation (substance).** *Formatio (substantia) reticularis.* Mesencephalic portion of reticular formation extending up from the spinal cord. It lies around the cerebral aqueduct, and its scattered ganglion cells function in the integration of muscular activities. B C D
- 23 **Corticoreticular fibers.** *Fibrae corticoreticulares.* Nerve fibers extending from the cerebral motor cortex to the ganglion cells of the reticular formation.
- 24 **Medial longitudinal fasciculus.** *Fasciculus longitudinalis medialis.* Fiber bundle with connections to the ocular muscles, neck muscles and vestibular nuclei for coordination of movements of the eyeball and head. B C D
- 25 **Posterior longitudinal fasciculus.** *Fasciculus longitudinalis posterior* [[Schütz]]. Descending and ascending fibers with projections to the hypothalamus and cranial nerve nuclei III, V, VII, X, XII, as well as the nucleus ambiguus and the tractus solitarius and salivatorius. D
- 26 **Mesencephalic tract of trigeminal nerve.** *Tractus mesencephalicus nervi trigeminalis.* Trigeminal fibers to the nucleus of the tract of the trigeminal nerve located lateral to the cerebral aqueduct and the 4th ventricle. D
- 27 **Nucleus of mesencephalic tract of the trigeminal nerve.** *Nucleus tractus mesencephalici nervi trigeminalis* (n. mesencephalica trigeminalis). Upper sensory trigeminal nucleus extending to below the tectal lamina. D
- 28 **Nucleus of oculomotor nerve.** *Nucleus nervi oculomotorii* (nucleus oculomotorius). It is found in front of the cerebral aqueduct. B
- 29 **Accessory nucleus of oculomotor nerve.** *Nucleus oculomotorius accessorius* (autonomicus). A parasymphetic portion of oculomotor nucleus. 96% supplies the ciliary muscle, the rest supplies sphincter pupillae muscle.
- 30 **Nucleus of trochlear nerve.** *Nucleus nervi trochlearis* (nucleus trochlearis). It is located in the central gray matter caudal to the nucleus of the oculomotor nerve. C
- 31 **Interpeduncular nucleus.** *Nucleus interpeduncularis.* Located in the floor of the interpeduncular fossa and has projections to the olfactory tract. C



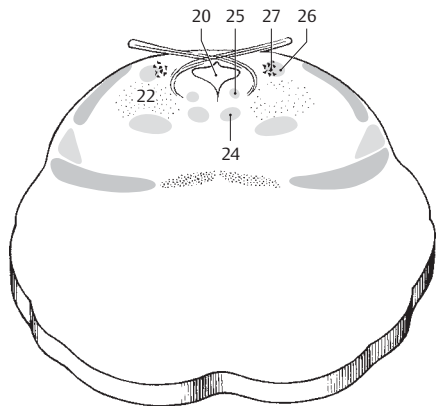
A Midbrain and rhomboid fossa



B Section through superior colliculus

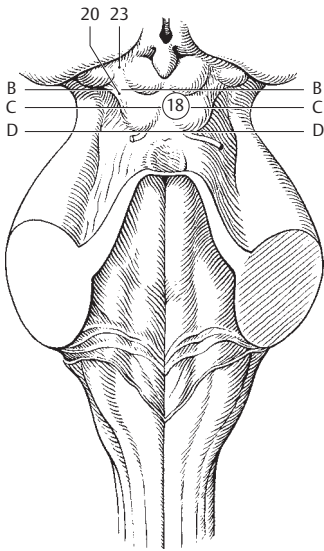


C Section through inferior colliculus

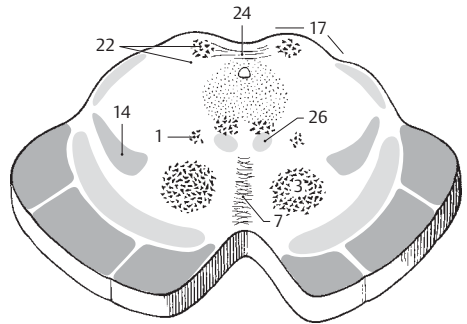


D Section through level of exit of trochlear nerve

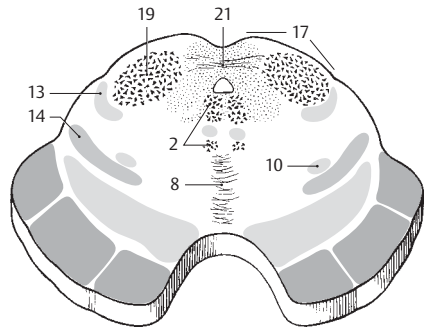
- 1 **Interstitial nucleus of Cajal.** Nucleus interstitialis [[Cajal]]. Group of cells located lateral to the nucleus of the oculomotor nerve, from which it is separated by the medial longitudinal fasciculus. It contains fibers from the vestibular nuclei, globus pallidus and stratum griseum of the superior colliculus. B
- 2 **Tegmental nuclei.** Nuclei tegmenti (tegmentales). Nuclei in the reticular formation dorsal to the trochlear nucleus and ventral to the medial longitudinal fasciculus. C
- 3 **Red nucleus.** Nucleus ruber. Iron-rich nucleus between the substantia nigra and central gray matter with tributaries from the cerebral cortex and thalamus. It is inserted in the tract from the cerebellum to the spinal cord. B
- 4 **Parvicellular part.** Pars parvocellularis. Group of small cells forming the larger part of the red nucleus and part of the rubrospinal tract.
- 5 **Magnocellular part.** Pars magnocellularis. Group of large cells occupying the caudal part of the red nucleus; most of its fibers enter the rubrospinal tract.
- 6 **Endopeduncular nucleus.** Nucleus endopeduncularis. Cell group located medially in the cerebral crus directly after the site where it enters the base of the brain. It probably inserts in the tract between the globus pallidus and reticular formation.
- 7 **Decussations of tegmentum.** Decussationes tegmenti (tegmentales). Crossing of the rubrospinal, rubroreticular and tectospinal tracts. B
- 8 **Decussation of superior cerebellar peduncle.** Decussatio pedunculorum cerebellarium superiorum. Crossing of the superior cerebellar peduncle below the inferior colliculus and anterior to the medial longitudinal fasciculus. C
- 9 **Dentatorubral fibers.** Fibrae dentatorubrales. Component of the superior cerebellar peduncle which passes into the red nucleus.
- 10 **Rubrospinal tract.** Tractus rubrospinalis [[Monakow]]. From its origin in front of the lateral pyramidal tract, this extrapyramidal tract passes from the red nucleus to the anterior horn cells.
- 11 **Tectobulbar tract.** Tractus tectobulbaris. It extends from the posterior tegmental decussation to the opposite side, anterior to the medial longitudinal fasciculus and then passes to the pontine nuclei, especially to the nuclei of the ocular muscles.
- 12 **Tectospinal tract.** Tractus tectospinalis. Initially courses similar to the tectobulbar tract, then descends in the anterior funiculus of the spinal cord.
- 13 **Lateral lemniscus.** Lemniscus lateralis. Partly crossing portion of auditory tract passing to the inferior colliculus. C D
- 14 **Lemniscus medialis.** Decussating connection between nuclei of posterior funiculus and thalamus. B C D
- 15 **Spinal lemniscus.** Lemniscus spinalis. Segment of spinothalamic tract lodging in the midbrain adjacent to the medial lemniscus. D
- 16 **Trigeminal lemniscus.** Lemniscus trigeminalis. Crossing fiber tract between the sensory nuclei of the trigeminal and the thalamus. It also lies in the vicinity of the medial lemniscus.
- 17 **Mesencephalic tectum.** Tectum mesencephalicum. Part of midbrain located dorsal to the above-mentioned plane through the cerebral aqueduct. B C
- 18 **Tectal lamina.** Lamina tectalis [[quadrigemina]]. Quadrigeminal plate. A
- 19 **Nucleus of inferior colliculus.** Nucleus colliculi inferioris. Nucleus connecting the auditory tract with the extrapyramidal system. C
- 20 **Brachium of inferior colliculus.** Brachium colliculi inferioris. Connecting arm between the inferior colliculus and medial geniculate body. A
- 21 **Commissure of inferior colliculus.** Commissura colliculorum inferiorum. Connection between the right and left inferior colliculi which also receives fibers from the lateral lemniscus of the opposite side. C
- 22 **Gray and white layers of superior colliculus.** Strata [grisea et alba] colliculi superioris. Gray matter and white matter surrounding the superior colliculus. B
- 23 **Brachium of superior colliculus.** Brachium colliculi superioris. Connection between the superior colliculus and lateral geniculate body. A
- 24 **Commissure of superior colliculus.** Commissura colliculorum superiorum. Connection between the right and left superior colliculi. B
- 25 **Decussation of trochlear nerve.** Decussatio trochlearis (d. nervorum trochlearium). Fibers of trochlear nerve crossing in the white matter. D
- 26 **Central tegmental tract.** Tractus tegmentalis centralis. Tract passing to the olive, thought to partially arise from the thalamus. B D



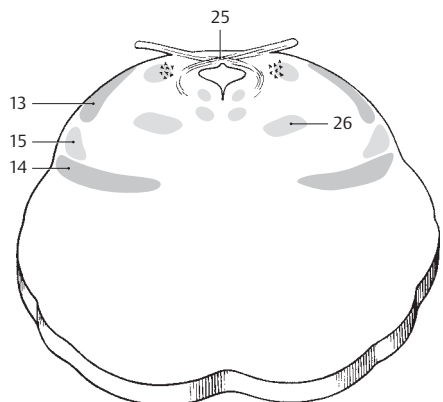
A Brain stem, dorsal view



B Section through midbrain

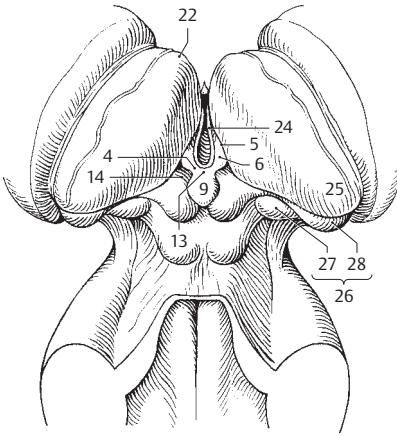


C Section through midbrain

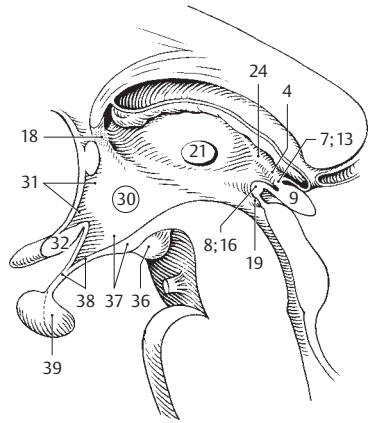


D Section through midbrain

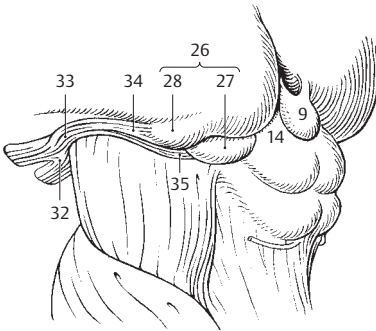
- 1 **FOREBRAIN.** Prosencephalon. Terminal portion of neural tube situated anterior to the anterior margin of the mesencephalon. It comprises the telencephalon and diencephalon.
- 2 **DIENCEPHALON.** The part of the prosencephalon that extends from the anterior margin of the anterior colliculus to the interventricular foramen.
- 3 **Epithalamus.** It consists mainly of the habenulae, their accessories and the epiphysis.
- 4 **Habenula.** Dorsal continuation of the stria medullaris of the thalamus. A B
- 5 **Habenular sulcus.** Sulcus habenuale (habenularis). Shallow furrow between the habenular trigone and the pulvinar. A
- 6 **Trigone of habenula.** Trigonum habenulae (t. habenulare). Triangular field between the stria medullaris of the thalamus and the habenula. The habenular nuclei lie beneath it. A
- 7 **Commissure of habenula.** Commissura habenularum (habenularis). Fibers of the habenulae crossing over the midline. The decussation lies superior to the pineal recess. B
- 8 **Posterior (epithalamic) commissure.** Commissura epithalamica (posterior). Commissure located between the pineal recess and entrance into the cerebral aqueduct; its fibers cross from a nearby area. B
- 9 **Pineal gland (body), epiphysis.** Corpus pineale (glandula pinealis). Topographically speaking, it lies free on the quadrigeminal plate and is suspended from the habenula without a functional connection. A B C
- 10 **Sections of epithalamus.** Sectiones epithalamici.
- 11 **Medial and lateral habenular nuclei.** Nuclei habenulares medialis et lateralis. Cell groups contained in the reflex tract of the rhinencephalon. D
- 12 **Habenulointerpeduncular tract.** Tractus habenulointerpeduncularis. Connection between habenulae and interpeduncular nucleus. D
- 13 **Commissure of habenula.** Commissura habenularum (habenularis). See p. 7 A B
- 14 **Pretectal area.** Area pretektalis. Region extending from in front of the upper margin of superior colliculus as far as the commissure of the epithalamus. C
- 15 **Pretectal nuclei.** Nuclei pretektales. From their origin dorsolateral to the commissure of the epithalamus, they extend as far as the superior colliculus. They receive fibers from the occipital lobe and the area in front of it, as well as the optic tract and send fibers to the accessory nucleus of the oculomotor nerve for the sphincter pupillae muscle.
- 16 **Posterior (epithalamic) commissure.** Commissura epithalamica (posterior). See p. 8 B
- 17 **Pineal gland (body).** Corpus pineale (glandula pinealis). See p. 9 A B C
- 18 **Subformal organ.** Organum subformicale. Organ in the interventricular foramen between right and left fornix. It influences blood pressure and water excretion. B
- 19 **Subcommissural organ.** Organum subcommissurale. Group of specialized ependymal cells below the posterior commissure. They produce Reissner's fiber. B
- 20 **Dorsal thalamus.** Thalamus dorsalis. Portion of thalamus located cranial to the hypothalamic sulcus.
- 21 **Interthalamic adhesion (massa intermedia).** Adhesio interthalamica. Inconstant (70–85%) connection between right and left thalami. B
- 22 **Anterior tubercle of thalamus.** Tuberculum anterius thalamicum. Small protuberance dorsal to the anterior end of the thalamus above the anterior nucleus of the thalamus. A
- 23 **Internal/external medullary laminae.** Laminae medullares interna/externa. Layers of white matter located partly lateral to the thalamus and partly in it. They incompletely separate the individual thalamic nuclei. E
- 24 **Medullary stria of thalamus.** Stria medullaris thalamica. Bundle located at the medial side of the thalamus below the thalamic tenia. It continues dorsally into the habenula and receives fibers from the fornix of the stria terminalis and the precommissural septum. A B
- 25 **Pulvinar.** Posterior part of thalamus projecting freely. A
- 26 **Metathalamus.** Appendage of thalamus below the pulvinar. A C
- 27 **Medial geniculate body.** Corpus geniculatum mediale. United with the inferior colliculus, it forms a part of the auditory pathway. A C
- 28 **Lateral geniculate body.** Corpus geniculatum laterale. Connects with the superior colliculus and visual cortex; it is the termination of most of the fibers of the optic tract. A C
- 29 **Ventral thalamus (subthalamus).** Thalamus ventralis (subthalamus). Part of the diencephalon situated basally with respect to the hypothalamic sulcus.
- 30 **Hypothalamus.** Basal part of the diencephalon. B
- 31 **Preoptic area.** Area preoptica. Area behind the lamina terminalis and in front of the paraventricular nucleus, partly also in front of the supra-optic nucleus. Its nuclei are probably inserted between the olfactory tract and tuber cinereum. B
- 32 **Optic chiasma.** Chiasma opticum. Decussation of medial optic nerve fibers between the optic tract and nerve. B C
- 33 **Optic tract.** Tractus opticus. Superficial part of the visual pathway between the optic chiasma and lateral geniculate body visible at the base of the brain. C
- 34 **Lateral root.** Radix lateralis. Fibers of optic tract which end in the lateral geniculate body or superior colliculus. C
- 35 **Medial root.** Radix medialis. C
- 36 **Mamillary body.** Corpus mamillare. Paired, round elevation on the floor of the diencephalon connected with the thalamus and midbrain. B
- 37 **Tuber cinereum.** Gray matter in the posterior wall of the infundibulum. B
- 38 **Infundibulum.** Funnel-shaped passage to the posterior lobe of the hypophysis. B
- 39 **Neurohypophysis.** Posterior lobe of hypophysis suspended by the infundibulum. B



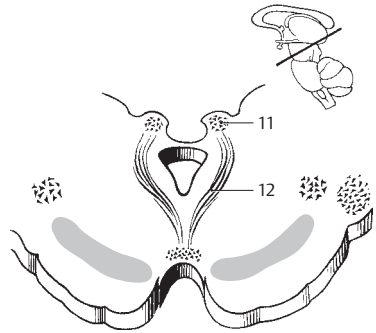
A Brain stem, dorsal view



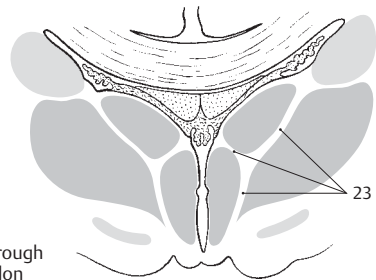
B Brain stem, sagittal section



C Termination of optic tract

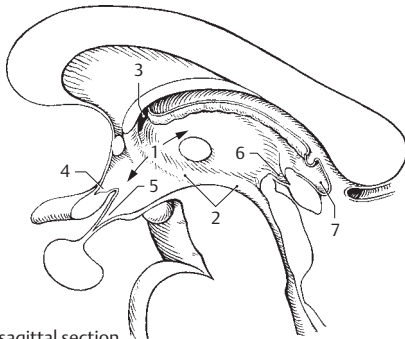


D Oblique section through midbrain

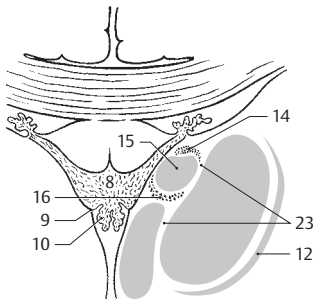


E Section through diencephalon

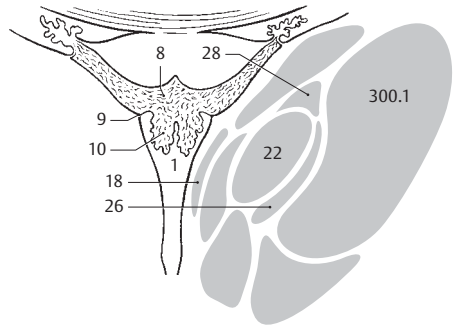
- 1 **Third ventricle.** *Ventriculus tertius.* Diencephalic portion of the cerebral ventricular system. It extends from the lamina terminalis to the beginning of the cerebral aqueduct. A C
- 2 **Hypothalamic sulcus.** *Sulcus hypothalamicus.* Furrow extending from the interventricular foramen to the entrance into the cerebral aqueduct. It separates the dorsal and ventral thalami. A
- 3 **Interventricular foramen.** *Foramen interventriculare.* Opening between the lateral ventricle and third ventricle behind the genu of the fornix. A
- 4 **Optic recess.** *Recessus opticus.* Recess of third ventricle above the optic chiasm. A
- 5 **Recess of infundibulum.** *Recessus infundibuli (infundibularis).* Recess of third ventricle within the infundibulum. A
- 6 **Pineal recess.** *Recessus pinealis.* Recess of third ventricle extending partially into the epiphysis. A
- 7 **Supraspinal recess.** *Recessus supraspinalis.* Recess between the roof of the third ventricle and the epiphysis. A
- 8 **Tela choroidea.** Forms the thin, narrow roof of third ventricle and its choroid plexus. B C
- 9 **Tenia of thalamus.** *Taenia thalami.* Lateral attachment line of the upper wall of the third ventricle along the stria medullaris of the thalamus. B C
- 10 **Choroid plexus.** *Plexus choroideus.* Paired, highly vascularized villous infolding which hangs down from the thin roof of the third ventricle and is continuous anteriorly with the choroid plexus of the 4th ventricle via the interventricular foramen. B C
- 11 **Sections of thalamus and metathalamus.** *Sectiones thalamicae et metathalamicae.* See p. 409.
- 12 **Reticular nucleus of thalamus.** *Nucleus reticulatus [thalami].* Thin layer lying mainly laterally along the thalamus between the posterior limb of the internal capsule and external medullary lamina of the thalamus. It receives tributaries from the entire cerebral cortex, globus pallidus and reticular formation of the brainstem and gives off efferent fibers to the reticular formation of the midbrain and thalamus. B
- 13 **Anterior nuclei of thalamus.** *Nuclei anteriores [thalami].* Cell group in the apex of the thalamus. They receive fibers from the mammillothalamic tract and have projections to the cingulate gyrus.
- 14 **Anterodorsal nucleus.** *Nucleus anterodorsalis (anterosuperior).* Narrow cell plate anterosuperiorly. B
- 15 **Anteroventral nucleus.** *Nucleus anteroventralis (anteroinferior).* Main nucleus of the anterior nuclei. B
- 16 **Anteromedial nucleus.** *Nucleus anteromedialis.* Degenerating nucleus remains situated medial and inferior to the anteroventral nucleus. B
- 17 **Medial nuclei of thalamus.** *Nuclei mediani [thalami].* Collective term for the nuclei located medial and for the most part directly inferior to the ependyma.
- 18 **Anterior/posterior paraventricular nuclei.** *Nuclei paraventriculares anteriores/posteriores.* Cell groups in the wall of the third ventricle with neuronal function (among others, vasopressin, angiotensin II, renin). C D E
- 19 **Rhomboidal nucleus.** *Nucleus rhomboidalis.* It often forms the interthalamic adhesion. D
- 20 **Nucleus reuniens.** *Nucleus reuniens.* Nucleus extending from the anterior end of the anterior tubercle to the middle of the interthalamic adhesion. It may be concerned with the formation of the latter when present. It is absent in 28% of males and 14% of females. D
- 20a **Paratenial nucleus of thalamus.** *Nucleus parataenialis [thalami].* Located between the stria medullaris, tenia, anterodorsal and paraventricular nuclei of the thalamus; it is probably involved in the processing of olfactory stimuli.
- 21 **Medial nuclei of thalamus.** *Nuclei mediales [thalami].* Mass of nuclei medial to the internal medullary lamina with projections to other thalamic nuclei and to the frontal lobe.
- 22 **Dorsal medial nucleus.** *Nucleus medialis dorsalis.* Principal nucleus of this group. C D
- 23 **Internal/external medullary lamina.** *Lamina medullaris interna/externa.* Layer of white matter which, provided it is located internally, has Y-shaped sections and divides the thalamus into anterior, medial and lateral regions. B
- 24 **Reticular (intralaminar) nuclei of thalamus.** *Nuclei reticulares (intralaminares thalami).* Nuclei located in the medullary lamina. They correspond functionally to the reticular formation and thus are integrating nuclei.
- 25 **Centromedian nucleus.** *Nucleus centromedianus.* It is the largest nucleus of this group and has projections to the corpus striatum, hypothalamus, and other structures. E
- 26 **Paracentral nucleus.** *Nucleus paracentralis.* It lies in the internal medullary lamina lateral to the centromedian nucleus. CD
- 27 **Parafascicular nucleus.** *Nucleus parafascicularis.* It lies medial to the occipital region of the centromedian nucleus. E
- 28 **Lateral central nucleus.** *Nucleus centralis lateralis.* It lies dorsolateral and medial to the centromedian nucleus. E
- 29 **Medial central nucleus.** *Nucleus centralis medialis.* It lies at the lower medial end of the internal medullary lamina.



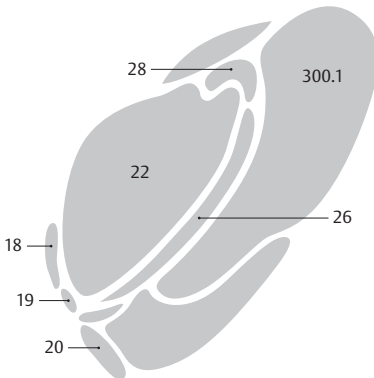
A Diencephalon, sagittal section



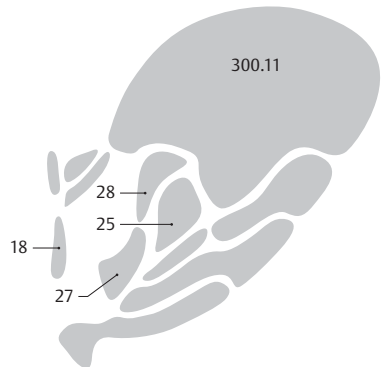
B Diencephalon, cross section



C Diencephalon, cross section



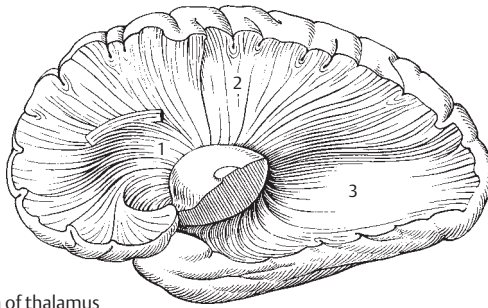
D Diencephalon, cross section



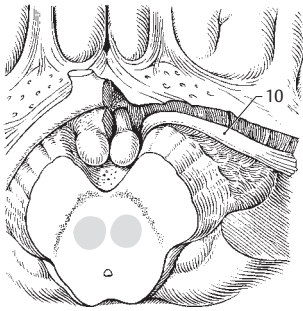
E Diencephalon, cross section

- 1 **Nuclei ventrolaterales [thalami].** Ventrolateral nuclei, the group of nuclei lateral to the internal medullary lamina. B
- 2 **Posterior lateral nucleus.** Nucleus lateralis posterior. Portion of the lateral nucleus situated between the pulvinar and dorsal lateral nucleus with connections to the parietal lobe. A
- 3 **Dorsal lateral nucleus.** Nucleus lateralis dorsalis. Anterosuperior portion of the lateral nucleus with projections to the region of the posterior cingulum segment and the lower part of the parietal lobe. A
- 4 **Anterior ventral nucleus.** Nucleus ventralis anterior. Anterior portion of the ventral nucleus with projections to the interlaminar nuclei, globus pallidus and dentate nucleus and reciprocal connections to the precentral gyrus and the area anterior to it. It plays a role in Parkinson's disease. A
- 5 **Intermediate ventral nucleus.** Nucleus ventralis intermedius. Portion of the ventral nucleus situated behind the anterior ventral nucleus; it is a synaptic station connecting the cerebellum, red nucleus and motor cortex. A
- 6 **Medial ventral nucleus.** Nucleus ventralis medialis. Poorly demarcated nuclear region situated anterior to the posterior ventral nuclei; its function is unclear. A
- 7 **Posterior ventral nuclei.** Nuclei ventrales posteriores. Collective term for the following two nuclei.
- 8 **Posterolateral ventral nucleus.** Nucleus ventralis posterolateralis. The lateral part of the posterior ventral nucleus that receives the medial lemniscus and spinothalamic tract and relays their impulses to the postcentral gyrus via the thalamocortical tract. A
- 9 **Posteromedial ventral nucleus.** Nucleus ventralis posteromedialis. Part located between the centromedian and posterolateral nuclei. It receives the trigeminal lemniscus. A
- 10 **Posterior nuclei of thalamus.** Nuclei posteriores [thalami]. Collective term for the following three parts of the thalamus.
- 11 **Pulvinar nuclei.** Nuclei pulvinares. Nuclei that occupy the posterior portion of the thalamus; they begin at the habenulae, receive tributaries from the auditory and visual pathways as well as from other thalamic nuclei and are connected with the visual cortex, optic and acoustic control centers, and other structures. A
- 12 **Lateral geniculate nucleus [dorsal part].** Nucleus [corporis geniculati] lateralis [pars dorsalis]. Part of the visual pathway. A
- 13 **Medial geniculate nucleus [dorsal part].** Nucleus [corporis geniculati] medialis [pars dorsalis]. Part of medial geniculate body containing small cells. A
- 14 **Sections of ventral thalamus.** Sectiones thalami ventralis.
- 15 **Lateral geniculate nucleus [ventral part].** Nucleus corporis geniculati lateralis [pars ventralis]. Small group of cells with fibers from the retina; part of a light reflex tract. C
- 16 **Medial geniculate nucleus [ventral part].** Nucleus corporis geniculati medialis [pars ventralis]. Possibly the true acoustic part of the geniculate nucleus. C
- 17 **Subthalamic nucleus.** Nucleus subthalamicus [corpus Luysii]. It lies between the lower end of the internal capsule and the zona incerta. Of clinical importance is its reciprocal connection with the globus pallidus. B
- 18 **Reticular nuclei of thalamus.** Nuclei reticulares [thalami]. Disaggregated cell layer on the lateral surface of the thalamus between the external medullary lamina and internal capsule. B
- 19 **Zona incerta.** Basal continuation of the reticular nucleus of the thalamus and other structures. It lies in the path of the globus pallidus to the tegmentum of the diencephalon. B
- 20 **Nuclear regions H, H1 and H2.** Nuclei regionum H, H1 and H2. Dispersed neurons in the corresponding Forel's fields. Field H lies medial to the zona incerta and in front of the red nucleus, H1 between the thalamus and zona incerta, H2 between the zona incerta and subthalamic nucleus. B
- 21 **Thalamic tract and fasciculi.** Tractus et fasciculi thalamici.
- 22 **Lateral lemniscus.** Lemniscus lateralis. Auditory pathway passing into the medial geniculate body. A
- 23 **Medial lemniscus.** Lemniscus medialis. Continuation of the tract from the posterior funiculus radiating into the posterolateral ventral nucleus. A
- 24 **Spinal lemniscus.** Lemniscus spinalis. Pain pathway extending into the posterolateral ventral nucleus. A
- 25 **Trigeminal lemniscus.** Lemniscus trigeminalis. Fibers of the sensory trigeminal nucleus. They pass into the posteromedial ventral nucleus. A
- 26 **Brachium of inferior colliculus.** Brachium colliculi inferioris. Outwardly visible connection between the inferior colliculus and the medial geniculate body. C
- 27 **Acoustic radiation.** Radiatio acustica. Portion of auditory pathway extending from the medial geniculate body to the transverse temporal gyn. It passes through the occipital part of the posterior limb of the internal capsule. A
- 28 **Brachium of superior colliculus.** Brachium colliculi superioris. Externally visible connection between the superior colliculus and the lateral geniculate body. Connection of the visual pathway with the extrapyramidal system. C
- 29 **Optic radiation.** Radiatio optica [[Gratiolet]]. Portion of the visual pathway emanating from the lateral geniculate body. It passes through the occipital part of the posterior limb of the internal capsule and around the posterior horn of the lateral ventricle to the area striata. A

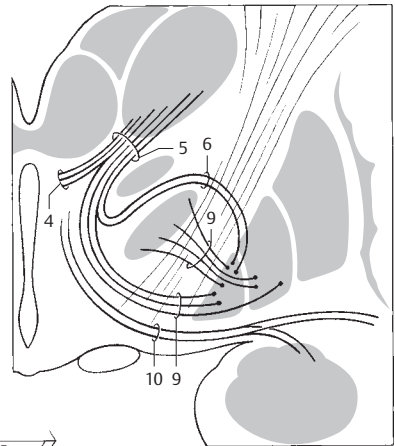
- 1 **Anterior thalamic radiations.** Radiones thalamicae anteriores. Fibers of the anterior nucleus passing to and from the cingulate gyrus and likewise reciprocal connections between the lateral nucleus and frontal lobe. The fibers run in the anterior limb of the internal capsule. A
- 2 **Central thalamic radiations.** Radiones thalamicae centrales. Reciprocal fibers passing fan-like through the posterior limb of the internal capsule from the posterior lateral, anterior ventral, lateral ventral and posterior ventral nuclei to the pre- and postcentral gyri in addition to the connecting fields of the cortex. A
- 3 **Posterior thalamic radiations.** Radiones thalamicae posteriores. They lie in the occipital region of the posterior limb of the internal capsule and contain fibers from the lateral geniculate body (optic radiation) and the pulvinar for the occipital lobes and adjacent regions. A
- 4 **Dentatthalamic tract.** Tractus dentatthalamicus. It arises from the cerebellum and radiates into the thalamic fasciculus and to the lateral ventral nucleus. C
- 5 **Thalamic fasciculus.** Fasciculus thalamicus. It lies below the thalamus, next to and above the zona incerta in field H1 and is composed of the ventricular fasciculus, ansa lenticularis and fibers from the cerebellum. It is a conveyor of impulses for the anterior ventral and lateral ventral nuclei. C
- 6 **Subthalamic fasciculus.** Fasciculus subthalamicus. Fiber bundle extending from the globus pallidus to the subthalamic nucleus. C
- 7 **Mamillothalamic fasciculus.** Fasciculus mamillothalamicus. Fiber tract extending from the mamillary body to the anterior nucleus of the thalamus. D
- 8 **Inferior thalamic peduncle.** Pedunculus thalamicus inferior. Fibers between the hypothalamus and thalamus. According to some anatomists, it consists of fibers of the pulvinar from and to the occipital lobes and its vicinity, as well as fibers of the auditory tract.
- 9 **Ansa lenticularis and fasciculus lenticularis.** Ansa et fasciculus lenticulares. Two fiber bundles from the lentiform nucleus to the ventral nuclei of the thalamus. One part passes around the anterior margin of the internal capsule (ansa lenticularis); the other part passes through the internal capsule. Both tracts are united in the thalamic fasciculus. C
- 10 **Ansa peduncularis and fasciculus peduncularis.** Ansa et fasciculus pedunculares. Fiber tract connecting the thalamus and claustrum, thereby extending between the lentiform nucleus and the amygdaloid body. B C
- 11 **Intrathalamic fibers.** Fibrae intrathalamicae. Connections of individual thalamic nuclei.
- 12 **Periventricular fibers.** Fibrae periventriculares. Fibers coursing beneath the ependyma of the third ventricle between the medial nucleus and the hypothalamic nucleus to enter the posterior longitudinal fasciculus.
- 13 **Sections of the hypothalamus.** Sectiones hypothalamici.
- 14 **Dorsal (posterior) hypothalamic region.** Regio (area) hypothalamica dorsalis. Area of the hypothalamus next to the apex.
- 15 **Nucleus of ansa lenticularis.** Nucleus ansae lenticularis. Groups of cells dispersed in the ansa lenticularis.
- 16 **Anterior (ventral) region of hypothalamus.** Regio hypothalamica anterior.
- 17 **Medial/lateral preoptic nucleus.** Nucleus preopticus medialis/lateralis. Group of nuclei located beneath the anterior commissure and along the lamina terminalis with projections to the stria terminalis, medial telencephalic fasciculus and medial thalamic nuclei. D
- 18 **Supraoptic nucleus.** Nucleus supraopticus. Nucleus lying above the optic chiasm with neurosecretory fibers (oxytocin and vasopressin) projecting to the posterior pituitary. D
- 19 **Paraventricular nuclei.** Nuclei paraventriculares. Group of autonomic nuclei with neurosecretory fibers (oxytocin and vasopressin) projecting to the posterior lobe of the hypophysis. They lie superiorly near the base of the hypothalamic sulcus and behind the anterior hypothalamic nucleus. D
- 20 **Anterior hypothalamic nucleus.** Nucleus hypothalamicus anterior. Located behind the preoptic nucleus with projections to the hemispheres, stria terminalis and thalamus, its efferent fibers communicate with motor and autonomic nuclei. It influences heat regulation, glandular activity and circulation. D
- 21 **Intermediate hypothalamic region.** Regio hypothalamica intermedia. Area situated between the anterior and posterior hypothalamic regions.
- 22 **Arcuate nucleus.** [[Nucleus arcuatus]]. Mural nucleus situated in the entrance to the infundibulum. It belongs to the tuberal nuclei, i. e., it regulates the release of hormones from the anterior lobe by delivering an active substance (neurohormone) to blood vessels of the hypophysial stalk where its processes (axons) are found. D
- 23 **Tuberal nuclei.** Nuclei tuberales. Groups of nuclei in the posterior wall of the infundibulum. They function similar to the arcuate nucleus. D
- 24 **Lateral hypothalamic region.** Regio hypothalamica lateralis. Area separated from the medial hypothalamus by the fornix, mamillothalamic fasciculus and medial telencephalic fasciculus. It is occupied by the lateral preoptic nucleus and the supraoptic nucleus including its lateral portion. D



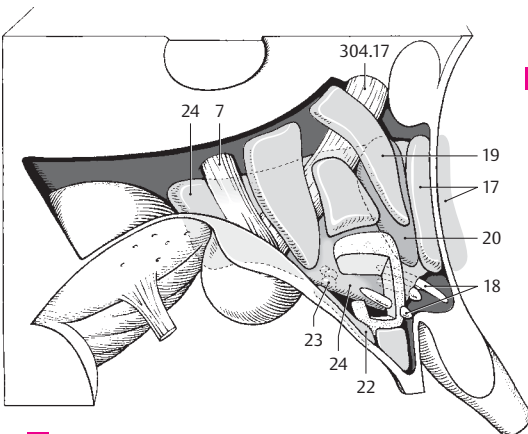
A Radiation of thalamus



B Ansa et fasciculus peduncularis

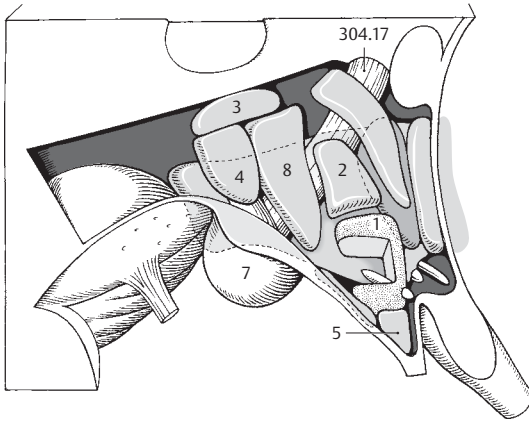


C Subthalamic pathways

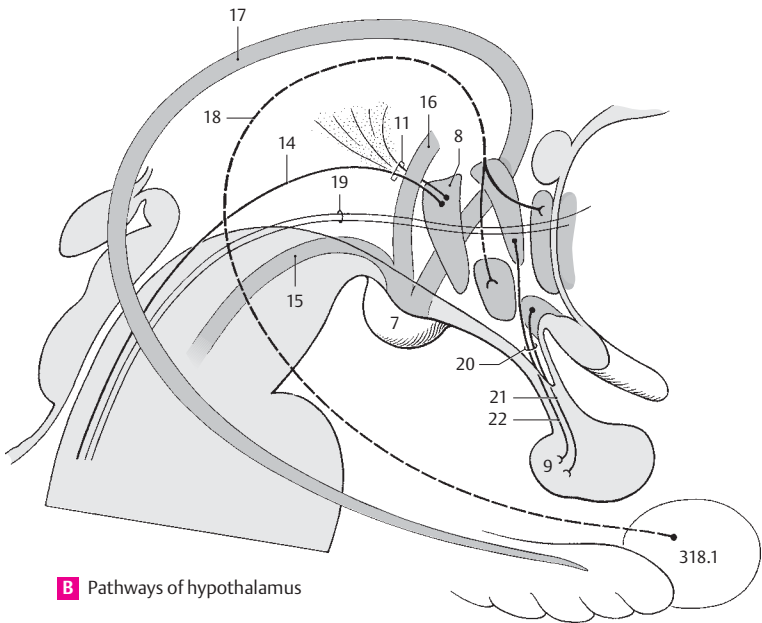


D Nuclei of hypothalamus

- 1 **Ventromedial hypothalamic nucleus.** Nucleus hypothalamicus ventromedialis. Lies in and above the entrance into the infundibulum. This nucleus belongs to the group of tuberal nuclei and, like them, controls the release of regulating hormones for the anterior lobe via the hypophysial stalk. A
- 2 **Dorsomedial hypothalamic nucleus.** Nucleus hypothalamicus dorsomedialis. It lies near the apex of the ventromedial hypothalamic nucleus and has similar functions. A
- 3 **Dorsal hypothalamic nucleus.** Nucleus hypothalamicus dorsalis. Group of cells located below the dorsal hypothalamic area (see p. 302.14). A
- 4 **Posterior periventricular nucleus.** Nucleus periventricularis posterior. Cell group located below the ependyma in the posterior segment of the 3rd ventricle. A
- 5 **Infundibular (arcuate) nucleus.** Nucleus infundibularis (arcuatus). It lies near the apex of the funnel of the infundibulum and has functions similar to those of the tuberal nuclei. A
- 6 **Posterior hypothalamic area.** Regio hypothalamica posterior. It contains the lateral and medial nuclei of the mamillary body and other structures.
- 7 **Medial and lateral nuclei of mamillary body.** Nuclei corporis mamillaris mediales/laterales. The medial nucleus forms the mamillary body and is the origin of the mamillothalamic fasciculus. The lateral nucleus lies ventrolateral and receives the fornix. A B
- 8 **Posterior hypothalamic nucleus.** Nucleus hypothalamicus posterior. It lies occipital to the dorsomedial and ventromedial nuclei and above the mamillary body up to the hypothalamic sulcus and influences circulation, peristalsis and the blood sugar level. A B
- 9 **Neurohypophysis.** In contrast to the two other posterior lobes of the hypophysis, it is of neurogenic origin; so is the continuation of the infundibulum. B
- 10 **Hypothalamic tract and fasciculi.** Tractus et fasciculi hypothalamici. Tracts and fiber bundles of the hypothalamus.
- 11 **Periventricular fibers.** Fibrae periventriculares. Fiber tract directly under the ependyma of the 3rd ventricle. It is permeated by cells, connects the thalamus with the hypothalamus and continues posteriorly into the posterior longitudinal fasciculus. B
- 12 **Dorsal supraoptic commissure.** Commissura supraoptica dorsalis [[Meynert]]. Decussation lying directly above the chiasm. Passes to the other side and may connect the subthalamic nucleus with the contralateral globus pallidus.
- 13 **Ventral supraoptic commissure.** Commissura supraoptica ventralis [[Gudden]]. Crossing fibers lying partially in the chiasm. Among other things, it may connect the medial geniculate bodies with one another.
- 14 **Posterior (dorsal) longitudinal fasciculus.** Fasciculus longitudinalis dorsalis [[Schütz]]. Cranial continuation of a large portion of the ventricular fibers. In the midbrain they lie close to the cerebral aqueduct and connect the hypothalamus with the rest of the brainstem. B
- 15 **Mamillothalamic fasciculus.** Fasciculus mamillothalamicus. Dissectible fiber bundle between the mamillary body and the tegmental nuclei of the midbrain. It arises as a common trunk together with the mamillothalamic fasciculus and branches off into the mesencephalic tegmentum. B
- 16 **Mamillothalamic fasciculus.** Fasciculus mamillothalamicus. It arises together with the mamillothalamic fasciculus and passes to the anterior thalamic nuclei. B
- 17 **Fornix.** It conveys fibers from the hippocampal formation to the medial thalamic nuclei and hypothalamus, and projects fibers to the lateral nuclei of the mamillary body. B
- 18 **Fibers of stria terminalis.** Fibrae striae terminalis. Fibers from the amygdaloid body which communicate with the stria terminalis in the hypothalamus. B
- 19 **Medial prosencephalic fasciculus.** Fasciculus prosencephalicus medialis. Fibers lying between the medial and lateral hypothalamus. They connect individual hypothalamic nuclei with one another and continue toward the occiput in the posterior longitudinal fasciculus. B
- 20 **Hypothalamohypophysial tract.** Tractus hypothalamohypophysialis. Bundle of neurosecretory fibers that arises after the union of the fiber groups from the supraoptic and paraventricular nuclei. B
- 21 **Supraoptic fibers.** Fibrae supraopticae. Fibers that arise in the supraoptic nucleus. B
- 22 **Paraventricular fibers.** Fibrae paraventriculares. Fibers that arise in the paraventricular nucleus. B
- 23 **Supraopticohypophysial tract.** Tractus supraopticohypophysialis. Fibers that arise in the supraoptic nucleus and form part of the hypothalamohypophysial tract.
- 24 **Paraventriculohypophysial tract.** Tractus paraventriculohypophysialis. Fibers that arise in the paraventricular nucleus and form part of the hypothalamohypophysial tract.

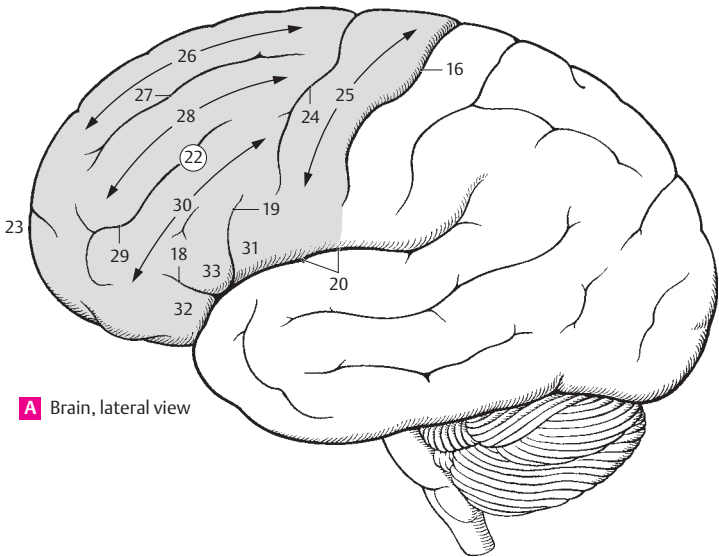


A Nuclei of hypothalamus

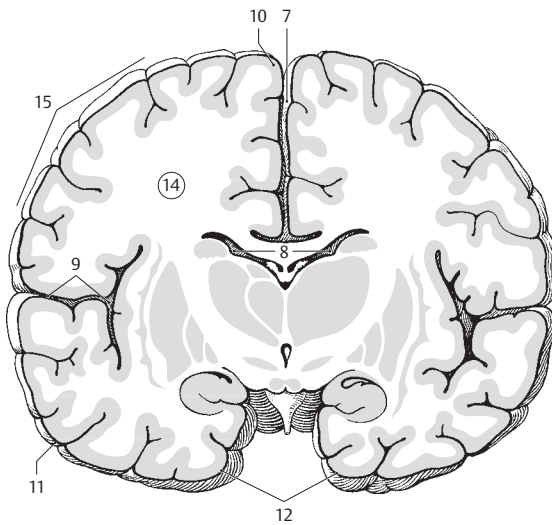


B Pathways of hypothalamus

- 1 **ENDBRAIN.** Telencephalon. The endbrain, which is formed by invagination of the prosencephalon (forebrain). It consists of the cerebral cortex together with the corpus callosum, corpus striatum and olfactory brain.
- 2 **CEREBRUM.** In the present context, it comprises the two cerebral hemispheres and their contents.
- 3 **Cerebral cortex.** Cortex cerebri (pallium). Paired portion of the hemispheres covering most of the brainstem.
- 4 **Cerebral gyri.** Gyri cerebrales. Convolutions of the cerebral hemispheres, about 1 cm wide.
- 5 **Cerebral sulci.** Sulci cerebrales. Fissures between gyri.
- 6 **Cerebral lobes.** Lobi cerebrales. The four lobes of the cerebrum: frontal, parietal, temporal and occipital.
- 7 **Longitudinal fissure of cerebrum.** Fissura longitudinalis cerebri. Deep longitudinal groove between the right and left cerebral hemispheres. It lodges the falx cerebri. B
- 8 **Transverse fissure of cerebrum.** Fissura transversa cerebri [[fissura telodiencephalica]]. Fissure beneath the corpus callosum and fornix as well as above the thalamus and roof of the 3rd ventricle. B
- 9 **Lateral fossa of cerebrum.** Fossa lateralis cerebri. Space deep within the lateral sulcus. B
- 10 **Superior (superomedial) margin.** Margo superior (superomedialis). Superior border of a hemisphere between the superolateral and medial surface. B
- 11 **Inferior (inferolateral) margin.** Margo inferior (inferolateralis). Inferolateral border of a hemisphere between the superolateral and inferior surfaces. B
- 12 **Medial (inferomedial) margin.** Margo medialis (inferomedialis). Inferomedial border of either hemisphere between the inferior and medial surfaces. B
- 13 **[[Fissura limitans]].** Fissure between the insula and opercula. The floor of this cleft, the sulcus limitans, receives the insula.
- 14 **Cerebral hemisphere.** Hemispharium (cerebri). Half of the telencephalon. B
- 15 **Superolateral surface of hemisphere.** Facies superolateralis hemispherii. Upper and lateral surface of the hemisphere. B
- 16 **Central sulcus.** Sulcus centralis. Furrow located between the pre- and postcentral gyri and between the frontal and parietal lobes. A
- 17 **Lateral sulcus.** Sulcus lateralis. Deep cleft passing superiorly between the temporal and frontal lobes and inferiorly between the temporal and parietal lobes.
- 18 **Anterior ramus.** Ramus anterior. Short anteriorly directed branch of the lateral sulcus. A
- 19 **Ascending ramus.** Ramus ascendens. Short branch of the lateral sulcus ascending into the frontal lobe. A
- 20 **Posterior ramus.** Ramus posterior. Long posterior branch of the lateral sulcus terminating near the supramarginal gyrus. A
- 21 **Interlobar sulci.** Sulci interlobares. Furrows which separate the cerebral lobes from one another. They include the central and parieto-occipital sulci and the lateral sulcus together with its posterior ramus.
- 22 **Frontal lobe.** Lobus frontalis. Lobe extending from the frontal pole to the central sulcus. A
- 23 **Frontal pole.** Polus frontalis. Anterior end of the frontal lobe. A
- 24 **Precentral sulcus.** Sulcus precentralis. Furrow in front of the precentral gyrus. A
- 25 **Precentral gyrus.** Gyrus precentralis. Convolution of the frontal lobe lying in front of the central sulcus. Motor area of the cerebral cortex. A
- 26 **Superior frontal gyrus.** Gyrus frontalis superior (primary motor area ???). A
- 27 **Superior frontal sulcus.** Sulcus frontalis superior. Furrow below the superior frontal gyrus. A
- 28 **Middle frontal gyrus.** Gyrus frontalis medius. A
- 29 **Inferior frontal sulcus.** Sulcus frontalis inferior. Furrow lying between the middle and inferior frontal gyri. A
- 30 **Inferior frontal gyrus.** Gyrus frontalis inferior.
- 31 **Opercular part (frontal operculum).** Pars opercularis [operculum frontale]. Part of inferior frontal gyrus lying behind the ascending ramus and covering the insula. A
- 32 **Orbital part.** Pars orbitalis. Part of the inferior frontal gyrus located below the anterior ramus of the lateral sulcus. A
- 33 **Triangular part.** Pars triangularis. Portion of the inferior frontal gyrus located between the anterior and descending rami of the lateral sulcus. Region of the motor speech center of Broca. A

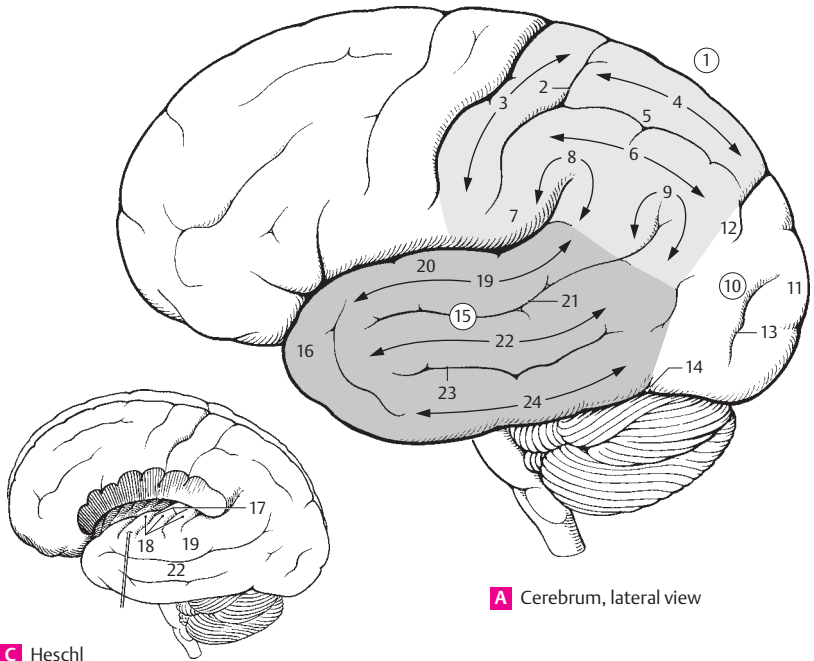


A Brain, lateral view



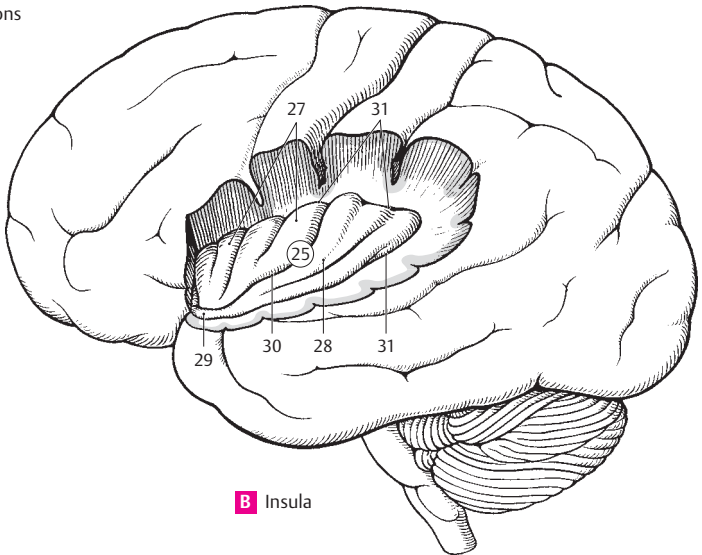
B Brain, frontal section

- 1 **Parietal lobe.** Lobus parietalis. It is bounded anteriorly by the central sulcus, posteriorly by the parieto-occipital sulcus. A
- 2 **Postcentral sulcus.** Sulcus postcentralis. Posterior boundary of the postcentral gyrus. A
- 3 **Postcentral gyrus.** Gyrus postcentralis. Predominantly sensory area of the parietal lobe that lies between the central and postcentral sulci. A
- 4 **Superior parietal lobule.** Lobulus parietalis superior. Upper half of parietal lobe situated behind the postcentral gyrus and above the intraparietal sulcus. A
- 5 **Intraparietal sulcus.** Sulcus intraparietalis. Inconstant sagittal furrow between the superior and inferior parietal lobules. A
- 6 **Inferior parietal lobule.** Lobulus parietalis inferior. Lower half of parietal lobe situated behind the postcentral gyrus and below the intraparietal sulcus. A
- 7 **Frontoparietal operculum.** Operculum frontoparietale. Part of the cerebral segment located above the posterior ramus of the lateral sulcus and covering the insula. It extends toward the occiput and approaches the site where the posterior ramus turns upward. A
- 8 **Supramarginal gyrus.** Gyrus supramarginalis. Convolution curving around the posterior end of the posterior ramus of the lateral sulcus. A
- 9 **Angular gyrus.** Gyrus angularis. Convolution curving around the posterior end of the superior temporal sulcus. A
- 10 **Occipital lobe.** Lobus occipitalis. It is incompletely bounded by the parietal and parieto-occipital sulci and the pre-occipital incisure. A
- 11 **Occipital pole.** Polus occipitalis. Posterior end of occipital lobe. A
- 12 **Transverse occipital sulcus.** Sulcus occipitalis transversus. Continuation of the intraparietal sulcus on the occipital lobe. A
- 13 **Lunate sulcus.** Sulcus lunatus. Sometimes conspicuous semilunar furrow that forms the anterior boundary of the visual cortex. It lies on the superolateral surface of the cerebrum near the occipital pole of the hemisphere at the posterior end of the calcarine fissure. A
- 14 **Preoccipital incisure.** Incisura preoccipitalis. Notch near the inferolateral edge of the cerebral hemisphere that marks the boundary between the occipital and temporal lobes. On the bony skull it is marked by the site where the petrous ridge enters the lateral wall of the skull. A
- 15 **Temporal lobe.** Lobus temporalis. It is bounded superiorly by the posterior ramus of the lateral sulcus. A
- 16 **Temporal pole.** Polus temporalis. Anterior end of temporal lobe. A
- 17 **Transverse temporal sulci.** Sulci temporales transversi. Transverse furrows between the transverse temporal gyri in the floor of the posterior ramus of the lateral sulcus. C
- 18 **Transverse temporal gyri.** Gyri temporales transversi [Heschl's transverse convolutions]. 2–4 transverse convolutions in the floor of the posterior ramus of the lateral sulcus. Acoustic center. C
- 19 **Superior temporal gyrus.** Gyrus temporalis superior. A C
- 20 **Temporal operculum.** Operculum temporale. Part of superior temporal gyrus which covers the insula. A
- 21 **Superior temporal sulcus.** Sulcus temporalis superior. Cleft between the superior and middle temporal gyri. A
- 22 **Middle temporal gyrus.** Gyrus temporalis medius. A C
- 23 **Inferior temporal sulcus.** Sulcus temporalis inferior. Cleft between the middle and inferior temporal gyri. A
- 24 **Inferior temporal gyrus.** Gyrus temporalis inferior. A
- 25 **Insula (insular lobe).** Lobus insularis (insula). Originally exposed cerebral cortex overlapped during ontogenesis. It lies on the floor of the lateral cerebral fossa. B
- 26 **Insular gyri.** Gyri insulae. Gyri on the surface of the insula.
- 27 **Short gyri of insula** *Gyri breves insulae.* Short gyri located in the upper portion of the insula. B
- 28 **Long gyrus of insula.** Gyrus longus insulae. Long horizontal convolution located below the short gyri. B
- 29 **Limen insulae.** Terminal portion of the insular directed anteroinferiorly toward the anterior perforated substance. It is covered by the middle cerebral artery. B
- 30 **Central sulcus of insula.** Sulcus centralis insulae. Cleft between the long and short gyri of the insula. B
- 31 **Circular sulcus of insula.** Sulcus circularis insulae. Limiting furrow of the insula. It is interrupted by the limen insulae. B



A Cerebrum, lateral view

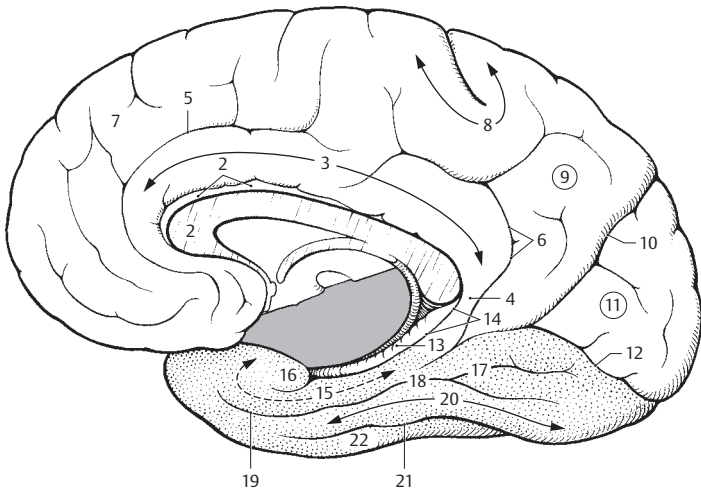
C Heschl convolutions



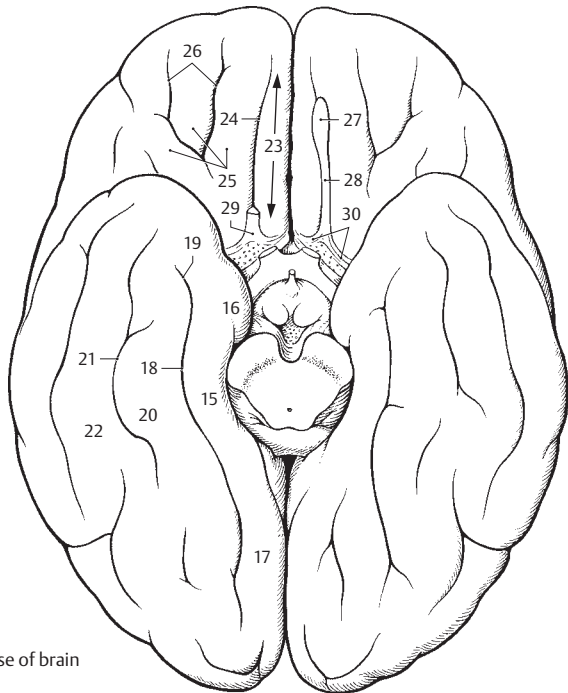
B Insula

17

- 1 **Medial and inferior surfaces of a cerebral hemisphere.** Facies medialis et inferior hemispherii cerebri.
- 2 **Sulcus of corpus callosum.** Sulcus corporis callosi. Cleft between the corpus callosum and the cingulate gyrus. A
- 3 **Cingulate gyrus.** Gyrus cinguli (cingulatum). Convolution between the cingulate sulcus and sulcus of the corpus callosum coursing parallel to the corpus callosum. It is part of the limbic cortex. A
- 4 **Isthmus of cingulate gyrus.** Isthmus gyri cinguli (cingulatus). Constricted area where the cingulate gyrus connects with the parahippocampal gyrus posterior and inferior to the splenium of the corpus callosum. A
- 5 **Cingulate sulcus.** Sulcus cinguli (cingulatus). Furrow bounding the anterior portion of cingulate gyrus anteriorly and superiorly. A
- 6 **Subparietal sulcus.** Sulcus subparietalis. Furrow bounding the posterior portion of the cingulate gyrus superiorly and posteriorly. A
- 7 **Medial frontal gyrus.** Gyrus frontalis medialis. Convolution superior to the medial surface of the frontal lobe, bounded inferiorly by the cingulate sulcus. A
- 8 **Paracentral lobule.** Lobulus paracentralis. Hooklike connection between the pre- and postcentral gyri on the medial surface. A
- 9 **Precuneus.** Precuneus.³ Area in front of the parieto-occipital sulcus. Anteriorly; it is partly bounded by the subparietal sulcus. A
- 10 **Parieto-occipital sulcus.** Sulcus parieto-occipitalis. Deep cleft in front of the cuneus separating the occipital and parietal lobes. A
- 11 **Cuneus.** Portion of the brain located between the calcarine and parieto-occipital sulci. A
- 12 **Calcarine sulcus.** Sulcus calcarinus. Deep furrow below the cuneus near the primary visual area. Anteriorly, it meets the parieto-occipital sulcus at an acute angle. A
- 13 **Dentate gyrus.** Gyrus dentatus. Curved convolution of gray matter with a serrated appearance due to numerous indentations. It forms the inferior continuation of the fasciolar gyrus, reaches up to the medial surface of the uncus and lies between the hippocampus and parahippocampal gyrus. A
- 14 **Hippocampal sulcus.** Sulcus hippocampi (hippocampalis). Furrow situated between the parahippocampal and dentate gyri. It joins the uncus anteriorly. A
- 15 **Parahippocampal gyrus.** Gyrus hippocampi (parahippocampalis). Thick convolution located below the hippocampal sulcus. A B
- 16 **Uncus.** Hooklike structure on the anterior end of the parahippocampal gyrus. A B
- 17 **Lingual gyrus.** Gyrus lingualis. Occipitally directed continuation of the parahippocampal gyrus. A B
- 18 **Collateral sulcus.** Sulcus collateralis. Furrow between the parahippocampal and medial occipitotemporal gyri extending into the occipital lobe. A B
- 19 **Rhinal sulcus.** Sulcus rhinalis. Continuation of the collateral sulcus occasionally present lateral to the uncus. A B
- 20 **Medial occipitotemporal gyrus.** Gyrus occipitotemporalis medialis. Basal convolution between the collateral and occipitotemporal sulci. A B
- 21 **Occipitotemporal sulcus.** Sulcus occipitotemporalis. Cleft between the medial and lateral occipitotemporal gyri located on the inferior surface of the brain lateral to the collateral sulcus. A B
- 22 **Lateral occipitotemporal gyrus.** Gyrus occipitotemporalis lateralis. Convolution adjoining the occipitotemporal sulcus laterally. At the inferior margin of the temporal lobe it becomes continuous with the inferior temporal gyrus without interruption. A B
- 23 **Gyrus rectus.** Elongated convolution located above the orbit at its medial margin. B
- 24 **Olfactory sulcus.** Sulcus olfactorius. Groove for the olfactory tract on the inferior surface of the frontal lobe. B
- 25 **Orbital gyri.** Gyri orbitales. Frontal convolutions located lateral to the gyrus rectus.
- 26 **Orbital sulci.** Sulci orbitales. Furrows between the orbital gyri. B
- 26 a **Olfactory brain.** Rhinencephalon.
- 27 **Olfactory bulb.** Bulbus olfactorius. Knob-like enlargement containing dendrite-rich mitral cells at the beginning of the olfactory tract. B
- 28 **Olfactory tract.** Tractus olfactorius. Connection between the olfactory bulb and trigone on the inferior surface of the frontal lobe. B
- 29 **Olfactory trigone.** Trigonum olfactorium. Triangular widening at the end of the olfactory tract. B
- 30 **Medial and lateral olfactory striae.** Striae olfactoriae medialis et lateralis. Diverging fiber bundles of the olfactory tract radiating fanlike at the olfactory trigone. B
- 31 **Medial and lateral olfactory gyri.** Gyri olfactorii medialis et lateralis. Cellular continuations of the corresponding olfactory striae.



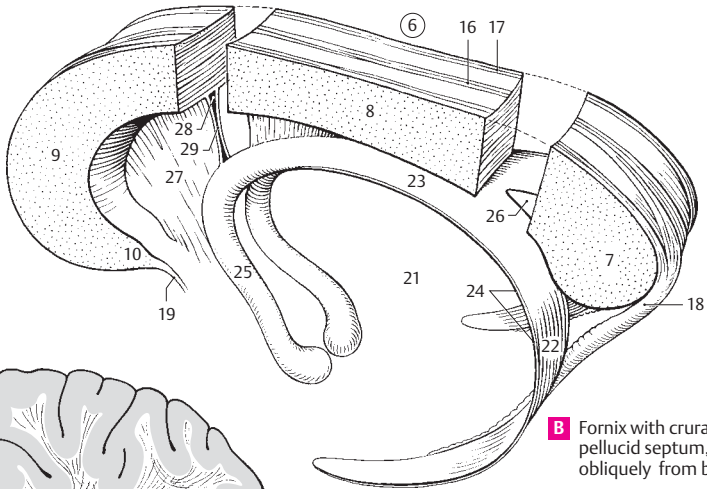
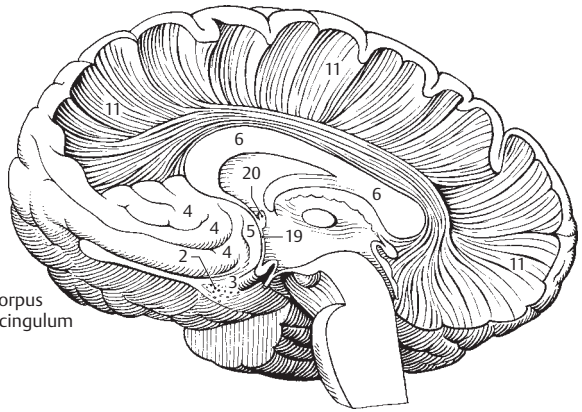
A Cerebrum, medial view



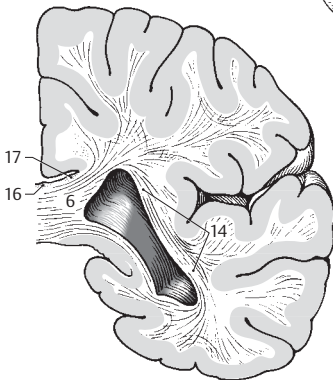
B Base of brain

- 1 **Olfactory brain.** Its comprised of the *substantia perforata anterior*, *stria diagonalis*, *area subcallosa* and *gyrus paraterminalis*.
- 2 **Anterior perforated substance.** *Substantia perforata anterior*. Area posterior to the olfactory trigone with perforations for the passage of cerebral vessels. A
- 3 **Diagonal stria (band) of Broca.** *Stria diagonalis* [Broca]. Bundle of myelinated fibers often coursing obliquely over the anterior perforated substance. It connects the precommissural septum with the uncus. A
- 4 **Subcallosal area.** *Area subcallosa*. Area on the medial surface of the frontal lobe situated below the genu and rostrum of the corpus callosum. A
- 5 **Paraterminal gyrus.** *Gyrus paraterminalis*. Convolution on the medial surface below the rostrum and in front of the lamina terminalis. A
- 6 **Corpus callosum.** Massive transverse fibers connecting the right and left hemispheres at the base of the longitudinal fissure of the cerebrum. A B C
- 7 **Splenium.** Thick, free posterior end of the corpus callosum. B
- 8 **Trunk.** *Truncus*. Portion of corpus callosum between the splenium and genu. B
- 9 **Genu.** Bend in the corpus callosum located anteriorly above the rostrum. B
- 10 **Rostrum.** Anterior end of corpus callosum that tapers inferiorly to a point where it joins the lamina terminalis. B
- 11 **Radiation of corpus callosum.** *Radiatio corporis callosi*. Fibers radiating from the corpus callosum to the cerebral cortex. A D
- 12 **Forceps minor.** *Forceps frontalis (minor)*. U-shaped fibers passing through the genu of the corpus callosum and connecting the frontal lobes. D
- 13 **Forceps major.** *Forceps occipitalis (major)*. U-shaped fibers passing through the splenium of the corpus callosum and connecting the posterior parts of the occipital lobes. D
- 14 **Tapetum.** Continuous layer of fibers arching laterally and inferiorly from the corpus callosum and forming the lateral wall of the inferior and posterior horns of the lateral ventricle as well as the roof of the posterior horn. C
- 15 **Indusium griseum.** Thin layer of gray matter on the superior surface of the corpus callosum. B C
- 16 **Medial longitudinal stria.** *Stria longitudinalis medialis*. A medial longitudinal band of white fibers in the indusium griseum. It is part of the olfactory brain. B C
- 17 **Lateral longitudinal stria.** *Stria longitudinalis lateralis*. Paired longitudinal stripe embedded in the indusium griseum and covered laterally by the cingulate gyrus. It is part of the olfactory brain. B C
- 18 **Gyrus fasciolaris.** Convolution that passes around the splenium of the corpus callosum and forms a connection between the longitudinal striae, including the *indusium griseum* and *dentate gyrus*. B
- 19 **Lamina terminalis.** Thin walled, anterior border of the 3rd ventricle. A B
- 20 **Anterior commissure.** *Commissura anterior*. Anterior, transverse connection between the right and left halves of the cerebrum. It lies behind the lamina terminalis and is visible in the most anterior segment of the 3rd ventricle. A
- 21 **Fornix.** Curved bundle of fibers that pass in both directions between the mamillary body and hippocampus. B
- 22 **Crus of fornix.** *Crus*. The posterior limb of the fornix that arises from the hippocampus as the hippocampal fimbria, circles around the pulvinar and unites with the contralateral limb to form the body of the fornix. B
- 23 **Body of fornix.** *Corpus*. Unpaired middle part of fornix situated below the corpus callosum and formed by the union of both crura. B
- 24 **Tenia.** *Taenia*. Thin, lateral margin of the fornix that gives attachment to the choroid plexus of the lateral ventricle. B
- 25 **Column.** *Columna*. Anterior part of the fornix located partly in the lateral wall of the 3rd ventricle. It extends as far as the mamillary body. B
- 26 **Commissure.** *Commissura*. Triangular connecting plate situated between the crura of the fornix below the posterior part of the corpus callosum. It contains fibers crossing from the hippocampal fimbriae of both sides. B
- 27 **Septum pellucidum (lucidum).** Bilayered, thin plate extending between the corpus callosum and fornix. It separates the anterior horns of the lateral ventricles from one another. B
- 28 **Cavity of septum pellucidum.** *Cavum septi pellucidi*. Enclosed cavity of variable size between the two laminae of the septum pellucidum. B
- 29 **Lamina of septum pellucidum.** *Lamina septi pellucidi*. Paired sheet forming the septum pellucidum and the lateral wall of its cavity. B
- 30 **Precommissural septum.** *Septum precommissurale*. Area on the free medial surface of the frontal lobe in front of the lamina terminalis.

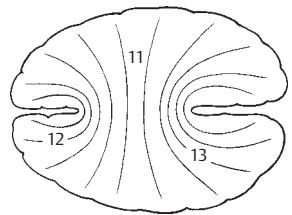
A Radiation of corpus callosum and cingulum



B Fornix with crura and pellucid septum, obliquely from behind

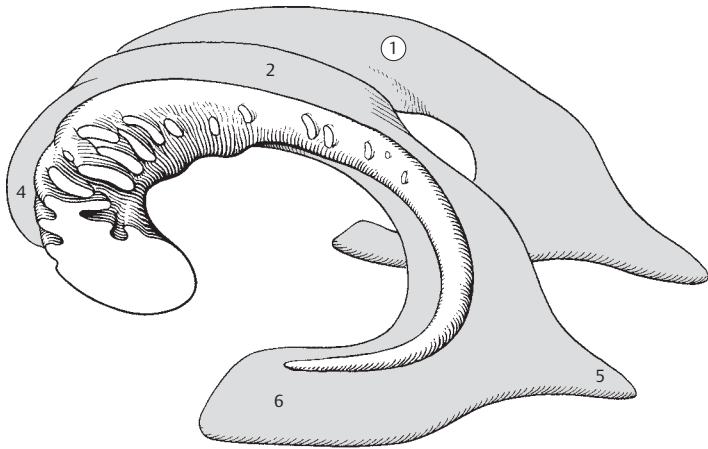


C Tapetum

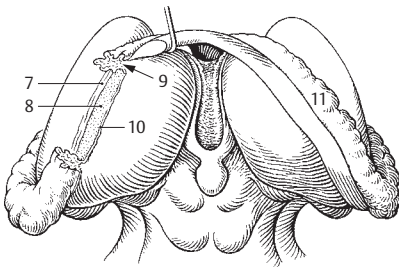


D Major and minor forceps

- 1 **Lateral ventricle.** Ventriculus lateralis. Paired ventricle which communicates with the third ventricle via the interventricular foramen. It consists of the pars centralis and three horns (anterior, posterior, inferior). A
- 2 **Central part.** Pars centralis. Middle portion of lateral ventricle located above the thalamus and below the corpus callosum. It contains a part of the choroid plexus. A
- 3 **Interventricular foramen.** Foramen interventriculare. Passage behind and below the genu of the fornix through which the lateral and third ventricles communicate. D
- 4 **Anterior horn.** Cornu frontale (anterior). Part of the lateral ventricle that extends forward from the interventricular foramen. It is bounded medially by the septum pellucidum, laterally by the head of the caudate nucleus, superiorly by the trunk of the corpus callosum, anteriorly and inferiorly by the genu and rostrum of the corpus callosum. A
- 5 **Posterior horn.** Cornu occipitale (posterior). Part of the lateral ventricle that extends into the occipital lobe. A
- 6 **Inferior horn.** Cornu temporale (inferius). Part of the lateral ventricle that accompanies the hippocampus laterally and contains a part of the choroid plexus. A
- 7 **Stria terminalis.** Longitudinal band of myelinated fibers located in the angle between the thalamus and caudate nucleus above the thalamostriate vein. It arises from the amygdaloid body. B
- 8 **Lamina affixa.** Floor of lateral ventricle between the stria terminalis and tenia choroidea. B
- 9 **Choroid fissure.** Fissura choroidea. Cleft between the thalamus and fornix for passage of the choroid plexus into the lateral ventricle. In the inferior horn it lies between the fimbria of the hippocampus and the stria terminalis. B
- 10 **Tenia choroidea.** Taenia choroidea. Line of attachment of the lateral choroid plexus to the thalamus. It becomes visible after removal of the choroid plexus. B
- 11 **Choroid plexus of lateral ventricle.** Plexus choroideus ventriculi lateralis. Highly vascularized, fringelike villous folds that protrude into the lateral ventricle through the choroid fissure. They extend anteriorly to the interventricular foramen and posteriorly into the inferior horn. B
- 12 **Bulb of posterior horn.** Bulbus cornus occipitalis (posterioris). Enlargement on the medial side of the posterior horn caused by fibers of the splenium of the corpus callosum. C
- 13 **Calcar avis.** Enlargement on the medial side of the posterior horn produced by the calcarine fissure. C
- 14 **Collateral eminence.** Eminentia collateralis. Elevation in the lateral floor of the inferior horn near the hippocampus. It is caused by the collateral sulcus. C
- 15 **Collateral trigone.** Trigonum collaterale. Broadened triangular area near the beginning of the collateral eminence at the border between the inferior and posterior horns. C
- 16 **Hippocampus.** Enlongated elevation in the inferior horn formed by the hippocampal sulcus. It is a specifically structured part of the rhinencephalon. C
- 17 **Pes.** Foot like elevation at the anterior end of the hippocampus. C
- 18 **Alveus.** Thin layer of white matter on the hippocampus. C
- 19 **Fimbria.** Bundle of white fibers emanating from the alveus and passing medially and upward on the hippocampus to continue into the fornix as its crus. C
- 19a **Sections of the telencephalon.** Sectiones telencephalici.
- 20 **Archicortex (archipallium).** Archaeocortex. Phylogenetically speaking, this is an older part of the cerebral cortex. Unlike the neocortex, it has three instead of six layers and is formed by the hippocampus and dentate gyrus.
- 21 **Paleocortex.** Palaeocortex. Oldest part of cerebral cortex originally derived from the piriform lobe.
- 22 **Neocortex.** The largest part of the cerebral cortex comprised of six layers.
- 22a **Mesocortex.** Incompletely differentiated zone in the region of the insular cortex with visceral functions.



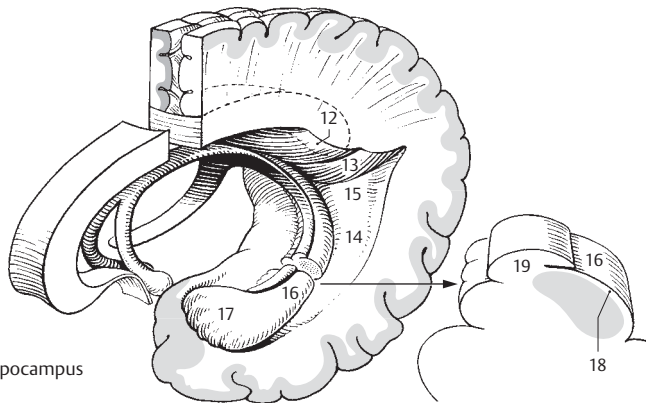
A Right and left lateral ventricles with left caudate nucleus



B Thalamus with fornix

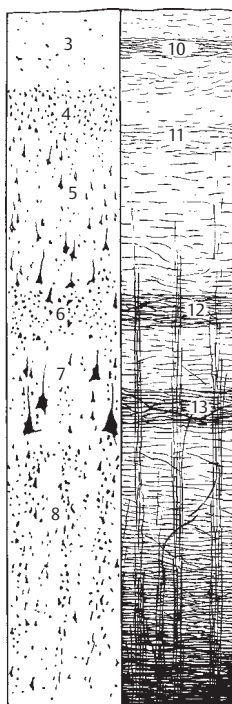


D Interventricular foramen

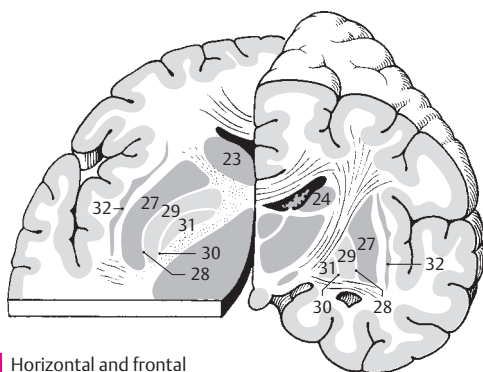


C Left hippocampus

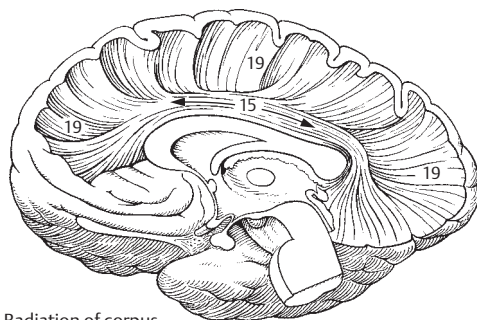
- 1 **Sections through telencephalon.** Sectiones telencephali.
- 2 **Cerebral cortex.** Cortex cerebri (pallium). Gray matter, 1.5–4.5 mm thick, consisting mainly of the following six layers. A
- 3 **Molecular (plexiform) layer.** 1st layer. Lamina molecularis (plexiformis). It contains a few tangential cells and a thick network of tangential fibers from dendrites of pyramidal cells and axons of other cells. None of its projections extend beyond the cerebral cortex. A
- 4 **External granular layer.** 2nd layer. Lamina granularis externa. A layer of small cells in a fine fiber network. A
- 5 **External pyramidal layer (pyramidal cell layer).** 3rd layer. Lamina pyramidalis externa. It contains medium-sized pyramidal cells which do not form long tracts. A
- 6 **Internal granular layer.** 4th layer. Lamina granularis interna. It consists predominantly of closely packed stellate cells and receives impulses primarily from thalamocortical fibers. Its stria is comprised of densely stratified tangential fibers. A
- 7 **Internal pyramidal (ganglionic) layer.** 5th layer. Lamina pyramidalis interna (ganglionaris). It contains larger pyramidal cells and is the exit of the corticonuclear and corticospinal tracts in the corresponding regions of areas 4 and 6. A
- 8 **Multiform (fusiform) layer.** 6th layer. Lamina multiformis. Poorly defined layer made up of many, mostly small, fusiform cells extending into the white matter. A
- 9 **Tangential fibers.** Neurofibrae tangenciales. Superficial fiber complex comprised of the following four layers.
- 10 **Stria of molecular layer.** Stria laminae molecularis (plexiformis). Band of tangential fibers in the 1st layer of the cerebral cortex. A
- 11 **Stria of external granular layer.** Stria laminae granularis externa. Thinner band of tangential fibers in the 2nd layer of the cerebral cortex. A
- 12 **Stria of internal granular layer.** Stria laminae granularis interna. Band of tangential fibers in the 4th layer of the cerebral cortex [[outer stripe of Baillarger]]. A
- 13 **Stria of internal pyramidal layer.** Stria laminae pyramidalis interna (ganglionaris). Band of tangential fibers in the 5th layer of the cerebral cortex [[inner stripe of Baillarger]]. A
- 14 **Arcuate fibers of cerebrum.** Fibrae arcuatae cerebri. Arcuate fibers connecting the adjacent cerebral gyri. F
- 15 **Cingulum.** Fiber bundle lying in the medulla of the cingulate gyrus. It arises from the area subcallosa, arches around the corpus callosum, passes the splenium and extends anteriorly up to the uncus. C
- 16 **Superior longitudinal fasciculus.** Fasciculus longitudinalis superior. Largest bundle of association fibers in the cerebrum, extending from the frontal lobe to the temporal lobe via the occipital lobe. E
- 17 **Inferior longitudinal fasciculus.** Fasciculus longitudinalis inferior. Bundle of association fibers connecting the temporal and occipital lobes. E
- 18 **Uncinate fasciculus.** Fasciculus uncinatus. Association fibers connecting the inferior surface of the frontal lobe and the anterior part of the temporal lobe. E
- 19 **Radiation of corpus callosum.** Radiatio corporis callosi. Fibers connecting the right and left cerebral cortices. See also p. 312.11–14. C
- 20 **Basal nuclei.** Nuclei basales. Basal ganglion.
- 21 **Corpus striatum.** The striate body, which is comprised of basal ganglia (caudate nucleus and putamen) united by bundles of gray matter. Central synaptic station of the extrapyramidal system. D
- 22 **Caudate nucleus.** Nucleus caudatus. Elongated, arched nucleus that arises from the ganglionic mass of the telencephalon and curves around the thalamus.
- 23 **Head of caudate nucleus.** Caput [[nuclei caudati]]. Anteriorly situated structure that forms the lateral wall of the anterior horn of the lateral ventricle. B D
- 24 **Body of caudate nucleus.** Corpus [[nuclei caudati]]. Middle part of caudate nucleus lying on the thalamus. B D
- 25 **Tail of caudate nucleus.** Cauda [[nuclei caudati]]. It accompanies the inferior horn and forms the tapering posterior and inferior segments of the caudate nucleus. D
- 26 **Lentiform nucleus.** Nucleus lentiformis (lenticularis). Part of the corpus striatum that arises from the telencephalon and diencephalon. D
- 27 **Putamen.** Lateral, telencephalic portion of the lentiform nucleus. B
- 28 **Lateral medullary lamina.** Lamina medullaris lateralis. Medullary layer of the corpus striatum situated between the globus pallidus and putamen. B
- 29 **Lateral globus pallidus.** Globus pallidus lateralis. Part of the diencephalic globus pallidus located between the lateral and medial medullary laminae. B
- 30 **Medial medullary lamina.** Lamina medullaris medialis. Medullary layer between the medial and lateral parts of the globus pallidus. B
- 31 **Medial globus pallidus.** Globus pallidus medialis. Part of the globus pallidus located medial to the medial medullary lamina. B
- 32 **Clastrum.** Layer of gray matter between the lentiform nucleus and the insular cortex. B



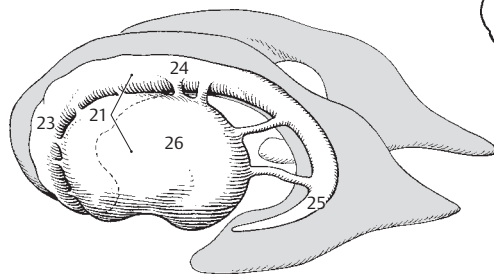
A Cerebral cortex
Cells at left
Medullary sheaths at right



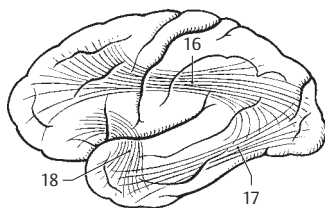
B Horizontal and frontal sections of the brain



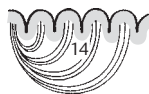C Radiation of corpus callosum and cingulum



D Lateral ventricle
with left striate body



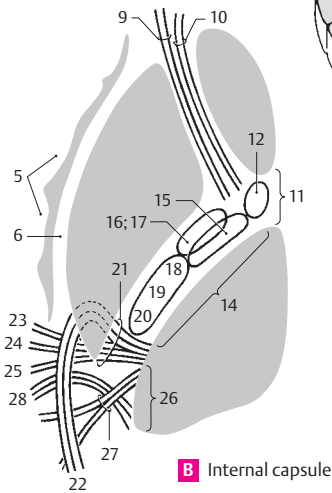
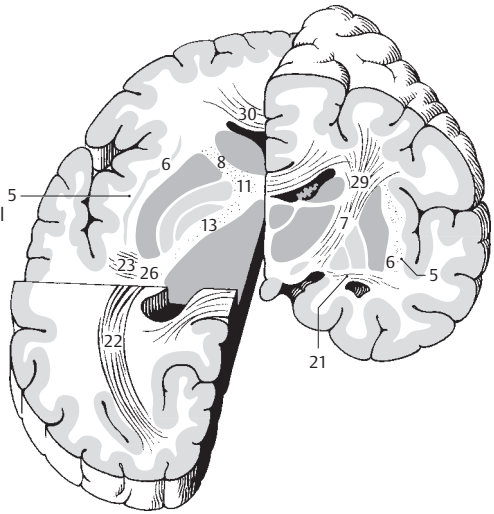
E Association pathways



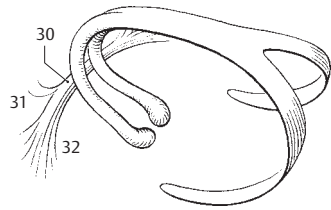
F Arcuate fibers

- 1 **Amygdaloid body (amygdala).** Corpus amygdaloideum. Ovoid group of nuclei in front of the inferior horn of the lateral ventricle that communicates with the medial cerebral cortex. It forms part of the rhinencephalon, has some autonomic functions, and influences emotional behavior. D
- 2 **Anterior amygdaloid area.** Area amygdaloidea anterior. Anterior group of cells directed toward the anterior perforated substance. It receives fibers from the lateral olfactory tract. The diagonal band of Broca arises from this area. D
- 3 **Basolateral part.** Pars basolateralis. In humans, it contains the largest group of nuclei of the amygdala complex. It receives no olfactory fibers but has projections to the hypothalamus, hippocampus and other parts of the brain, as well as with the stria terminalis. D
- 4 **Corticomedial part.** Pars corticomediales [olfactoria]. Smaller superomedially directed group of nuclei that receives fibers from the olfactory tract and is involved in the formation of the stria terminalis. D
- 5 **Extreme capsule.** Capsula extrema. White matter between the cortex of the insula and the claustrum. A B
- 6 **External capsule.** Capsula externa. White matter between the claustrum and lentiform nucleus. A B
- 7 **Internal capsule.** Capsula interna. Very important conduction band lying medial to the lentiform nucleus and lateral to the thalamus and caudate nucleus. A
- 8 **Anterior limb of internal capsule.** Crus anterior capsulae internae. Structure lying between the lentiform nucleus and the head of the caudate nucleus. A
- 9 **Anterior thalamic radiations.** Radiationes thalamicae anteriores. It contains fibers that connect the frontal lobe and the medial nucleus of the thalamus, as well as the anterior nucleus of the thalamus and the anterior region of the cingulate gyrus. B
- 10 **Frontopontine tract.** Tractus frontopontinus. Fibers extending from the frontal lobe to the nuclei of the pons. B
- 11 **Genu of internal capsule.** Genu capsulae internae. It lies between the anterior and posterior limbs of the internal capsule and forms part of the lateral wall of the ventricular system. A B
- 12 **Corticonuclear tract.** Tractus corticonuclearis. Part of the pyramidal tract passing into the motor nuclei of the cranial nerves. B
- 13 **Posterior limb of internal capsule.** Crus posterior capsulae internae. The part of the internal capsule that separates the lentiform nucleus from the thalamus and body of caudate nucleus. A
- 14 **Thalamolentiform part.** Pars thalamolentiformis. Portion of the posterior limb of the internal capsule that extends up to the posterior margin of the lentiform nucleus. B
- 15 **Corticospinal fibers.** Fibrae corticospinales. Part of the pyramidal tract that is organized somatotopically in such a way that the fibers for the most caudal region of the body lie farthest toward the occiput. B
- 16 **Corticorubral fibers.** Fibrae corticorubrales. Fibers extending from the frontal lobe to the red nucleus. B
- 17 **Corticoreticular fibers.** Fibrae corticoreticulares. Fibers passing from the region in front of and behind the central sulcus to the reticular formation. B
- 18 **Corticothalamic fibers.** Fibrae corticothalamicae. Part of the thalamic radiation in the thalamus. B
- 19 **Thalamoparietal fibers.** Fibrae thalamoparietales. Nerve fibers that project from the cerebral cortex to the thalamus. B
- 20 **Central thalamic radiations.** Radiationes thalamicae centrales. Nerve fibers that radiate from the superior portion of the cerebral cortex to the thalamus. B See also p. 302.2.
- 21 **Sublentiform part.** Pars sublentiformis. Portion of internal capsule lying below the posterior part of the lentiform nucleus. A B
- 22 **Optic radiation [Gratioleti].** Radiatio optica. Fiber tract that radiates from the lateral geniculate body to the area striata in the occipital lobe. A B
- 23 **Acoustic radiation.** Radiatio acustica. Auditory tract that radiates from the medial geniculate body to the transverse temporal gyrus [Heschl]. A B
- 24 **Corticoteotal fibers.** Fibrae corticotectales. Connecting fibers between the cerebral cortex and the tectum. B
- 25 **Temporopontine fibers.** Fibrae temporopontinae. Fibers of the cerebropontocerebellar tract that arise from the temporal lobe. B
- 26 **Retrolentiform part.** Pars retrolentiformis. Portion of internal capsule situated occipital to the lentiform nucleus. A B
- 27 **Posterior thalamic radiations.** Radiationes thalamicae posteriores. B
- 28 **Parieto-occipitopontine fasciculus.** Fasciculus parieto-occipitopontinus. Portion of cerebropontocerebellar tract arising from the parietal and occipital lobes. B
- 29 **Corona radiata.** Fibers of the internal capsule radiating fanlike in all directions toward the cerebral cortex. A
- 30 **Anterior commissure.** Commissura anterior. It lies in front of the column of the fornix and is readily visible in the anterior wall of the third ventricle. A C
- 31 **Anterior part.** Pars anterior. It radiates into the area subcallosa and is part of the phylogenetic rhinencephalon. C
- 32 **Posterior part.** Pars posterior. Larger portion of anterior commissure that connects the two temporal lobes. C
- 33 **Association neurofibers.** Neurofibrae associationes. Association fibers connecting adjacent or distant parts of the same side of the cerebrum. They form some of the above-named tracts, e.g., cingulum, superior longitudinal fasciculus, etc.
- 34 **Commissural neurofibers.** Neurofibrae commissurales. They connect equivalent structures of contralateral hemispheres.
- 35 **Projecting neurofibers.** Neurofibrae projectiones. They form the longer tracts, e.g., pyramidal tract, optic and acoustic radiations, thalamic radiation.

A Frontal and stepped horizontal cut through cerebrum

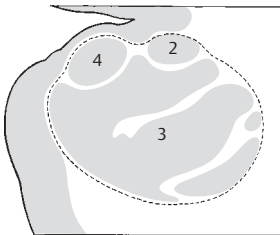


B Internal capsule

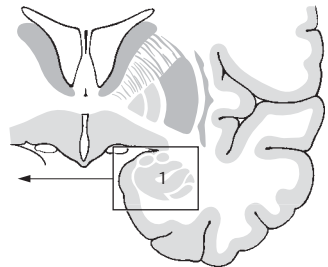


C Fornix with anterior commissure of cerebrum

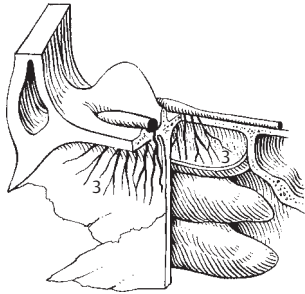
17



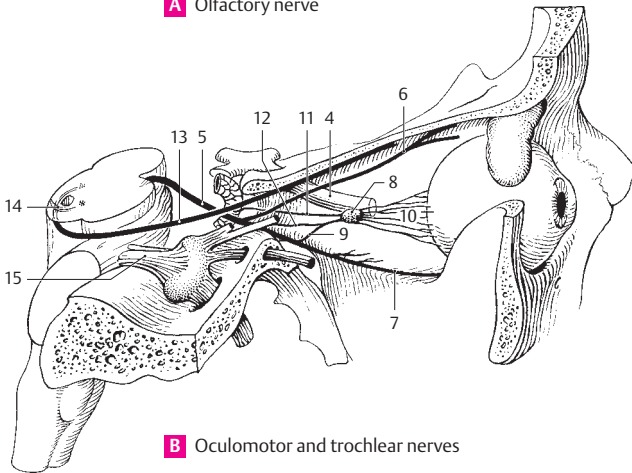
D Amygdaloid body



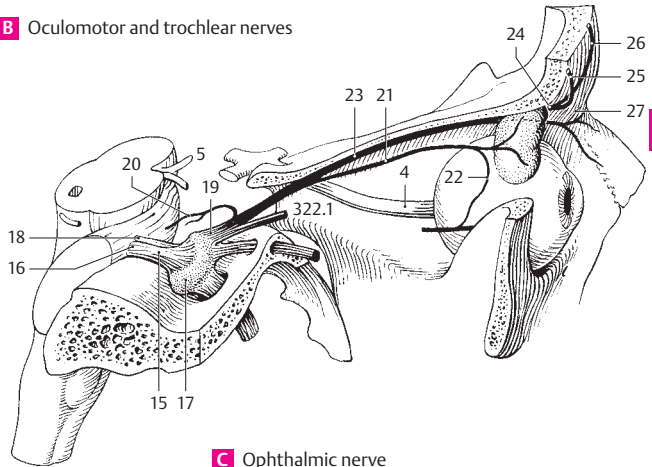
- 1 **Peripheral nervous system.** Pars peripherica (systema nervosum periphericum). The peripheral part of the nervous system which includes all peripheral conducting tracts (nerves). The border between it and the central nervous system lies at the surface of the brain and spinal cord.
- 2 **CRANIAL NERVES.** Nervi craniales (encephalici). The 12 pairs of nerves connected with the brain. With the exception of the trochlear (IV), all of them emerge from the base of the brain and exit through the base of the skull (in contrast to the spinal nerves). Area of distribution: head, neck, as well as the thorax and abdomen (via vagus nerve).
- 3 **OLFACTORY NERVE (I).** Nn. olfactorii (I). First cranial nerve, which is formed by about 20 small bundles of nonmyelinated axons from the olfactory cells. It passes through the cribriform plate of the ethmoid into the olfactory bulb (synaptic site). A
- 4 **OPTIC NERVE (II).** N. opticus [II]. Second cranial nerve which leaves the eyeball medial to the posterior optic pole and extends up to the optic chiasm. B C
- 5 **OCULOMOTOR NERVE (III).** N. oculomotorius [III]. Third cranial nerve, which exits from the sulcus on the medial side of the cerebral peduncle. This motor nerve (somatic and visceral) passes into the orbit through the superior orbital fissure. B C
- 6 **Superior ramus (division).** Ramus superior. Superior branch for the superior rectus and levator palpebrae superioris muscles. B
- 7 **Inferior ramus (division).** Ramus inferior. Inferior branch for the medial and inferior recti and inferior oblique muscles. B
- 8 **Ciliary ganglion.** Ganglion ciliare. Located about 2 cm behind the eyeball and lateral to the optic nerve. This parasympathetic ganglion serves as a relay station for fibers innervating the ciliary and sphincter pupillae muscles. B
- 9 **Parasympathetic (motor) root.** Radix parasympathetica (oculomotoria). Branch of the oculomotor nerve with preganglionic, parasympathetic fibers projecting to the ciliary ganglion. B
- 10 **Short ciliary nerves.** Nn. ciliares breves. Several (up to 20) nerves penetrating the sclera above and below the optic nerve and carrying postganglionic, parasympathetic and sympathetic fibers. B
- 11 **Sympathetic root.** Radix sympathetica. Fine, postganglionic fiber tract from the internal carotid plexus with no synapses in the ciliary ganglion. B
- 12 **Sensory root.** Radix sensoria (nasociliaris). Fine, long connection with afferent fibers to the nasociliary nerve. B
- 13 **TROCHLEAR NERVE (IV).** N. trochlearis [IV]. Fourth cranial nerve. Thin nerve exiting dorsal and caudal to the tectal lamina and supplying the superior oblique muscle. B
- 14 **Decussation of trochlear nerve.** Decussatio nervorum trochlearium. The crossing of trochlear nerve fibers in the superior medullary velum. B
- 15 **TRIGEMINAL NERVE (V).** N. trigeminus [V]. Fifth cranial nerve (nerve of the 1st pharyngeal arch). Nerve that exits laterally from the pons with two groups of fibers, supplies the masticatory muscles and provides sensory innervation to the face. B C
- 16 **Sensory root of trigeminal nerve.** Radix sensoria [portio major]. Sensory part which exits from the pons caudally and enters the trigeminal ganglion. C
- 17 **Trigeminal (semilunar, gasserian) ganglion.** Ganglion trigeminale [[semilunare; Gasserii]]. Semilunar ganglion that is equivalent to a spinal ganglion. It is located in an outpocketing of the subarachnoid space (cavum trigeminale) above the foramen lacerum at the medial, anterior border of the petrous part of the temporal bone. C
- 18 **Motor root.** Radix motoria [portio minor]. Motor portion of trigeminal nerve for innervation of the masticatory muscles. It is situated cranially at the exit of the trigeminal nerve and below the trigeminal ganglion. C
- 19 **Ophthalmic nerve.** N. ophthalmicus. First division (branch) of trigeminal nerve. It passes through the superior orbital fissure. C
- 20 **Tentorial (meningeal) branch.** Ramus tentorii (meningeus). Recurrent nerve for the tentorium cerebelli and falx cerebri. C
- 21 **Lacrimal nerve.** N. lacrimalis. Passes laterally through the superior orbital fissure and supplies the lacrimal gland, conjunctiva and lateral portion of upper eyelid. C
- 22 **Communicating ramus with zygomatic nerve.** Ramus communicans [cum. n. zygomatico]. Connection to the zygomatic nerve with autonomic fibers extending from the pterygopalatine ganglion to the lacrimal gland. C
- 23 **Frontal nerve.** N. frontalis. Nerve that enters the orbit through the superior orbital fissure. It lies on the levator palpebrae superioris and continues toward the forehead. C; see also p. 323 A
- 24 **Supraorbital nerve.** N. supraorbitalis. Thickest branch of the frontal nerve. It supplies the conjunctiva, upper eyelid, frontal sinus and the skin of the forehead. C
- 25 **Lateral branch.** Ramus lateralis. It passes through the supra-orbital notch. C
- 26 **Medial branch.** Ramus medialis. It passes medially through the frontal notch. C
- 27 **Supratrochlear nerve.** N. supratrochlearis. Thin, medial branch of frontal nerve. It divides at the medial angle of the eye to form an ascending and descending branch. C



A Olfactory nerve

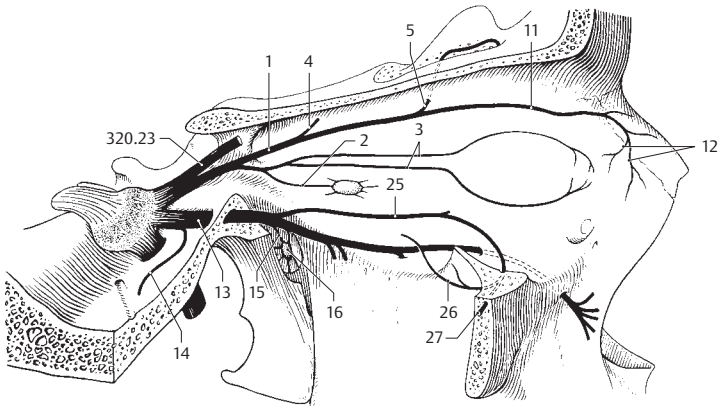


B Oculomotor and trochlear nerves

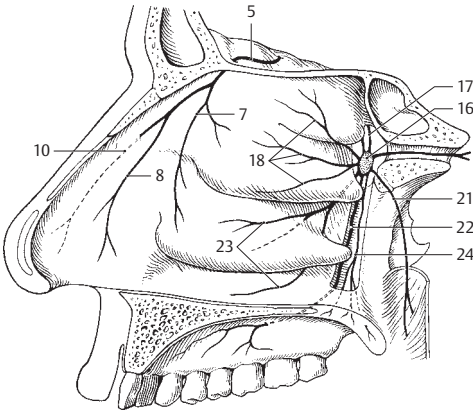


C Ophthalmic nerve

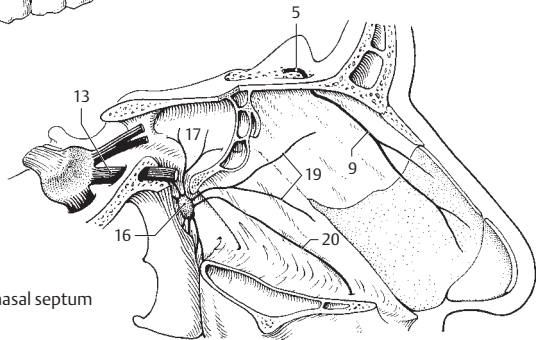
- 1 **Nasociliary nerve.** N. nasociliaris. Most medial branch of the ophthalmic nerve. It courses below the superior rectus and between the superior oblique and medial rectus. A
- 2 **Communicating branch of nasociliary nerve with ciliary ganglion.** Ramus communicans [cum ganglio ciliari]. Any branch carrying sensory fibers from the eye through the ciliary ganglion to the nasociliary nerve. A
- 3 **Long ciliary nerves.** Nn. ciliares longi. Two long, fine twigs with sympathetic fibers supplying the dilator pupillae muscle and afferent fibers from the iris, ciliary body and cornea. A
- 4 **Posterior ethmoidal nerve.** N. ethmoidalis posterior. Thin nerve at the posterior end of the orbit supplying the sphenoidal sinus and posterior ethmoidal cells. A
- 5 **Anterior ethmoidal nerve.** N. ethmoidalis anterior. Nerve that enters the cranial cavity (extradural part) through the anterior ethmoidal foramen. It then courses through the cribriform plate of the ethmoid into the nasal cavity. A B C
- 6 **Nasal branches of anterior ethmoidal nerve.** Rami nasales [n. ethmoidalis anterior]. Collective term for the following four branches of the anterior ethmoidal nerve.
- 7 **Internal nasal branches.** Rami nasales interni. Rami that innervate the nasal mucosa in front of the conchae and for the anterior nasal septum. B
- 8 **Lateral nasal branches.** Rami nasales laterales. Innervate the anterior part of lateral nasal wall. B
- 9 **Medial nasal branches.** Rami nasales mediales. Innervate the anterior part of the nasal septum. C
- 10 **External nasal branch.** Ramus nasalis externus. Innervates the skin on the tip of the nose and the nasal ala; it passes through the ethmoidal sulcus of the nasal bone. B
- 11 **Infratrochlear nerve.** N. infratrochlearis. It passes below the trochlea of the superior oblique at the inner angle of the eye and supplies the lacrimal sac, lacrimal caruncle and surrounding skin. A
- 12 **Palpebral branches.** Rami palpebrales. Rami for part of the upper and lower eyelids. A
- 13 **Maxillary nerve.** N. maxillaris. Second division (branch) of trigeminal nerve. It passes through the foramen rotundum to the pterygopalatine fossa and subsequently through the inferior orbital fissure into the orbit. A C
- 14 **Meningeal nerve.** Ramus meningeus [medius]. Branch given off in front of the foramen rotundum. It supplies the dura in the region of the frontal branch of the middle meningeal artery. A
- 15 **Ganglionic branches.** Rami ganglionici (ganglionares). Usually two rami from the pterygopalatine ganglion. They contain autonomic fibers for the lacrimal gland and sensory fibers from the periorbit of the orbit. A
- 16 **Pterygopalatine ganglion.** Ganglion pterygopalatinum. Parasympathetic ganglion located in the corresponding fossa close to the sphenopalatine foramen. Their postganglionic fibers innervate the lacrimal and nasal glands. A B C
- 16a **Parasympathetic root.** Radix parasympathetica. Communicates with the greater petrosal nerve.
- 16b **Sympathetic root.** Radix sympathetica. Communicates with the deep petrosal nerve.
- 16c **Sensory root.** Radix sensoria. Communicates with the maxillary nerve.
- 17 **Orbital branches.** Rami orbitales. Two to three fine rami which pass into the orbit through the inferior orbital fissure, then through the bone to the posterior ethmoidal cells and to the sphenoidal sinus. B C
- 18 **Lateral posterior superior nasal branches.** Rami nasales posteriores superiores laterales. Up to 10 fine rami which pass through the sphenopalatine foramen to the superior and middle nasal conchae and to the posterior ethmoidal cells. B
- 19 **Medial posterior superior nasal branches.** Rami nasales posteriores superiores mediales. Two to three branches which pass through the sphenopalatine foramen to the upper part of the nasal septum. C
- 20 **Nasopalatine nerve.** N. nasopalatinus [[incisivus]]. It passes between the periosteum and mucosa of the nasal septum, then through the incisive canal to the anterior part of the palatine mucosa and the gingiva of the upper incisor teeth. C
- 20a **Long nasopalatine nerve.** Nervus nasopalatinus longus.
- 20b **Branches to nasal septum.** Rami septales nasales.
- 20c **Short nasopalatine nerves.** Nervi nasopalatini breves.
- 20d **Lateral nasal branches.** Rami nasales laterales.
- 20e **Branches to maxillary sinus.** Rami sinus maxillaris.
- 21 **Pharyngeal nerve.** Nervus pharyngeus. Fine nerve for the pharyngeal mucosa. B
- 22 **Greater palatine nerve.** N. palatinus major. After passing through the greater palatine canal, it courses through the corresponding foramen and supplies the mucosa of the hard palate and its glands. B
- 23 **Posterior inferior nasal branches.** Rami nasales posteriores inferiores. Rami for the middle and inferior nasal meatuses as well as the inferior nasal concha. B
- 24 **Lesser palatine nerves.** Nn. palatini minores. They travel in their respective, slender canals, exit through the lesser palatine foramina and supply the soft palate. B
- 24a **Tonsillar branches.** Rami tonsillares. Branches to the palatine tonsil.
- 25 **Zygomatic nerve.** N. zygomaticus. It branches into the pterygopalatine fossa, passes through the inferior orbital fissure to the lateral wall of the orbit and provides an anastomotic branch to the lacrimal gland. A
- 26 **Zygomaticotemporal branch.** Ramus zygomaticotemporalis. It passes through the respective foramen to the lateral wall of the orbit. A
- 27 **Zygomatofacial branch.** Ramus zygomatofacialis. It passes through the corresponding foramen to the skin on the zygomatic bone. A



A Nasociliary and maxillary nerves

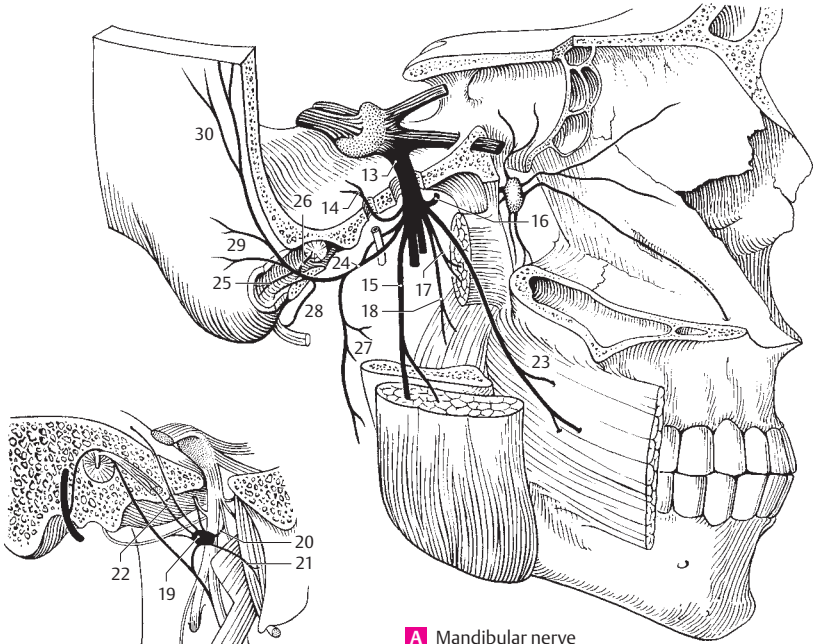


B Pterygopalatine ganglion and anterior ethmoidal nerve



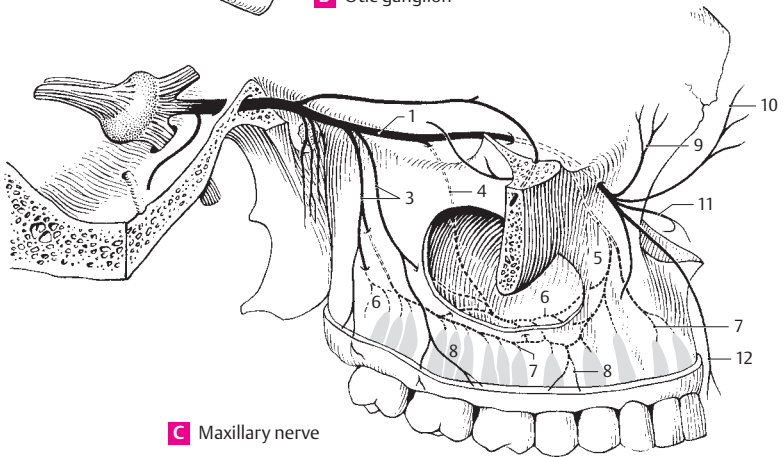
C Nerves of nasal septum

- 1 **Infraorbital nerve.** N. infraorbitalis. Terminal branch of maxillary nerve. It passes through the inferior orbital fissure and corresponding sulcus and foramen to the skin of the upper eyelid, nose, upper lip and cheek. C
- 2 **Superior alveolar nerves.** Nn. alveolares superiores. Branches to the maxillary teeth.
- 3 **Posterior superior alveolar branches.** Rami alveolares superiores posteriores. Two to three branches passing through the alveolar foramina to the inner surface of the maxilla. They supply the maxillary sinus and the molars including their buccal gingiva. C
- 4 **Middle superior alveolar branch.** R. alveolaris superior medius. It courses through the infraorbital sulcus to the maxilla and passes along the lateral wall of the maxillary sinus up to the superior dental plexus. C
- 5 **Anterior superior alveolar branches.** Rami alveolares superiores anteriores. They run in their respective canals and via the superior dental plexus to the incisors, canines, premolars and first molar tooth. C
- 6 **Superior dental plexus.** Plexus dentalis superior. Nerve plexus in the bone above the roots of the teeth formed by the superior alveolar rami. C
- 7 **Superior dental branches.** Rami dentales superiores. Branches to the individual roots of the teeth. C
- 8 **Superior gingival branches.** Rami gingivales superiores. Rami to the gingiva. C
- 9 **Inferior palpebral branches.** Rami palpebrales inferiores. Rami given off to the lower eyelid outside of the infraorbital foramen. C
- 10 **External nasal branches.** Rami nasales externi. Branches to the outside of the nasal ala. C
- 11 **Internal nasal branches.** Rami nasales interni. Branches to the skin of the nasal vestibule. C
- 12 **Superior labial branches.** Rami labiales superiores. Rami to the skin and mucosa of the upper lip. C
- 13 **Mandibular nerve.** N. mandibularis. Third division (branch) of the trigeminal nerve. It passes through the foramen ovale and into the infratemporal fossa. Besides sensory fibers, it contains motor fibers for the masticatory muscles. A
- 14 **Meningeal branch (nervus spinosus).** Ramus meningeus (n. spinosus). It passes through the foramen spinosum accompanied by both branches of the middle meningeal artery and supplies the dura, a part of the sphenoidal sinus and the mastoid air cells. A
- 15 **Masseteric nerve.** N. massetericus. Motor nerve for the masseter muscle passing above the lateral pterygoid muscle and through the mandibular notch. A
- 16 **Deep temporal nerves.** Nn. temporales profundi. Motor nerves passing to the temporalis muscle from below. A
- 17 **Nerve to lateral pterygoid.** N. pterygoideus lateralis. Motor nerve for the corresponding muscle. It frequently arises together with the buccal nerve. A
- 18 **Nerve to medial pterygoid.** N. pterygoideus medialis. Motor nerve for the corresponding muscle. It also sends small twigs to the tensor veli palatini and tensor tympani muscles. A
- 19 **Otic ganglion.** Ganglion oticum. Parasympathetic ganglion located medial to the mandibular nerve below the foramen ovale. It receives tributaries from the glossopharyngeal nerve via the lesser petrosal nerve and sends secretory fibers to the parotid gland. B
- 20 **Ramus communicans [cum nervo pterygoideo mediali].** Branch which communicates with the nerve to the medial pterygoid muscle. B
- 21 **Nerve to tensor veli palatini muscle.** N. musculi tensoris veli palatini. It sometimes arises from the nerve to the medial pterygoid muscle. B
- 22 **Nerve to tensor tympani muscle.** N. musculi tensoris tympani. It also sometimes arises from the nerve to the medial pterygoid muscle. B
- 23 **Buccal nerve.** N. buccalis. Sensory nerve for the skin and mucosa of the cheek and the buccal gingiva in the region of the first molar. A
- 24 **Auriculotemporal nerve.** N. auriculotemporalis. It usually encircles the middle meningeal artery, sends a small branch to the temporomandibular joint and then passes upward between the ear and superficial temporal artery to the skin of the temporal region. A
- 25 **Nerve to external acoustic meatus.** N. meatus acustici externi. Usually two small branches for the skin of the external acoustic meatus. A
- 26 **Fine branches to the tympanic membrane.** Rami membranae tympani. A
- 27 **Parotid branches.** Rami parotidei. Small branches supplying the parotid gland. A
- 28 **Branches communicating with the facial nerve.** Rami communicantes [cum n. faciali]. They carry parasympathetic fibers from the otic ganglion to the parotid gland via the facial nerve. A
- 29 **Anterior auricular nerves.** Nn. auriculares anteriores. They supply the anterior surface of the pinna. A
- 30 **Superficial temporal rami.** Rami temporales superficialis. Branches supplying the skin of the temporal region in front of and above the ear. A



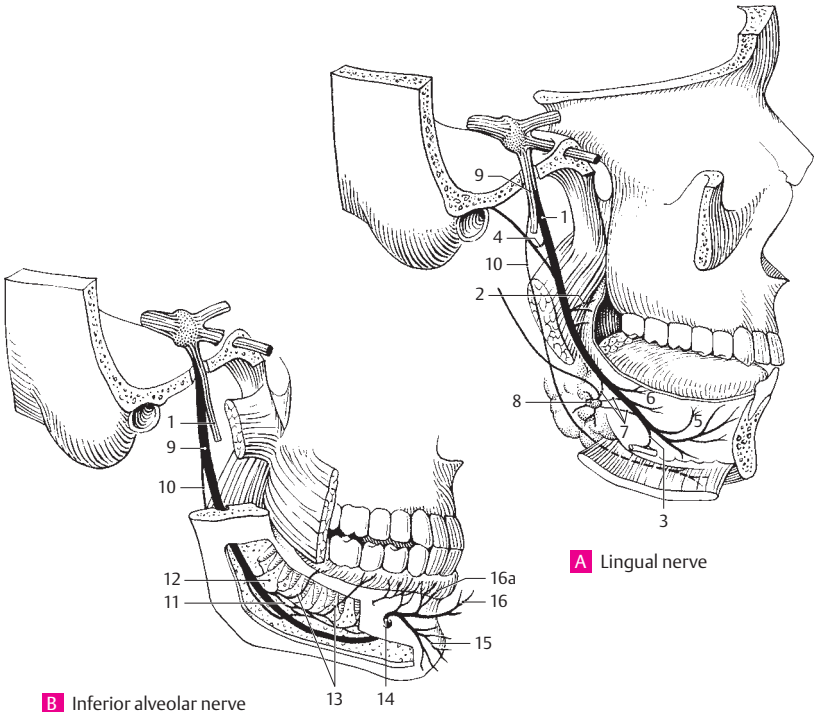
A Mandibular nerve

B Otic ganglion



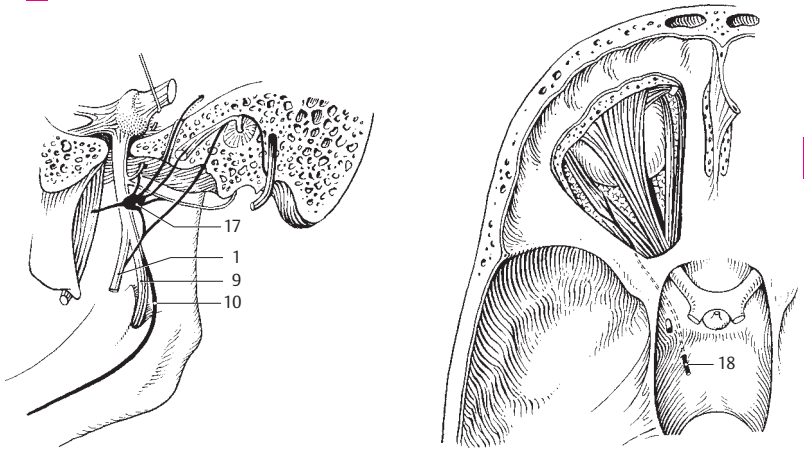
C Maxillary nerve

- 1 **Lingual nerve.** N. lingualis. A branch of the mandibular nerve that arches anteriorly between the lateral and medial pterygoid muscles to the floor of the mouth where it lies near a wisdom tooth directly below the mucosa. A B C
- 2 **Branches to isthmus of the fauces.** Rami isthmi faucium (rami fauciales). It also branches to the tonsils. A
- 3 **Communicating rami to the hypoglossal nerve.** Rami communicantes [cum n. hypoglossus]. It lies on the hyoglossus muscle. A
- 4 **Communicating ramus to the chorda tympani nerve.** Ramus communicans [cum chorda tympani]. A
- 5 **Sublingual nerve.** N. sublingualis. It passes lateral to the sublingual gland into the mucosa of the floor of the mouth and into the gingiva of the anterior mandibular teeth. A
- 6 **Lingual branches.** Rami linguales. Numerous rami containing sensory and taste fibers from the anterior two-thirds of the lingual mucosa. A
- 7 **Ganglionic branches.** Rami ganglionares. Rami communicating with the submandibular ganglion. A
- 8 **Submandibular ganglion.** Ganglion submandibulare. Parasympathetic ganglion above or in front of the submandibular gland. Synaptic station for preganglionic fibers of the chorda tympani with postganglionic fibers for the sublingual and submandibular glands. A
- 9 **Inferior alveolar nerve.** N. alveolaris inferior. Largest branch of mandibular nerve with sensory and motor components. It passes 1 cm behind the lingual nerve and through the mandibular foramen into the mandibular canal. A B C
- 10 **Mylohyoid nerve.** N. mylohyoideus. Coursing in the mylohyoid groove and then below the mylohyoid muscle, this motor nerve supplies the mylohyoid muscle and the anterior belly of the digastric. A B C
- 18 **Inferior dental plexus.** Plexus dentalis inferior. Plexus of nerves within the mandibular canal. B
- 12 **Inferior dental branches.** Rami dentales inferiores. Rami for the mandibular teeth. B
- 13 **Inferior gingival branches.** Rami gingivales inferiores. Rami for the buccal gingiva of the mandibular teeth (except for the first molar). B
- 14 **Mental nerve.** N. mentalis. Sensory nerve exiting from the mental foramen below the 2nd premolar tooth. B
- 15 **Mental branches.** Rami mentales. Branches supplying the chin. B
- 16 **Labial branches.** Rami labiales. Branches supplying the lower lip. B
- 16a **Gingival branches.** Rami gingivales. B
- 17 **Otic ganglion.** Ganglion oticum. Parasympathetic ganglion located medial to the mandibular nerve below the foramen ovale. It communicates with the glossopharyngeal nerve via the lesser petrosal nerve and sends secretory fibers into the parotid gland. C
- 18 **ABDUCENT NERVE (VI).** N. abducens [VI]. Sixth cranial nerve. It exits the brain in the angle between the pons and pyramid, penetrates the dura at the level of the middle of the clivus, passes laterally into the cavernous sinus and then through the inferior orbital fissure into the orbit where it supplies the rectus lateralis muscle. D



A Lingual nerve

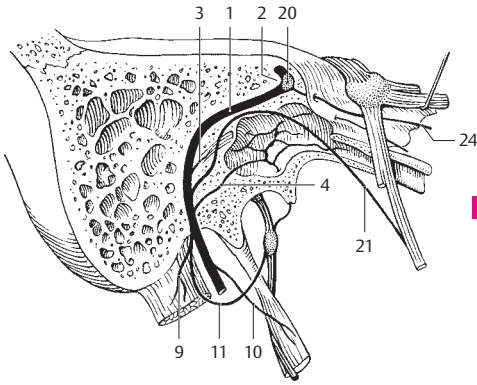
B Inferior alveolar nerve



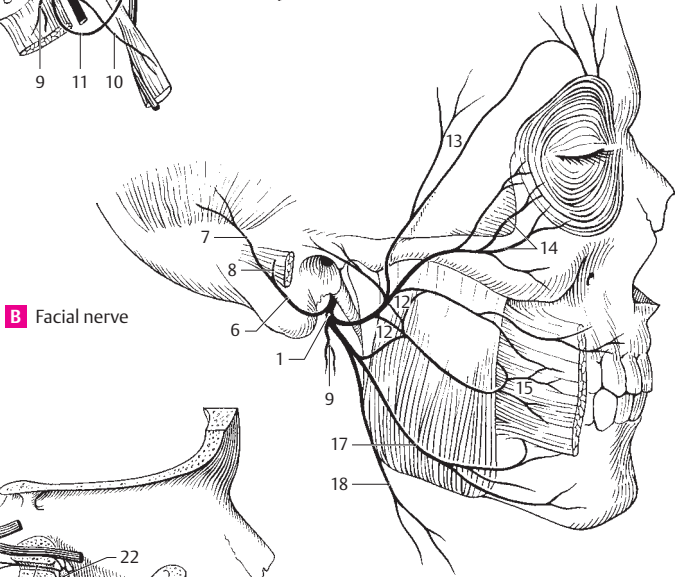
C Otic ganglion and branches

D Abducent nerve

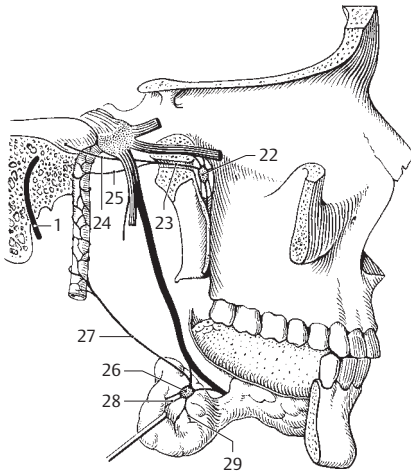
- 1 **FACIAL NERVE (VII).** N. facialis (n. intermedio-facialis) [VII]. Seventh cranial nerve (nerve of the 2nd pharyngeal arch). It exits between the pons and olive, passes with the vestibulocochlear nerve into the petrous temporal bone and leaves it through the stylomastoid foramen. It supplies the muscles of facial expression. A B C D
- 2 **Genu of facial nerve.** Geniculum [n. facialis]. Bend in the facial nerve just below the anterior wall of the petrous temporal bone. A
- 3 **Nerve to the stapedius.** N. stapedius. Slender branch supplying the stapedius muscle. A
- 4 **Communicating branch of facial nerve with tympanic plexus.** Ramus communicans [cum plexus tympanico]. A
- 5 **Communicating branch of facial nerve with vagus nerve.** Ramus communicans [cum nervo vago]. Located directly below the stylomastoid foramen.
- 6 **Posterior auricular nerve.** N. auricularis posterior. Ramifies beneath the stylomastoid foramen, passes upward between the mastoid process and the external acoustic meatus and supplies the posterior ear muscles and the occipital belly of the occipitofrontalis muscle. B
- 7 **Occipital branch.** Ramus occipitalis. Ramus supplying the occipital belly of the occipitofrontalis muscle. B
- 8 **Auricular branch.** Ramus auricularis. Branch to the muscles of the pinna. B
- 9 **Digastric branch.** Ramus digastricus. It supplies the posterior belly of the digastric muscle. A B
- 10 **Stylohyoid branch.** Ramus stylohyoideus. Branch that often arises together with the lingual branch. It supplies the stylohyoid muscle. A
- 11 **Communicating branch of facial nerve with glossopharyngeal nerve.** Ramus communicans [cum n. glossopharyngeo]. A
- 12 **Intraparotid plexus.** Plexus intraparotideus. Facial nerve plexus situated in the space accessible anteriorly between the two parotid lobes. B
- 13 **Temporal branches.** Rami temporales. Rami ascending over the zygomatic arch to the muscles of facial expression above the palpebral fissure and along the ear. B
- 14 **Zygomatic branches.** Rami zygomatici. Rami supplying the lateral part of the orbicularis oculi and the muscles of facial expression between the palpebral and oral fissures. B
- 15 **Buccal branches.** Rami buccales. Rami supplying the buccinator muscle and the muscles of facial expression around the mouth. B
- 16 **Lingual branch.** Ramus lingualis. Inconstant ramus to the tongue. It sometimes arises in together with the stylohyoid ramus.
- 17 **Marginal mandibular branch.** Ramus marginalis mandibularis. It passes to the chin and supplies the muscles of facial expression below the oral fissure. B
- 18 **Cervical branch.** Ramus colli (cervicalis). Motor branch for the platysma. It anastomoses with the transverse cervical nerve. B
- 19 **Sensory root of facial nerve.** N. intermedius. It arises from the brainstem independently between the facial and vestibular nerves and transports autonomic and taste fibers. After anastomosing with various vessels, it ultimately unites with the facial nerve in the petrous part of the temporal bone. D
- 20 **Geniculate (facial) ganglion.** Ganglion geniculi (geniculatum). Equivalent to a spinal ganglion with pseudo-unipolar ganglion cells. It is located in the petrous part of the temporal bone at the bend of the facial nerve. It receives taste fibers from the chorda tympani. A
- 21 **Chorda tympani.** Nerve bundle with parasympathetic fibers for the submandibular gland and sensory fibers from the taste buds occupying the anterior two-thirds of the tongue. It returns to the tympanic cavity where it passes between the malleus and incus, then goes through the petrotympanic fissure [[Glaser] or sphenopetrosal fissure to subsequently join the lingual nerve. A
- 22 **Pterygopalatine ganglion.** Ganglion pterygopalatinum. Parasympathetic ganglion located in its respective fossa near the sphenopalatine foramen. It receives preganglionic fibers from the facial nerve via the greater petrosal nerve and sends postganglionic secretory fibers to the lacrimal and nasal glands. C
- 23 **Nerve of pterygoid canal.** N. canalis pterygoidei [Radix facialis]. Located in the pterygoid canal at the root of the pterygoid process. It contains parasympathetic (facial nerve), sympathetic and sensory fibers destined for the pterygopalatine ganglion. C
- 24 **Greater petrosal nerve.** N. petrosus major. Branch of facial nerve emerging from the anterior wall of the petrous part of the temporal bone. It incorporates parasympathetic and sensory fibers, and penetrates the covering plate of the foramen lacerum lateral to the internal carotid artery where it is joined by the deep petrosal nerve. A C
- 25 **Deep petrosal nerve.** N. petrosus profundus. Nerve carrying sympathetic fibers from the internal carotid plexus; it joins the greater petrosal nerve to form the nerve of the pterygoid canal. C
- 26 **Submandibular ganglion.** Ganglion submandibulare. Located above or in front of the submandibular gland. This parasympathetic ganglion is the synaptic site between preganglionic fibers from the chorda tympani and postganglionic fibers to the sublingual and submandibular glands. C
- 27 **Sympathetic branch (to the submandibular ganglion).** Ramus sympathicus (ad ganglion submandibulare). Branch from the internal carotid plexus. Its fibers arrive at the submandibular ganglion above the facial artery and pass through the ganglion without synapsing. C
- 28 **Glandular branches.** Rami glandulares. Small rami at the inferior margin of the submandibular ganglion that supply the submandibular gland. C
- 29 **Sublingual ganglion.** [Ganglion sublinguale]. Small group of cells occasionally present on the glandular rami. C



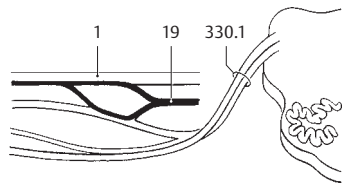
A Facial nerve in temporal bone



B Facial nerve

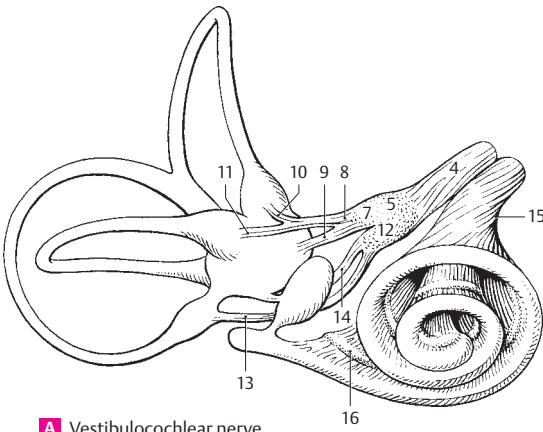


C Pterygopalatine and submandibular ganglia

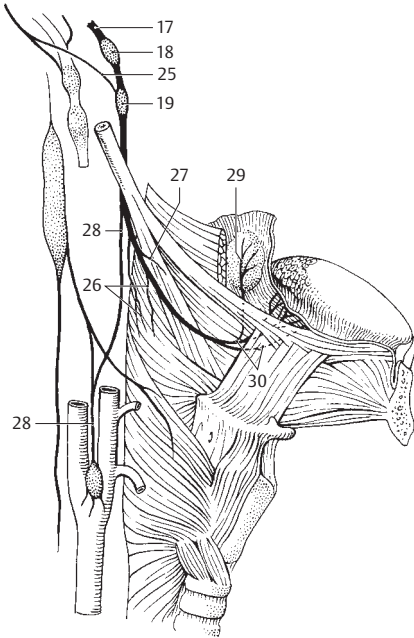
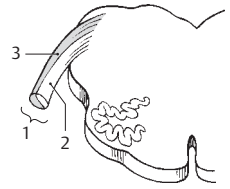


D Facial and vestibulocochlear nerves

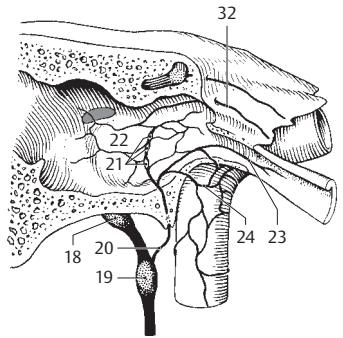
- 1 **VESTIBULOCOCHLEAR NERVE (VIII).** N. vestibulocochlearis [VIII]. Eighth cranial nerve. Nerve that exits at the lower margin of the pons and passes through the internal acoustic meatus to the vestibular (equilibrium) and auditory organs. A
- 2 **Vestibular nerve.** N. vestibularis. Superior, ventral, vestibular portion of vestibulocochlear nerve. A
- 3 **Cochlear nerve.** Nervus cochlearis. Inferior, dorsal, cochlear part of vestibulocochlear nerve. A
- 4 **Vestibular nerve.** Nervus vestibularis. Portion of VIII nerve passing from the vestibular nucleus to the maculae and ampullary crest. A
- 5 **Vestibular ganglion.** Ganglion vestibulare. Ganglion located in the floor of the internal acoustic meatus. It contains bipolar neurons associated with the vestibular nerve. A
- 6 **Communicating branch with cochlear nerve.** Ramus communicans cochlearis.
- 7 **Upper part of vestibular ganglion.** Pars superior. It supplies the anterior and lateral semicircular canals, utricle and anterior part of sacculus. A
- 8 **Utriculoampullar nerve.** N. utriculoampullaris. Superior branch of vestibular nerve with fibers from the macula and ampullary crest of the superior (anterior) and lateral semicircular canals. A
- 9 **Utricular nerve.** N. utricularis. Branch from the macula utriculi. A
- 10 **Anterior ampullar nerve.** N. ampullaris anterior. Branch from the ampullary crest of the anterior semicircular canal. A
- 11 **Lateral ampullar nerve.** N. ampullaris lateralis. Branch from the ampullary crest of the lateral semicircular canal. A
- 12 **Inferior part of the vestibular ganglion.** Pars inferior. It supplies the posterior semicircular canal and a part of the sacculus. A
- 13 **Posterior ampullar nerve.** N. ampullaris posterior. Branch from the ampullary crest of the posterior semicircular canal. A
- 14 **Saccular nerve.** N. saccularis. Branch from the macula sacculi. A
- 15 **Cochlear nerve.** Nervus cochlearis. Part of the vestibulocochlear nerve for the auditory organ in the cochlea. A
- 16 **Cochlear (spiral) ganglion.** Ganglion cochleare (spiral cochleae). Helical band of ganglion cells directed towards the axis of the cochlea and situated along the base of the osseous spiral lamina. A
- 17 **GLOSSOPHARYNGEAL NERVE (IX).** N. glossopharyngeus [IX]. Ninth cranial nerve (nerve of the 3rd pharyngeal arch). It leaves the brain through the posterolateral sulcus behind the olive, courses through the jugular foramen and passes obliquely downward posterior to the stylopharyngeus muscle. It contains motor fibers for the pharyngeal constrictors and stylopharyngeus muscle and sensory fibers for the pharyngeal mucosa, tonsils and posterior third of the tongue (taste fibers) and parasympathetic fibers to the otic ganglion via the tympanic and lesser petrosal nerves. B
- 18 **Superior (jugular) ganglion.** Ganglion superius [intracraniale]. Smaller ganglion in the jugular foramen. It contains cell bodies of afferent fibers. B C
- 19 **Inferior (petrous) ganglion.** Ganglion inferius [extracraniale]. Larger ganglion situated directly below the jugular foramen. It contains cell bodies of afferent fibers. B C
- 20 **Tympanic nerve.** N. tympanicus. First branch of the IX nerve. It branches off from the inferior ganglion and passes between the jugular foramen and carotid canal, then through the tympanic canaliculus to the tympanic cavity. C
- 21 **Tympanic enlargement (ganglion).** Intumescencia tympanica (ganglion tympanicum). Irregularly scattered ganglion cells forming a dilatation in the course of the tympanic nerve. C
- 22 **Tympanic plexus.** Plexus tympanicus. N. plexus in the mucosa over the promontory. It is formed by the tympanic n., internal carotid plexus and communicating ramus of the facial n. with the tympanic plexus. C
- 23 **Tubal branch of tympanic plexus.** Ramus tubarius (tubalis). Ramus for the auditory tube. C
- 24 **Caroticotympanic nerves.** Nn. caroticotympanici. Sympathetic fibers of the tympanic plexus derived from the internal carotid plexus. C
- 25 **Communicating branch of glossopharyngeal nerve with auricular branch of the vagus nerve.** Ramus communicans [cum ramo auriculari nervi vagi]. Fine branch from the inferior ganglion to the auricular ramus of the vagus. B
- 26 **Pharyngeal branches of IX nerve.** Rami pharyngeales (pharyngei). Three to four rami passing into the pharyngeal plexus. B
- 27 **Ramus to stylopharyngeus muscle.** Ramus m. stylopharyngei. B
- 28 **Branch to carotid sinus.** Ramus sinus carotici. It also passes to the carotid body and communicates with the sympathetic trunk and vagus nerve. B
- 29 **Tonsillar branches.** Rami tonsillares. Branches supplying the mucosa of the palatine tonsil and its surroundings. B
- 30 **Lingual branches.** Rami linguales. Taste fibers from the posterior third of the tongue including the vallate papillae which are also supplied by the lingual nerve via the chorda tympani. B
- 31 **Otic ganglion.** Ganglion oticum. Parasympathetic ganglion located medial to the mandibular nerve below the foramen ovale. It receives preganglionic fibers from the glossopharyngeal nerve via the lesser petrosal nerve and sends postganglionic secretory fibers to the parotid gland. D
- 32 **Lesser petrosal nerve.** N. petrosus minor. Nerve containing parasympathetic fibers from the glossopharyngeal nerve. It emerges from the tympanic plexus, penetrates the anterior wall of the petrous temporal bone and leaves the middle cranial fossa through the sphenopetrosal fissure. Its fibers synapse in the otic ganglion. C D
- 33 **Communicating branch with the meningeal branch.** Ramus communicans [cum ramo meningeo]. D
- 34 **Communicating branch with auriculo-temporal nerve.** Ramus communicans [cum n. auriculotemporalis]. It includes postganglionic parasympathetic fibers that supply the parotid gland. D
- 35 **Communicating branch with chorda tympani.** Ramus communicans [cum chorda tympani]. It contains sensory nerve fibers. D



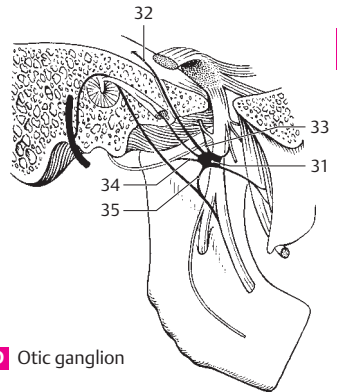
A Vestibulocochlear nerve, schematic



B Glossopharyngeal and vagus nerves



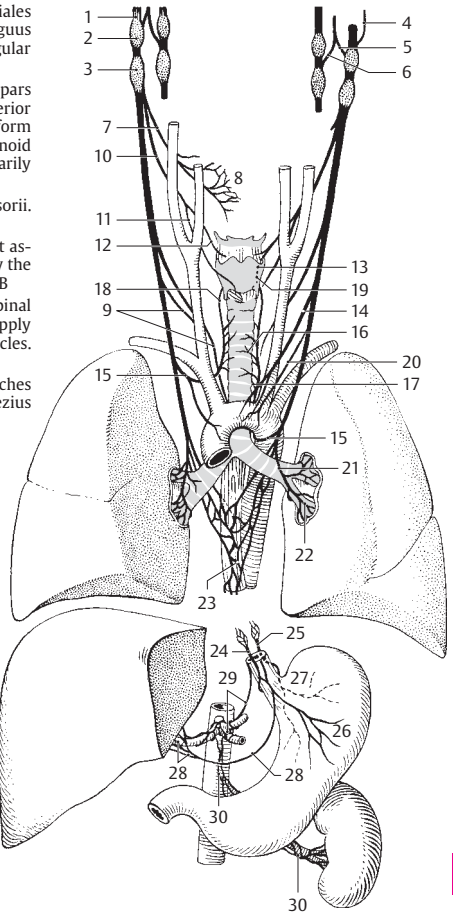
C Tympanic nerve with branches



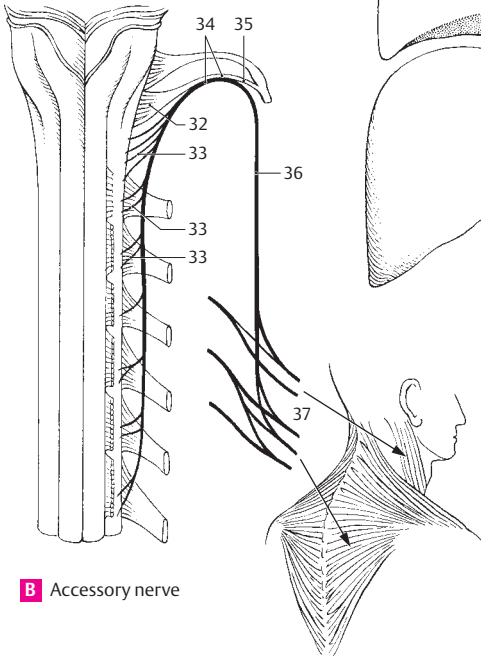
D Otic ganglion

- 1 **VAGUS NERVE (X).** N. vagus [X]. Tenth cranial nerve (nerve of 4th and 5th pharyngeal arches). Together with the IX nerve, it exits the brain in the posterolateral sulcus and passes through the jugular foramen. Its supply region extends into the thoracic and abdominal cavities. A
- 2 **Superior (jugular) ganglion.** Ganglion superius. Small superior sensory ganglion of vagus situated in the jugular foramen. A
- 3 **Inferior (nodose) ganglion.** Ganglion inferius. Large inferior, spindle-shaped ganglion of the vagus nerve. A
- 4 **Meningeal branch.** Ramus meningeus. Recurrent branch from the superior ganglion supplying the dura of the posterior cranial fossa in the region of the transverse and occipital sinuses. A
- 5 **Auricular branch.** Ramus auricularis. Branch that arises from the superior ganglion of the vagus nerve, passes through the mastoid canal, exits through the tympanomastoid fissure and supplies the posterior surface of the pinna and the posterior-inferior wall of the external acoustic meatus. A
- 6 **Communicating branch with IX nerve.** Ramus communicans [cum. n. glossopharyngeo]. Anastomotic branch from the auricular ramus to the glossopharyngeal nerve. A
- 7 **Pharyngeal branch.** Ramus pharyngealis (pharyngei). Branch radiating into the pharyngeal plexus. A
- 8 **Pharyngeal plexus.** Plexus pharyngealis. Nerve plexus below the middle pharyngeal constrictor formed by the glossopharyngeal and vagus nerves and the cervical sympathetic trunk. A
- 9 **Superior cervical cardiac branches.** Rami cardiaci cervicales superiores. Branches given off at variably high cervical levels; they travel to the deep part of the cardiac plexus. A
- 10 **Superior laryngeal nerve.** N. laryngealis superior. Nerve that arises from the inferior ganglion and passes downward medial to the internal carotid artery to supply the larynx. A
- 11 **External branch of superior laryngeal nerve (external laryngeal nerve).** Ramus externus. Nerve that branches to the inferior pharyngeal constrictor and then, covered by the infrahyoid musculature, passes to the cricothyroid muscle. A
- 12 **Internal branch (internal laryngeal nerve).** Ramus internus. Together with the superior laryngeal artery, it penetrates the thyrohyoid membrane and emerges below the mucosa of the piriform recess. It supplies the mucosae of the epiglottic valleculae, the epiglottis and the larynx as far down as the level of the vocal folds. A
- 13 **Branch communicating with the recurrent laryngeal nerve.** Ramus communicans [cum. n. laryngeali recurrenti]. A
- 14 **Inferior cervical cardiac branches.** Rami cardiaci cervicales inferiores. On the right, they pass to the deep part of the cardiac plexus; on the left, they pass to the superficial part of the cardiac plexus accompanied by the vagus nerve. A
- 15 **Recurrent laryngeal nerve.** N. laryngealis recurrens. On the right, it loops around the subclavian artery whereas, on the left, it curves around the arch of the aorta before ascending in the groove between the trachea and esophagus. Its terminal branch penetrates the inferior pharyngeal constrictor and enters the larynx, where it supplies the mucosa up to the vocal folds and all intrinsic laryngeal muscles except the cricothyroid. It also provides a communicating branch to the internal laryngeal nerve. A
- 16 **Tracheal branches.** Rami tracheales. A
- 17 **Esophageal branches.** Rami oesophageales. A
- 17 a **Rami pharyngeales.** Pharyngeal branches to the inferior pharyngeal constrictor.
- 18 **Inferior laryngeal nerve.** [N. laryngeus inferior]. Term sometimes used to denote the terminal branch of the recurrent laryngeal nerve, which supplies the intrinsic muscles of the larynx except the cricothyroid and projects a communicating branch to the internal laryngeal nerve. A
- 19 **[R. communicans [cum ramo laryngeo interno]].** Communicating branch of the inferior (recurrent) laryngeal nerve to the internal laryngeal nerve. A
- 20 **Thoracic cardiac branches.** Rami cardiaci thoracici. Rami to the thoracic inlet. A
- 21 **Bronchial branches.** Rami bronchiales. Rami projected to the hilum of the lung below the recurrent laryngeal nerve. A
- 22 **Pulmonary plexus.** Plexus pulmonalis. Nerve plexus located anterior and posterior to the hilum of the lung for innervation of bronchi, vessels and visceral pleura. A
- 23 **Esophageal plexus.** Plexus oesophagealis. Nerve plexus around the esophagus formed directly by the two vagus nerves and superiorly also by the left recurrent laryngeal nerve. A
- 24 **Anterior vagal trunk.** Truncus vagalis anterior. Weak anterior plexus emerging from the esophageal plexus and containing fibers from the both vagi. A
- 25 **Posterior vagal trunk.** Truncus vagalis posterior. Better developed posterior nerve plexus arising from the esophageal plexus and containing fibers from both vagi. A
- 26 **Anterior gastric branches.** Rami gastrici anteriores. Rami extending from the anterior vagal trunk to the anterior surface of the stomach. A
- 27 **Posterior gastric branches.** Rami gastrici posteriores. Rami extending from the posterior vagal trunk to the posterior surface of the stomach. A
- 28 **Hepatic branches.** Rami hepatici. Rami to the hilum of the liver. A
- 29 **Celiac branches.** Rami coeliaci. Rami to the celiac plexus. A
- 30 **Renal branches.** Rami renales. Rami to the renal plexus. A
- 31 **ACCESSORY NERVE (XI).** N. accessorius [XI]. Eleventh cranial nerve. Its two roots unite in the skull and pass through the jugular foramen together with the IX and X nerves. B

- 32 **Cranial roots (vagal part).** Radices craniales (pars vagalis). Fibers from the nucleus ambiguus which leave the accessory nerve in the jugular foramen and join the vagus nerve. B
- 33 **Spinal roots (spinal part).** Radices spinales (pars spinalis). They arise from the base of the anterior horn of the cervical spinal cord (C1–6) and form a trunk which ascends into the subarachnoid space of the skull where it unites temporarily with fibers from the cranial roots. B
- 34 **Accessory nerve trunk.** Truncus nervi accessorii. It is formed by the union of both roots. B
- 35 **Internal branch.** Ramus internus. Fiber tract associated with the vagus nerve and formed by the united cranial roots of the accessory nerve. B
- 36 **External branch.** Ramus externus. United spinal root fibers of the accessory nerve. They supply the sternocleidomastoid and trapezius muscles. B
- 37 **Muscular branches.** Rami musculares. Branches supplying the sternocleidomastoid and trapezius muscles. B

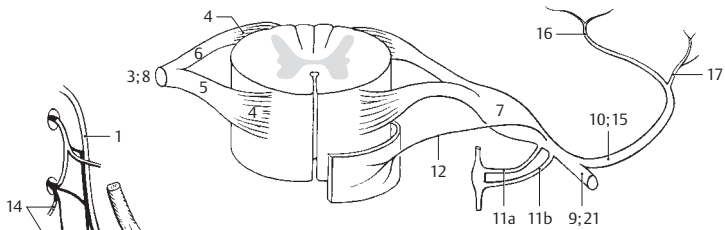


A Vagus nerves with branches

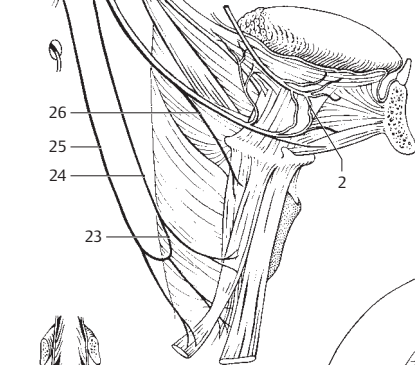


B Accessory nerve

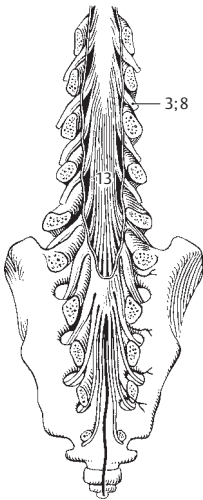
- 1 **HYPOGLOSSAL NERVE (XII).** N. hypoglossus [XII]. Twelfth cranial nerve. Formed by numerous roots emerging from the brain between the pyramid and olive. It passes through the hypoglossal canal and descends between the internal jugular vein and internal carotid artery. At the level of the angle of the mandible it then proceeds anteriorly above the posterior margin of the floor of the mouth to enter the tongue. B
- 2 **Lingual branches.** Rami linguales. Rami beginning lateral to the hyoglossus muscle and supplying the styloglossus, hyoglossus and genio-glossus muscles as well as the intrinsic muscles of the tongue. B
- 3 **SPINAL NERVES.** Nervi spinales. They are formed by two roots and, in contrast to the cranial nerves, they exit through the intervertebral foramina. A C
- 4 **Root filaments.** Fila radicularia. Fine root fibers emerging from the spinal cord within the anterior and posterior roots of the individual spinal nerves. A
- 5 **Anterior (ventral) root.** Radix anterior (motoria). Motor root. A
- 6 **Posterior (dorsal) root.** Radix posterior (sensoria). Sensory root. A
- 7 **Spinal (dorsal root) ganglion.** Ganglion spinale (sensorium). Ganglion situated in the intervertebral foramen, composed of pseudo-unipolar cells. It lies in the posterior root just in front of the site where it joins the anterior root. A
- 8 **Spinal nerve trunk.** Truncus nervi spinalis. Segment between the union of the two roots and the first branch of the spinal nerve. A C
- 9 **Anterior (ventral) branch.** Ramus anterior. Larger anterior branch of a spinal nerve. It communicates with adjacent anterior rami to form large plexuses. In the thoracic region it becomes continuous with an intercostal nerve. A
- 10 **Posterior (dorsal) branch.** Ramus posterior. Weaker branch supplying the skin of the back and autochthonous back muscles. A
- 11 **Rami communicantes.** Communicating branches connecting the spinal nerve and the sympathetic trunk. A
- 11a **Gray communicating ramus.** Ramus griseus. Postganglionic part. A
- 11b **White communicating ramus.** Ramus albus. Preganglionic part. A
- 12 **Meningeal branch.** Ramus meningeus. Delicate, recurrent ramus. It passes in front of the spinal nerve to re-enter the vertebral canal through the intervertebral foramen and supply the meninges of the spinal cord, where it unites with other meningeal rami to form a plexus. It contains sensory and sympathetic fibers. A
- 13 **Cauda equina.** Collection of all spinal nerve roots extending from L1–2 caudally in addition to the filum terminale. C
- 14 **CERVICAL NERVES.** Nervi cervicales. Eight spinal nerves emerging from the cervical spinal cord. B
- 15 **Posterior (dorsal) branches.** Rami posteriores. Posterior branches of the spinal nerve that supply the nuchal muscles and the skin lateral to the nuchal region and near the occiput. A
- 16 **Medial branch of posterior ramus.** Ramus medialis. Branch with motor and sensory fibers supplying the muscles and skin. A
- 17 **Lateral branch of posterior ramus.** Ramus lateralis. Purely motor branch passing obliquely laterad into the muscles. A
- 18 **Suboccipital nerve.** N. suboccipitalis. Posterior branch of the first cervical spinal nerve. It exits between the vertebral artery and posterior arch of the atlas and supplies the short muscles of the neck. D
- 19 **Greater occipital nerve.** N. occipitalis major. Posterior branch of the second cervical spinal nerve. It emerges between the axis and obliquus capitis inferior muscle, pierces the trapezius and supplies the nuchal muscles and skin of the occipital region. D
- 20 **Third occipital nerve.** N. occipitalis tertius. Posterior branch of the third cervical spinal nerve. It supplies the skin of the nuchal region close to the midline. D
- 21 **Anterior (ventral) branches.** Rami anteriores. Anterior rami of cervical spinal nerves. They form the cervical and brachial plexuses. A
- 22 **Cervical plexus.** Plexus cervicalis. Nerve plexus formed by the anterior rami of spinal nerves C1–4. They supply the skin and muscles of the neck.
- 23 **Nerve loop from C1–3.** Ansa cervicalis [hypoglossi]. A nerve loop in the neck (C1–C3) that supplies the infrahyoid muscles. B
- 24 **Anterior (ventral) root.** Radix anterior. The anterior root, part of which supplies the geniohyoid and thyrohyoid muscles via the hypoglossal nerve. B
- 25 **Posterior (dorsal) root.** Radix posterior. Posterior root. B
- 26 **Thyrohyoid branch of the ansa cervicalis.** Ramus thyrohyoideus. Branch supplying the thyrohyoid muscle. B
- 27 **Lesser occipital nerve.** N. occipitalis minor. Uppermost cutaneous branch of the cervical plexus. It passes upward at the posterior margin of the sternocleidomastoid and, at the occiput, ramifies as a lateral communicating nerve of the greater occipital nerve. D
- 28 **Great auricular nerve.** N. auricularis magnus. It courses to the ear, thereby crossing the sternocleidomastoid vertically somewhat above its middle. D
- 29 **Posterior (dorsal) branch.** Ramus posterior. It supplies the skin of the posterior surface of the pinna and the adjacent area. D
- 30 **Anterior (ventral) ramus.** Ramus anterior. It supplies the skin of the anterior surface of the ear up to the angle of the mandible. D



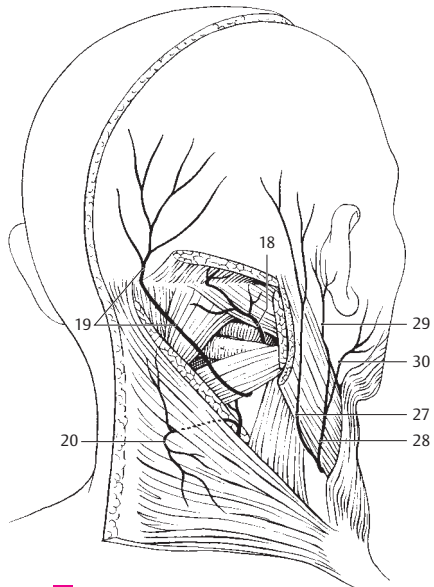
A Spinal nerve with roots and branches



B Hypoglossal nerve and ansa cervicalis

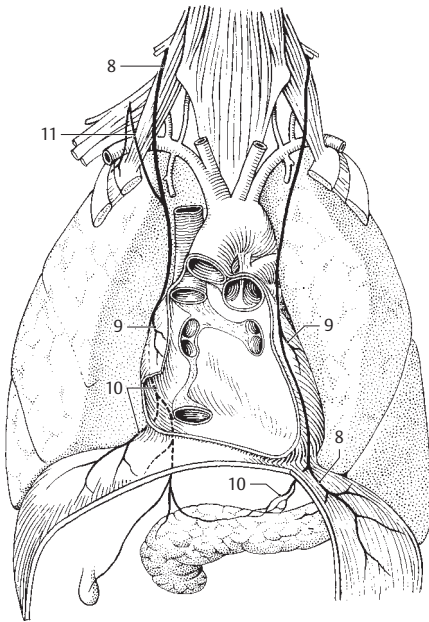


C Cauda equina

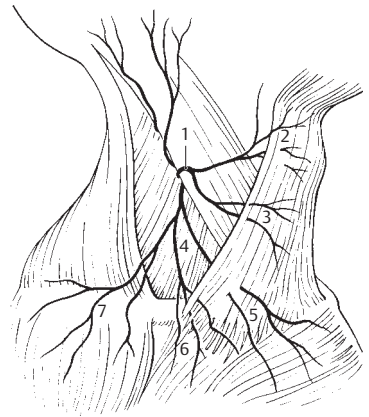


D Nerves of the nape of the neck

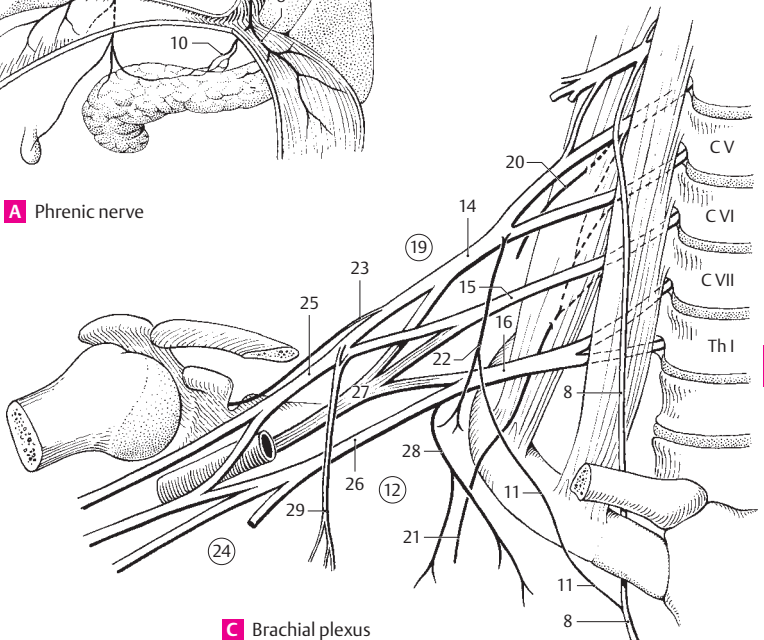
- 1 **Transverse cervical (colli) nerve.** N. transversus colli. Arises from C3 and is the third nerve occupying the "nerve point" at the posterior margin of the middle third of the sternocleidomastoid muscle where it turns anteriorly and passes beneath the platysma to supply the skin. It receives motor fibers for the platysma from the cervical branch of the facial nerve. B
- 2 **Superior branches.** Rami superiores. They ascend to the suprahyoid region. B
- 3 **Inferior branches.** Rami inferiores. They descend to the infrahyoid region. B
- 4 **Supraclavicular nerves.** Nn. supraclaviculares. Cutaneous branches from C3–4. They spread out fanlike to the shoulder and clavicular regions. B
- 5 **Medial supraclavicular nerves.** Nn. supraclaviculares mediales. They pass over the middle third of the clavicle and supply the skin of the neck in this region and the thorax as far as the sternal angle, as well as the sternoclavicular joint. B
- 6 **Intermediate supraclavicular nerves.** Nn. supraclaviculares intermedii. They descend beneath the platysma and over the middle third of the clavicle to supply the skin up to the 4th rib. B
- 7 **Lateral (posterior) supraclavicular nerves.** Nn. supraclaviculares laterales (posteriores). Posterior group of nerves supplying the skin over the acromion, deltoid muscle and the acromioclavicular joint. B
- 8 **Phrenic nerve.** N. phrenicus. It arises from C4 with additional rami from C3 and C5, extends on the scalenus anterior muscle, then passes through the middle mediastinum to the diaphragm. Some of its fibers extend further into the peritoneum. A C
- 9 **Pericardial branch.** Ramus pericardiacus. Slender branch to the anterior surface of the pericardium. A
- 10 **Phrenicoabdominal branches.** Rami phrenicoabdominales. Fibers supplying the peritoneum up to the gallbladder and pancreas. On the right side they pass through the foramen for the vena cava, on the left side further anteriorly through the diaphragm near the left margin of the heart. A
- 11 **Accessory phrenic nerves.** Nn. phrenici accessorii. Frequent additional roots of the phrenic nerve from C5 and C6 via the nerve to the subclavius. A C
- 12 **BRACHIAL PLEXUS.** Plexus brachialis. Nerve plexus formed by the anterior rami of spinal nerves C5–T1. Supplying the arm and part of the shoulder girdle, it passes between the scalenus anterior and medius extending as far as the head of the humerus. C
- 12a **Nerve roots.** Radices.
- 13 **Trunks.** Trunci. Three primary trunks make up the brachial plexus and each is usually formed from one or two anterior rami of spinal nerves.
- 14 **Upper trunk.** Truncus superior. Formed by the union of C5 and C6 spinal nerves, it generally arises lateral to the scalenus gap. C
- 15 **Middle trunk.** Truncus medius. A continuation of C7 spinal nerve itself. C
- 16 **Lower trunk.** Truncus inferior. Formed by the union of C8 and T1 spinal nerves; it lies within the scalenus gap posterior to the subclavian artery. C
- 17 **Anterior divisions.** Divisiones anteriores. Portions of brachial plexus formed by the anterior branches of the three trunks. They supply the flexor muscles.
- 18 **Posterior divisions.** Divisiones posteriores. Portions of brachial plexus formed by the posterior branches of the three trunks. They unite to form the posterior cord and supply the extensor muscles.
- 18a **Cords.** Fasciculi. Three nerve bundles formed by the union of branches (anterior and/or posterior) from the three trunks.
- 19 **SUPRACLAVICULAR PART.** Pars supraclavicularis. Part of brachial plexus extending up to the superior margin of the clavicle. C
- 20 **Dorsal scapular nerve.** N. dorsalis scapulae. Nerve that arises from C5 directly lateral to the intervertebral foramen, penetrates the scalenus medius and then courses below the levator scapulae and the two rhomboid muscles, which it innervates. C
- 21 **Long thoracic nerve.** N. thoracicus longus. Nerve that arises from C5–7, penetrates the scalenus medius and travels on the serratus anterior, which it supplies. C
- 22 **Nerve to subclavius.** N. subclavius. Slender nerve from the upper trunk with fibers from C4–6 for the subclavius muscle. It frequently sends a branch (11) to the phrenic nerve. C
- 23 **Suprascapular nerve.** N. suprascapularis. Nerve that arises from C5–6, passes over the brachial plexus to the scapular notch and then goes under the superior transverse ligament of the scapula to innervate the supra- and infraspinatus muscles. C
- 24 **INFRACLAVICULAR PART.** Pars infraclavicularis. Portion of brachial plexus below the clavicle. It extends from the upper margin of the clavicle to the level where the cords divide into the individual nerves. C
- 25 **Lateral cord.** Fasciculus lateralis. Located lateral to the axillary artery, it is formed by the union of the anterior divisions of the upper and middle trunks, thus from C5–7. C
- 26 **Medial cord.** Fasciculus medialis. Cord located medial to the axillary artery. It is formed solely by the anterior division of the lower trunk, thus from C8–T1. C
- 27 **Posterior cord.** Fasciculus posterior. Cord located posterior to the axillary artery; it is formed by the union of the posterior divisions of all three trunks, thus from C5–T1. C
- 28 **Medial pectoral nerve.** N. pectoralis medialis. Nerve formed by fibers from the medial cord, thus from C8–T1. It supplies the pectoralis major and minor muscles. C
- 29 **Lateral pectoral nerve.** N. pectoralis lateralis. Fibers from C5–7 that supply the two pectoral muscles. C



A Phrenic nerve

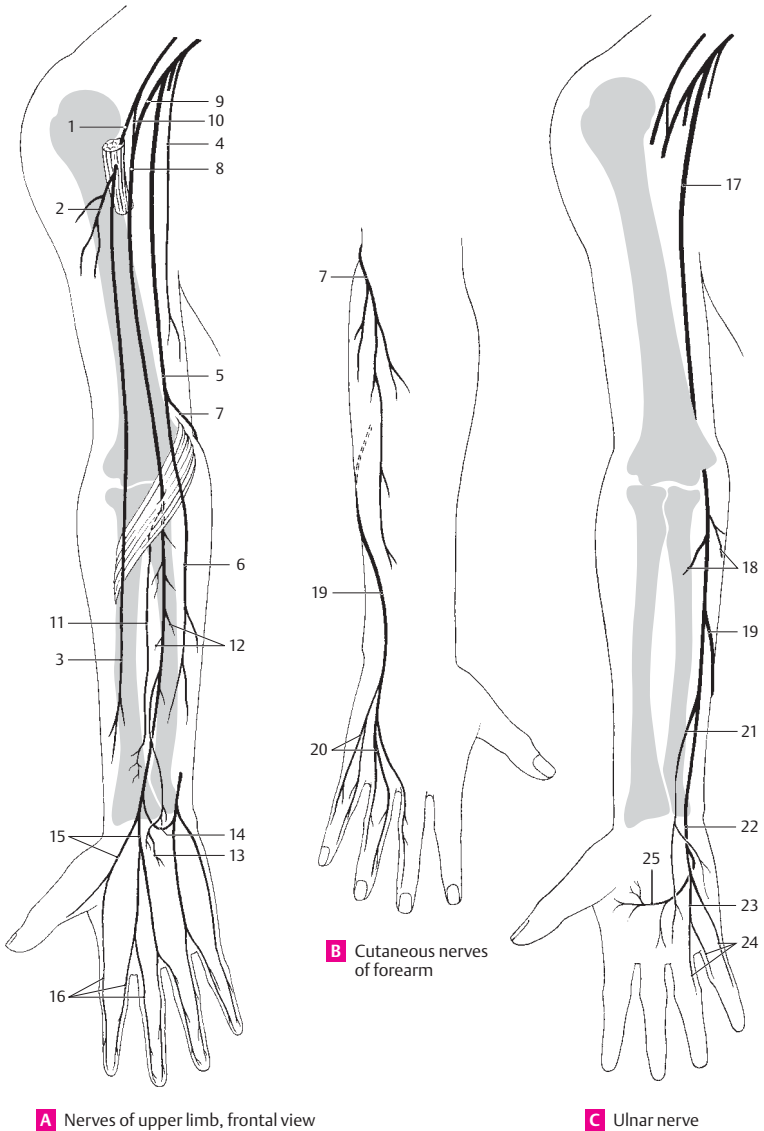


B Nerves forming the "nerve point"



C Brachial plexus

- 1 **Musculocutaneous nerve.** N. musculocutaneus. Nerve that arises from the lateral cord (C5–7), penetrates the coracobrachialis and supplies it as well as the biceps and brachialis muscles. It ends as the lateral antebrachial cutaneous nerve. A
- 2 **Muscular branches.** Rami musculares. Branches to the coracobrachialis, biceps and brachialis muscles. A
- 3 **Lateral antebrachial cutaneous nerve.** N. cutaneus antebrachii lateralis. Terminal branch of musculocutaneous nerve. It penetrates the fascia at the bend of the elbow and supplies the skin of the lateral forearm. A
- 4 **Medial brachial cutaneous nerve.** N. cutaneus brachii medialis. Nerve that arises from the medial cord (C8, T1) and supplies the skin of the medial upper arm together with the intercostobrachial nerve. A
- 5 **Medial antebrachial cutaneous nerve.** N. cutaneus antebrachii medialis. Nerve that arises from the medial cord (C8, T1) and penetrates the fascia at about the middle of the upper arm and accompanies the basilic vein. It supplies the skin on the medial side of both the distal upper arm and the forearm. A
- 6 **Anterior branch.** Ramus anterior. It supplies the medial flexor side of the forearm. A
- 7 **Posterior (ulnar) branch.** Ramus posterior [[ulnaris]]. It supplies the medial upper 2/3 of the posterior aspect of the forearm. A B
- 8 **Median nerve.** N. medianus. Nerve formed by the union of medial and lateral roots from the medial and lateral cords (C6–T1). A
- 9 **Medial root.** Radix medialis. Part of the median nerve coming from the medial cord with fibers from C8 and T1. A
- 10 **Lateral root.** Radix lateralis. Part of the median nerve arising from the lateral cord with fibers from C6–7. A
- 11 **Anterior interosseous nerve of forearm.** N. interosseus (antebrachii) anterior. Nerve that arises from the bend of the elbow from the posterior side of the median nerve, runs on the interosseous membrane and supplies the radiocarpal joint, intercarpal joints, flexor pollicis longus, flexor digitorum profundus (radial part) and pronator quadratus. A
- 12 **Muscular branches.** Rami musculares. Branches that supply the pronator teres, flexor carpi radialis, palmaris longus and flexor digitorum superficialis muscles. A
- 13 **Palmar branch of median nerve.** Ramus palmaris n. mediani. Nerve that arises in the distal third of the forearm and supplies the skin of the lateral palm. A
- 14 **Communicating branch to the ulnar nerve.** Ramus communicans [cum nervo ulnari]. A
- 15 **Common digital nerves.** Nn. digitales communes. Nerves that run in the spaces between the first four fingers and then divide. A
- 16 **Proper palmar digital nerves.** Nn. digitales palmares proprii. Terminal branches of common palmar digital nerves. They supply the palmar aspect of the skin of the radial 3 1/2 fingers and dorsal aspect of the skin of the radial 2 1/2 distal phalanges. A
- 17 **Ulnar nerve.** N. ulnaris. Nerve that arises from the medial cord (C8, T1). It initially lies in the medial bicipital groove, breaks through the medial intermuscular septum and then, after passage in the groove for the ulnar nerve, penetrates the flexor carpi ulnaris. C
- 18 **Muscular branches.** Rami musculares. They supply the flexor carpi ulnaris and the ulnar part of the flexor digitorum profundus. C
- 19 **Dorsal branch of ulnar nerve.** Ramus dorsalis n. ulnaris. Cutaneous branch passing between the distal and middle third of the forearm beneath the flexor carpi ulnaris to innervate the dorsum of the hand. B C
- 20 **Dorsal digital nerves.** Nn. digitales dorsales. Individual branches to the little finger, ring finger and the ulnar side of the middle finger. This area of innervation can be displaced by the radial nerve. B
- 21 **Palmar branch of ulnar nerve.** Ramus palmaris nervi ulnaris. Nerve that arises in the distal third of the forearm, penetrates the deep fascia and supplies the skin on the palmar surface of the hand. C
- 22 **Superficial branch.** Ramus superficialis. Branch that courses beneath the palmar aponeurosis and divides to form the common palmar distal nerves and a fine branch to the palmaris brevis. C
- 23 **Common palmar digital nerves.** Nn. digitales palmares communes. Usually only one branch which runs in the region between the ring and little fingers. C
- 24 **Proper palmar digital nerves.** Nn. digitales palmares proprii. Cutaneous nerves to the little finger and the ulnar side of the ring finger. They also supply the dorsal aspect of the middle and distal phalanges of the 1 1/2 ulnar fingers. C
- 25 **Deep branch (of ulnar nerve).** Ramus profundus. Branch that curves around the hamulus to supply the muscles of the hypothenar eminence, the interossei, the two ulnar lumbricals, the adductor pollicis and the deep head of the flexor pollicis brevis. C

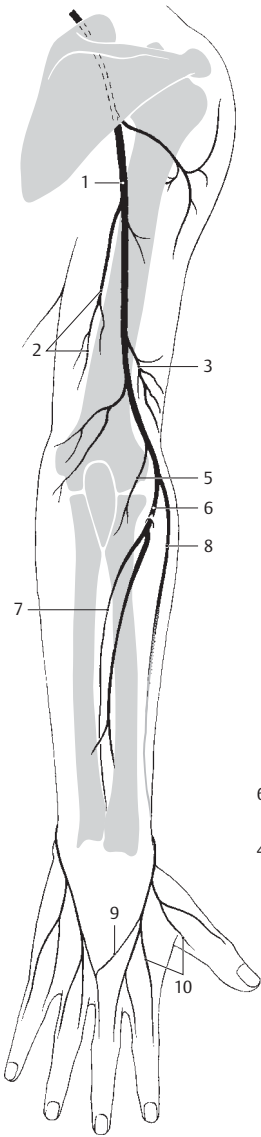


A Nerves of upper limb, frontal view

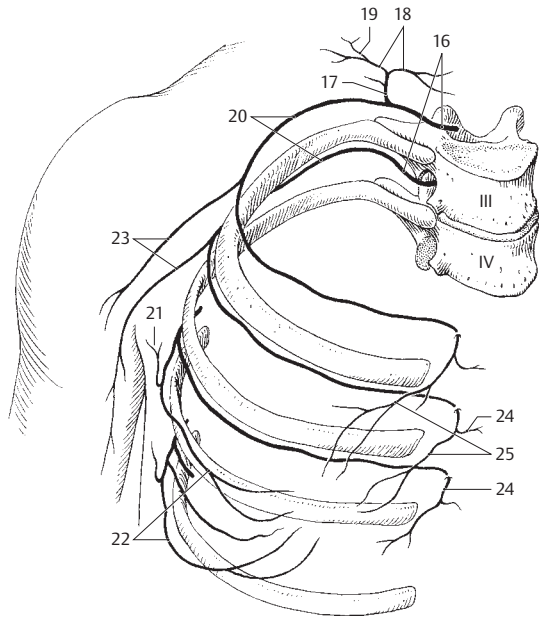
B Cutaneous nerves of forearm

C Ulnar nerve

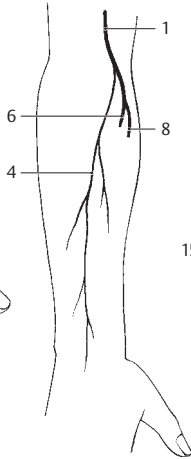
- 1 **Radial nerve.** N. radialis. Nerve that originates from the posterior cord (usually with fibers from C5–T1), takes a spiral course around the posterior aspect of the humerus while within the groove for the radial nerve, then proceeds laterally between the brachialis and brachioradialis as well as both extensor carpi radialis muscles. At the elbow it divides to form its deep and superficial rami. A B D
- 2 **Posterior brachial cutaneous nerve.** N. cutaneus brachii posterior. Small cutaneous branch supplying the skin on the extensor side of the upper arm. A
- 3 **Lateral brachial cutaneous nerve.** N. cutaneus brachii lateralis inferior. Second cutaneous branch for the lateral and dorsal surfaces of the upper arm below the deltoid muscle. A
- 4 **Posterior antebrachial cutaneous nerve.** N. cutaneus antebrachii posterior. Cutaneous branch for the field between the lateral and medial antebrachial cutaneous nerves. B
- 5 **Muscular branches.** Rami musculares. Motor rami to the triceps, anconeus, brachioradialis and extensor carpi radialis longus muscles. A
- 6 **Deep branch.** Ramus profundus. Branch that supplies the extensors of the forearm. It penetrates the supinator, supplying it and all extensors (except the extensor carpi radialis longus) and the abductor pollicis longus. A B
- 7 **Posterior interosseous nerve of forearm.** N. interosseus (antebrachii) posterior. Terminal branch of the deep ramus that lies on the interosseous membrane in the distal third of the forearm beneath the extensors and extends to the wrist joint. A
- 8 **Superficial branch.** Ramus superficialis. Branch that runs along the brachioradialis together with the radial artery, crosses under its accompanying muscle and then arrives at the dorsum of the hand and fingers as a cutaneous nerve. A B
- 9 **Communicating branch to the ulnar nerve.** Ramus communicans ulnaris. It joins the dorsal ramus of the ulnar nerve on the dorsum and the hand. A
- 10 **Dorsal digital nerves.** Nn. digitales dorsales. Terminal rami of the superficial branch passing on the radial and ulnar sides of the extensor aspect of the lateral 2^{1/2}, sometimes also 3^{1/2} fingers. A
- 11 **Subscapular nerves.** Nervi subscapulares. Two to three branches from the brachial plexus (supraclavicular part or posterior cord) supplying the subscapularis and teres major muscles. D
- 12 **Thoracodorsal nerve.** N. thoracodorsalis. Longest subscapular nerve with fibers from C6–8. It courses along the lateral margin of the scapula and supplies the latissimus dorsi. D
- 13 **Axillary nerve.** N. axillaris. Nerve that arises from the posterior cord (C5–6) and passes together with the posterior circumflex humeral artery through the axilla to the teres minor and deltoid muscles. D
- 14 **Muscular branches.** Rami musculares. Fibers to the teres minor and deltoid muscles. D
- 15 **Superior lateral brachial cutaneous nerve.** N. cutaneus brachii lateralis superior. It supplies the area of the skin located somewhat over the deltoid muscle. D
- 16 **THORACIC NERVES.** Nn. thoracici. Twelve thoracic spinal nerves emerging below thoracic vertebrae 1–12, respectively. C
- 17 **Posterior branches.** Rami posteriores. Rami that pass dorsally through the autochthonous muscles of the back, then divide to form lateral and medial cutaneous branches. C
- 18 **Lateral/medial muscular branches.** Ramus muscularis lateralis/medialis. C
- 19 **Posterior cutaneous branch.** Ramus cutaneus posterior. C
- 20 **Anterior branches (intercostal nerves).** Rami anteriores (nn. intercostales). Rami forming the intercostal nerves ventrally in the thoracic region. C
- 21 **Lateral cutaneous branch (pectoral/abdominal).** Ramus cutaneus lateralis (pectoralis/abdominalis). Nerve arising from the middle of the intercostal nerve. It passes obliquely ventrad and appears between the slips of the serratus anterior muscle and the latissimus dorsi. C
- 22 **Lateral mammary branches.** Rami mammarii laterales. Rami of lateral cutaneous branches arising from T4–6 and passing anteriorly to the mammary region. C
- 23 **Intercostobrachial nerves.** Nn. intercostobrachiales. Lateral cutaneous rami arising usually from T1, but also from T1–3 and passing to the upper arm. C
- 24 **Anterior cutaneous branch (pectoral/abdominal).** Ramus cutaneus anterior (pectoralis/abdominalis). Branch that emerges medially and anteriorly and divides to form medial and lateral branches. C
- 25 **Medial mammary branches.** Rami mammarii mediales. Medial branches from the anterior cutaneous rami of intercostal nerves 2–4. C
- 26 **Subcostal nerve.** N. subcostalis. Anterior branch of the 12th thoracic nerve located below the 12th rib.



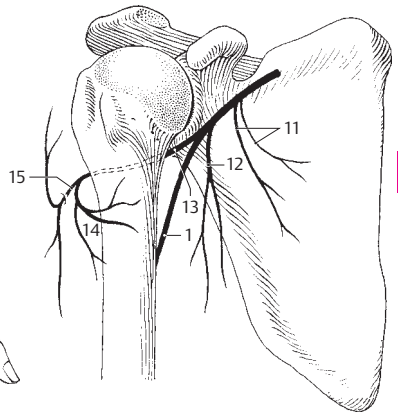
A Radial nerve



C Intercostal nerves

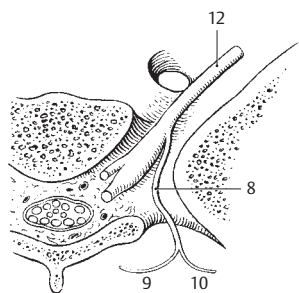


B Posterior antebrachial cutaneous nerve

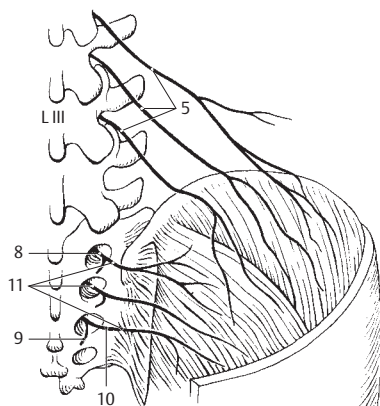


D Axillary nerve

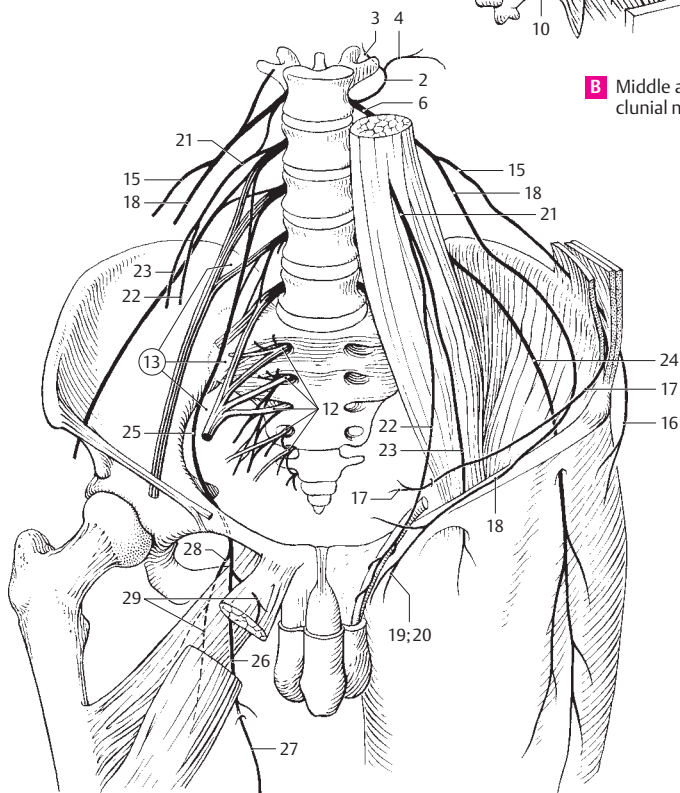
- 1 **LUMBAR NERVES.** Nn. lumbales (lumbares). Five lumbar spinal nerves each emerging below its respective lumbar vertebra.
- 2 **Posterior branches.** Rami posteriores. They supply the autochthonous back muscles and the skin overlying them. C
- 3 **Medial branch.** Ramus medialis. Weak motor branch in the lumbar region. C
- 4 **Lateral branch.** Ramus lateralis. Predominantly sensory. C
- 5 **Superior clunial (gluteal) branches.** Rami clunium (gluteales) superiores. Lateral rami of L1–3 supplying the skin up to the greater trochanter (buttock region). B
- 6 **Anterior branches.** Rami anteriores. Ventral branches forming the lumbar plexus. C
- 7 **SACRAL NERVES AND COCCYGEAL NERVE.** Nn. sacrales et n. coccygeus. Five sacral and one coccygeal nerve.
- 8 **Posterior branches.** Rami posteriores. Sensory and motor rami emerging from the posterior sacral foramina. A B
- 9 **Medial branch.** Ramus medialis. It supplies the multifidus and the skin over the sacrum and coccyx. A B
- 10 **Lateral branch.** Ramus lateralis. Sensory branch for the skin over the coccyx formed by the union of sensory fibers from the posterior rami of S1–3. A B
- 11 **Medial clunial (gluteal) nerves.** Rami clunium (gluteales) mediales. Sensory nerves from S1–3. They penetrate the gluteus maximus and supply the skin of the medial, upper gluteal region. B
- 12 **Anterior branches.** Rami anteriores. They pass through the anterior sacral foramina and form the sacral plexus. A C
- 13 **LUMBOSACRAL PLEXUS.** Plexus lumbosacralis. Collective term for the combined lumbar and sacral plexuses joined together by fibers from L4 and mutually supplying the lower limb. C
- 14 **LUMBAR PLEXUS.** Plexus lumbalis (lumbaris). Nerve network formed by spinal nerves L1–4 which lie at the anterior side of the leg.
- 15 **Iliohypogastric nerve.** N. iliohypogastricus. Nerve that contains sensory and motor fibers from T12 and L1 for the abdominal muscles. It traverses the psoas major, then courses between the transversus abdominis and internal abdominal muscles and pierces the latter medial to the anterior superior iliac spine. C
- 16 **Lateral cutaneous branch.** Ramus cutaneus lateralis. It can reach as far as the lateral gluteal region. C
- 17 **Anterior cutaneous branch.** Ramus cutaneus anterior. It frequently penetrates the aponeurosis of the external oblique just above the superficial inguinal ring and supplies the skin in this area. C
- 18 **Ilioinguinal nerve.** N. ilioinguinalis. Nerve arising from L1, possibly also T12. It appears at the lateral margin of the psoas and courses between the kidney and quadratus lumborum, then between the transversus abdominis and internal abdominal oblique (muscular branches) to enter the inguinal canal. C
- 19 **Anterior scrotal nerves.** Nn. scrotales anteriores. Sensory branches to the anterior skin of the scrotum, mons pubis and adjacent skin of the thigh. C
- 20 **Anterior labial nerves.** Nn. labiales anteriores. Sensory rami to the labium majus, mons pubis and adjacent skin of the thigh. C
- 21 **Genitofemoral nerve.** N. genitofemoralis. Nerve that arises from L1–2, penetrates the psoas major and courses on top of it. C
- 22 **Genital branch.** Ramus genitalis. Branch that courses through the inguinal canal and supplies the cremaster muscle, skin of scrotum (labium majus) and adjacent skin of the thigh. C
- 23 **Femoral branch.** Ramus femoralis. Branch that passes through the vascular lacuna (between femoral artery and iliopectineal arch), then through the saphenous hiatus to supply the skin located there. C
- 24 **Lateral femoral cutaneous nerve.** N. cutaneus femoris lateralis. Nerve that arises from L2–3. It appears at the lateral margin of the psoas and courses beneath the iliac fascia and through the lateral part of the muscular lacuna into the thigh, where it proceeds below or above the sartorius to the lateral skin of the thigh. C
- 25 **Obturator nerve.** N. obturatorius. Nerve that arises from L2–4. It passes beneath the psoas, behind the internal iliac artery and lateral to the ureter, then through the obturator canal to the adductor group and to the medial skin of the thigh. C
- 26 **Anterior branch.** Ramus anterior. Nerve that courses on top of the adductor brevis and obturator externus muscles and beneath the adductor longus and pectineus muscles. It supplies these and the gracilis muscles. C
- 27 **Cutaneous branch.** Ramus cutaneus. Variable terminal branch which appears between the adductor longus and gracilis muscles and supplies the distal 2/3 of the skin of the thigh. C
- 28 **Posterior branch.** Ramus posterior. It pierces the obturator externus and supplies it and the adductor magnus and brevis. Via a sensory branch it extends as far as the posterior wall of the knee joint. C
- 29 **Muscular branches.** Rami musculares. Branches supplying the previously named muscles. C
- 30 **Accessory obturator nerve.** N. obturatorius accessorius. It frequently arises as an additional obturator nerve from L3–4 to supply the pectineus and hip joint.



A Exit of a sacral nerve

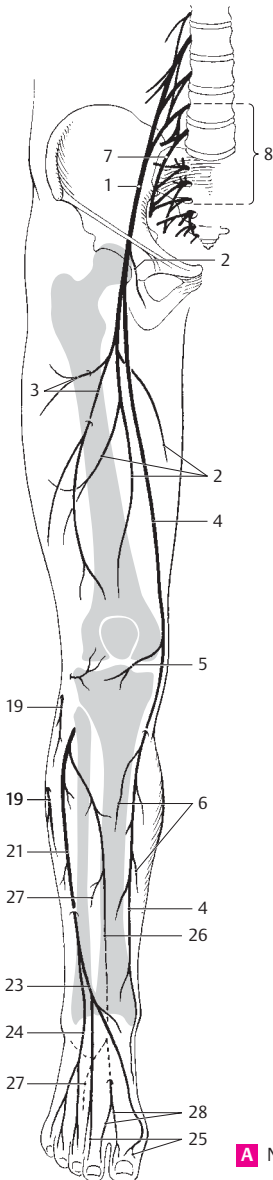


B Middle and superior clunial nerves

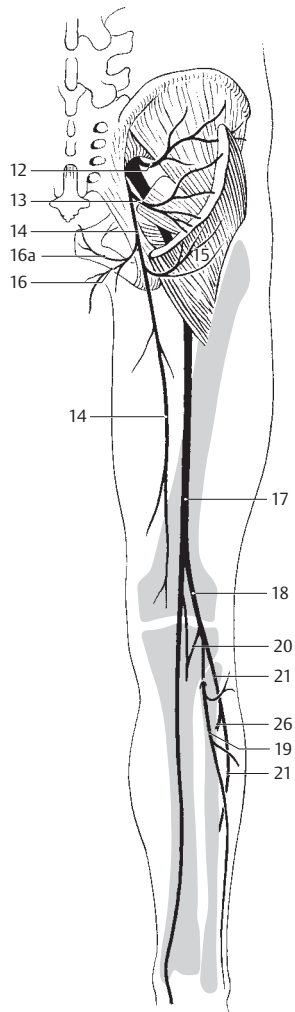


C Lumbosacral plexus

- 1 **Femoral nerve.** N. femoralis. Nerve arising from L2–4. It appears at the lateral margin of the psoas and runs between the iliac and psoas major muscles to pass through the muscular lacuna. A
- 2 **Muscular branches.** Rami musculares. Branches to the sartorius, pectineus and quadriceps femoris muscles. A
- 3 **Anterior cutaneous branches.** Rami cutanei anteriores. Main branches for the distal 3/4 of the anterior surface of the thigh up to the patella. A
- 4 **Saphenous nerve.** N. saphenus. Longest, purely sensory ramus of the femoral nerve. It begins in the femoral triangle, passes beneath the “vastoadductor membrane”, which it pierces, arrives beneath the skin between the sartorius and gracilis muscles and, together with the great saphenous vein, proceeds as far as the medial side of the foot. A
- 5 **Infrapatellar branch.** Ramus infrapatellaris. It penetrates the sartorius and arrives at the skin below the patella. A
- 6 **Medial cutaneous branches of the leg.** Rami cutanei cruris mediales. Branches of saphenous nerve to skin of the lower leg and foot. A
- 7 **Lumbosacral trunk.** Truncus lumbosacralis. Connection to the lumbar plexus formed by L5 and a part of L4. A
- 8 **SACRAL PLEXUS.** Plexus sacralis. Plexus arising from L5–S3 and a part of L4 and S4, lying anterior to and beneath the fascia of the piriformis muscle beneath its fascia. Its nerves pass to the posterior side of the lower limb. A
- 9 **Nerve to obturator internus muscle.** N. musculi obturatorii interni. Nerve that arises from L5–S2 and passes through the greater sciatic foramen into the ischioanal fossa from which it extends to the obturator internus muscle.
- 10 **Nerve to piriformis muscle.** N. musculi piriformis. Nerve that arises from S1–2 and proceeds to the anterior side of the piriformis.
- 11 **Nerve to quadratus femoris.** N. musculi quadrati femoris. Nerve that arises from L4–S1, passes through the greater sciatic foramen and proceeds down to the quadratus femoris and the hip joint.
- 12 **Superior gluteal nerve.** N. gluteus superior. Nerve that arises from L4–S1, passes through the greater sciatic foramen cranial to the piriformis [“suprapiriform foramen”] and then between the gluteus medius and minimus as far as the tensor fasciae latae. It supplies all of the above-mentioned muscles except the piriformis. B
- 13 **Inferior gluteal nerve.** N. gluteus inferior. Nerve that arises from L5–S2, passes through the infrapiriform foramen and supplies the gluteus maximus. B
- 14 **Posterior femoral cutaneous nerve.** N. cutaneus femoralis posterior. Nerve that arises from S1–3, passes through the greater sciatic foramen below the piriformis [“infrapiriform foramen”] and supplies the skin on the posterior side of the thigh and proximal portion of lower leg. B
- 15 **Inferior clunial (gluteal) rami.** Rami clunium (gluteales) inferiores. Cutaneous branches passing upward around the lower margin of the gluteus maximus. B
- 16 **Perineal branches.** Rami perineales. Branches that arise from the lower margin of the gluteus maximus and pass beneath the ischial tuberosity medially to the scrotum (labia). One of the branches ascends as far as the coccyx. B
- 16a **Perforating cutaneous nerve.** N. cutaneus perforans. Ramus of the posterior femoral cutaneous nerve supplying the skin of the anus. B
- 17 **Sciatic nerve.** N. ischiadicus (sciaticus). Nerve that arises from L4–S3. It is the thickest nerve of the body. It leaves the pelvis through the greater sciatic foramen below the piriformis [infrapiriform foramen] and passes downward lateral to the ischial tuberosity, beneath the gluteus maximus and the long head of the biceps. B
- 18 **Common peroneal (fibular) nerve.** N. fibularis communis. Nerve that arises from L4–S2, branches off from the sciatic nerve at a variable level, passes in company with the biceps tendon as far as the posterior aspect of the head of the fibula and then crosses obliquely forward between the skin and fibula. B
- 19 **Lateral sural cutaneous nerve.** N. cutaneus surae lateralis. It usually arises in the popliteal fossa and supplies the skin on the lateral aspect of the proximal 2/3 of the posterior side of the lower leg. A B
- 20 **Communicating branch of common peroneal (fibular) nerve.** Ramus communicans fibularis. It passes beneath the fascia over the lateral head of the gastrocnemius and joins the medial sural cutaneous nerve to form the sural nerve. B
- 21 **Superficial peroneal (fibular) nerve.** N. fibularis superficialis. One of the terminal branches of the common fibular nerve. It descends between the peroneal muscles and extensor digitorum longus. A B
- 22 **Muscular branches.** Rami musculares. Branches to the peroneus longus and brevis.
- 23 **Medial dorsal cutaneous nerve.** N. cutaneus dorsalis medialis. It runs over the extensor retinacula and supplies the skin of the dorsum of the foot, the medial side of the big toe and the halves of the 2nd and 3rd toes facing one another. A
- 24 **Intermediate dorsal cutaneous nerve.** N. cutaneus dorsalis intermedius. Lateral cutaneous branch of the superficial fibular nerve to the middle and lateral aspect of the dorsum of the foot. A
- 25 **Dorsal digital nerves of foot.** Nn. digitales dorsales pedis. Branches for all toes except the distal phalanges. A
- 26 **Deep peroneal (fibular) nerve.** N. fibularis profundus. It proceeds beneath the peroneus longus, then lateral to the tibialis anterior muscle to supply the dorsum of the foot. A B
- 27 **Muscular branches.** Rami musculares. Rami passing to the tibialis anterior, extensor hallucis longus and brevis, and extensor digitorum longus and brevis muscles. A
- 28 **Dorsal digital nerves of lateral surface of great toe and of medial surface of second toe.** Nn. digitales dorsales, hallucis lateralis et digiti secundi medialis. Sensory branches. A

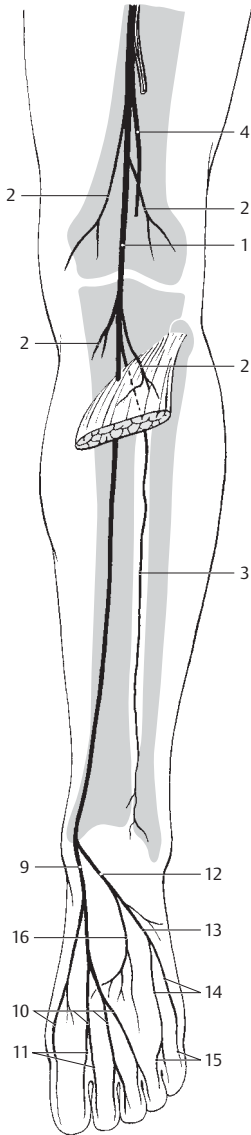


A Nerves of lower limb from front

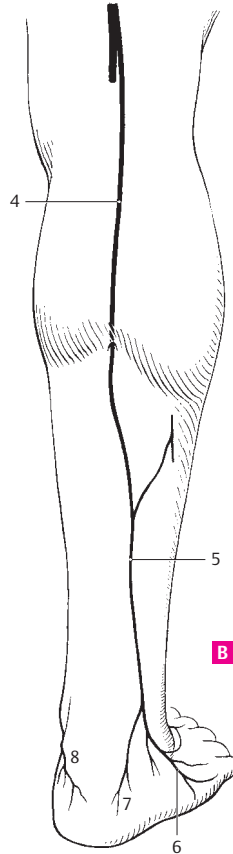


B Nerves of lower limb from behind

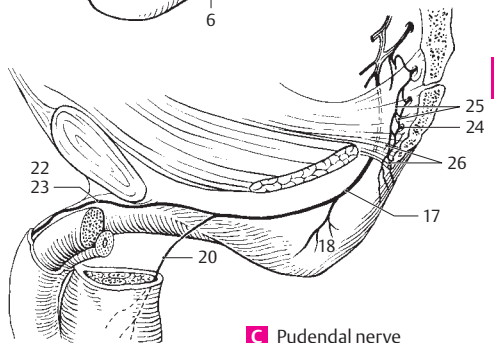
- 1 **Tibial nerve.** N. tibialis. Nerve arising from L4–S3. It is the second terminal branch of the sciatic nerve. It passes through the popliteal fossa, disappears beneath the tendinous arch of the soleus muscle and proceeds, accompanied by the posterior tibial artery, around the medial malleolus to the sole of the foot. A
- 2 **Muscular branches.** Rami musculares. Rami to the gastrocnemius, plantaris, soleus and the deep flexors at the lower leg. A
- 3 **Interosseous nerve of leg.** N. interosseus curus. It is accompanied by the anterior tibial artery and contains fibers for the bones and tibiofibular joint. A
- 4 **Medial sural cutaneous nerve.** N. cutaneus surae medialis. Nerve that arises from the tibial nerve in the popliteal fossa, then descends subfascially lateral to the small saphenous vein and joins the communicating branch of the common fibular nerve to form the sural nerve. A B
- 5 **Sural nerve.** N. suralis. Continuation of the medial sural cutaneous nerve after its union with the communicating branch of the common fibular nerve. B
- 6 **Lateral dorsal cutaneous nerve.** N. cutaneus dorsalis lateralis. It passes to the lateral aspect of the dorsum of the foot and anastomoses with the intermediate dorsal cutaneous nerve. B
- 7 **Lateral calcaneal branches.** Rami calcanei laterales. Lateral branches to the calcaneus. B
- 8 **Medial calcaneal branches.** Rami calcanei mediales. Branches arising directly from the tibial nerve. They pass to the medial aspect of the calcaneus. B
- 9 **Medial plantar nerve.** N. plantaris medialis. The larger terminal branch of the tibial nerve. It proceeds beneath the flexor retinaculum and the abductor hallucis to the sole of the foot which it supplies, as well as the skin and the flexor hallucis brevis and flexor digitorum brevis. A
- 10 **Common plantar digital nerves.** Nn. digitales plantares communes. They course in the interval between toes 1–4 and divide to form the proper plantar digital nerves. A
- 11 **Proper plantar digital nerves.** Nn. digitales plantares proprii. Cutaneous nerves passing on the tibial and fibular sides of the flexor aspect of the medial $3\frac{1}{2}$ toes. They supply the distal phalanges, including their dorsal aspect. A
- 12 **Lateral plantar nerve.** N. plantaris lateralis. Smaller terminal branch of the tibial nerve. It passes beneath the flexor digitorum brevis medial to the lateral plantar artery as far as the base of the 5th metatarsal bone. A
- 13 **Superficial branch.** Ramus superficialis. Predominantly sensory branch of lateral plantar nerve. A
- 14 **Common plantar digital nerves.** Nn. digitales plantares communes. Two branches, one passing to the little toe and giving off a branch to the flexor digiti minimi brevis, the other proceeding to the interval between the 4th and 5th toes. A
- 15 **Proper plantar digital nerves.** Nn. digitales plantares proprii. They pass to the fibular and tibial sides of the little toe as well as to the fibular side of the 4th toe. A
- 16 **Deep branch.** Ramus profundus. Muscular branch passing in company with the plantar arch to the interossei, adductor hallucis and the lateral three lumbrical muscles. A
- 17 **Pudendal nerve.** N. pudendus. Arising from S2–4, it passes through the greater sciatic foramen below the piriformis [“infrapiriform foramen”] to the ischioanal fossa. C
- 18 **Inferior rectal nerves.** Nn. rectales (anales) inferiores. Fibers from S3–4 for the external anal sphincter and the anal skin. C
- 19 **Perineal nerves.** Nn. perineales. Collective term for the nerves of the perineum.
- 20 **Posterior scrotal (labial) nerves.** Nn. scrotales/libiales posteriores. They reach the scrotum (labium majus) from behind. C
- 21 **Muscular branches.** Rami musculares. They supply the muscles of the perineum.
- 22 **Dorsal nerve of penis.** N. dorsalis penis. Paired nerves lying on the dorsum of the penis with branches also to the underside of the penis. C
- 23 **Dorsal nerve of clitoris.** N. dorsalis clitoridis. Smaller nerve corresponding to the dorsal nerve of the penis. C
- 24 **Coccygeal nerve.** N. coccygeus. Last spinal nerve. It emerges between the coccyx and sacrum and anastomoses with S4–5 nerves. C
- 25 **Coccygeal plexus.** Plexus coccygeus. Nerve plexus formed by fibers from a part of S4, all of S5 and the coccygeal nerve. It supplies the skin over the coccyx. C
- 26 **Anococcygeal nerves.** Nn. anococcygei. Several fine nerves from the coccygeal plexus. They pierce the anococcygeal ligament and supply the skin lying over it. C



A Nerves of leg and foot from behind

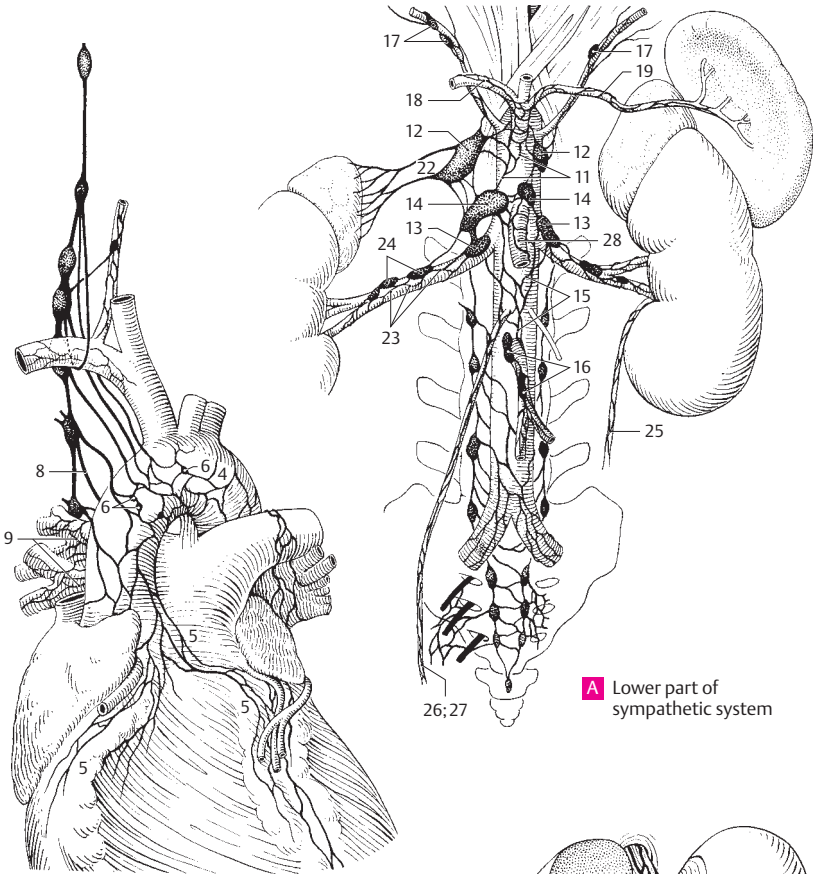


B Cutaneous nerves of leg from behind



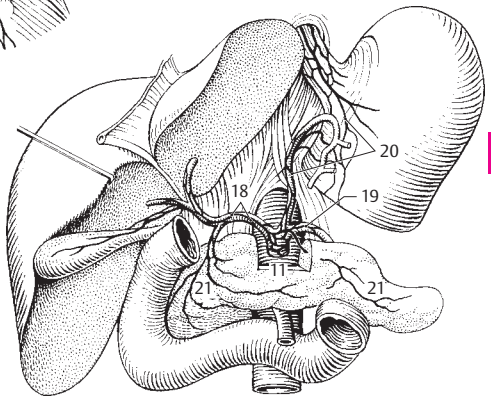
C Pudendal nerve

- 1 **AUTONOMIC NERVOUS SYSTEM.** Pars autonómica (systema nervorum autonomicum). It regulates the functions of the internal organs (viscera) by its influence on smooth muscle, cardiac muscle and glands.
- 2 **AUTONOMIC (VISCERAL) PLEXUS.** Plexus autonomici (viscerales). Autonomic nerve plexuses mainly in front of the vertebral column at the branches of the aorta.
- 3 **GANGLIA OF AUTONOMIC PLEXUS.** Ganglia plexuum autonomicorum (visceralium). Groups of ganglion cells scattered in the autonomic plexuses for synaptic connections between pre- and postganglionic fibers.
- 3a **PARS THORACICA AUTONOMICICA.** Thoracic part of the autonomic nervous system.
- 4 **Thoracic aortic plexus.** Plexus aorticus thoracicus. Autonomic nerve plexus around the aorta with fibers from the first five thoracic ganglia and the splanchnic nerve. It also contains afferent vagal fibers. B
- 5 **Cardiac plexus.** Plexus cardiacus. Autonomic nerve plexus from sympathetic and vagal fibers at the base of the heart, especially around the arch of the aorta and at the root of the pulmonary trunk, as well as along the coronary vessels and between the aorta and tracheal bifurcation. B
- 6 **Cardiac ganglia.** Ganglia cardiaca. Small macroscopic accumulations of ganglion cells especially to the right of the ligamentum arteriosum. B
- 7 **Esophageal plexus.** Plexus oesophagealis. Network of autonomic nerve fibers around the esophagus.
- 8 **Pulmonary branches.** Rami pulmonales. Rami from the 3rd to 4th thoracic sympathetic ganglia, particularly to the posterior part of the pulmonary plexus. B
- 9 **Pulmonary plexus.** Plexus pulmonalis. Plexus in front of and behind the hilum of the lung formed by vagal and sympathetic fibers. It is connected across the midline with the pulmonary plexus of the opposite side and with the cardiac plexus. B
- 9a **PARS ABDOMINALIS AUTONOMICICA.** Abdominal part of the autonomic nervous system.
- 10 **Abdominal aortic plexus.** Plexus aorticus abdominalis. Nerve plexus in front of and on both sides of the aorta. It extends from the celiac plexus to the aortic bifurcation, receives fibers from both upper lumbar ganglia and continues caudally into the superior hypogastric plexus.
- 11 **Celiac plexus.** Plexus coeliacus. Nerve plexus around the celiac trunk. It communicates with adjacent plexuses and receives fibers from both splanchnic nerves and from the vagus. A C
- 12 **Celiac ganglia.** Ganglia coelica. Aggregations of ganglion cells communicating with the celiac plexus and lying to the right and left of the aorta by the celiac trunk. A
- 13 **Aorticorenal ganglia.** Ganglia aorticorenalia. Accumulations of ganglion cells at the exit of the renal artery. They receive the lesser splanchnic nerve and may be fused with the celiac ganglia. A
- 14 **Superior mesenteric ganglion.** Ganglion mesentericum superius. Group of ganglion cells at the right and left of the aorta near the superior mesenteric artery and its branches. It is often fused with adjacent ganglia. A
- 15 **Intermesenteric plexus.** Plexus intermesentericus. Nerve plexus between the superior and inferior mesenteric plexuses. A
- 16 **Inferior mesenteric ganglion.** Ganglion mesentericum inferius. Ganglion cells located entirely within the inferior mesenteric plexus. A
- 17 **Phrenic ganglia.** Ganglia phrenica. Small accumulation of ganglion cells in the nerve plexus accompanying the inferior phrenic artery. A
- 18 **Hepatic plexus.** Plexus hepaticus. Continuation of the celiac plexus at the liver with fibers from the vagus and phrenic nerves. A C
- 19 **Splenic (lienal) plexus.** Plexus splenicus (lienalis). Extensions of the celiac plexus along the splenic artery to the spleen. A C
- 20 **Gastric plexus.** Plexus gastrici. Autonomic nerve plexus for the stomach. The anterior and posterior part is formed by the vagus, the left part is a continuation of the celiac plexus along the left gastric artery. C
- 21 **Pancreatic plexus.** Plexus pancreaticus. Continuation of the celiac plexus along the pancreatic vessels. C
- 22 **Suprarenal plexus.** Plexus suprarenalis. Continuation of the celiac plexus along the suprarenal vessels with preganglionic fibers for the suprarenal medulla. A
- 23 **Renal plexus.** Plexus renalis. Nerve plexus continued onto the renal artery. It also contains vagal fibers. A
- 24 **Renal ganglia.** Ganglia renalis. Microscopically small groups of ganglion cells dispersed within the renal plexus. A
- 25 **Ureteric plexus.** Plexus uretericus. Nerve plexus along the ureter with fibers from the renal and abdominal aortic plexuses and the aorticorenal ganglia. A
- 26 **Testicular plexus.** Plexus testicularis. Nerve plexus along the testicular artery. It extends as far as the testis and receives fibers from the renal and abdominal aortic plexuses. A
- 27 **Ovarian plexus.** Plexus ovaricus. Autonomic nerve plexus along the ovarian artery with fibers from the abdominal aortic and renal plexuses. A
- 28 **Superior mesenteric plexus.** Plexus mesentericus superior. Nerve plexus accompanying the superior mesenteric artery and its branches. It contains sympathetic fibers from the celiac plexus and parasympathetic fibers from the vagus nerve. A



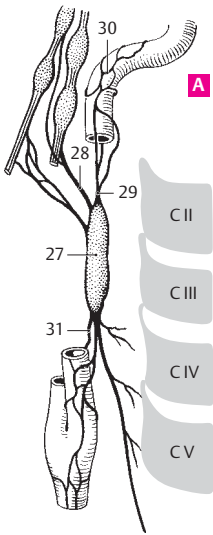
A Lower part of sympathetic system

B Cardiac plexus

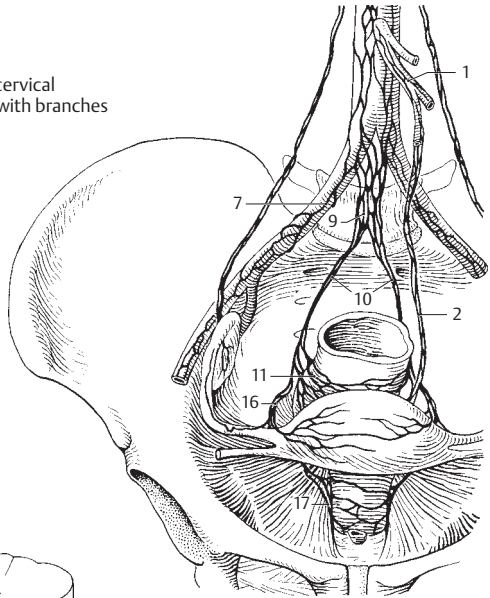


C Celiac plexus

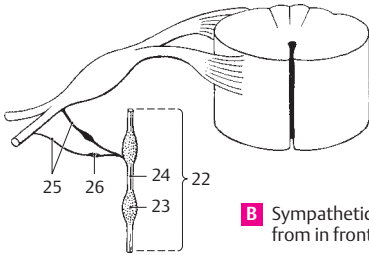
- 1 **Inferior mesenteric plexus.** Plexus mesentericus inferior. Continuation of the abdominal aortic plexus along the inferior mesenteric artery including its branches. D
- 2 **Superior rectal plexus.** Plexus rectalis superior. Continuation of the inferior mesenteric plexus on the superior rectal artery and rectum. It also contains parasympathetic fibers from the inferior hypogastric plexus. D
- 3 **Enteric plexus.** Plexus entericus. Collective term for the autonomic plexuses in the wall of the intestinal tract.
- 4 **Subserosal plexus.** Plexus subserosus. Fine autonomic plexus located directly beneath the serosa. C
- 5 **Myenteric (Auerbach's) plexus.** Plexus myentericus [[Auerbach]]. Prominent plexus situated between the longitudinal and circular muscle layers. It contains ganglion cells and regulates the peristaltic action of the intestine. C
- 6 **Submucosal (Meissner's) plexus.** Plexus submucosus [[Meissner]]. Prominent plexus occupying the submucosa. It contains ganglion cells and regulates the activity of the muscularis mucosae and villi. C
- 7 **Iliac plexus.** Plexus iliaci. Continuation of the abdominal aortic plexus onto both iliac arteries. D E
- 8 **Femoral plexus.** Plexus femoralis. Continuation of the iliac plexus onto the femoral artery. E
- 8a **PARS PELVICA AUTONOMICA.** Pelvic part of the autonomic nervous system.
- 9 **Superior hypogastric plexus (presacral nerve).** Plexus hypogastricus superior (n. praesacralis). Plexus-like connection between the abdominal aortic and inferior hypogastric plexuses located predominantly in front of the 5th lumbar vertebral body and receiving branches from the lumbar sympathetic ganglia. D E
- 10 **Right/left hypogastric nerve.** N. hypogastricus dexter/sinister. Right and left branches of the superior hypogastric plexus to the pelvic viscera. They communicate with the inferior hypogastric plexus. D E
- 11 **Inferior hypogastric plexus (pelvic plexus).** Plexus hypogastricus inferior (plexus pelvicius). Network of sympathetic and parasympathetic fibers located to the right and left of the rectum and in front of it. D
- 12 **Middle rectal plexus.** Plexus rectalis medius. Continuation of the inferior hypogastric plexus onto the wall of the rectum. E
- 13 **Inferior rectal plexus.** Plexus rectalis inferior. Autonomic nerve plexus located around the branches of the internal iliac artery and passing to both sides of the rectum. E
- 14 **Prostatic plexus.** Plexus prostaticus. Nerve plexus mainly located at the posterior and inferior surfaces of the prostate and extending as far as the membranous part of the urethra. E
- 15 **Deferential plexus.** Plexus deferentialis. Nerve plexus around the ductus deferens. E
- 16 **Uterovaginal plexus.** Plexus uterovaginalis. Nerve plexus occupying the parametrium and infiltrated with many ganglia. It sends branches to the uterus, vagina, uterine tube and ovary and communicates with the inferior hypogastric plexus in the rectouterine fold. D
- 17 **Vaginal nerves.** Nervi vaginales. Branches of the uterovaginal plexus passing to the vagina. D
- 18 **Vesical plexus.** Plexus vesicalis. Plexus situated on both sides of the urinary bladder. It contains parasympathetic fibers and is involved in regulating the voiding mechanism of the urinary bladder. E
- 19 **Cavernous nerves of penis.** Nn. cavernosi penis. Rami from the prostatic plexus to the cavernous bodies of the penis. E
- 20 **Cavernous nerves of clitoris.** Nn. cavernosi clitoridis. Nerves corresponding to the cavernous nerves of the penis. E
- 21 **SYMPATHETIC PART (SYSTEM).** Pars sympathetica. Thoracolumbar part of the autonomic nervous system represented in the sympathetic trunk. Excitable by adrenalin (adrenergic), it has a stimulatory effect on the circulation and an inhibitory effect on the intestinal tract.
- 22 **Sympathetic trunk.** Truncus sympatheticus. Chain of ganglia connected by nerve fibers. It lies to the right and left of the vertebral column and extends from the base of the skull to the coccyx. B
- 23 **Ganglia of sympathetic trunk.** Ganglia trunci sympathetici. Groups of small, mostly multipolar ganglion cells producing macroscopic thickenings and forming synaptic sites between myelinated preganglionic and nonmyelinated postganglionic fibers. B
- 24 **Interganglionic branches.** Rami interganglionares. Bundles of white and gray fibers linking the sympathetic ganglia. B
- 25 **Rami communicantes.** Communicating branches (afferent and efferent) between the spinal nerves and sympathetic trunk. B
- 26 **Intermediate ganglia.** Ganglia intermedia. Additional accumulations of sympathetic ganglion cells mainly in the rami communicantes of the cervical and lumbar regions. B
- 27 **Superior cervical ganglion.** Ganglion cervicale superius. Uppermost sympathetic trunk ganglion, about 2.5 cm long and lying 2 cm below the base of the skull between the longus capitis and posterior belly of the digastric. A
- 28 **Jugular nerve.** N. jugularis. Branch to the inferior ganglion of the glossopharyngeal nerve and to the superior ganglion of the vagus. A
- 29 **Internal carotid nerve.** N. caroticus internus. It contains postganglionic fibers and forms the internal carotid plexus in the carotid canal. A
- 30 **Internal carotid plexus.** Plexus caroticus internus. Nerve plexus in the carotid canal giving rise to the deep petrosal nerve and branches to the inner ear. It supplies the eye with sympathetic fibers. A
- 31 **External carotid nerves.** Nn. carotici externi. Nerves for the external carotid plexus descending along the external carotid artery. A



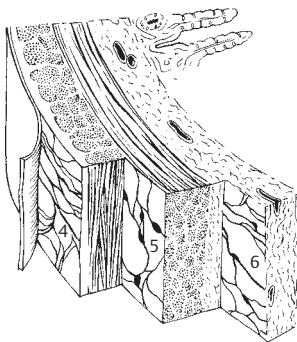
A Superior cervical ganglion with branches



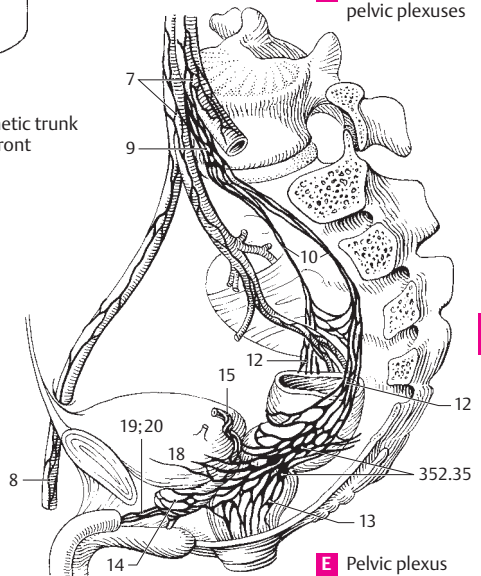
D Abdominal and pelvic plexuses



B Sympathetic trunk from in front

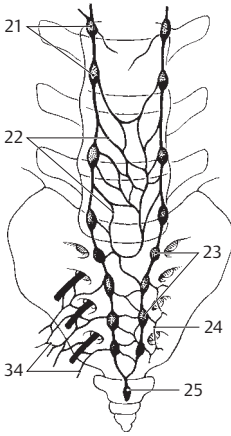


C Plexuses in intestinal wall

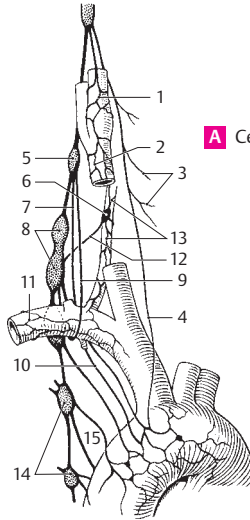


E Pelvic plexus

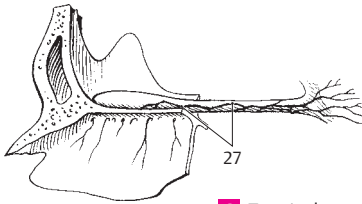
- 1 **External carotid plexus.** Plexus caroticus externus. Autonomic nerve plexus around the external carotid artery. A
- 2 **Common carotid plexus.** Plexus caroticus communis. It surrounds the common carotid artery. A
- 3 **Laryngopharyngeal branches.** Rami laryngopharyngeales. Postganglionic fibers to the pharyngeal plexus. A
- 4 **Superior cervical cardiac nerve.** N. cardiacus cervicalis superior. Fibers to the cardiac plexus. A
- 5 **Middle cervical ganglion.** Ganglion cervicale medium. Often very small ganglion of the sympathetic trunk that lies at the level of C6 in front of or behind the inferior thyroid artery. A E
- 6 **Vertebral ganglion.** Ganglion vertebrale. Small accessory ganglion usually on the vertebral artery in front of its entrance into the foramen transversarium. A
- 7 **Middle cervical cardiac nerve.** N. cardiacus cervicalis medius. It passes from the middle cervical ganglion to the deep part of the cardiac plexus. A
- 8 **Cervicothoracic (stellate) ganglion.** Ganglion cervicothoracicum (stellatum). Fusion of the inferior cervical ganglion with the 1st or, in many cases (ca. 75%) 2nd thoracic ganglion. A E
- 9 **Ansa subclavia.** Cord of nerve fibers forming a loop around the subclavian artery. A
- 10 **Inferior cervical cardiac nerve.** N. cardiacus cervicalis inferior. It passes to the deep part of the cardiac plexus. A
- 11 **Subclavian plexus.** Plexus subclavius. Autonomic nerve plexus around the subclavian artery. A
- 12 **Vertebral nerve.** N. vertebralis. Located behind the vertebral artery; it forms the vertebral plexus. A
- 13 **Vertebral plexus.** Plexus vertebralis. Network of nerves around the vertebral artery. A
- 14 **Thoracic ganglia.** Ganglia thoracica. 11–12 thickenings in the thoracic sympathetic trunk. A E
- 15 **Thoracic cardiac branches.** Rami cardiaci thoracici. Rami with efferent and afferent (pain) fibers passing from T2–4(5) thoracic ganglia to the cardiac plexus. A E
- 15a **Thoracic pulmonary branches.** Rami pulmonales thoracici. Efferent fibers from T2–4 ganglia to the pulmonary plexus at the lung hilum.
- 15b **Esophageal branches.** Rami oesophageales. Efferent fibers from T2–5 ganglia.
- 16 **Greater splanchnic nerve.** N. splanchnicus major. It passes from sympathetic trunk ganglia 5–9(10) to the celiac ganglion and contains pre- and postganglionic fibers which conduct pain and other sensations from the upper abdominal organs. E
- 17 **Thoracic splanchnic ganglion.** Ganglion thoracicum splanchnicum. Accessory ganglion at the level of T9. It is incorporated into the greater splanchnic nerve. E
- 18 **Lesser splanchnic nerve.** N. splanchnicus minor. Arises from sympathetic trunk ganglia 9–11 and is similar to the greater splanchnic nerve. E
- 19 **Renal branch.** Ramus renalis. Occasional branch from the lesser splanchnic nerve to the renal plexus. E
- 20 **Lowest splanchnic nerve.** N. splanchnicus imus. It often arises independently from the T12 ganglion and passes to the renal plexus. E
- 21 **Lumbar ganglia.** Ganglia lumbalia (lumbaria). The sympathetic ganglia of the lumbar vertebral column, usually four on either side. B
- 22 **Lumber splanchnic nerves.** Nervi splanchnici lumbales (lumbares). Usually four nerves from the lumbar sympathetic trunk forming a plexus on L5. B
- 23 **Sacral ganglia.** Ganglia sacralia. Four smaller ganglia lying medial to the pelvic sacral foramina. B
- 24 **Sacral splanchnic nerves.** Nervi splanchnici sacrales. Two to three fine nerves from sacral ganglia 2–4. B
- 25 **Ganglion impar.** Last unpaired sympathetic trunk ganglion lying in front of the coccyx. B
- 26 **PARASYMPATHETIC PART (SYSTEM).** Pars parasympathetica. Craniosacral component of the autonomic nervous system involving cranial nerves III, VII, IX, and X and sacral spinal nerves 2–4. Antagonistic to the sympathetic division, it slows down the heart beat and stimulates intestinal and sexual functions.
- 26a **Cranial part.** Pars cranialis.
- 27 **Terminal nerve.** N. terminalis. A slender, partly interwoven nerve of unknown function, but probably autonomic. It unites the olfactory region with the anterior perforated substance. C
- 28 **Terminal ganglion.** Ganglion terminale. It comprises all of the ganglion cells dispersed in the terminal nerves.
- 29 **Ciliary ganglion.** Ganglion ciliare. Located lateral to the optic nerve. It receives preganglionic fibers from the oculomotor nerve and gives off postganglionic fibers which constrict the pupil and contract the ciliary muscles during accommodation. D
- 30 **Pterygopalatine ganglion.** Ganglion pterygopalatinum. Nerve that lies lateral to the sphenopalatine foramen, receives motor fibers from the facial nerve via the nerve of the pterygoid canal and supplies the lacrimal and nasal glands. D
- 31 **Otic ganglion.** Ganglion oticum. Situated below the foramen ovale and medial to the mandibular nerve. It receives motor fibers from the glossopharyngeal nerve via the lesser petrosal nerve and innervates the parotid gland. D
- 32 **Submandibular ganglion.** Ganglion submandibulare. Located along the lingual nerve below the mandible. It receives motor fibers from the facial nerve via the chorda tympani and sends efferent fibers to the sublingual and submandibular glands. D
- 33 **Sublingual ganglion.** Ganglion sublinguale. Small accumulations of cells occasionally present on the glandular branches.
- 33a **Pelvic part (Pars pelvica).** Sacral part of parasympathetic division.
- 34 **Pelvic splanchnic nerves.** Nn. pelvici splanchnici (nn. erigentes). Parasympathetic fibers from S2–4 spinal nerves to the pelvic ganglia for the pelvic and genital organs. They also contain afferent fibers. B
- 35 **Pelvic ganglia.** Ganglia pelvica. Groups of autonomic cells in the inferior hypogastric plexus. They give rise to the postganglionic axons. See p. 351 E



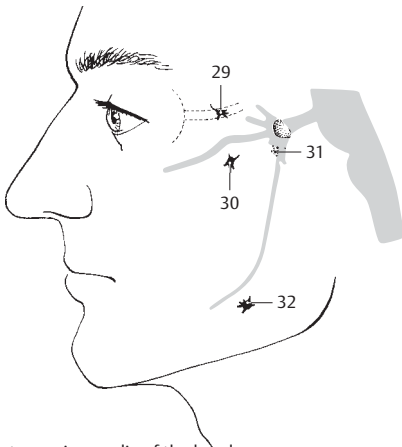
B Lumbo-sacral sympathetic trunk



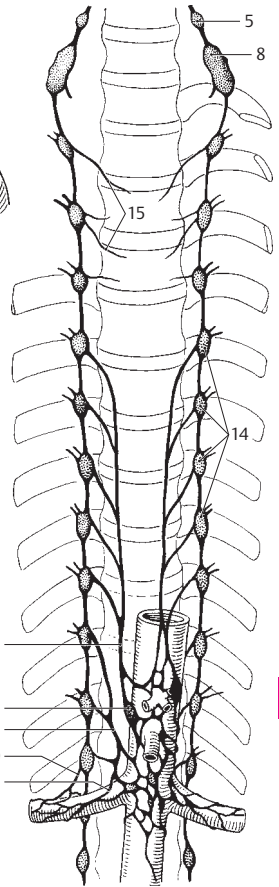
A Cervical sympathetic trunk



C Terminal nerves

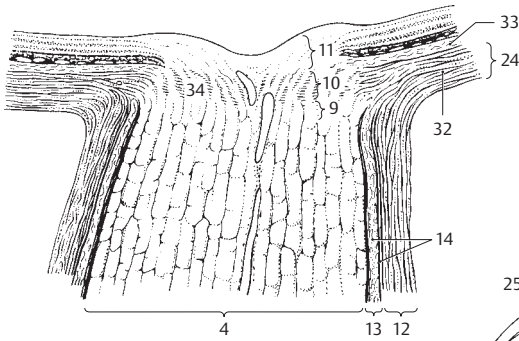


D Autonomic ganglia of the head

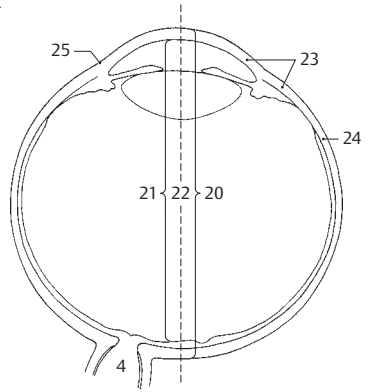


E Splanchnic nerves

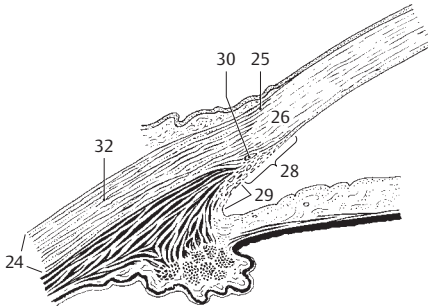
- 1 **SENSE ORGANS.** Organa sensoria (sensuum). In the narrow sense, the organs of vision, hearing, smell and taste.
- 2 **ORGAN OF VISION.** Organum visus (visuale).
- 3 **EYE.** Oculus.
- 4 **Optic nerve.** N. opticus. Fiber bundle beginning in the retina and extending as far as the optic chiasm. Histologically and embryologically speaking, it is the tract of the brain that is accordingly enclosed by meninges up to the posterior aspect of the eyeball. Its axons have no neurilemma (sheath of Schwann) but are myelinated. The myelin sheath is formed by the oligodendroglia. A C E
- 5 **Intracranial part.** Pars intracranialis. Segment of the optic nerve between the optic canal and the chiasm. E
- 6 **Intracanalicular part.** Pars intracanicularis. Segment of the optic nerve located in the optic canal. It is partially connected with the canal wall. E
- 7 **Orbital part.** Pars orbitalis. Slightly tortuous segment of the optic nerve measuring about 3 cm in length and occupying the orbit. E
- 8 **Intraocular part.** Pars intraocularis. Segment of optic nerve located in the wall of the eyeball.
- 9 **Postlaminar part.** Pars postlaminaris. Intraocular segment located behind the lamina cribrosa and thus at the site where the external sheath of the optic nerve (dura) blends into the sclera. A
- 10 **Intralaminar part.** Pars intralaminaris. Intraocular segment lying within the lamina cribrosa. A
- 11 **Prelaminar part.** Pars preliminaris. Intraocular segment extending between the lamina cribrosa and the nerve fiber layer of the retina. A
- 12 **External sheath.** Vagina externa. Dural covering of the optic nerve extending up to the eyeball. A
- 13 **Internal sheath.** Vagina interna. Pia and arachnoid coverings accompanying the optic nerve to the eyeball. A
- 14 **Intervaginal spaces.** Spatia intervaginalia. Subarachnoid space accompanying the optic nerve and the capillary space between the arachnoid and dura. A
- 15 **Eyeball.** Bulbus oculis. Globe of the eye. It consists of the cornea and sclera together with all of the structures they enclose. D
- 16 **Anterior pole.** Polus anterior (center of anterior curvature) of the eyeball, which is determined by the corneal vertex. D
- 17 **Posterior pole.** Polus posterior (center of posterior curvature) of the eyeball, which lies lateral to the exit of the optic nerve and opposite to the anterior pole. D
- 18 **Equator.** Aequator. Greatest circumference of the eyeball located equidistant from the anterior and posterior poles. D
- 19 **Meridians.** Meridiani. Semicircles oriented at right angles to the equator between the anterior and posterior poles. D.
- 20 **External axis of eyeball.** Axis bulbi externus. Line connecting anterior and posterior poles. C
- 21 **Internal axis of eyeball.** Axis bulbi internus. Distance from posterior surface of cornea to the inner surface of retina measured along an imaginary line (external axis of eyeball) through the anterior and posterior poles. C
- 22 **Optic axis.** Axis opticus. Line passing through the midline of the cornea and lens and bisecting the retina between the fovea centralis and optic disc. C
- 23 **FIBROUS TUNIC OF EYEBALL.** Tunica fibrosa bulbi. External wall of eyeball comprising the cornea and sclera. C
- 24 **Sclera.** The bluish-white outer coat of the eyeball, which consists of irregularly arranged collagenous fibers visible through the conjunctiva. A B C
- 25 **Scleral sulcus.** Sulcus sclerae. Shallow groove between the cornea and sclera caused by the greater curvature of the cornea. B C D
- 26 **Corneoscleral junction.** Limbus. The concave border of the sclera adjacent to the cornea. B
- 27 **Trabecular meshwork (pectinate ligament).** Reticulum trabeculare (lig. pectinatum) [[spongium iridocorneale]]. Connective tissue framework at the iridocorneal (filtration) angle.
- 28 **Corneoscleral part.** Pars corneoscleralis. Part of the meshwork attached to the sclera. B
- 29 **Uveal part.** Pars uvealis. Part of the trabecular meshwork attached to the iris. B
- 30 **Canal of Schlemm.** Sinus venosus sclerae. Circular vessel occupying the interior aspect of the trabecular meshwork. It can be interrupted or doubled and is involved in the discharge of aqueous humor from the anterior chamber. B
- 31 **Episclera.** Lamina episcleralis. Delicate displaceable connective tissue between the outer surface of the sclera and [[Tenon's capsule]] (bulbar fascia).
- 32 **Substantia propria sclerae corneal stroma.** The proper substance, i.e., main part of the sclera. It consists of irregularly arranged collagenous fibers with sparse elastic fibers. A B
- 33 **Lamina fusca sclerae.** Layer of loose connective tissue connecting the sclera and the choroid lying below it. It appears yellowish owing to the pigment cells dispersed within it. A
- 34 **Lamina cribrosa.** Fine, perforated layer of the sclera for the passage of optic nerve fibers from the retina. A



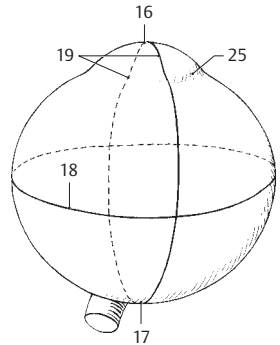
A Optic nerve with coverings at point of exit



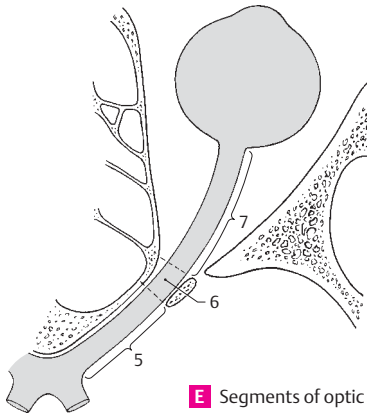
C Eye, schematic



B Iridocorneal angle




D Eye, lines of orientation

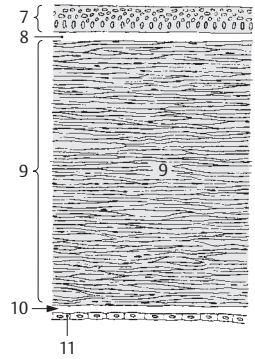


E Segments of optic nerve

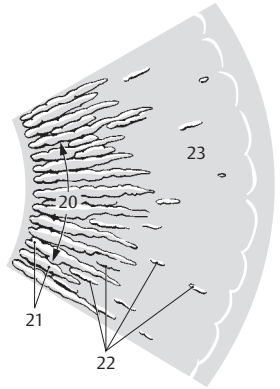
- 1 **Cornea.** The transparent anterior part (1/6) of the eyeball with an anterior convex curvature and a posterior concave curvature. It is 0.9 mm thick in the middle, 1.2 mm thick at its margins. B D
- 2 **Conjunctival ring.** Anulus conjunctivae. Junction between bulbar conjunctival epithelium and the anterior epithelium of the cornea. D
- 3 **Corneoscleral junction.** Limbus corneae. D
- 4 **Vertex corneae.** The most prominent point on the anterior surface of the cornea.
- 5 **Anterior surface.** Facies anterior. Corneal surface facing the outside air. D
- 6 **Posterior surface.** Facies posterior. Corneal surface facing the anterior chamber. D
- 7 **Anterior epithelium.** Epithelium anterius. Stratified (about 5 layers) squamous epithelium covering the anterior surface of the cornea with a very smooth surface. B D
- 8 **Anterior limiting (Bowman's) membrane.** Lamina limitans anterior [[Bowman]]. Basal membrane of the anterior epithelium, about 10–20 mm thick. It is continuous posteriorly with the substantia propria. B
- 9 **Substantia propria.** Predominant part of the avascular cornea consisting of highly organized lamellar connective tissue embedded within a mucopolysaccharide substance. The state of turgescence of its fibers and the distribution of its colloidal matrix affect the transparency of the cornea. B
- 10 **Posterior limiting (Descemet's) membrane.** Lamina limitans posterior [[Descemet]]. Basal membrane of the corneal (posterior) endothelium. At its lateral margin it divides into fibers which radiate into the trabecular meshwork of the sclera and iris. Aqueous humor passes through its interstices to drain into the sinus venosus sclerae. B D
- 11 **Posterior epithelium (endothelium).** Epithelium posterius. Simple squamous epithelium lining the posterior surface of the cornea. B D
- 12 **VASCULAR TUNIC OF EYEBALL (UVEAL TRACT).** Tunica vasculosa bulbi (tractus uvealis). It represents the middle layer of the wall of the eyeball and consists of the choroid, ciliary body and iris.
- 13 **Choroid.** Choroidea. The vascular coat lying between the retina and sclera. A
- 14 **Suprachoroid lamina (lamina fusca).** Lamina suprachoroidea. Displaceable layer directly beneath the sclera. It contains only a few vessels and pigment; its fibers are partly covered by endothelium. A
- 15 **Perichoroidal space.** Spatium perichoroideale. Spatial system in the suprachoroid lamina, part of which forms lymph pathways. It houses the ciliary nerves, long and short posterior ciliary arteries and the vorticosae veins. A
- 16 **Vascular lamina.** Lamina vasculosa. It contains the branchings of the short posterior ciliary arteries. A
- 17 **Choriocapillaris.** Lamina choriocapillaris. Pigment-free layer of connective tissue with a dense network of capillaries extending as far as the ora serrata. It is often delimited from the vascular lamina by a special connective tissue layer. A
- 18 **Basal lamina [[Bruch's membrane]].** Complexus (lamina) basalis. Homogeneous zone about 2–4 mm thick between the choriocapillaris and the pigment epithelium of the retina. A
- 19 **Ciliary body.** Corpus ciliare. Enlarged uveal segment situated between the ora serrata and root of the iris. It contains ciliary muscles and processes. C
- 20 **Pars plicata (Corona ciliaris).** Circular zone occupied by ciliary processes. C
- 21 **Ciliary processes.** Processus ciliares. 70–80 radially oriented, capillary-rich folds, 0.1–0.2 mm wide, 1 mm high and 2–3 mm long. Their epithelium produces aqueous humor. C
- 22 **Ciliary folds.** Plicae ciliares. Low folds in the region of the corona ciliaris and between the ciliary processes. C
- 23 **Pars plana.** Orbiculus ciliaris. Circular zone lying between the corona and ora serrata. It is occupied by ciliary folds. C
- 24 **Ciliary muscle.** M. ciliaris. Smooth muscle occupying the ciliary body. It pulls the choroid forward and, in so doing, relaxes the zonule fibers so that the lens can become more strongly curved for accommodation of near objects. D
- 25 **Meridional (longitudinal) fibers.** Fibrae meridionales [fibrae longitudinales]. Larger muscle fibers oriented meridionally (longitudinally). Anteriorly they are attached to the posterior limiting lamina above the trabecular meshwork; posteriorly, they insert into the choroid. D
- 26 **Circular fibers.** Fibrae circulares. Circular muscle lying internal to the meridional fibers. D
- 27 **Radial fibers.** Fibrae radiales. Muscle fibers crossing perpendicular to the two other muscle systems and coursing outwardly.
- 28 **Basal lamina.** Lamina basalis. Continuation of the basal membrane of the choroid. It supports the epithelium. D



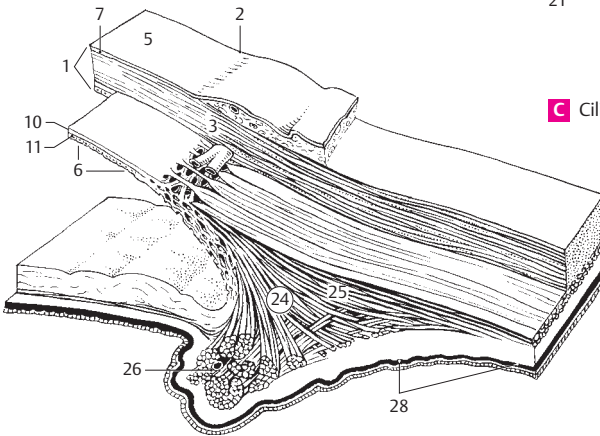
A Choroid



B Cornea

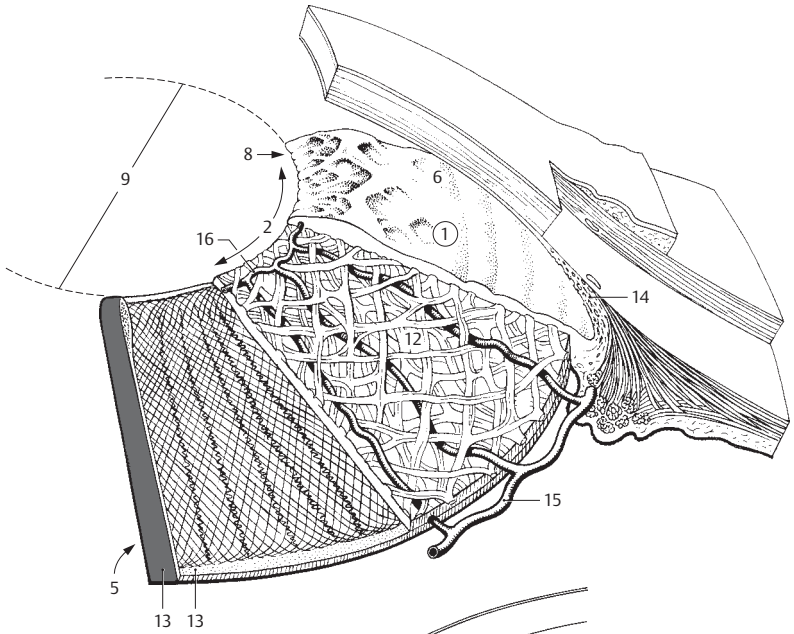


C Ciliary body from behind

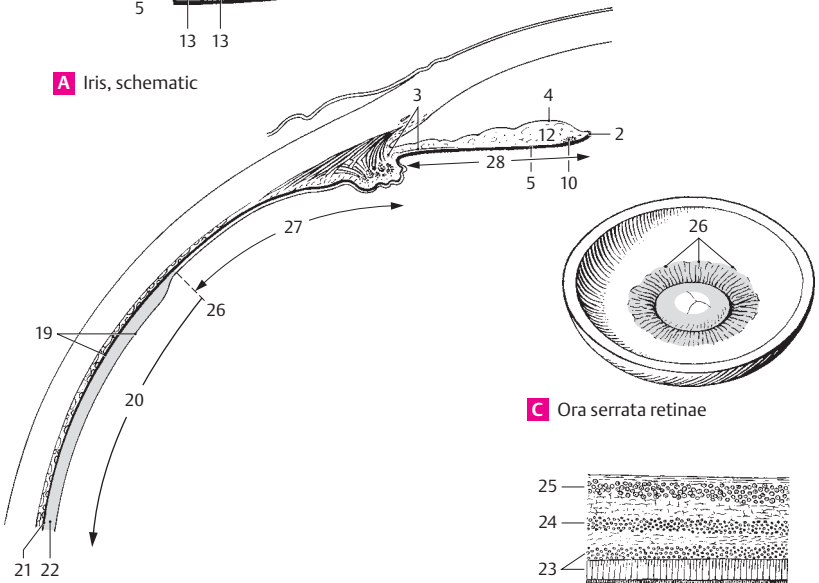


D Iridocorneal angle, schematic

- 1 **Iris.** Frontally-located, round, variably colored disk about 10–12 mm in diameter, with a central aperture (pupil). The iris forms the posterior border of the anterior chamber of the eye. Its lateral margins become continuous with the ciliary body. A
- 2 **Pupillary margin.** Margo pupillaris. Medial (internal) margin of the iris bordering the pupil. A B
- 3 **Ciliary margin.** Margo ciliaris. Lateral (external) margin of iris attached to ciliary body at the iridocorneal angle. B
- 4 **Anterior surface.** Facies anterior. It faces the anterior chamber. B
- 5 **Posterior surface.** Facies posterior. Surface facing the posterior chamber. A B
- 6 **Greater ring (circle) of iris.** Anulus iridis major. Ciliary segment of the iris, and outer circular zone on the anterior surface of the iris. It is coarser and broader than the lesser ring. A
- 7 **Lesser ring (circle) of iris.** Anulus iridis minor. Pupillary segment of iris. Narrow, circular inner zone on the anterior surface of iris. Its structure is finer than that of the greater ring. A
- 8 **Iridial folds.** Plicae iridis. Folds passing around the pupillary margin on the anterior side of the iris. They make the pupillary margin appear slightly serrated. A
- 9 **Pupil.** Pupilla. Aperture in the iris surrounded by the pupillary margin of the iris. Its diameter varies depending upon the intensity of light and the focal distance of the observed object. A
- 10 **M. sphincter pupillae.** Network of spirally coursing muscle fibers the longitudinal axes of which run approximately parallel to the pupillary margin when the pupil is dilated. It is innervated by parasympathetic fibers from the oculomotor nerve. B
- 11 **M. dilator pupillae.** Thin layer of smooth muscle mainly comprised of radially oriented fibers. It is innervated by sympathetic fibers from the carotid plexus.
- 12 **Stroma iridis.** Vascular framework of the iris infiltrated by pigmented connective tissue cells. Its anterior and posterior portions are thicker than the rest and are divided by a fine fibrous network. A B
- 13 **Pigmented (posterior) epithelium.** Epithelium pigmentosum. Bilayered epithelium on the posterior surface of the iris. It is so heavily pigmented that no nuclei are visible on the surface facing the posterior chamber. A
- 14 **Spaces of iridocorneal angle [spaces of Fontana].** Spatia anguli iridocornealis. Interstices between the fibers of the trabecular meshwork. They form passageways that convey aqueous fluid to the sinus venosus sclerae. A
- 15 **Greater arterial circle of iris.** Circulus arteriosus iridis major. Ringlike vascular system with radiating branches. It is formed by anastomoses between the long and short posterior ciliary arteries. A
- 16 **Lesser arterial circle of iris.** Circulus arteriosus iridis minor. Ringlike vascular system in the vicinity of the pupillary margin formed by anastomoses between the radial branches of the greater arterial circle. A
- 17 **Pupillary membrane.** [Membrana pupillaris]. Anterior part of embryonal vascular membrane around the lens that is situated behind the pupil. It is fused to the pupillary margin and receives blood vessels from there.
- 18 **INTERNAL (SENSORY) TUNIC OF EYEBALL.** Tunica interna bulbi. It comprises the retina with its pigment epithelium.
- 19 **Retina.** Inner lining of eyeball developed from the two layers of the optic cup. Most of it is light-sensitive (pars optica). B
- 20 **Pars optica retinae.** Retinal segment capable of transforming light stimuli into nerve impulses. It lines the posterior aspect of the eyeball and extends as far anteriorly as the ora serrata. B
- 21 **Pigmented part.** Pars pigmentosa. Pigment epithelium arising from the external layer of the optic cup. B
- 22 **Nervous part.** Pars nervosa. Retina proper consisting essentially of three nuclear layers lying internal to the pigment epithelium. B
- 23 **Neuroepithelial (photosensitive) layer.** Stratum neuroepitheliale (photosensorium). Outer layer of the cerebral stratum. It consists of rods and cones, the outer segments of which affect the transformation of light stimuli into nerve impulses. Cell bodies of rods and cones form the outermost layer of the retinal nuclei (external nuclear layer). D
- 24 **Internal nuclear layer.** [[Stratum ganglionare retinae]]. Middle layer of cell nuclei mainly consisting of the cell bodies of bipolar and amacrine cells. D
- 25 **Ganglion cell layer.** [[Stratum ganglionare n. optici]]. Internal layer of nuclei consisting of multipolar cell bodies of initially non-myelinated ganglion cells the axons of which form the optic nerve. D
- 26 **Ora serrata.** Serrated margin between the light-sensitive and light-insensitive parts of the neural retina. B C
- 27 **Pars ciliaris retinae.** Light-insensitive retinal segment consisting of a bilayered cuboidal epithelium (ciliary epithelium) forming the posterior surface of the ciliary body. Its outer layer of epithelium is continuous with the pigment epithelium of the retina and is pigmented, whereas the innermost epithelium is continuous with the pars nervosa of the retina and is devoid of pigment. B
- 28 **Pars iridica retinae.** Light-insensitive retinal segment on the posterior surface of the iris. It is continuous with the pars ciliaris retinae and forms the bilayered posterior epithelium of the iris. Both layers are heavily pigmented. B



A Iris, schematic

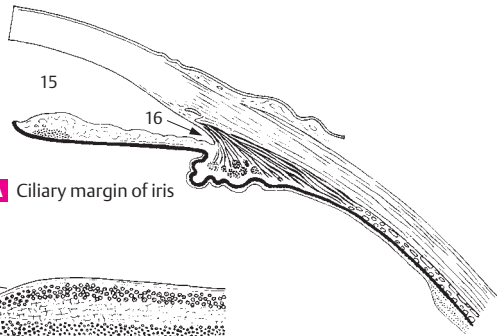


B Sections of retina

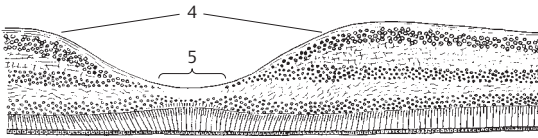
C Ora serrata retinae

D Retinal layers

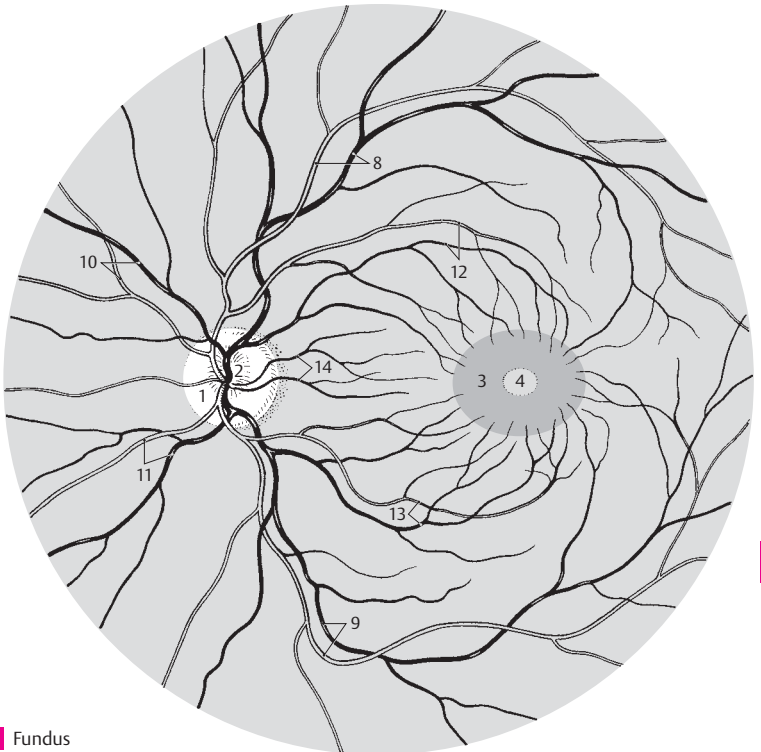
- 1 **Optic disc (papilla).** Discus nervi optici [papilla nervi optici]. Beginning of the optic nerve as visualized in the fundus about 3–4 mm medial to the macula. It is about 1.6 mm in diameter. C
- 2 **Physiological cup.** Excavatio disci. Depression in the middle of the optic disc with the stems of the central retinal artery and vein. C
- 3 **Macula** [[lutea]]. Transversely oval, yellowish area, 2–4 mm in diameter, at the posterior pole of the retina. C
- 4 **Fovea centralis.** Central fovea, a small depression in the macula caused by thinning of the upper retinal layers. Its diameter, measured from the beginning of the decrease in retinal thickness from one side to the other, is approximately 1–2 mm. B C
- 5 **Foveola.** Thinnest area of fovea centralis with a diameter of about 0.2–0.4 mm. Here, the retina is comprised entirely of approx. 2500 closely packed cones. B
- 6 **Retinal blood vessels.** Vasa sanguinae retinae. Branches of the central retinal artery and vein located on the internal aspect of the retina.
- 7 **Circle of arteries around the optic nerve.** Circulus vasculosus nervi optici. Small vascular ring penetrating the sclera around the optic nerve.
- 8 **Superior temporal arteriole/venule of retina.** Arteriola/venula temporalis retinae superior. Lateral upper branch of the central retinal artery and vein. C
- 9 **Inferior temporal arteriole/venule of retina.** Arteriola/venula temporalis retinae inferior. Lateral lower branch of the central retinal artery and vein. C
- 10 **Superior nasal arteriole/venule of retina.** Arteriola/venula nasalis retinae superior. Upper medial branch of the central retinal artery and vein. C
- 11 **Inferior nasal arteriole/venule of retina.** Arteriola/venula nasalis retinae inferior. Lower medial branch of the central retinal artery and vein. C
- 12 **Superior macular arteriole/venule.** Arteriola/venula macularis superior. They supply and drain the upper part of the macula. C
- 13 **Inferior macular arteriole/venule.** Arteriola/venula macularis inferior. They supply and drain the lower part of the macula. C
- 14 **Medial arteriole/venule of retina.** Arteriola/venula medialis retinae. Small branches that supply and drain the medial part of retina proximal to the optic disc. C
- 14a **CHAMBERS OF THE EYE.** Camerae bulbi.
- 15 **Anterior chamber.** Camera anterior. Space that extends from the anterior surface of the iris to the posterior surface of the cornea and communicates with the posterior chamber via the pupil. A
- 16 **Iridocorneal angle.** Angulus iridocornealis. Angle between the iris and cornea. It houses the trabecular meshwork, the interstices of which serve as passageways that drain aqueous humor into the sinus venosus sclerae. A
- 17 **Aqueous humor.** Humor aquosus. Fluid produced by the epithelium of the ciliary processes (total quantity: 0.2–0.3 cm³). The clear fluid consists of 98% water, 1.4% NaCl and traces of protein and sugar. It has a refractive index of 1.336.



A Ciliary margin of iris

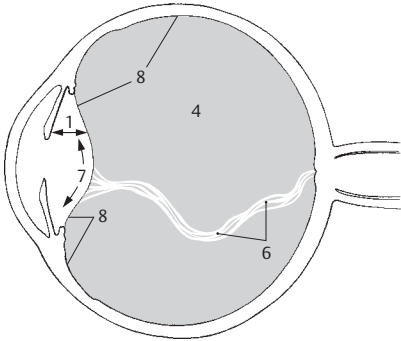


B Fovea centralis

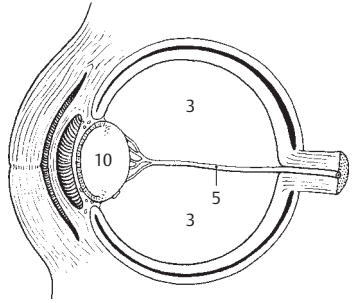


C Fundus

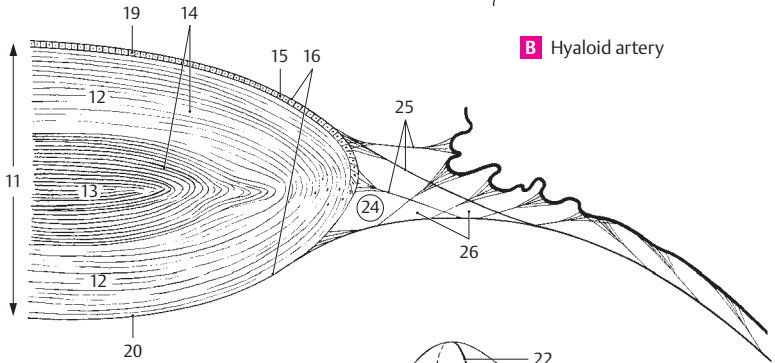
- 1 **Posterior chamber.** Camera posterior. It extends from the iris and ciliary body to the anterior surface of the vitreous. A
- 2 **Aqueous humor.** Humor aqueus. Produced by the ciliary processes. It flows between the interstices of the suspensory ligaments of the lens to the anterior surface of the lens and then between the iris and lens to the pupil, through which it enters the anterior chamber.
- 3 **Vitreous chamber.** Camera vitrea. Space filled up by the vitreous body. B
- 4 **Vitreous body.** Corpus vitreum. It consists of about 98% water and primarily contains traces of protein and NaCl and a mixture of fine fibrils which thicken near the surface to form a limiting membrane. It has a gelatinous consistency due to its high content of hyaluronic acid. A
- 5 **Hyaloid artery.** [A. hyaloidea]. Branch of the ophthalmic artery supplying the vascular membrane of the lens. Present only during embryonic development. The proximal portion persists in the optic nerve as the central retinal artery. B
- 6 **Hyaloid canal.** Canalis hyaloideus. Canal within the vitreous body formerly occupied by the embryonic hyaloid artery which degenerates in this region. The canal assumes a downward sagging corkscrew shape; it extends from the optic disc to the posterior surface of the lens. Its wall is formed by condensed fibers. A
- 7 **Hyaloid (lenticular, patellar) fossa.** Fossa hyaloidea. Fossa on the anterior surface of the vitreous body adjacent to the lens. A
- 8 **Vitreous (hyaloid) membrane.** Membrana vitrea. Condensation of fibers on the surface of the vitreous body. See (4), vitreous body. A
- 9 **Stroma of vitreous body.** Stroma vitreum. Fine network of fibers in the vitreous body. Its surface thickens to form the vitreous membrane.
- 9a **Vitreous humor.** Humor vitreus. Fluid part of vitreous body. Primarily consists of mucopolysaccharides and is situated between the fibers of the stroma.
- 10 **LENS.** Structure of the eye situated between the pupil and vitreous body. It is suspended by the ciliary zonule (suspensory ligaments), has a diameter of 9–10 mm and is about 4 mm thick. B C D
- 11 **Substantia lentis.** Lens substance situated beneath the lens epithelium and comprising the lens nucleus and lens cortex with a refractive index of 1.44–1.55. C
- 12 **Lens cortex.** Cortex lentis. External zone of the lens. It is softer owing to its high water content and blends into the lens nucleus without a sharp boundary. C
- 13 **Nucleus of lens.** Nucleus lentis. Harder core of the lens with a low water content, as is especially evident in the elderly. C
- 14 **Lens fibers.** Fibrae lentis. Fibers corresponding to the lens epithelium from which they develop. They form the lens substance measuring 2.5–12 μm thick and up to 10 mm long. C
- 15 **Epithelium of lens.** Epithelium lentis. Part of the lens confined to the anterior surface and extending as far as the equator. It is derived embryologically from the anterior epithelium of the lens vesicle. C
- 16 **Lens capsule.** Capsula lentis. Transparent membrane, up to 15 μm thick, covering the lens including its epithelium. Its anterior pole is thicker than the posterior pole. It gives attachment to the suspensory ligaments. C
- 17 **Anterior pole.** Polus anterior. D
- 18 **Posterior pole.** Polus posterior. D
- 19 **Anterior surface.** Facies anterior. Less curved lens surface with a radius of 8.3–10 mm. C
- 20 **Posterior surface.** Facies posterior. More curved lens surface with a radius of about 6.5 mm. C
- 21 **Axis.** Line connecting anterior and posterior poles. D
- 22 **Equator.** Margin of lens. D
- 23 **Radii of lens.** Suture line of the individual lens fibers. In the young it resembles a triradiate seam. D
- 24 **Ciliary zonule.** Zonula ciliaris. Suspensory apparatus together with its interstices. It encircles the lens equator and consists of a radially oriented system of fibers of variable length and the folds situated between them. C
- 25 **Zonular fibers (suspensory ligaments).** Fibrae zonulares. Suspensory fibers attached to the equator and the adjacent anterior and posterior surfaces of the lens. They arise distally from the basal lamina of the ciliary body and the pars ciliaris retinae. C
- 26 **Zonular spaces.** Spatia zonularia. Spaces between the zonule fibers filled with percolating aqueous humor. C



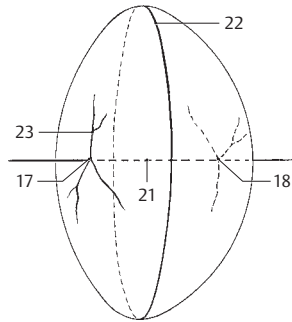
A Posterior chamber of eye



B Hyaloid artery

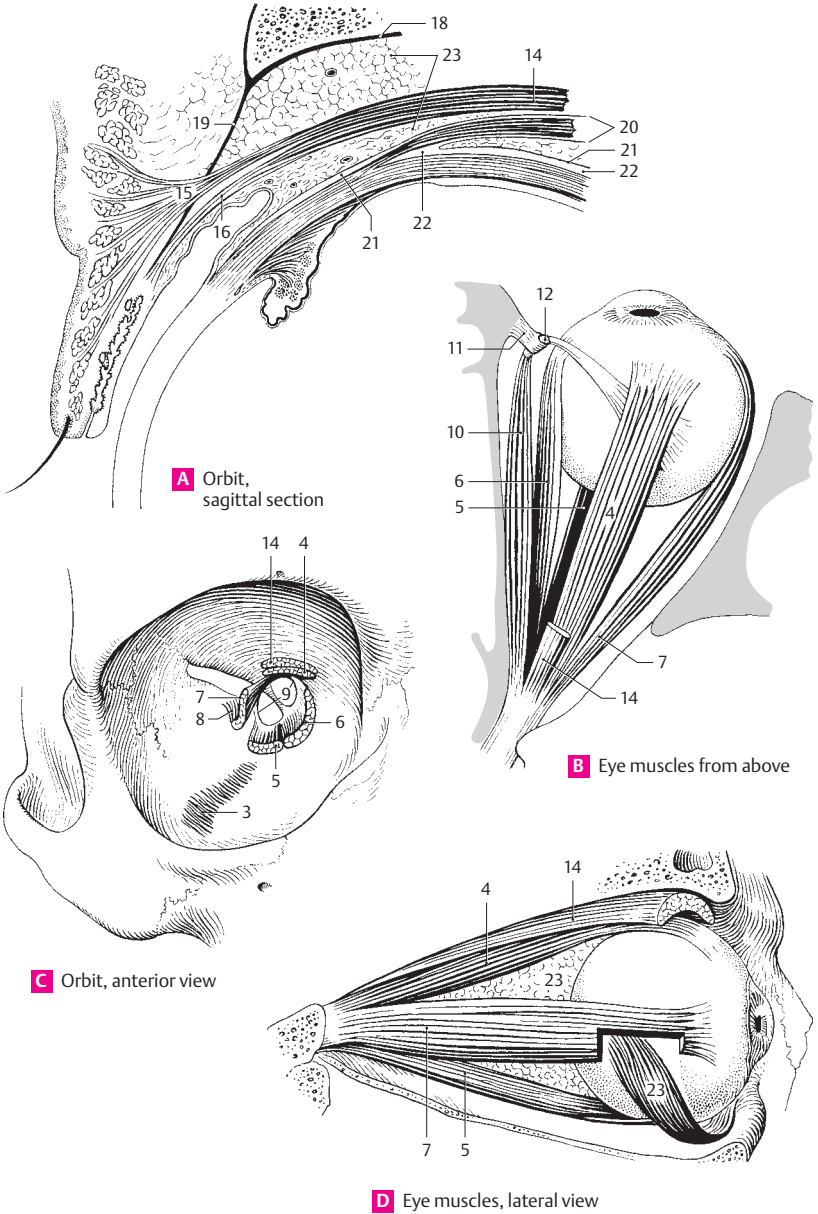


C Lens and zonula ciliaris

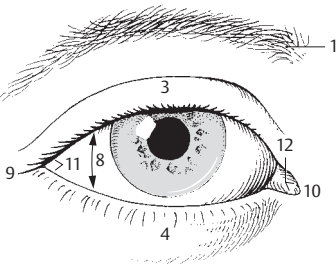


D Lens of eye

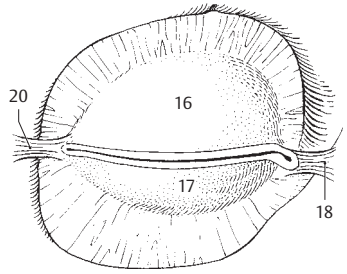
- 1 **ACCESSORY ORGANS OF EYE.** Organa oculi accessoria.
- 2 **Muscles of eye.** Musculi bulbi. Extrinsic ocular muscles.
- 3 **Orbital muscle.** M. orbitalis. Thin layer of smooth muscle which bridges the inferior orbital fissure. C
- 4 **Superior rectus.** M. rectus superior. o: Common tendinous ring. i: Along an oblique line in front of the equator, 7–8 mm posterior to the corneal margin. A: Elevation and medial rotation of superior pole of eyeball. I: Oculomotor nerve. B C D
- 5 **Inferior rectus.** M. rectus inferior. o: Common tendinous ring. i: Along an oblique line about 6 mm behind the corneal margin. A: Depression and lateral rotation of superior pole of eyeball. I: Oculomotor nerve. B C D
- 6 **Medial rectus.** M. rectus medialis. o: Common tendinous ring. i: About 5.5 mm from the corneal margin. A: Adduction of corneal pole. I: Oculomotor nerve. B C
- 7 **Lateral rectus.** M. rectus lateralis. o: Common tendinous ring and lesser wing. i: 5.5 mm behind corneal margin. A: Abduction of corneal pole. I: Abducent nerve. B C D
- 8 **Tendon of lateral rectus at greater wing.** Lacertus musculi recti lateralis. C
- 9 **Common tendinous ring (common annular tendon).** Anulus tendineus communis. Tendinous ring for attachment of the recti ocular muscles. It surrounds the optic canal and medial part of the superior orbital fissure. C
- 10 **Superior oblique.** M. obliquus superior. o: Body of sphenoid medial to common tendinous ring. i: Posterolateral aspect of sclera behind the equator after its tendon passes through the trochlea and approaches sclera obliquely from the medial margin of orbit. A: Abduction, medial rotation and depression. I: Trochlear nerve. B
- 11 **Trochlea.** Cartilaginous sling attached to the medial wall of the orbit [trochlear spine] and serving as a pulley for the tendon of the superior oblique muscle. B
- 12 **Tendon sheath of superior oblique muscle (synovial bursa of trochlea).** Vagina tendinis m. obliqui superioris [bursa synovialis trochlearis]. Synovial sheath (bursa) for the tendon of the superior oblique muscle separating the tendon from the trochlea. B
- 13 **Inferior oblique.** M. obliquus inferior. o: Lateral to the nasolacrimal canal. i: Posterior to equator. A: Elevation, abduction and lateral rotation. I: Oculomotor nerve. D
- 14 **M. levator palpebrae superioris.** o: Bone above optic canal and dura of optic nerve. Its tendon broadens anteriorly and splits to form an upper and lower layer. I: Oculomotor nerve. A C D
- 15 **Superficial lamina of levator tendon.** Lamina superficialis. It passes between the tarsus and orbicularis oculi to insert into the subcutaneous connective tissue of the upper eyelid. It is so broad that it extends mainly laterally to the wall of the orbit. A
- 16 **Deep lamina of levator tendon.** Lamina profunda. It inserts into the upper margin and the anterior surface of the tarsus. A
- 17 **Orbital fasciae.** Fasciae orbitales.
- 18 **Periosteum of orbit.** Periorbita. It is delicate and fused solidly to the bone at the inlet and outlet of the orbit. Anteriorly, it is continuous with the adjacent periosteum, posteriorly with the dura. A
- 19 **Orbital septum.** Septum orbitale. Connective tissue septum partly reinforced by tendon. It passes from the orbital margin below the orbicularis oculi to the external margins of the tarsi and forms the anterior end of the orbit. A
- 20 **Muscular fasciae.** Fasciae musculares. Sheaths of Tenon's capsule enveloping the tendons and muscular bellies of the 6 extrinsic ocular muscles. A
- 21 **Tenon's capsule (fascia bulbi).** Vagina bulbi. Connective tissue gliding membrane between the eyeball and orbital fat. It is fused to the sclera posteriorly at the optic nerve. Anteriorly it ends beneath the conjunctiva. It is separated from the sclera primarily by the episcleral space. A
- 22 **Episcleral space.** Spatium episclerale [inter-vaginale]. Gliding space between the eyeball and Tenon's capsule. It is traversed by long, delicate connective tissue fibers. A
- 23 **Orbital fat body.** Corpus adiposum orbitae. Adipose tissue fills the spaces around the ocular muscles, the eyeball and the optic nerve and is bordered anteriorly by the orbital septum. A D



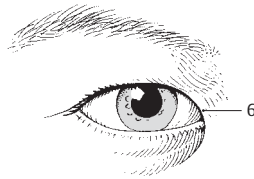
- 1 **Eyebrow.** Supercilium. The transverse elevation above the eyes, covered by thick, bristle-like hairs. A
- 2 **Eyelids.** Palpebrae.
- 3 **Upper eyelid.** Palpebra superior. A
- 4 **Lower eyelid.** Palpebra inferior. A
- 5 **Anterior palpebral surface.** Facies anterior palpebralis. The anterior external (skin-covered) surface of the eyelid. E
- 6 **Epicanthus (mongolian fold).** [Plica palpebronasalis] [[epicanthus]]. Vertical fold covering the medial angle of the eye. It is a continuation of the upper eyelid at the lateral nasal wall. C
- 7 **Posterior palpebral surface.** Facies posterior palpebralis. Surface lined by conjunctival epithelium and containing dispersed goblet cells. E
- 8 **Palpebral fissure.** Rima palpebrarum. Space between the margins of the upper and lower eyelids. A E
- 9 **Lateral palpebral commissure.** Commissura palpebralis lateralis. Lateral junction of the upper and lower eyelids. A
- 10 **Medial palpebral commissure.** Commissura palpebralis medialis. Medial junction of the upper and lower eyelids. A
- 11 **Lateral angle (canthus) of eye.** Angulus oculi lateralis. Acute lateral angle of the eye; it is also the lateral end of the palpebral fissure. A
- 12 **Medial angle (canthus) of eye.** Angulus oculi medialis. More rounded medial end of the palpebral fissure which delimits a triangular space, the lacrimal lake. A
- 13 **Limbi palpebrales anteriores.** Anterior edges of the free margins of the eyelids adjacent to the external skin. E
- 14 **Limbi palpebrales posteriores.** Posterior edges of the free margins of the eyelids adjacent to the conjunctiva. E
- 15 **Eyelashes.** Cilia. The 3–4 rows of hair growing near the anterior edge of the free margin of the eyelids. E F
- 16 **Superior tarsal plate.** Tarsus superior. Curved plate about 10 mm high occupying the upper eyelid and consisting of compact, interwoven collagenous connective tissue with tarsal glands. B E
- 17 **Inferior tarsal plate.** Tarsus inferior. Plate about 5 mm high within the lower eyelid. It likewise consists of firm, interwoven collagenous connective tissue with tarsal glands. B E
- 18 **Medial palpebral ligament.** [[Lig. palpebrale mediale]]. Band of connective tissue between the medial palpebral commissure and the medial wall of the orbit. It lies in front of the lacrimal sac. B D
- 19 **Lateral palpebral raphe.** [[Raphe palpebralis lateralis]]. Delicate band on the lateral palpebral ligament. It is reinforced by the orbicularis oculi muscle. D
- 20 **Lateral palpebral ligament.** Lig. palpebrale laterale. Fibrous band that attaches the lateral palpebral commissure to the lateral wall of the orbit in front of the orbital septum. B
- 21 **Tarsal [[Meibomian]] glands.** Glandulae tarsales. Elongated holocrine glands located in the superior and inferior tarsal plates with openings near the posterior edge of the free margin of the eyelids. They produce a sebaceous secretion for lubrication of the lid margins. E
- 22 **Superior tarsal muscle.** M. tarsalis superior. Smooth muscle fibers between the muscle-tendon border of the levator palpebrae muscle and the superior tarsal plate. E
- 23 **Inferior tarsal muscle.** M. tarsalis inferior. Smooth muscle fibers between the inferior fornix of the conjunctiva and the inferior tarsal plate. E
- 24 **Tunica conjunctiva.** The lining of the inner surface of the eyelids, which consists of two or more layers of columnar epithelium with goblet cells and a loose, cell-rich lamina propria containing multiple blood vessels. The tunica extends around the fornix of the conjunctiva to the eyeball, which it covers with a layer of stratified squamous epithelium that extends up to the corneal margin. E
- 25 **Semilunar fold of conjunctive.** Plica semilunaris conjunctivae. It lies in the medial angle of the eye between the fornix of the upper and lower eyelid. F
- 26 **Lacrimal caruncle.** Caruncula lacrimalis. Mucosal mass in the medial angle of the eye covered by stratified squamous or columnar epithelium. F



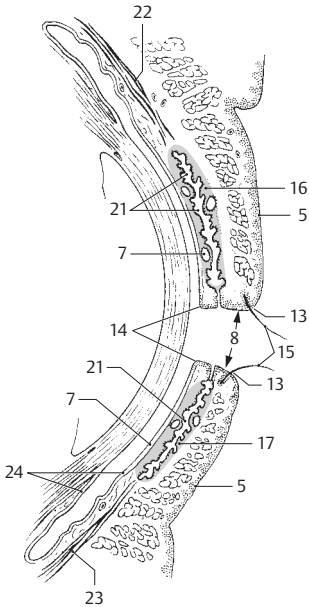
A Palpebral fissure



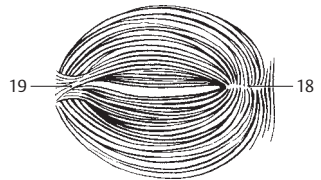
B Tarsal plates and ligaments



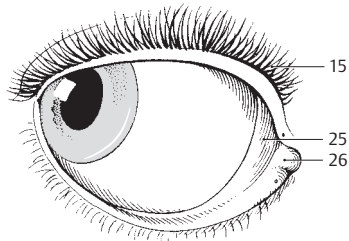
C Epicanthus (epicanthic fold)



E Eyelids, sagittal section

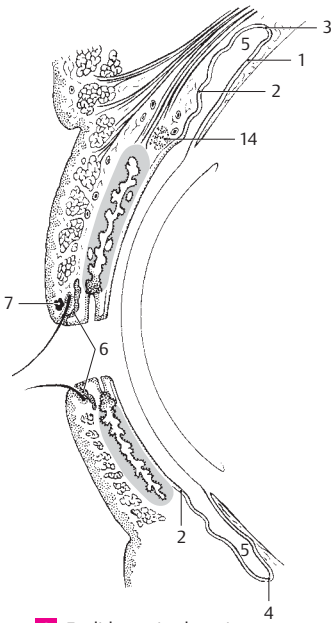


D Orbicular muscle of eye from behind

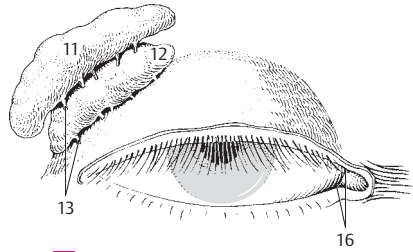


F Inner (nasal) canthus of eye

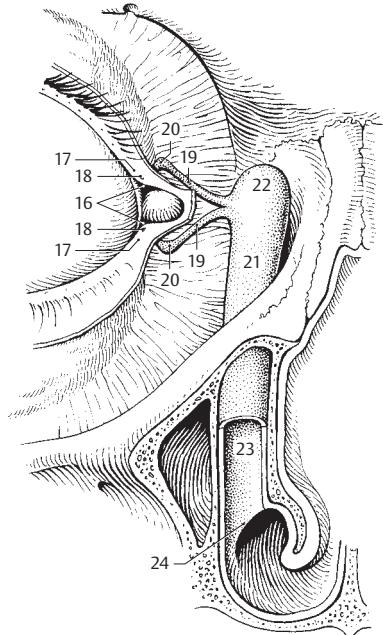
- 1 **Bulbar conjunctiva.** Tunica conjunctiva bulbaris. Part of conjunctiva covering the eyeball. It consists of stratified, nonkeratinized squamous epithelium with only a few goblet cells and a loose, cell-poor lamina propria permeated with elastic fibers. A
- 2 **Palpebral conjunctiva.** Tunica conjunctiva palpebralis. The portion of the conjunctiva covering the posterior surface of the eyelid. It consists of two or more layers of columnar epithelium with goblet cells and a loose, vascularized lamina propria. A
- 3 **Superior fornix of conjunctiva.** Fornix conjunctivae superior. Reflected fold of conjunctiva extending from the eyeball (bulbar) to the upper eyelid (palpebral). A
- 4 **Inferior fornix of conjunctiva.** Fornix conjunctivae inferior. Reflected fold of conjunctiva from the eyeball (bulbar) on to the lower eyelid (palpebral). A
- 5 **Conjunctival sac.** Saccus conjunctivalis. Space between palpebral and bulbar conjunctivae. Its upper and lower ends form the superior and inferior fornices of the conjunctiva. A
- 6 **Ciliary glands (of Moll).** Glandulae ciliares [[Moll]]. Apocrine glands on the lid margin. They open either into the hair follicles of the eyelashes or at the lid margin. A
- 7 **Sebaceous glands (of Zeiss).** Glandulae sebaceae [[Zeiss]]. Small sebaceous glands with openings into the hair follicles of the eyelashes. A
- 8 **Conjunctival glands.** Glandulae conjunctivales. Follicular aggregations of lymphocytes at the medial angle of the eye.
- 9 **Lacrimal apparatus.** Apparatus lacrimalis. The system of structures that lubricate the cornea and conjunctiva. B
- 10 **Lacrimal gland.** Glandula lacrimalis. Gland located above the lateral angle of the eyelids; it is separated into an upper and lower portion by the tendon of levator palpebrae muscle. Its excretory ducts open laterally into the superior fornix of the conjunctiva. B
- 11 **Orbital part.** Pars orbitalis. Larger portion of lacrimal gland located above the tendon of the levator palpebrae muscle. B
- 12 **Palpebral part.** Pars palpebralis. Smaller portion of lacrimal gland located below the tendon of the levator palpebrae muscle. B
- 13 **Excretory ducts of lacrimal gland.** Ductuli excretorii [[glandulae lacrimalis]]. 6–14 ducts opening into the superior fornix of the conjunctiva. B
- 14 **Accessory lacrimal glands.** [Gll. lacrimales accessoriae]. Additional smaller lacrimal glands found scattered especially in the vicinity of the superior conjunctival fornix. A
- 15 **Rivus lacrimalis.** Pathway that conducts tears from the excretory ducts to the lacrimal lake. It lies within the conjunctival sac between the closed eyelids and the eyeball.
- 16 **Lacrimal lake.** Lacus lacrimalis. Space in the medial angle of the eye around the lacrimal caruncle. B C
- 17 **Papilla lacrimalis.** Small cone-shaped elevation medial to the inner edge of both the upper and lower eyelids. Each apex houses an opening or lacrimal punctum. C
- 18 **Lacrimal punctum.** Punctum lacrimale. Small opening marking the beginning of the lacrimal fluid drainage system. C
- 19 **Lacrimal canaliculus.** Canaliculus lacrimalis. Small canal, up to 1 cm long, from each lacrimal punctum to the lacrimal sac. C
- 20 **Ampulla of lacrimal canaliculus.** Ampulla canaliculi lacrimalis. Slight enlargement at the bend of the lacrimal canaliculus. C
- 21 **Lacrimal sac.** Saccus lacrimalis. It is located in the lacrimal fossa and is about 1.5 cm long and about 0.5 cm wide. It descends directly into the nasolacrimal duct. C
- 22 **Fornix of lacrimal sac.** Fornix sacci lacrimalis. Dome-shaped upper margin of the lacrimal sac. C
- 23 **Nasolacrimal duct.** Ductus nasolacrimalis. Duct that is directly continuous with the lacrimal sac and about 1.2–2.4 cm in length. It passes through the nasolacrimal canal and opens into the inferior nasal meatus. Its flattened lumen is lined by a mucosa containing two or more layers of columnar epithelium bearing cilia at some sites. C
- 24 **Lacrimal fold.** Plica lacrimalis. Mucosal fold at the opening of the nasolacrimal duct. It is located in the inferior nasal meatus about 3–3.5 cm posterior to the external naris. C



A Eyelids, sagittal section

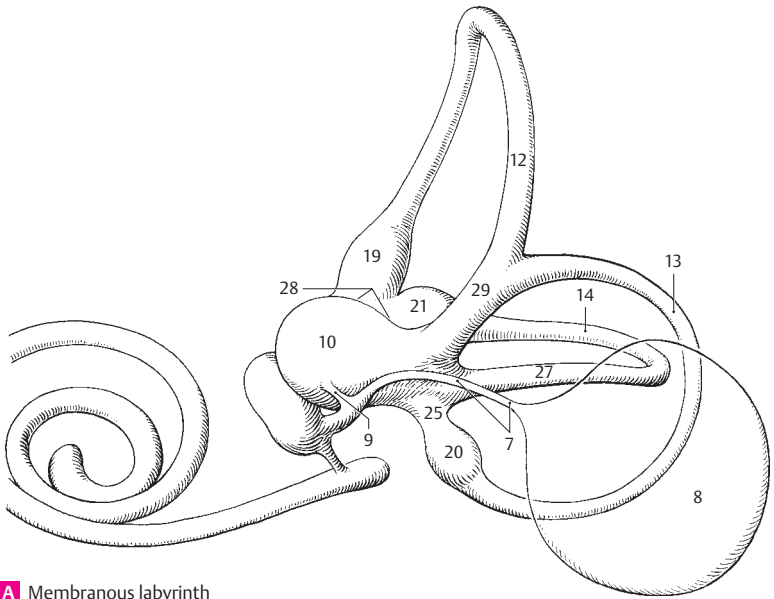


B Lacrimal gland

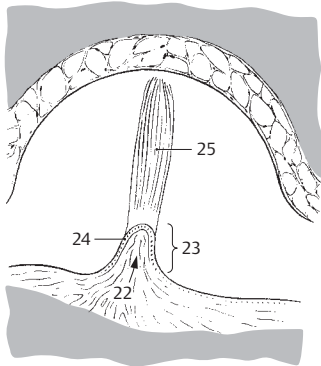


C Lacrimal system

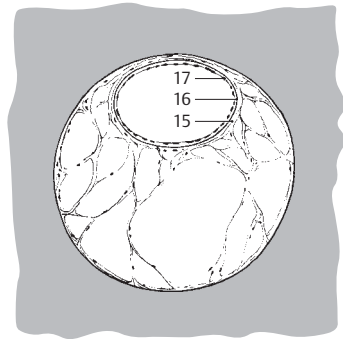
- 1 **VESTIBULOCOCHLEAR ORGAN.** Organum vestibulocochleare. Sensory apparatus housed in the temporal bone for the perception of sound, equilibrium and positional changes.
- 2 **INTERNAL EAR.** Auris interna. Part of the vestibulocochlear organ residing in the petrous temporal bone.
- 3 **MEMBRANOUS LABYRINTH.** Labyrinthus membranaceus. Complicated system of ducts and dilations within the bony labyrinth, which contains sensory epithelium and is suspended by connective tissue. A
- 4 **Endolymph.** Fluid contained within the membranous labyrinth.
- 5 **Perilymph.** Fluid occupying the osseous labyrinth and surrounding the membranous labyrinth.
- 6 **Vestibular labyrinth.** Labyrinthus vestibularis. Portion of membranous labyrinth constituting the organ of equilibrium. It includes the semicircular ducts.
- 7 **Endolymphatic duct.** Ductus endolymphaticus [[aquaeductus vestibuli]]. Slender duct arising from the utriculosaccular duct and passing through the osseous aqueduct of the vestibule to terminate as the endolymphatic sac. A
- 8 **Endolymphatic sac.** Saccus endolymphaticus. Blind sac of endolymphatic duct located between two dural layers at the posterior wall of the petrous temporal. A
- 9 **Utriculosaccular duct.** Ductus utriculosaccularis. Slender duct between the saccule and utricle. It gives rise to the endolymphatic duct. A
- 10 **Utricle.** Utriculus. Sac 2.5–3.5 mm in diameter, serving as the base for the three semicircular ducts. A
- 11 **Semicircular duct.** Ductus semicircularis. Three membranous ducts that resemble two-thirds of a circular arch, each occupying its own osseous semicircular canal oriented perpendicular to the others.
- 12 **Anterior (superior) semicircular duct.** Ductus semicircularis anterior. It is oriented vertically and somewhat perpendicular to the petrous part of the temporal bone. A
- 13 **Posterior semicircular duct.** Ductus semicircularis posterior. It is oriented somewhat vertically in a plane which runs parallel to the longitudinal axis of the petrous part of the temporal bone. A
- 14 **Lateral semicircular duct.** Ductus semicircularis lateralis. The most lateral, horizontally oriented semicircular duct. It may create a bulge in the medial wall of the tympanic cavity. A
- 15 **Proper membrane of semicircular duct.** Membrana propria ductus semicircularis. Layer below the basal membrane consisting primarily of densely packed fibers which extends into the looser network of the perilymphatic space. C
- 16 **Basal membrane of semicircular duct.** Membrana basalis ductus semicircularis. Appears upon light microscopy as a homogeneous basal membrane situated directly below the epithelium. C
- 17 **[[Epithelium of semicircular duct]].** [[Epithelium ductus semicircularis]]. Simple epithelium lining the inner aspect of the membranous semicircular duct. The cells are flat and become cuboidal on their concave side. C
- 18 **Membranous ampullae.** Ampullae membranaceae. Dilatations of the semicircular ducts in the vicinity of the utricle.
- 19 **Anterior membranous ampulla.** Ampulla membranacea anterior. Dilatation at the end of anterior (superior) semicircular duct located near the lateral membranous ampulla. A
- 20 **Posterior membranous ampulla.** Ampulla membranacea posterior. Dilatation at the end of the posterior semicircular duct located distal to the other two membranous ampullae. A
- 21 **Lateral membranous ampulla.** Ampulla membranacea lateralis. Ampulla of the lateral semicircular duct located proximal to the anterior membranous ampulla. A
- 22 **Sulcus ampullaris.** Indentation below the ampullary crest bearing branches from the ampullary nerve for innervation of the ampullary crest. B
- 23 **Ampullary crest.** Crista ampullaris. Crescent-shaped ridge projecting into the ampullary space. It is covered by sensory epithelium and has a base of nerve fibers and connective tissue. B
- 24 **[[Neuroepithelium]].** Sensory epithelium of ampullae consisting of supporting cells and sensory cells with hairs (microvilli) projecting from the surface into an overlying cupula. B
- 25 **Cupula.** Gelatinous body suspended above the ampullary crest as far as the roof of the ampulla and penetrated by hairs of the sensory cells. B
- 26 **Membranous crura.** Crura membranacea. Limbs of semicircular ducts opening into the utricle.
- 27 **Simple membranous crus.** Crus membranaceum simplex. Posterior limb of lateral semicircular duct opening independently into the utricle. A
- 28 **Ampullary membranous crura.** Crura membranacea ampullaria. Semicircular duct segments situated between the ampullae and the utricle. A
- 29 **Common membranous crus.** Crus membranaceum commune. Common limb formed by the anterior and posterior semicircular ducts and opening into the utricle. A



A Membranous labyrinth

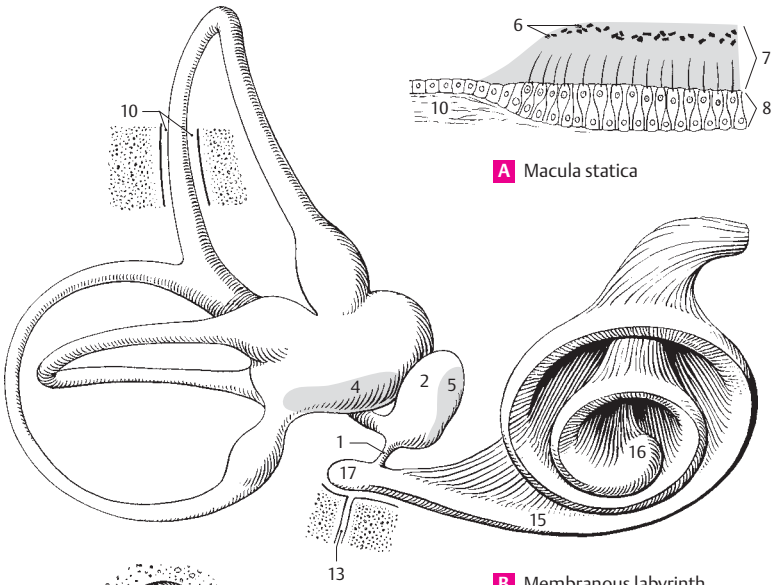


B Ampulla of semicircular duct



C Semicircular duct, cross section

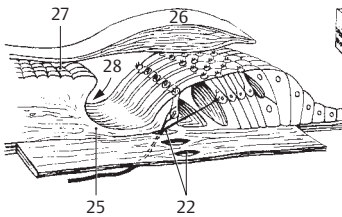
- 1 **Ductus reuniens.** Fine tube connecting the sacculus with the cochlear duct. B
- 2 **Sacculus.** Sacculus. Round vesicle, 2–3 mm in size, equipped with a sensory field. B
- 3 **Maculae** [[staticae]]. Sensory fields for the perception of the position of the head in space. A B
- 4 **Utricular macula.** Macula utricularis. Horizontally oriented sensory field, 2.3–3 mm in size, occupying the floor of the utricle. B
- 5 **Saccular macula.** Macula sacculi. Vertically oriented, arched sensory field, about 1.5 mm wide; in the medial wall of the sacculus. B
- 6 **Statoconia.** Calcium concretions, up to 15 µm in size, embedded in a gelatinous substance together with the sensory hairs. A
- 7 **Statoconial membrane.** Membrana statoconiorum. Membrane covering the maculae and consisting of a gelatinous ground substance with statoconia on its surface. It is penetrated by bristle-like processes from underlying macular sensory cells. A
- 8 **[[Neuroepithelium]].** Pseudostratified, prismatic, sensory epithelium of the macula consisting of supporting and sensory cells. The sensory cells bear 20–25 µm long bristle-like processes which project into the statoconial membrane. A
- 9 **Cochlear labyrinth.** Labyrinthus cochlearis. Complex contents of the osseous cochlea. C
- 10 **Perilymphatic space.** Spatium perilymphaticum. Space occupied by perilymph and partially permeated by connective tissue fibers. It includes the scala vestibuli and tympani. A B
- 11 **Scala vestibuli.** Perilymphatic canal located above the osseous spiral lamina and cochlear duct. It ascends as far as the apex of the cochlea (helicotrema). C
- 12 **Scala tympani.** Perilymphatic canal below the osseous spiral lamina and basilar membrane. C
- 13 **Cochlear aqueduct (perilymphatic duct).** Aquaeductus cochleae. Pathway connecting the perilymphatic space with the subarachnoid space. B
- 14 **External aperture of perilymphatic duct.** Apertura externa aquaeductus cochleae. Opening for the tympanic nerve in the vicinity of the canaliculus. See p. 14.22
- 15 **Cochlear duct.** Ductus cochlearis. A spiral endolymphatic tube taking $2\frac{1}{2}$ – $2\frac{3}{4}$ turns around a bony axis (modiolus) before ending blindly at the apex of the cochlea. It houses the sensory epithelium for the perception of sound. B C E
- 16 **Cupular caecum.** Caecum cupulare. Blind end of cochlear duct located at the apex of the cochlea. B
- 17 **Vestibular caecum.** Caecum vestibulare. Blind end of the cochlear duct facing the vestibule. B
- 18 **Tympanic wall of cochlear duct (spiral membrane).** Paries tympanicus ductus cochlearis (membrana spiralis). Inferior wall of cochlear duct situated above the scala tympani. E
- 19 **Spiral organ (of Corti).** Organum spirale [[Corti]]. Sensory field on the basilar membrane that transforms sound waves into nerve impulses. D
- 20 **Basilar membrane.** Lamina basilaris. Plate of connective tissue between the cochlear duct and scala tympani. It extends between the tympanic lip of the osseous spiral lamina and the spiral crest. E
- 21 **Spiral crest (ligament).** Crista spiralis (lig. spirale). Spirally arranged system of fibers arising from the periosteum of the cochlear canal and radiating into the basilar lamina. E
- 22 **Nerve foramina.** Foramina nervosa. Holes in the basilar lamina for transmission of cochlear nerve fibers from the hair cells to the spiral ganglion. D
- 23 **Limbus of osseous spiral lamina.** Limbus laminae spiralis osseae. Thickening and transformation of the endosteum on the upper layer of the osseous spiral lamina indented externally by the internal spiral sulcus. E
- 24 **Vestibular lip of limb of osseous spiral lamina.** Labium limbi vestibulare. Upper, shorter process of the limbus. Site of attachment of the tectorial membrane. E
- 25 **Tympanic lip of limb of osseous spiral lamina.** Labium limbi tympanicum. Lower, longer process of the limbus lying on the basilar membrane. D E
- 26 **Tectorial membrane.** Membrana tectoria. Fibrous membrane resting on the organ of Corti. It is narrow at the site where it attaches to the vestibular lip and ends freely beyond the row of outer hair cells. D E
- 27 **Auditory teeth.** Dentes acustici. The ridge-like rows of cells on the surface of the vestibular lip. The tectorial membrane attaches near here. D
- 28 **Internal spiral sulcus.** Sulcus spiralis internus. Groove between the vestibular and tympanic lips. D E
- 29 **External spiral sulcus.** Sulcus spiralis externus. Groove on the outer wall of the cochlear duct between the spiral prominence and the spiral organ. E



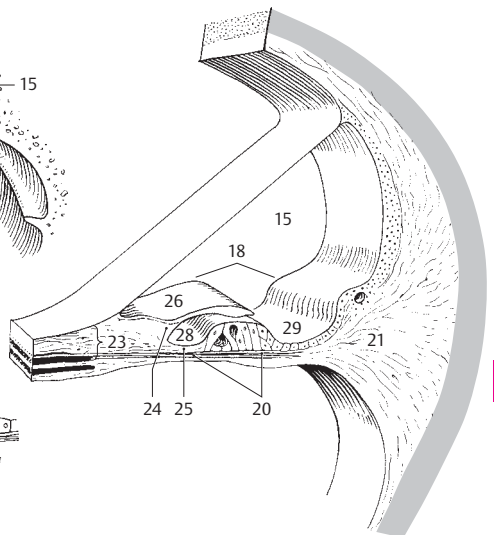
A Macula statica

B Membranous labyrinth

C Cochlea, opened

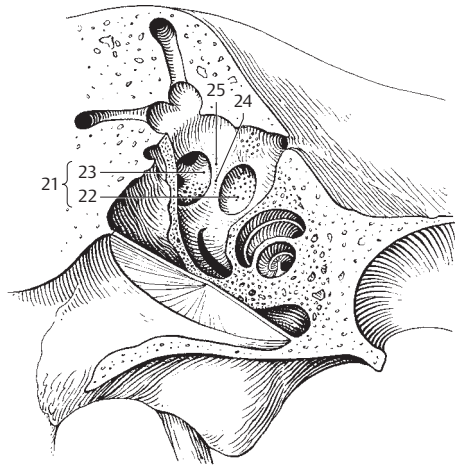
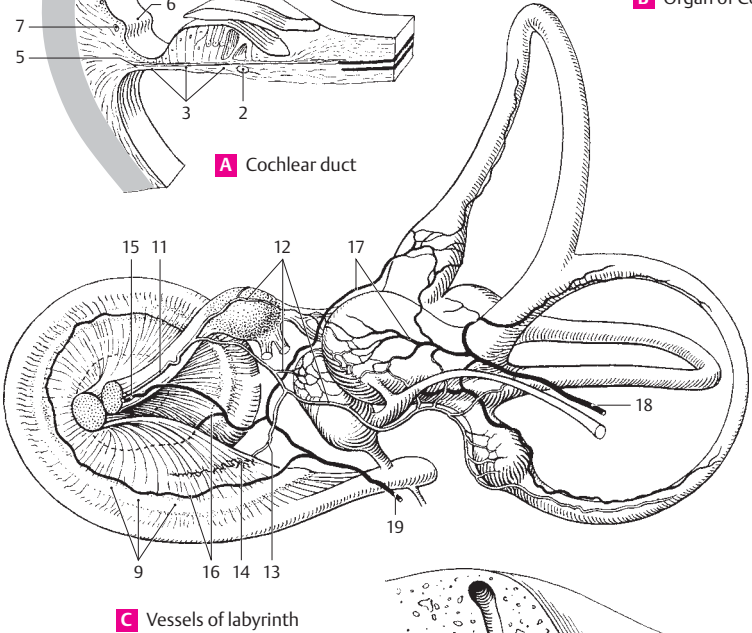
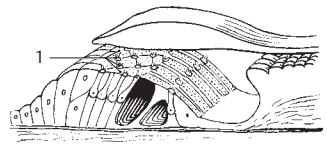
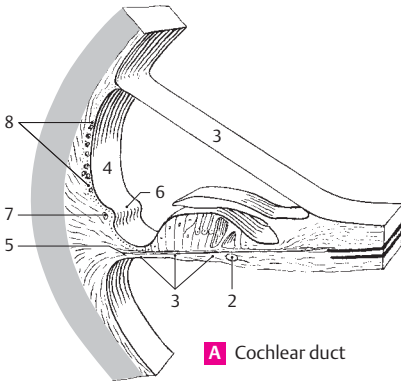


D Organ of Corti

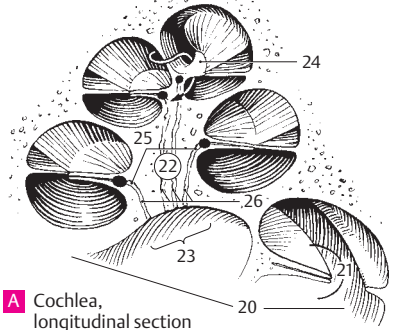


E Cochlear duct

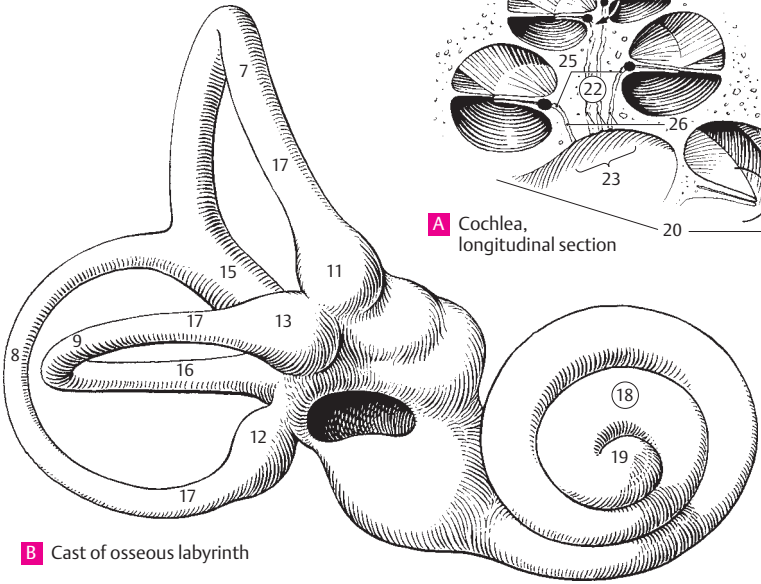
- 1 **Reticular membrane.** Membrana reticularis. Membrane covering the organ of Corti, formed by the heads of pillar/Deiters' cells. The microvilli of hair cells emerge through the gaps. B
- 2 **Spiral vessel.** Vas spirale. Small blood vessel below the tunnel, in the tympanic layer of the basilar membrane. A
- 3 **Vestibular wall of cochlear duct (vestibular [[Reissner's]] membrane).** Parietes vestibularis ductus cochlearis (membrana vestibularis) [[Reissner]]. Upper wall of the cochlear duct. It is about 3 μm thick. A
- 4 **External wall of cochlear duct.** Parietes externus ductus cochlearis. Lateral wall. A
- 5 **Basilar crest.** Crista basilaris. Pointed edge of the spiral crest that joins the basilar membrane. A
- 6 **Spiral prominence.** Prominentia spiralis. Marginal ridge projecting above the external spiral sulcus. It consists of connective tissue and contains a blood vessel. A
- 7 **Vas prominens.** The blood vessel in the spiral prominence. A
- 8 **Stria vascularis.** Broad, specialized band of highly vascularized stratified squamous epithelium above the spiral prominence. It is thought to secrete endolymph. A
- 9 **Spiral ganglion of cochlea.** Ganglion spirale cochlearis. Accumulation of bipolar ganglion cells in the spiral canal of the modioli. The afferent, peripheral fibers of these cells arise from the hair cells; the central, efferent fibers form the cochlear branch of the vestibulo-cochlear nerve. C
- 10 **Vessels of inner ear.** Vasa auris internae. C
- 11 **Labyrinthine artery.** A. labyrinthina. It arises from the basilar artery in front of the anterior inferior cerebellar artery, passes through the internal acoustic meatus with the vestibulo-cochlear nerve and enters the petrous part of the temporal bone, where it ramifies and supplies the inner ear. C
- 12 **Vestibular branches.** Rami vestibulares. Branches supplying the ampullae, maculae semicircular ducts and the lower third of the basal turn of the cochlea. C
- 13 **Cochlear branch.** Ramus cochlearis. It passes into the modioli where it supplies the spiral ganglion and the cochlear duct except for the lower third of the basal turn of the cochlea. C
- 14 **Arterial glomeruli of cochlea.** Glomeruli arteriosi cochleae. Spirally oriented arterial network accompanying the spiral vein. C
- 15 **Labyrinthine veins.** Vv. labyrinthinae. Companion veins of the labyrinthine artery. They pass through the internal acoustic meatus and open either into the inferior petrosal sinus or directly into the internal jugular vein. C
- 16 **Spiral vein of modioli.** V. spiralis modioli. It takes a spiral course in the modioli and empties into the labyrinthine vein. C
- 17 **Vestibular veins.** Vv. vestibulares. They arise from the semicircular ducts in the region of the utricle and saccule and drain partly into a labyrinthine vein, partly into the vein of the vestibular aqueduct. C
- 18 **Vein of vestibular aqueduct.** V. aqueductus vestibuli. Companion vein of endolymphatic duct. It opens into the inferior petrosal sinus. C
- 19 **Vein of cochlear aqueduct.** V. aqueductus cochleae. Companion vein of perilymphatic duct. It carries blood from the basal turn of the cochlea through the cochlear canaliculus. C
- 20 **OSSEOUS LABYRINTH.** Labyrinthus osseus. Bony capsule enclosing the membranous labyrinth. D
- 21 **Vestibule.** Vestibulum. Part of osseous labyrinth enclosing the utricle and saccule. D
- 22 **Spherical recess of vestibule.** Recessus sphericus. Rounded recess in the medial wall of the vestibule. It is occupied by the saccule. D
- 23 **Elliptical recess of vestibule.** Recessus ellipticus. Oval depression in the medial wall of the vestibule. It is occupied by the portion of the utricle between the posterior ampulla and common crus. D
- 24 **Crest of vestibule.** Crista vestibuli. Ridge between the spherical and elliptical recesses. D
- 25 **Pyramid of vestibule.** Pyramis vestibuli. Upper broadened part of the crest of the vestibule. D



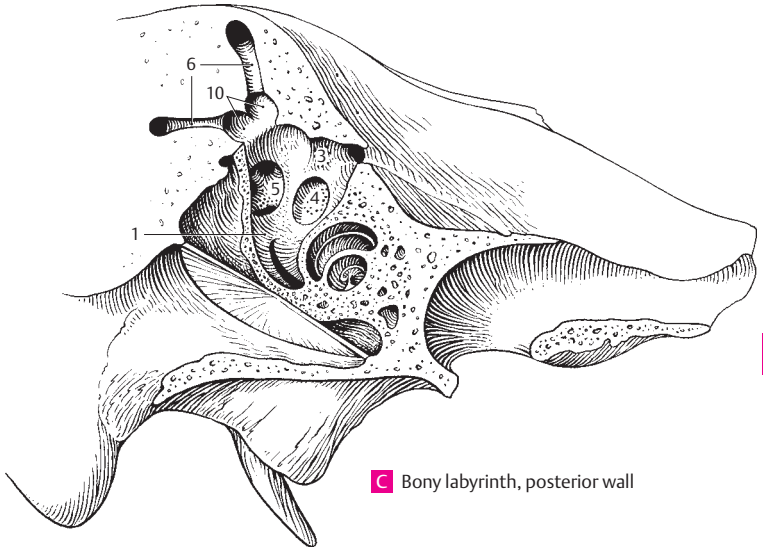
- 1 **Cochlear recess.** Recessus cochlearis. Depression lying below and in front of the spherical recess. It is occupied by the lower end of the cochlear duct. C
- 2 **Maculae cribrosae.** Perforated bony areas transmitting fibers of the vestibulocochlear nerve.
- 3 **Macula cribrosa superior.** Perforated bony area transmitting fibers of the utriculoampullar nerve. C
- 4 **Macula cribrosa media.** Perforated bony area near the base of the cochlea for passage of fibers of the saccular nerve. C
- 5 **Macula cribrosa inferior.** Perforated bony area in the wall of the posterior osseous ampulla for passage of fibers of the posterior ampullar nerve. C
- 6 **Osseous semicircular canals.** Canales semicirculares ossei. Bony canals containing perilymph and enclosing the membranous semicircular ducts (filled with endolymph). C
- 7 **Anterior (superior) semicircular canal.** Canalis semicircularis anterior. Canal sharing a common crus with the posterior semicircular canal and oriented vertically, somewhat perpendicular to the axis of the petrous part of the temporal bone. B
- 8 **Posterior semicircular canal.** Canalis semicircularis posterior. Posterior and most inferior semicircular canal. It lies somewhat parallel to the axis of the petrous part of the temporal bone. B
- 9 **Lateral semicircular canal.** Canalis semicircularis lateralis. Horizontally oriented canal that sometimes creates a bulge in the medial wall of the tympanic cavity. B
- 10 **Osseous ampullae.** Ampullae osseae. Dilatations close to the base of the semicircular crura. They lodge the membranous ampullae. C
- 11 **Anterior osseous ampulla.** Ampulla ossea anterior. Ampulla of the anterior semicircular canal located proximal to the ampulla of the lateral semicircular canal. B
- 12 **Posterior osseous ampulla.** Ampulla ossea posterior. Ampulla of the posterior semicircular canal. It lies below the plane of the lateral semicircular canal. B
- 13 **Lateral osseous ampulla.** Ampulla ossea lateralis. Ampulla of lateral semicircular canal. It lies near the anterior semicircular ampulla. B
- 14 **Crura ossea.** Osseous crura of the semicircular canals.
- 15 **Common osseous crus.** Crus osseum commune. Posteriorly situated common limb formed by the union of the crura of the superior and posterior semicircular canals. B
- 16 **Simple osseous crus.** Crus osseum simplex. Posteriorly situated crus of the lateral semicircular canal opening independently into the wall of the vestibule. B
- 17 **Ampullary osseous crura.** Crura ossea ampullaria. Crura of the semicircular canals dilated for accommodation of the ampullae of the membranous labyrinth. B
- 18 **Cochlea.** It makes $2\frac{1}{2}$ – $2\frac{3}{4}$ turns, measures 8–9 mm at its base and is altogether 4–5 mm high. B
- 19 **Apex of cochlea.** Cupula cochleae. Anteroinferiorly and laterally directed structure within the cranium. B
- 20 **Base of cochlea.** Basis cochleae. Structure with a surface pointing approx. in the direction of the internal acoustic meatus. A
- 21 **Spiral canal of cochlea.** Canalis spiralis cochleae. It is partitioned into three canals by the osseous spiral lamina and the basilar membrane on one side and the vestibular wall of the cochlear duct on the other. A
- 22 **Modiolus.** Conical axis of the cochlea. It is hollowed out for accommodation of the cochlear nerve and forms the medial wall of the spiral canal. A
- 23 **Base of modiolus.** Basis modioli. Beginning of the cochlear axis. A
- 24 **Lamina of modiolus.** Lamina modioli. Bony plate extending upward as a continuation of the bony spiral lamina. A
- 25 **Spiral canal of modiolus.** Canalis spiralis modioli. Fine channel in the axial wall near the base of the bony spiral lamina. It contains the spiral ganglion. A
- 26 **Longitudinal canals of modiolus.** Canales longitudinales modioli. Centrally located bony channels containing fibers of the cochlear nerve leaving the spiral ganglion. A



A Cochlea, longitudinal section

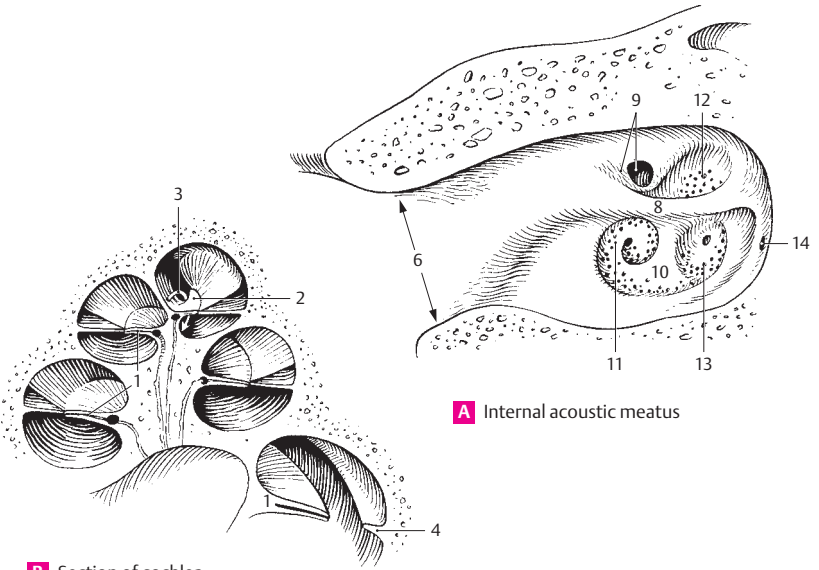


B Cast of osseous labyrinth



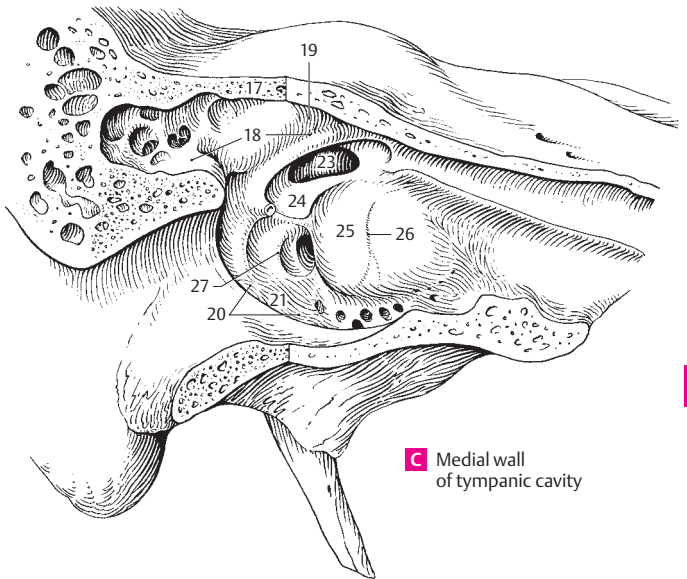
C Bony labyrinth, posterior wall

- 1 **Bony spiral lamina.** Lamina spiralis ossea. Bilayered bony plate projecting from the modiolus into the spiral canal of the cochlea in a spiral fashion. Together with the cochlear duct to which it is attached, it forms a complete partition between the scala vestibuli and scala tympani. B
- 2 **Hook of spiral lamina.** Hamulus laminae spiralis. Free hook-shaped upper end of the osseous spiral lamina at the apex of the cochlea. B
- 3 **Helicotrema.** Confluence between scala vestibuli and scala tympani at the apex of the cochlea. It exists because the bony spiral lamina and the cochlear duct end before reaching the apex of the cochlea. B
- 4 **Secondary spiral lamina.** Lamina spiralis secundaria. Bony ridge situated in the lower half of the basal turn. It projects from the outer wall of the spiral canal across from the bony spiral lamina. The inferior part of the basilar membrane extends between these two spiral laminae. B
- 5 **Internal acoustic (auditory) meatus.** Meatus acusticus internus. Arises near the posterior wall of the petrous part of the temporal bone. It is about 1 cm long and transmits the vestibulocochlear and facial nerves and the labyrinthine artery and vein. A
- 6 **Porus acusticus.** Outer opening of internal acoustic meatus into the posterior wall of the petrous part of the temporal bone above the jugular foramen. A
- 7 **Fundus of internal auditory meatus.** Fundus meatus acustici interni. Floor of meatus, which is subdivided into several fields. A
- 8 **Transverse crest.** Crista transversa. Transversely oriented ridge dividing the fundus of the internal acoustic meatus into an upper and lower part. A
- 9 **Facial nerve area.** Area nervi facialis. Region containing the beginning of the facial nerve canal. A
- 10 **Cochlear area.** Area cochleae. Large region below the transverse crest. It contains the foraminous spiral tract. A
- 11 **Foraminous spiral tract.** Tractus spiralis foraminosus. Area perforated by fibers of the spiral ganglion forming the cochlear part of the vestibulocochlear nerve. It corresponds to the spiral canal of the cochlea. A
- 12 **Superior vestibular area.** Area vestibularis superior. Region lateral to the facial canal and perforated by fibers of the utriculo-ampullar nerve. A
- 13 **Inferior vestibular area.** Area vestibularis inferior. Region located lateral to foraminous spiral tract and perforated by fibers of the saccular nerve. A
- 14 **Small opening for the posterior ampullar nerve.** Foramen singulare. It lies behind the inferior vestibular area. A
- 15 **MIDDLE EAR.** Auris media. Part of the ear comprising the tympanic (middle ear) cavity, auditory tube and mastoid cells.
- 16 **Tympanic cavity.** Cavitas tympanica (cavum tympani). Obliquely oriented space medial to the tympanic membrane (eardrum). It contains the auditory ossicles and communicates posteriorly with the mastoid air cells and anteriorly with the nasopharyngeal cavity via the auditory tube.
- 17 **Tegmental wall (tegen tympani).** Paries tegmentalis. Thin roof of the tympanic cavity. It lies lateral to the arcuate eminence of the petrous part of the temporal bone. C
- 18 **Epitympanic recess (attic).** Recessus epitympanicus. Dome of tympanic cavity located above the upper margin of the tympanic membrane and arching superiorly and laterally. C
- 19 **Cupular part.** Pars cupularis. Upper portion of epitympanic recess. C
- 20 **Jugular wall.** Paries jugularis. Floor of the tympanic cavity facing the jugular fossa. C
- 21 **Styloid prominence.** Prominentia styloidea. Elevation on the floor of the tympanic cavity produced by the styloid process. C
- 22 **Labyrinthine wall.** Paries labyrinthicus. Medial wall of tympanic cavity. C
- 23 **Oval window.** Fenestra vestibuli [[ovalis]]. It is closed by the base of the stapes. C
- 24 **Fossula fenestrae vestibuli.** Small depression in medial wall of tympanic cavity between the malleus and incus. C
- 25 **Promontory.** Promontorium. Prominence caused by the basal turn of the cochlea. C
- 26 **Sulcus promontorii.** Groove on the promontory produced by the tympanic nerve from the tympanic plexus. C
- 27 **Subiculum promontorii.** Small bony ridge behind the promontory and round window. C



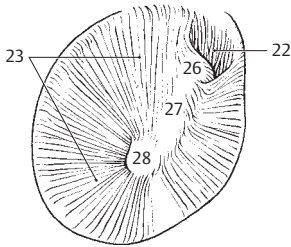
A Internal acoustic meatus

B Section of cochlea

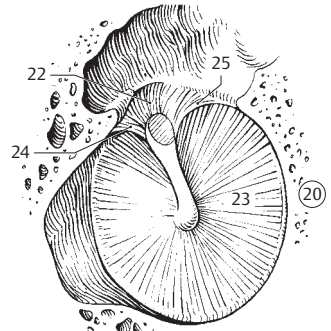


C Medial wall of tympanic cavity

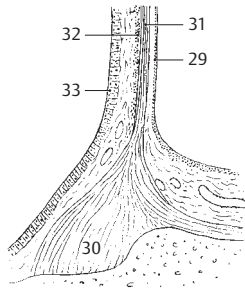
- 1 **Tympanic sinus.** Sinus tympani. Deep fossa behind the promontory and round window. D
- 2 **Round window (fenestra of cochlea).** Fenestra cochleae [[rotunda]]. Round opening at the end of the scala tympani. It is closed by the secondary tympanic membrane. D
- 3 **Fossula of round window.** Fossula fenestrae cochleae. Small fossa leading into the round window. D
- 4 **Crest of round window.** Crista fenestrae cochleae. Bony ridge along the edge of the round window for attachment of the secondary tympanic membrane. D
- 5 **Cochleariform process.** Processus cochleariformis. Spoon-shaped bony process found above the promontory at the end of the semicircular for the tensor tympani muscle. In combination with a connective tissue loop, it serves as a pulley for the muscle. D
- 6 **Secondary tympanic membrane.** Membrana tympani secundaria. Sheath across the round window that forms a membranous partition between the scala tympani and the tympanic cavity.
- 7 **Mastoid wall.** Paries mastoideus [adnexa mastoidea]. Components connected with the mastoid process.
- 8 **Mastoid (posterior) wall.** Paries mastoideus. Posterior wall of middle ear cavity facing the mastoid process. D
- 9 **Mastoid antrum.** Antrum mastoideum. Closed space, the posterosuperior part of which is continuous with the tympanic cavity. The inferior edge communicates with the mastoid cells. D
- 10 **Aditus ad antrum.** Entrance to the mastoid antrum from the tympanic cavity. D
- 11 **Prominentia canalis semicircularis lateralis.** Prominence on the wall of lateral semicircular canal, situated above the prominence of the facial canal. D
- 12 **Prominence of facial nerve canal.** Prominentia canalis facialis. Bulge lying between the oval window and prominence of the lateral semicircular canal. D
- 13 **Pyramidal eminence (pyramid).** Eminentia pyramidalis. Small, bony pyramidal projection at the level of the oval window. Its apex is perforated. The eminence contains the stapedius muscle, the tendon of which emerges from it. D
- 14 **Incudal fossa.** Fossa incudis. Small depression in the aditus ad antrum for the posterior ligament of the incus. D
- 15 **Sinus posterior.** Small groove between the incudal fossa and pyramid. D
- 16 **Tympanic aperture of canaliculus of chorda tympani.** Apertura tympanica canaliculi chordae tympani. Opening of chorda tympani canal into tympanic cavity. It lies at the posterior margin of the tympanic membrane at the level of the pyramid. D
- 17 **Mastoid air cells.** Cellulae mastoideae. Like the tympanic cavity, they are lined by squamous and/or cuboidal epithelium. D
- 18 **Tympanic cells.** Cellulae tympanicae. Small cell-like depressions in the floor of the tympanic cavity. D
- 19 **Carotid wall.** Paries caroticus. Anterior wall formed partly by the carotid canal, partly by the opening of the auditory tube. D
- 20 **Membranous wall.** Paries membranaceus. Lateral wall of tympanic cavity formed primarily by the tympanic membrane. B
- 21 **Tympanic membrane (eardrum).** Membrana tympanica. Obliquely oriented membrane at the end of the external acoustic meatus. Diameter: 9–11 mm. A B
- 22 **Pars flaccida** [[Shrapnell's membrane]]. Smaller, more flaccid part of tympanic membrane located above the anterior and posterior malleolar folds. A B
- 23 **Pars tensa.** By far, the largest part of the tympanic membrane, situated within the tympanic ring. A B
- 24 **Anterior malleolar fold (6).** Plica mallearis anterior. Fold on the inner surface of the tympanic membrane. It has a concave lower edge and extends anteriorly from the base of the manubrium of the malleus. B
- 25 **Posterior malleolar fold (6).** Plica mallearis posterior. Fold on the inner surface of the tympanic membrane. It has a concave lower edge and extends posteriorly from the root of the manubrium of the malleus. B
- 26 **Malleolar prominence.** Prominentia mallearis. Small elevation on the outside of the tympanic membrane caused by the lateral process of the malleus. A
- 27 **Stria mallearis.** A bright band that appears on the outer surface of the tympanic membrane due to the underlying manubrium of the malleus, which is fused with the tympanic membrane. A
- 28 **Umbo of tympanic membrane.** Umbo membranae tympani. Structure at the tip of the manubrium of the malleus, where the tympanic membrane is drawn inward. A
- 29 **Cutaneous layer.** Stratum cutaneum. The layer of stratified squamous epithelium on the external surface of the tympanic membrane. C
- 30 **Fibrocartilaginous ring.** Anulus fibrocartilagineus. Attaches the tympanic membrane in the tympanic sulcus. C
- 31 **Radiate layer.** Stratum radiatum. Outer group of radially oriented fibers of the tympanic membrane. C
- 32 **Circular layer.** Stratum circulare. Inner group of circularly oriented fibers of the tympanic membrane. C
- 33 **Mucosal layer.** Stratum mucosum. Layer of simple squamous epithelium covering the inner surface of the tympanic membrane. C



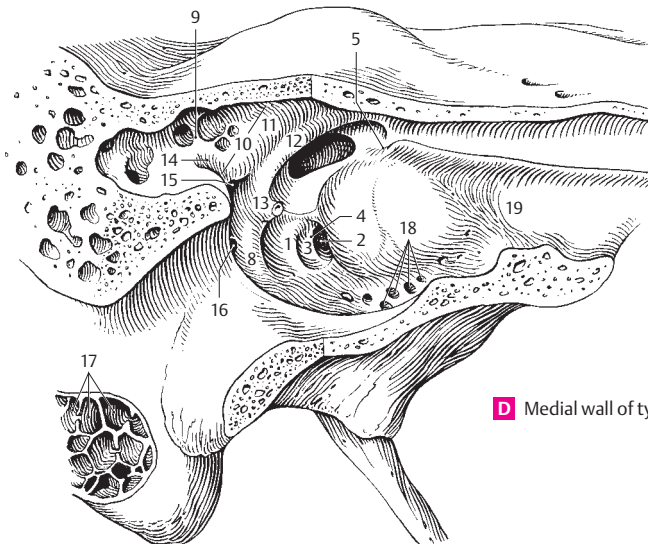
A Right eardrum, external view



B Lateral wall of tympanic cavity

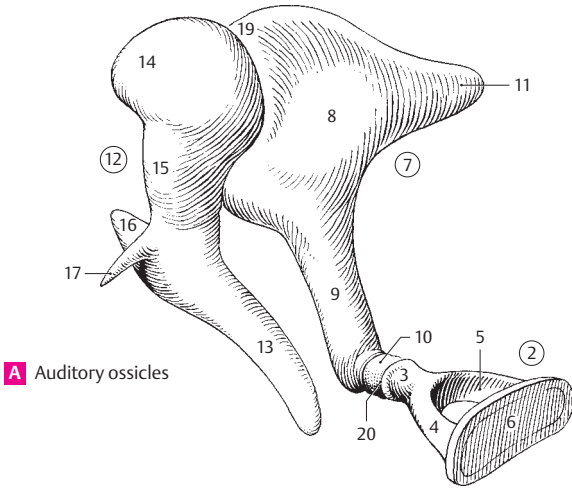


C Attachment of eardrum

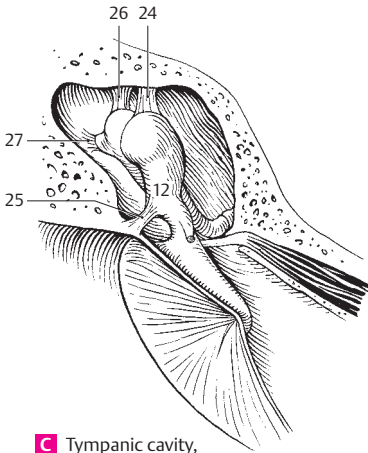


D Medial wall of tympanic cavity

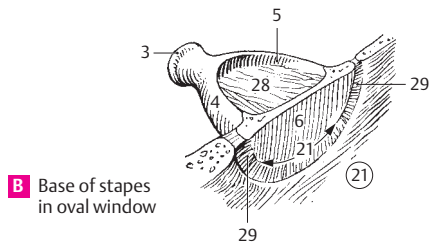
- 1 **Auditory ossicles (malleus, incus and stapes).** Ossicula auditoria (auditus). They operate collectively as a bent lever system transferring sound waves from the tympanic membrane to the inner ear.
- 2 **Stapes (stirrup).** A stirrup-shaped auditory ossicle. Its base is inserted into the fenestra vestibuli. A B
- 3 **Head of stapes.** Caput stapedis. It lies opposite the base of the stapes and articulates with the lenticular process of the incus. A B
- 4 **Anterior crus (limb.).** Crus anterior. The virtually straight anterior limb of the stapes. A B
- 5 **Posterior crus (limb.).** Crus posterior. The more curved posterior limb of the stapes. A B
- 6 **Base (footplate) of stapes.** Basis stapedis. The plate of bone inserts into the fenestra vestibuli (ovalis). A B
- 7 **Incus (anvil).** The central ossicle situated between the head of the malleus and the head of the stapes. A D
- 8 **Body of incus.** Corpus incudis. It articulates with the malleus by means of a saddle-shaped joint. A
- 9 **Long crus (limb.).** Crus longum. Long process which projects almost vertically downward behind the manubrium of the malleus with the lenticular process at its tip. A
- 10 **Lenticular process.** Processus lenticularis. Small bony projection on the tip of the long crus. It articulates with the stapes. A
- 11 **Short crus (limb).** Crus breve. Small posteriorly directed process attached to the incudal fossa by a ligament. A
- 12 **Malleus** [[hammer]]. It lies between the tympanic membrane and the incus. A C
- 13 **Handle (manubrium) of malleus.** Manubrium mallei. Its outer surface is fused to the tympanic membrane as far as the lateral process. A
- 14 **Head of malleus.** Caput mallei. It has a convex articular surface for accommodation of the body of the incus. A
- 15 **Neck of malleus.** Collum mallei. Structure connecting the head and manubrium of the malleus. A
- 16 **Lateral process of malleus.** Processus lateralis. Short process that projects from the end of the manubrium and produces the malleolar prominence. A
- 17 **Anterior process of malleus.** Processus anterior. Long, very thin process. It extends into the petrotympanic fissure in the newborn, but diminishes in the adult. A
- 18 **Articulations of auditory ossicles.** Articulationes ossiculorum auditoriorum. They are not true joints but syndesmoses.
- 19 **Incudomalleolar joint.** Articulatio incudomalleolaris. Joint between the incus and malleus. It occasionally exhibits an articular cavity. A
- 20 **Incudostapedial articulation.** Articulatio incudostapedialis. Union between the lenticular process of the long crus of the incus and the stapes. A
- 21 **Tympanostapedial syndesmosis.** Syndesmosis tympanostapedialis. Connective tissue attaching the base of the stapes to the oval window. It is broader anteriorly than posteriorly. B
- 22 **Ligaments of auditory ossicles.** Ligg. ossiculorum auditoriorum.
- 23 **Anterior ligament of malleus.** Lig. mallei anterior. Ligament that arises from the anterior process of the malleus, lies in the anterior malleolar fold and extends as far as the petrotympanic fissure. D
- 24 **Superior ligament of malleus.** Lig. mallei superior. It passes from the head of the malleus to the roof of the epitympanic recess. C D
- 25 **Lateral ligament of malleus.** Lig. mallei laterale. It unites the neck of the malleus with the upper margin of the tympanic notch. C
- 26 **Superior ligament of incus.** Lig. incudis superior. Courses approximately parallel to the superior ligament of the malleus and connects the body of the incus with the roof of the epitympanic recess. C D
- 27 **Posterior ligament of incus.** Lig. incudis posterior. It passes from the short limb of the incus to the lateral wall of the tympanic cavity. C D
- 28 **Stapedial membrane.** Membrana stapedialis. Thin membrane between the limbs and base of the stapes. B
- 29 **Anular ligament of stapes.** Lig. anulare stapediale. Ligament situated between the base of the stapes and the margin of the oval window. It is broader anteriorly than posteriorly. B



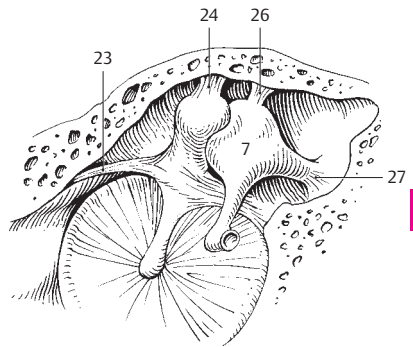
A Auditory ossicles



C Tympanic cavity, posterior half

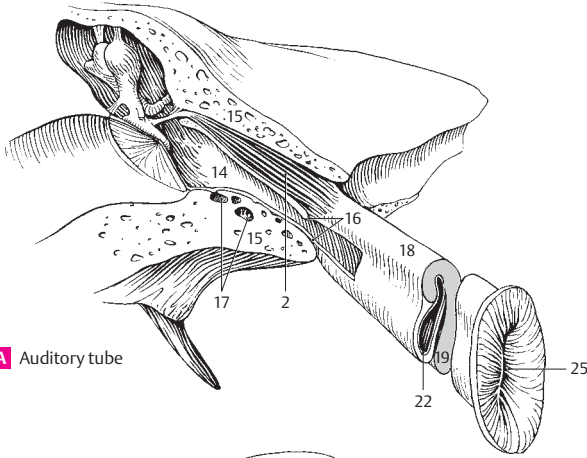


B Base of stapes in oval window

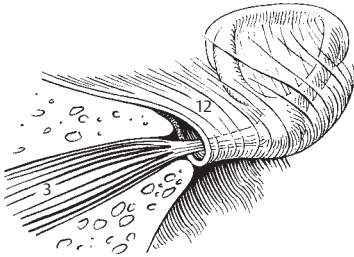


D Lateral wall of tympanic cavity

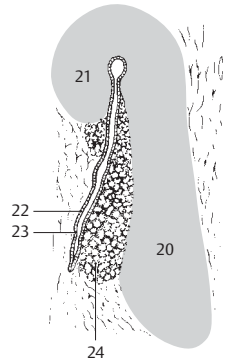
- 1 **Muscles of auditory ossicles.** Musculi ossiculorum auditoriorum. The following two muscles are attached to the ossicles.
- 2 **M. tensor tympani.** Muscle located in the semicanal for the tensor tympani muscle above the auditory tube. Its tendon bends laterally around the cochleariform process almost at a right angle and inserts at the base of the manubrium of the malleus. I: Mandibular nerve. A
- 3 **M. stapedius.** Muscle that originates in a bony canal on the posterior wall of the tympanic cavity. Its tendon passes through an opening at the apex of the pyramid before inserting at the head of the stapes. By tilting the stapes, it exerts a dampening effect on sound vibrations reaching the inner ear. I: Nerve to stapedius from the facial nerve. B
- 4 **Mucous membrane of tympanic cavity.** Tunica mucosa cavitatis tympanicae. It consists of simple squamous and/or cuboidal epithelium and a delicate vascular-rich lamina propria.
- 5 **Posterior malleolar fold.** Plica mallearis posterior. Fold extending from the base of the handle of the malleus to the posterior, upper part of the tympanic ring. It contains the posterior portion of the chorda tympani. D
- 6 **Anterior malleolar fold.** Plica mallearis anterior. Fold extending from the base of the manubrium to the anterior, upper part of the tympanic ring. It contains the anterior segment of the chorda tympani, the anterior process of the malleus and the anterior ligament of the malleus. D
- 7 **Fold of chorda tympani.** Plica chordae tympani. Fold created by the chorda tympani on the neck of the malleus between the two above-mentioned folds. D
- 7a **Recess of tympanic membrane.** Recessus membranæ tympanicae. Mucosal pouch in the tympanic cavity.
- 8 **Anterior recess of tympanic membrane.** Recessus [membranæ tympani] anterior. Mucosal pouch between the anterior malleolar fold and the tympanic membrane. D
- 9 **Superior recess of tympanic membrane (Prussak's pouch).** Recessus [membranæ tympani] superior. Recess bounded laterally by the flaccid part of the tympanic membrane, medially by the head and neck of the malleus and the body of the incus. D
- 10 **Posterior recess of tympanic membrane.** Recessus [membranæ tympani] posterior. Mucosal pouch between the posterior malleolar fold and tympanic membrane. D
- 11 **Incudal fold.** Plica incudialis. Mucosal fold extending from the roof of the epitympanic recess to the head of the incus or from the short limb of the incus to the posterior wall of the tympanic cavity. D
- 12 **Stapedial fold.** Plica stapedialis. Mucosal fold extending from the posterior wall of the tympanic cavity to the stapes. It covers the stapedius muscle and the stapes. B
- 13 **AUDITORY (PHARYNGOTYMPANIC, EUSTACHIAN) TUBE.** Tuba auditoria (auditiva). Narrow 4 cm long, partly cartilaginous, partly bony tube between the middle ear and the nasopharynx for aeration of the tympanic cavity. A C
- 14 **Tympanic ostium of auditory tube.** Ostium tympanicum tubae auditoriae. Opening of the auditory tube on the anterior wall of the tympanic cavity. It usually lies slightly above the floor of the tympanic cavity. A
- 15 **Osseous part of auditory tube.** Pars ossea tubae auditoriae. Laterally and posterosuperiorly situated portion that involves about 1/3 of the tube's length. It lies below the semicanal for the tensor tympani muscle and emerges between the carotid canal and the foramen spinosum. A
- 16 **Isthmus [tubae auditoriae].** Narrow portion of the tube between the cartilaginous and bony parts of the auditory tube. A
- 17 **Air cells.** Cellulae pneumaticae. Small fossae in the wall of the osseous part of the auditory tube. A
- 18 **Cartilaginous part of auditory tube.** Pars cartilaginea [tubae auditoriae]. Located anteromedially and has a length of about 2.5 cm. A
- 19 **Cartilage of auditory tube.** Cartilago tubae auditoriae. Hook-shaped in cross section. It becomes lower lateroposteriorly and contains elastic cartilage only in the angle between the two cartilaginous laminae. A
- 20 **Medial cartilaginous lamina.** Lamina (cartilaginosa) medialis. Broad plate of cartilage. C
- 21 **Lateral cartilaginous lamina.** Lamina (cartilaginosa) lateralis. Narrow anterolaterally directed plate of cartilage. C
- 22 **Membranous lamina.** Lamina membranacea. Membranous portion of the wall of the cartilaginous part of the auditory tube. A C
- 23 **Tunica mucosa.** Mucous membrane of auditory tube lined by a simple ciliated epithelium. C
- 24 **Glands of auditory tube.** Glandulae tubariae. Mucous glands especially in the cartilaginous part of the tube. C
- 25 **Pharyngeal opening of auditory tube.** Ostium pharyngeum tubae auditoriae. Funnel-shaped to slit-like opening above the levator eminence at the level of the inferior nasal meatus 1 cm lateral and anterior to the posterior wall of the pharynx. A



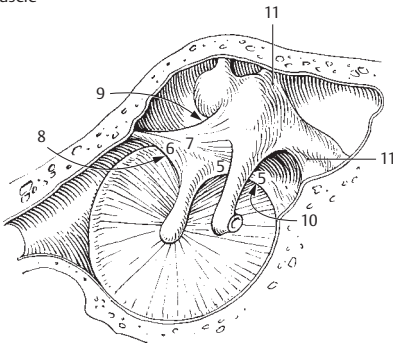
A Auditory tube



B Stapedius muscle

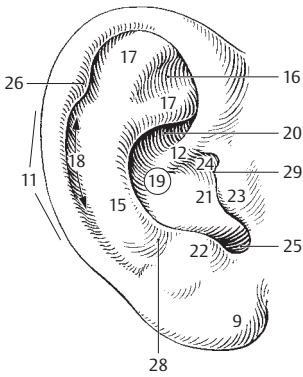


C Auditory tube, cross section

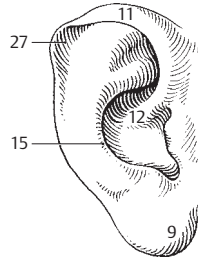


D Lateral wall of tympanic cavity

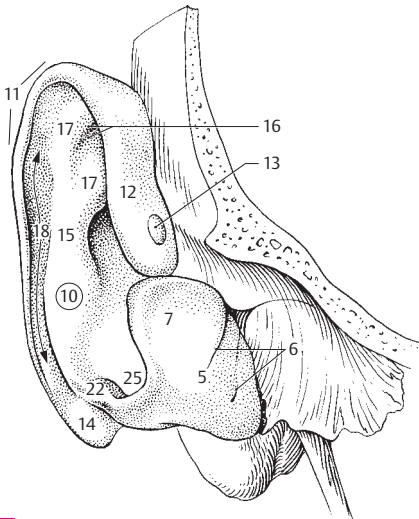
- 1 **EXTERNAL EAR.** Auris externa. The part of the ear consisting of the auricle (pinna) and external acoustic meatus.
- 2 **External acoustic (auditory) meatus (canal).** Meatus acusticus externus. Flat, partly cartilaginous, partly bony, S-shaped canal about 2.4 cm long with a diameter of about 6 mm. C
- 3 **External opening of acoustic canal.** Porus acusticus extrnus. C
- 3a **Tympanic notch.** Incisura tympanica. Defect between the greater and lesser tympanic spines. In the newborn, it is the superior gap between the still free ends of the tympanic ring. See p. 16.8
- 4 **Cartilaginous part of external acoustic meatus.** Meatus acusticus externus cartilagineus. Lateral, cartilaginous third of the external acoustic meatus. C
- 5 **Cartilage of external acoustic meatus.** Cartilago meatus acustici. Together with the cartilage of the pinna, it forms a groove that opens superiorly and posteriorly. D
- 6 **Incisurae cartilaginiae meatus acustici.** Two fissures in the cartilage of the external acoustic meatus. They are bridged by connective tissue and are usually directed anteriorly. D
- 7 **Lamina tragi.** Lateral part of the meatal cartilage. It lies in front of the external opening of the acoustic meatus. D
- 8 **Auricle (Pinna).** Auricula. A B
- 9 **Ear lobe.** Lobulus auricularis. Lower end of the pinna devoid of cartilage. A B C
- 10 **Auricular cartilage.** Cartilago auricularis. Structural framework of the pinna consisting of elastic cartilage. D
- 11 **Helix.** External, curved margin of the auricle. A B C D
- 12 **Crus of helix.** Crus heliciis. Site of origin of the helix in the cavity (concha) of the auricle. A B D
- 13 **Spine of helix.** Spina heliciis. Small, forward-projecting cartilaginous prominence on the crus helices. D
- 14 **Tail of helix.** Cauda heliciis. Posterior, inferior end of the helix separated from the antitragus by an indentation. D
- 15 **Anthelix** [[anhelix]]. Arched projection located in front of the posterior part of the helix. A B C D
- 16 **Triangular fossa.** Fossa triangularis. Anterosuperiorly located fossa enclosed by the two crura of the anhelix. A D
- 17 **Crura of anhelix (antihelix).** Crura anheliciis. Formed by the bifurcation of the anhelix superiorly, the two crura form the boundary of the triangular fossa. A D
- 18 **Scaphoid fossa.** Scapha. Narrow fossa situated posteriorly between the helix and anhelix. A D
- 19 **Concha (cavity) of auricle.** Concha auricularis. It is embraced by the anhelix, antitragus and tragus. A
- 20 **Cymba conchalis.** Upper, slit-like part of the concha between the crura of helix and anhelix. A
- 21 **Cavity of concha.** Cavitas (cavum) conchalis. Main part of the concha located below the crus of the helix and behind the tragus. A
- 22 **Antitragus.** Small tubercle present on the inferior continuation of the anhelix and separated from the tragus by the intertragic incisure. A D
- 23 **Tragus.** Flat projection in front of the external opening of the acoustic canal. A
- 24 **Anterior notch.** Incisura anterior (auris). It lies between the tragus (supratragic tubercle) and the crus of the helix. A
- 25 **Intertragic incisure.** Incisura intertragica. Notch between tragus and antitragus. A D
- 26 **Auricular** [[Darwin's]] **tubercle.** [Tuberculum auriculare]. It is occasionally present on the anterior margin of the helix from which it extends posteroinferiorly. A
- 27 **Apex of auricle.** [Apex auricularis]. Outer margin of the auricular cartilage (helix) which, when present, projects backward, upward and outward. B
- 28 **Posterior auricular sulcus.** Sulcus auricularis posterior. Shallow indentation between the antitragus and anhelix. A
- 29 **Supratragic tubercle.** [Tuberculum supratragicum]. Small tubercle occasionally present at the upper end of the tragus. A



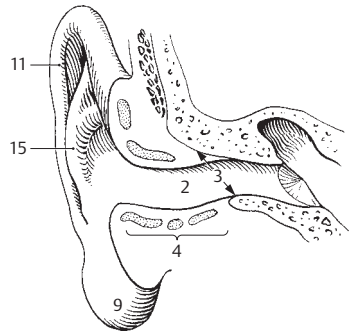
A Auricle (pinna)



B Auricle with apex

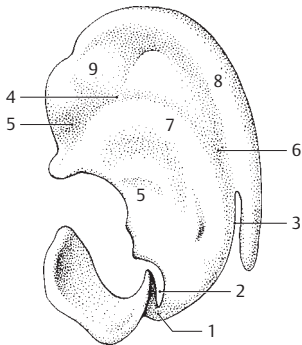


D Auricular cartilage frontal view

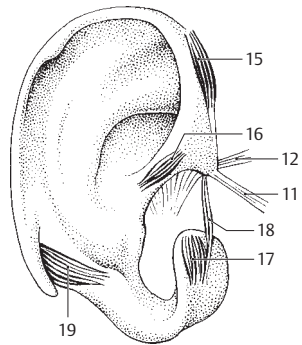


C External acoustic meatus

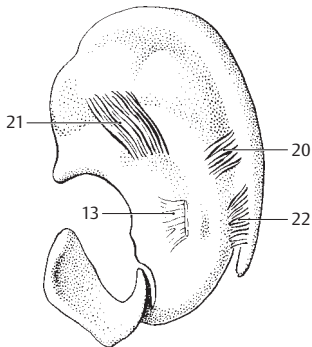
- 1 **Isthmus of auricular cartilage.** Isthmus cartilaginis auricularis. Narrow bridge of cartilage connecting the cartilage of the external acoustic meatus and tragic lamina with the auricular cartilage. A
- 2 **Terminal notch.** Incisura terminalis auricularis. Deep notch separating the lamina tragi from the auricular cartilage. A
- 3 **Fissura antitragohelicina.** Deep fissure separating the antitragus and helix inferiorly as well as the anthelix and helix further superiorly. A
- 4 **Transverse sulcus of anthelix.** [[Sulcus anthelicis transversus]]. Posteromedial depression visible between the eminences of the triangular fossa and concha. A
- 5 **Groove of crus of helix.** Sulcus cruris helicis. Shallow furrow on the posterior surface of the auricular cartilage. It corresponds to the crus of the helix on the anterior surface. A
- 6 **Fossa of anthelix.** Fossa anthelicis. Furrow on posterior surface of auricular cartilage corresponding to the anthelix on the anterior surface. A
- 7 **Eminence of concha.** Eminentia conchae. Elevation on the posterior surface of the auricular cartilage corresponding to the cavity of the concha. A
- 8 **Eminence of scaphoid fossa.** Eminentia scaphae. Curved elevation on the posterior surface of the auricular cartilage corresponding to the scaphoid fossa on the anterior surface. A
- 9 **Eminence of triangular fossa.** Eminentia fossae triangularis. Elevation on the posterior surface of the auricular cartilage corresponding to the triangular fossa. A
- 10 **Auricular ligaments.** Ligg. auricularia. Ligaments of the pinna. They attach the auricular cartilage to the temporal bone.
- 11 **Anterior auricular ligament.** Lig. auriculare anterius. It extends from the root of the zygomatic arch to the spine of the helix. B
- 12 **Superior auricular ligament.** Lig. auriculare superius. It passes from the upper margin of the osseous external auditory meatus to the spine of the helix. B
- 13 **Posterior auricular ligament.** Lig. auriculare posterius. It extends from the eminence of the concha to the mastoid process. C
- 14 **Mm. auriculares.** Muscles of the pinna.
- 15 **M. helicis major.** It passes upward from the spine of the helix to the helix. B
- 16 **M. helicis minor.** It lies on the crus of the helix. B
- 17 **M. tragicus.** It lies vertically on the lamina tragi. B
- 18 **M. pyramidalis auricularis.** Muscle fibers that occasionally split off from the tragicus muscle and pass to the spine of the helix. B
- 19 **M. antitragicus.** Muscle fibers on the antitragus. They extend partly to the tail of the helix. B
- 20 **M. transversus auricularis.** Muscle located on the posterior surface of the auricular cartilage. It extends between the eminences of the scaphoid fossa and concha. C
- 21 **M. obliquus auricularis.** It lies between the eminences of the concha and triangular fossa. C
- 22 **[M. incisurae helicis].** Muscle fibers occasionally present in the caudal continuation of transversus auricularis muscle. C
- 23 **OLFACTORY ORGAN.** Organum olfactorium (olfactus). Organ of smell.
- 24 **Nasal mucosa of the olfactory region.** Regio olfactoria tunicae mucosae nasi. This region, which is covered by olfactory epithelium, is about the size of a nickel and occupies the lateral and medial walls and roof (below the cribriform plate) of the nasal cavity at the level of the superior nasal concha. E F
- 25 **Olfactory glands (of Bowman).** Glandulae olfactoriae. Serous glands found below the olfactory epithelium. Their predominantly serous secretions can enhance or wash away odorous substances. F
- 26 **GUSTATORY ORGAN.** Organum gustatorium (Gustus). Organ of taste, comprised of all the taste buds.
- 27 **Taste bud.** Caliculus gustatorius (gemma gustatoria). Occupying the full thickness of the epithelium, it consists of supporting cells and taste cells. Each of the taste cells has microvilli on its surface which serve as chemoreceptors. Distribution of taste buds: aggregated in the epithelium of vallate (circumvallate) and foliate papillae; solitary on the outside of the tongue. D
- 28 **Taste pore.** Porus gustatorius. Space left by the epithelium above the apex of the taste bud. Microvilli project into it. D



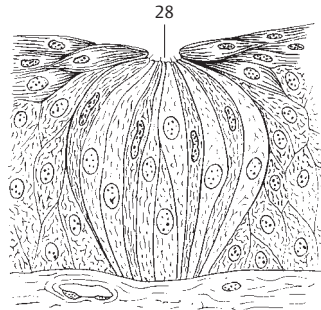
A Auricular cartilage, medial view



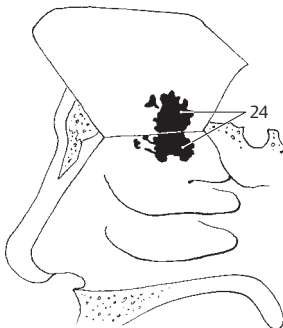
B Auricular cartilage, lateral view



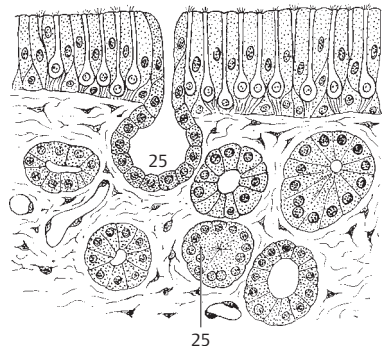
C Auricular cartilage, medial view



D Taste bud

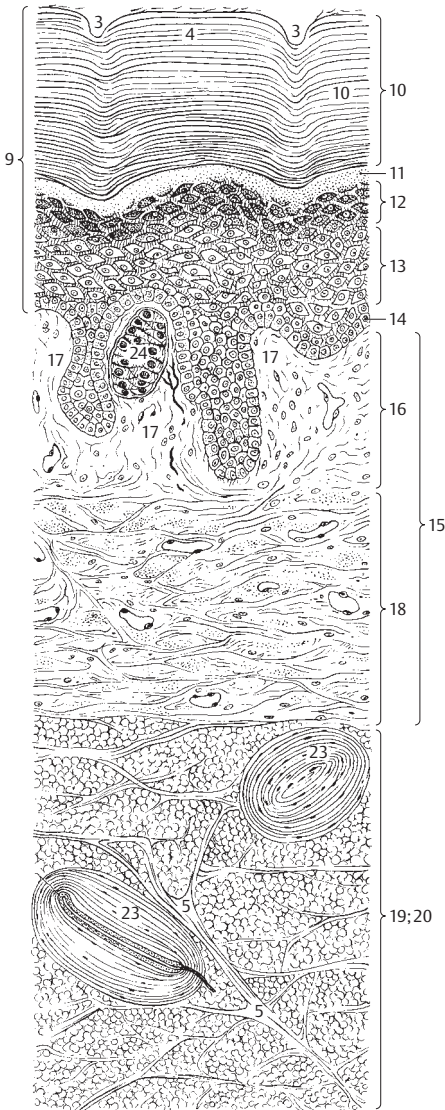


E Olfactory region

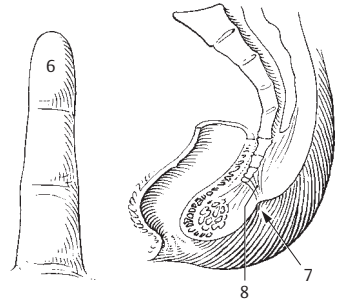


F Olfactory mucosa

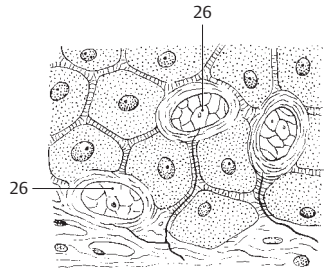
- 1 **SKIN (INTEGUMENT).** Integumentum commune. Common integument (skin). The outer covering of the body consisting of three layers, the epidermis, dermis (corium) and subcutis. In the adult it covers an area of about 1.8 square meters.
- 2 **Cutis.** Collective term for epidermis and dermis.
- 3 **Sulci of skin.** Sulci cutis. Variably sized depressions or furrows on the surface of the skin, e.g., the nasolabial sulcus, the deep sulci of the joints, the fine depressions on the smooth areas of the skin, and the dermal ridges on the palms and soles. A
- 4 **Dermal ridges.** Cristae cutis. Ridges produced by the underlying papillae of the corium on the thick skin of the palms of the hands and soles of the feet. A
- 5 **Retinacula cutis.** Bands of connective tissue which attach the skin to the underlying tissue. A
- 6 **Tactile elevations.** Toruli tactiles. Skin regions with more abundant fat deposits, e.g., near the phalanges, thenar and hypothenar eminences. B
- 7 **Coccygeal foveola.** [Foveola coccygea]. Pit above the coccyx caused by the caudal retinaculum. C
- 8 **Caudal retinaculum.** Retinaculum caudale. Connective tissue remains of the embryonic notochord lying between the coccygeal foveola and the coccyx. C
- 9 **Epidermis.** Stratified, keratinized squamous epithelium covering the body. Its thickness varies from 30 µm to 4 mm or more. A
- 10 **Stratum corneum.** Most superficial, cornified (keratinized) layer of the epidermis which undergoes continual desquamation. A
- 11 **Stratum lucidum.** Located between the stratum granulosum and stratum corneum. It is a homogeneous, strongly refractile layer rich in eleidin fibers. A
- 12 **Stratum granulosum.** It consists of 1–5 cell layers with degenerative nuclear changes. It contains strongly refractory keratohyaline granules. A
- 13 **Stratum spinosum.** Prickle cell layer. It consists of polygonal cells with spinous processes which project from their surfaces and contact each other by means of a desmosome. They appear to bridge over relatively large intercellular spaces (shrinkage artifact). A
- 14 **Stratum basale [cylindricum].** Deepest, cylindrical cell layer of the epidermis. Cell proliferation occurs here and in the stratum spinosum, thus ensuring the continual renewal of the epidermis. A
- 15 **Dermis (corium).** The layer of skin consisting of an intimate network of collagenous and elastic fibers rich in nerves and blood vessels and devoid of fat. A
- 16 **Papillary layer.** Stratum papillare. The delicate upper layer of the dermis with numerous connective tissue papillae connecting it to the epidermis. A
- 17 **Papillae.** Conical extensions of connective tissue projecting into the epidermis. They may form rows (dermal ridges) or branches and vary markedly in form and organization. A E
- 18 **Reticular layer.** Stratum reticulare. Part of dermis adjoining the papillary layer. It consists of more compact, densely interwoven connective tissue. A
- 19 **Subcutaneous tissue.** Tela subcutanea. Layer of subcutaneous fatty tissue compartmentalized by fibrous tracts and firmly connected with the corium with mobile connections to the fascia. A
- 20 **Panniculus adiposus.** The thicker layer of fat in the subcutaneous tissue. A
- 21 **Terminal nerve corpuscles.** Corpuscula nervosa terminalia. Collective term for encapsulated nerve endings.
- 22 **End bulbs of Krause (bulboid corpuscles).** Corpuscula bulboidea. Oval convolutions of nerve fibers found especially in the lamina propria of the mucosa. They are considered to be cold receptors. E
- 23 **Lamellated [Vater-Pacini, pacinian] corpuscles.** Corpuscula lamellosa. Oval bodies, 2–3 mm long, with concentric layers of connective tissue surrounding an inner core (axon and Schwann cells). They are pressure receptors found in the subcutaneous fat muscles and viscera. A
- 24 **Tactile [Meissner's] corpuscles.** Corpuscula tactus. These encapsulated sensory organs in the connective papilla of the dermis measure about 0.1 mm in length and consist of transversely oriented tactile cells within a ramified nerve network. A
- 25 **Genital corpuscles.** [Corpuscula genitalia]. Elliptical, encapsulated nerve endings similar to the end bulbs of Krause and found abundantly in the clitoris, glans and nipple. E
- 26 **Tactile menisci [Merkel's discs or corpuscles].** Menisci tractus. Flat group of light cells with intracellular neurofibrils. They occupy the epithelium. D
- 27 **Articular corpuscles.** [Corpuscula articularia]. Modified pacinian corpuscles within joint capsules.



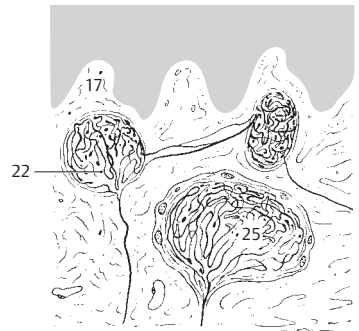
A Skin and subcutaneous layer



B Tactile elevation **C** Coccygeal dimple

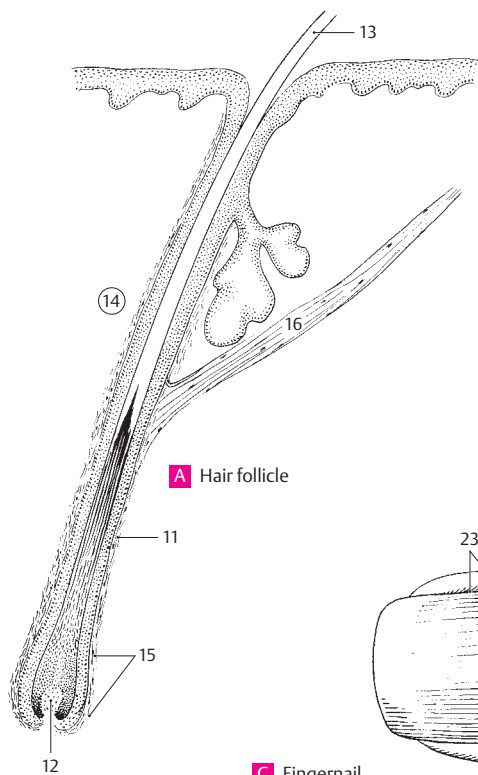


D Tactile discs (tactile menisci)

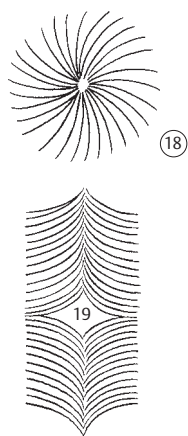


E Corpuscular nerve endings

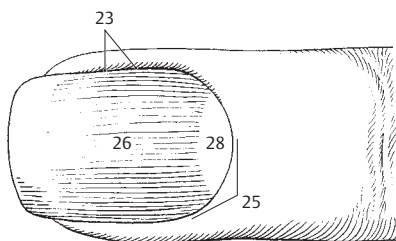
- 1 **Pili.** Collective term for any type of hair.
- 2 **Lanugo.** Fine woolly hair which is distributed over the entire body, especially in the newborn. It usually lacks a medulla.
- 3 **Scalp hairs.** Capilli.
- 4 **Hairs of eyebrow.** Supercilia.
- 5 **Eyelashes.** Cilia.
- 6 **Hairs of beard.** Barba.
- 7 **Hairs of external acoustic meatus.** Tragi.
- 8 **Hairs of the nasal vestibule.** Vibrissae.
- 9 **Axillary hairs.** Hirci.
- 10 **Pubic hairs.** Pubes.
- 11 **Hair follicle.** Folliculus pili. Connective tissue epithelium covering of the hair root. A
- 12 **Hair papilla.** Papilla pili. Connective tissue papilla which projects into the bulb-like, distended lowermost part of the hair root. A
- 13 **Hair shaft.** Scapus pili. Part of the hair that projects out from the skin. A
- 14 **Hair root.** Radix pili. A
- 15 **Bulb of hair.** Bulbus pili. Bulb-like enlargement at the lower end of the hair root. A
- 16 **Mm. arrectores pilorum.** Bundles of smooth muscle passing from the middle of the hair follicle to the papillary layer of the dermis. They are absent on hair of eyelashes, eyebrows, nose, ear and beard. A.: erect hairs (goose-bumps), probably also compression and emptying of sebaceous glands. Innervation: sympathetic fibers from the sympathetic ganglion. A
- 17 **Hair streams.** Flumina pilorum. Orientational patterns of hair. B
- 18 **Whorled pattern of hair growth.** Vortices pilorum. B
- 19 **Cruciate pattern of hair growth.** Cruces pilorum. It is found at sites where the hair patterns meet from two directions and continue two new directions perpendicular to each other. B
- 20 **Nails.** Unguis. Fingernails and toenails. C D
- 21 **Nail matrix (bed).** Matrix unguis. Tissue (epidermis) upon which the nail rests (root and lunula). Nail substance is formed in the region of the lunula. D E
- 22 **Crests of nail matrix.** Cristae matricis unguis. Longitudinal ridges in nail bed. E
- 23 **Nail groove (fold).** Sulcus matricis unguis. Cutaneous slit into which the lateral nasal margins are embedded. C
- 24 **Nail sinus.** Sinus unguis. Deep furrow into which the root of the nail is inserted. D
- 25 **Wall of nail.** Vallum unguis. Cutaneous fold overlapping the sides and proximal end of the nail. C D
- 26 **Body of nail.** Corpus unguis. C D E
- 27 **Root of nail.** [[Radix unguis]]. Part of nail situated in the nail sinus. D
- 28 **Lunula.** Crescentic, whitish area at the base of the nail. Its anterior margin corresponds to the anterior border of the nail-forming tissue. C
- 29 **Margo occultus.** Proximal, posterior margin of a nail located deep within the nail sinus. D



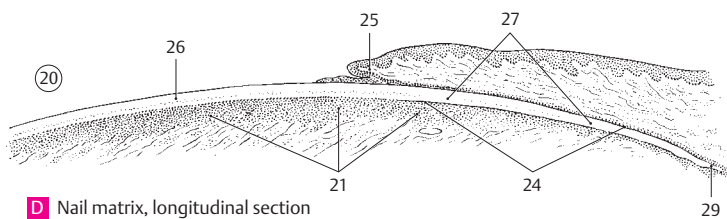
A Hair follicle



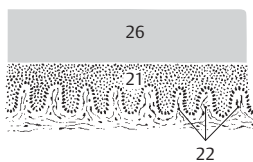
B Hair growth patterns



C Fingernail

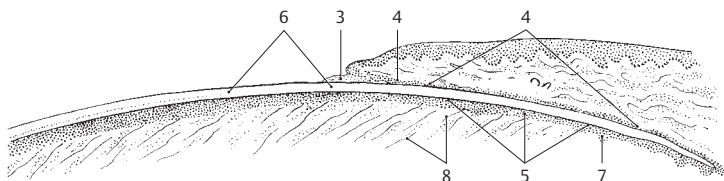


D Nail matrix, longitudinal section

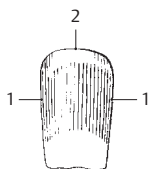


E Nail matrix, cross section

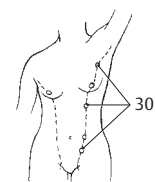
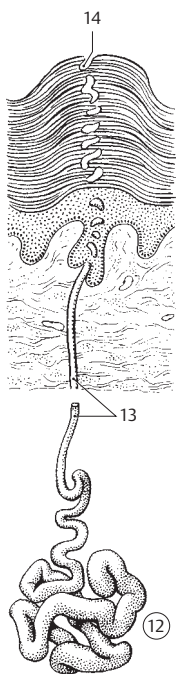
- 1 **Lateral margin.** Margo lateralis. Lateral margin of nail lying beneath the nail wall. B
- 2 **Free margin.** Margo liber. Anterior, free margin of nail. It corresponds to the abrasive or cutting edge of the nail. B
- 3 **Perionych.** Projecting edge of the eponychium covering the proximal strip of the lunula. A
- 4 **Eponychium.** Cuticle. The small band of epithelium that extends from the posterior nail wall onto the base of a nail. A
- 5 **Hyponychium.** Epithelium of nail bed located beneath the nail. Its posterior portion in the region of the lunula and nail root form the matrix. A
- 6 **Stratum corneum unguis.** Already cornified part of nail. A
- 7 **Stratum germinativum unguis.** Layer of nail bed epithelium still undergoing cell proliferation. A
- 8 **[[Retinacula unguis]].** Anchoring tracts of connective tissue extending from the nail bed to the periosteum of the nail segment. A
- 9 **Cutaneous glands.** Glandulae cutis. Glands arising from the epidermis and standing in close relationship to the skin.
- 10 **Sweat glands.** [[Gll. glomiformes]]. Collective term for the small eccrine sweat glands and the large apocrine sweat or odoriferous glands.
- 11 **Eccrine (merocrine) sweat (sudoriferous) glands.** Gll. sudorifer merocrina (eccrina). Eccrine sweat glands, as opposed to the apocrine sweat glands of the anal, genital and axillary regions. E
- 12 **Terminal secretory part.** Portio terminalis. Coiled, secretory body of a sweat gland lying in the subcutaneous tissue or in the deep portion of the dermis. E F
- 13 **Sweat gland duct.** Ductus sudorifer. Excretory duct passing to the surface. It is shaped like a corkscrew within the highly cornified squamous epithelium of palms and soles and opens on the dermal ridges. E F
- 14 **Pore of sweat gland.** Porus sudorifer. Opening of the excretory duct of a sweat gland on the skin. E
- 15 **Circumanal glands.** Gll. circumanales. Large apocrine sweat glands grouped around the anus.
- 16 **Ceruminous glands.** Gll. ceruminosae. Apocrine glands that secrete a proteinaceous material called cerumen (ear wax).
- 17 **Sebaceous glands.** Gll. sebaceae. Holocrine glands opening into the hair follicles. F
- 18 **Breast.** Mamma. It consists of glandular tissue, connective tissue tracts and fat. D
- 19 **Nipple.** Papilla mammae. It contains openings of the lactiferous ducts and smooth muscle tissue. D
- 20 **Body of mammary gland.** Corpus mammae. Glandular body surrounded by adipose tissue.
- 21 **Mammary gland.** Glandula mammaria. Glandular tissue of female breast. D
- 22 **Lateral (axillary) process; axillary tail.** Processus lateralis (axillaris). Glandular process extending toward the axilla.
- 23 **Lobes of mammary gland.** Lobi glandulae mammariae. 15–20 conical lobes. D
- 24 **Lobules of mammary gland.** Lobuli glandulae mammariae. Subdivisions of each lobe produced by connective tissue septa. D
- 25 **Lactiferous ducts.** Ductus lactiferi. Excretory ducts, 15–20, one from each lobe. They have a diameter of 1.7–2.3 mm and open on the nipple. D
- 26 **Lactiferous sinus.** Sinus lactiferi. Spindle-shaped dilatation of the lactiferous duct with a diameter of 5–8 mm shortly before opening at the apex of the nipple. D
- 27 **Areola mammae.** Round, pigmented area around the nipple with a ring of small, rounded papillae produced by the areolar glands. D
- 28 **Areolar glands (of Montgomery).** Glandulae areolares. 10–15 apocrine glands in the region of the areola. D
- 29 **Male mammary gland.** Mamma masculina. Rudimentary mammary gland of the male.
- 30 **Accessory mammary glands.** [Mammae accessoriae]. The accessory mammary glands lying along the embryonic milk ridge. C
- 31 **Suspensory ligaments of breast.** Ligg. suspensoria mammae. Tracts of connective tissue from the skin of the breast to the pectoral fascia with which they are united by a thin layer of loose displaceable tissue. D



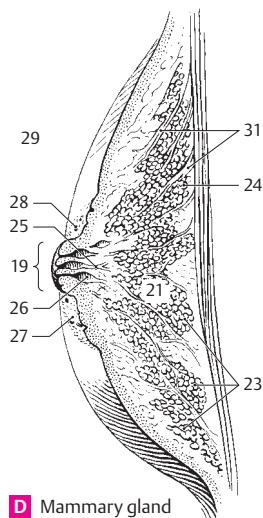
A Nail matrix, longitudinal section



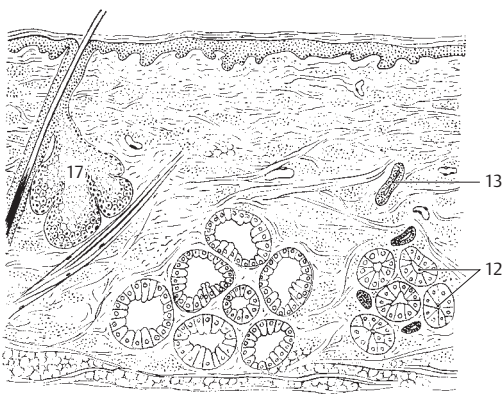
B Nail from above



C Milk line



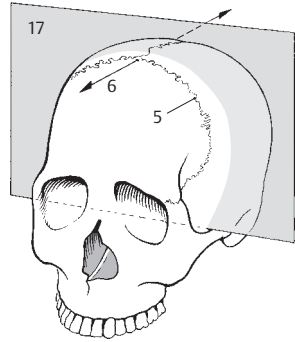
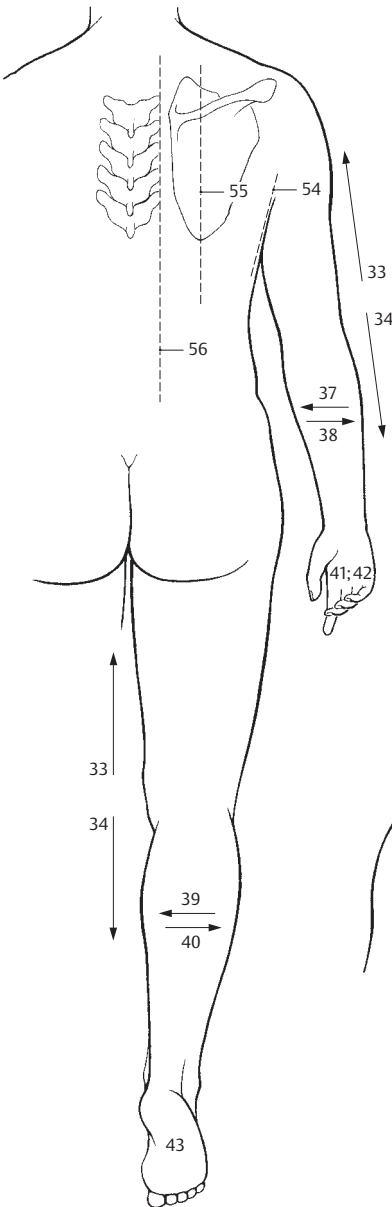
D Mammary gland



E Sudoriferous gland

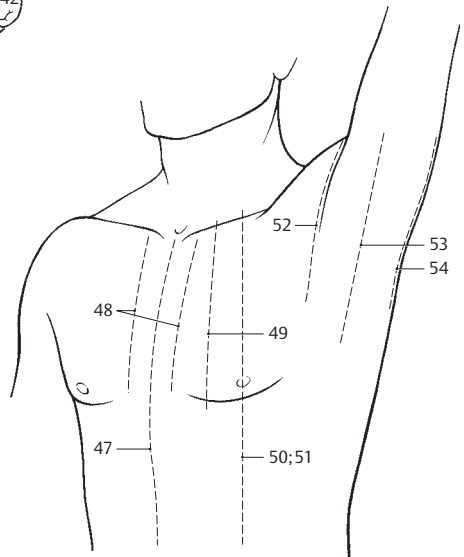
F Skin glands

- 1 **GENERAL TERMINOLOGY.** Termini generales.
- 2 **Vertical (perpendicular).** Verticalis.
- 3 **Horizontal.** Horizontalis.
- 4 **Median.** Medianus. Lying in the midline (mid-sagittal plane).
- 5 **Coronal.** Coronalis. Lying in the plane of the coronal suture. A
- 6 **Sagittal.** Sagittalis. Lying in the plane of the sagittal suture. A
- 7 **Right.** Dexter.
- 8 **Left.** Sinister.
- 9 **Transverse.** Transversalis. Situated at right angles to the long axis of a part.
- 10 **Medial.** Medialis. Lying close to the median plane.
- 11 **Intermediate.** Lying between two structures.
- 12 **Lateral.** Lateralis. Situated toward the side.
- 13 **Anterior.** Situated in front of.
- 14 **Posterior.** Situated behind.
- 15 **Ventral (anterior).** Ventralis. Toward the belly.
- 16 **Dorsal (posterior).** Dorsalis. Toward the back.
- 17 **Frontal.** Frontalis. 1. Pertaining to the forehead; 2. Plane separating the body into front and back parts (frontal or coronal plane). A
- 18 **Occipital.** Occipitalis. Pertaining to the occiput.
- 19 **Upper.** Superior.
- 20 **Lower.** Inferior.
- 21 **Cranial.** Cranialis. Pertaining to the head; toward the head.
- 22 **Caudal.** Caudalis. Situated toward the tail.
- 23 **Rostral.** Rostralis. Located toward the rostrum of the corpus callosum.
- 24 **Apical.** Apicalis. Pertaining to or located at the apex.
- 25 **Basal.** Basalis. Pertaining to or located at the base.
- 26 **Basilar.** Basilaris. Pertaining to the base of the skull.
- 27 **Middle.** Medius.
- 28 **Transverse.** Transversus.
- 29 **Longitudinal.** Longitudinalis. Running longitudinally.
- 30 **Axialis.** Pertaining to or located at the axis, e. g., the 2nd cervical vertebra.
- 30a **External (outer).** Externus.
- 30a **Internal (inner).** Internus.
- 31 **Superficial.** Superficialis. Lying near the surface.
- 32 **Deep.** Profundus.
- 33 **Proximal.** Proximalis. Lying near the trunk. B
- 34 **Distal.** Distalis. Lying further away from the trunk.
- 35 **Central.** Centralis. Lying in the midpoint.
- 36 **Peripheral.** Peripheralis. Not pertaining to the center.
- 36a **Periphery.** Periphericus.
- 37 **Radial.** Radialis. Pertaining to or located at the radius. B
- 38 **Ulnar.** Ulnaris. Pertaining to or located at the ulna. B
- 39 **Fibular.** Fibularis. Pertaining to the fibula or located on the fibular part of the leg. B
- 40 **Tibial.** Tibialis. Pertaining to the tibia or located on the tibial part of the leg. B
- 41 **Palmar.** Palmaris. Pertaining to or located on the palm. B
- 42 **Volar.** Volaris. Same as palmar. B
- 43 **Plantar.** Plantaris. Pertaining to or located on the sole of the foot. B
- 44 **Flexor.** A muscle that bends (flexes) a joint.
- 45 **Extensor.** A muscle that straightens (extends) a joint.
- 46 **REGIONS AND PARTS OF THE BODY.** Regiones et partes corporis.
- 47 **Anterior median line.** Linea mediana anterior. Vertical plane through the middle of the trunk. C
- 48 **Sternal line.** Linea sternalis. Line corresponding to the lateral margin of the sternum. C
- 49 **Parasternal line.** Linea parasternalis. Vertical line midway between the sternal and mid-clavicular lines. C
- 50 **Midclavicular (mammary) line.** Linea medio-clavicularis. Vertical line passing through the halfway point of the clavicle. C
- 51 **Mammary line.** Linea mamillarlis. Same as mid-clavicular line. C
- 52 **Anterior axillary line.** Linea axillaris anterior. It lies at the anterior fold of the axilla. C
- 53 **Axillary (midaxillary) line.** Linea axillaris media. It lies in the middle between the anterior and posterior axillary lines. C
- 54 **Posterior axillary line.** Linea axillaris posterior. It lies at the posterior fold of the axilla. B C
- 55 **Scapular line.** Linea scapularis. A vertical line through the inferior angle of the scapula. B
- 56 **Paravertebral line.** Linea paravertebralis. Vertical line through the ends of the transverse processes visible only in radiograms. B



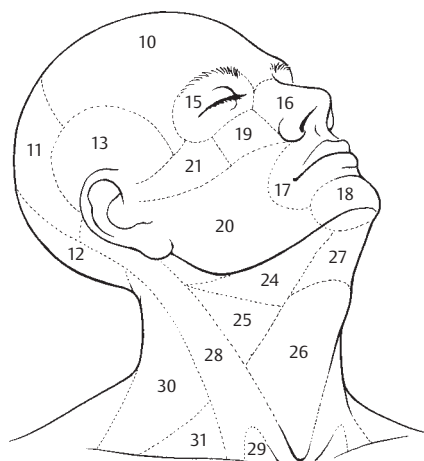
A Frontal plane of skull

B Directions of orientation

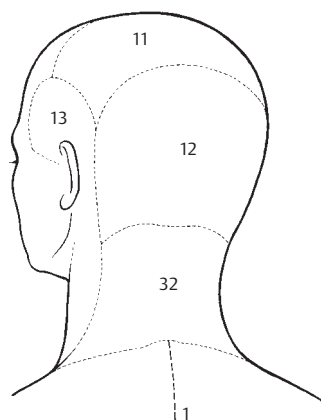


C Lines of orientation on upper part of body

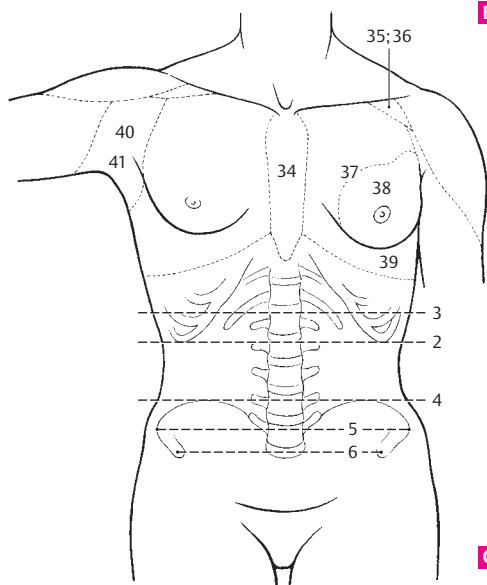
- 1 **Posterior median line.** Linea mediana posterior. Vertical line through the median plane of the posterior trunk. B
- 2 **Subcostal plane.** Planum subcostale. Transverse plane through the lower edge of the 10th costal cartilage. C
- 3 **Transpyloric plane.** Planum transpyloricum. Horizontal plane transecting the trunk halfway between the upper margin of the pubic symphysis and the upper margin of the manubrium sterni. C
- 4 **Supracristal plane.** Planum supracristale. Horizontal plane through the highest point of the iliac crest. It transects the vertebral column at the level of the spinous process of L4. C
- 5 **Intertubercular plane.** Planum intertuberculare. Transverse plane through the iliac tubercle. C
- 6 **Interspinal plane.** Planum interspinale. Transverse plane through the anterior superior iliac spine. C
- 7 **Preaxillary line.** Linea praeaxillaris.
- 8 **Postaxillary line.** Linea postaxillaris.
- 9 **Head regions.** Regiones capitis. The various anatomic regions of the head.
- 10 **Frontal region.** Regio frontalis. A
- 11 **Parietal region.** Regio parietalis. The region above the parietal bone. A B
- 12 **Occipital region.** Regio occipitalis. The region above the occipital bone. A B
- 13 **Temporal region.** Regio temporalis. The region above the temporal bone. A B
- 14 **Facial regions.** Regiones faciales. The various anatomic regions of the face. A
- 15 **Orbital region.** Regio orbitalis. Area involving the orbit. A
- 16 **Nasal region.** Regio nasalis. Region involving the nose. A
- 17 **Oral region.** Regio oralis. Area around the mouth. A
- 18 **Mental region.** Regio mentalis. Chin area. A
- 19 **Infraorbital region.** Regio infraorbitalis. Region below the orbit. A
- 20 **Buccal region.** Regio buccalis. Cheek area. A
- 21 **Zygomatic region.** Regio zygomatica. A
- 22 **Cervical regions.** Regiones cervicales. The various anatomic regions of the neck.
- 23 **Anterior triangle of neck.** Regio cervicalis anterior (trigonum cervicalis anterius). Region between the midline and the sternocleidomastoid muscle.
- 24 **Submandibular (digastric) triangle.** Trigonum submandibulare. Region bounded by the inferior border of the mandible and the two bellies of the digastric muscle. A
- 25 **Carotid triangle.** Trigonum caroticum. Triangular region bounded by the sternocleidomastoid muscle, posterior belly of the digastric muscle and superior belly of the omohyoid muscle. A
- 26 **Muscular (inferior carotid) triangle.** Trigonum musculare (omotracheale). Triangular region between the anterior median line of the neck, the anterior margin of the sternocleidomastoid muscle and the superior belly of the omohyoid muscle. A
- 27 **Submental (suprahyoid) triangle.** Trigonum submentale. Triangle below the chin between the hyoid bone and the anterior belly of the digastric muscle on each side. A
- 28 **Sternocleidomastoid region.** Regio sternocleidomastoidea. Region overlying the sternocleidomastoid muscle. A
- 29 **Lesser supraclavicular fossa.** Fossa supraclavicularis minor. Triangular depression between the sternal and clavicular origins of the sternocleidomastoid muscle. A
- 30 **Posterior triangle of neck.** Regio cervicalis lateralis (trigonum cervicale posterius). Triangle between the clavicle, anterior margin of the trapezius and posterior border of the sternocleidomastoid muscle. A
- 31 **Supraclavicular (omoclavicular, subclavian) triangle.** Trigonum omoclaviculare (fossa supraclavicular major) greater supraclavicular fossa. Triangle between the sternocleidomastoid and omohyoid muscles and the clavicle. A
- 32 **Posterior region of the neck (nuchal region).** Regio cervicalis posterior (regio nuchalis). B
- 33 **Pectoral regions.** Regiones pectorales. Collective term for the various regions of the chest, which are described below.
- 34 **Presternal region.** Regio presternalis. Area in front of the sternum. C
- 35 **Infraclavicular fossa.** Fossa infraclavicularis. Depression produced by the clavipectoral triangle. C
- 36 **Clavipectoral triangle.** Trigonum clavipectoralis. Triangle between the deltoid, pectoralis major and clavicle. C
- 37 **Pectoral region.** Regio pectoralis. Area on the pectoralis major muscle. C
- 38 **Mammary region.** Regio mammaria. Region pertaining to the mammary gland. C
- 39 **Inframammary region.** Regio inframammaria. Region below the mammary region. C
- 40 **Axillary region.** Regio axillaris. C
- 41 **Axillary fossa.** Fossa axillaris. C



A Head and neck regions

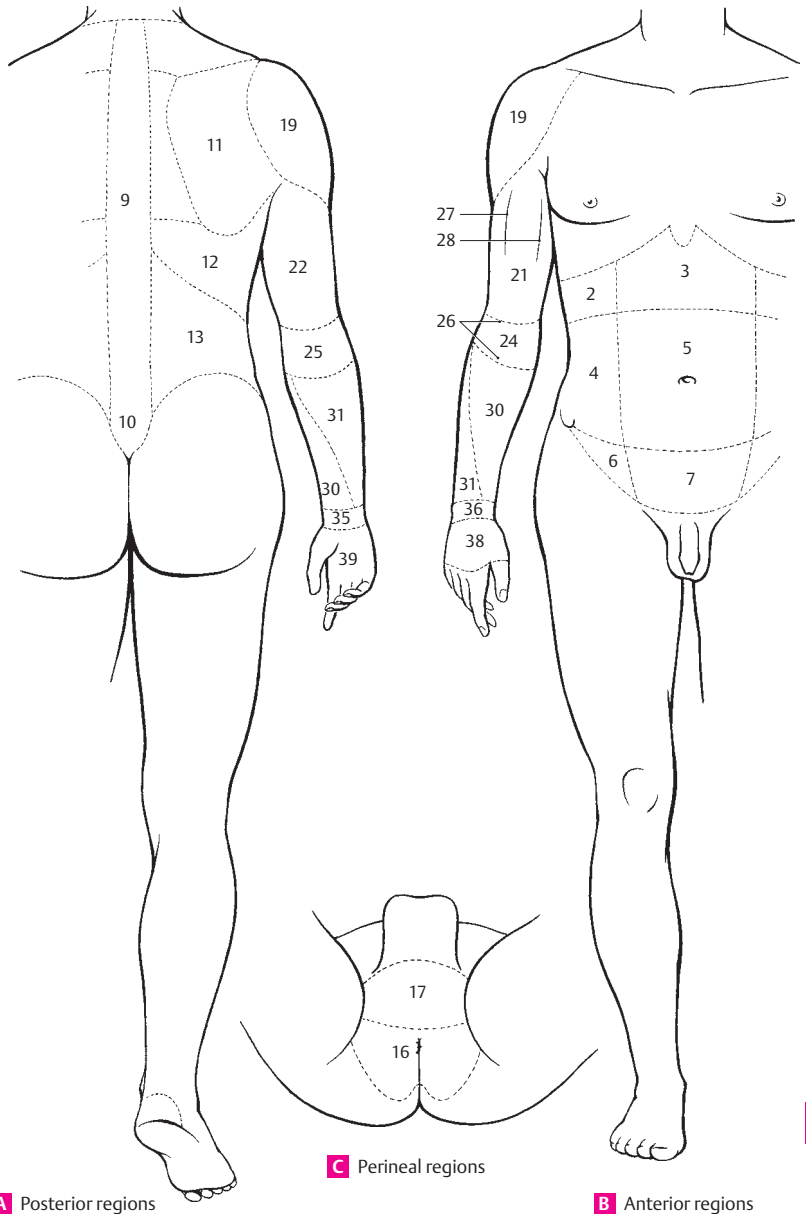


B Head and nuchal regions



C Planes for orientation and regions of trunk

- 1 **Abdominal regions.** Regiones abdominales.
- 2 **Hypochondriac region (hypochondrium).** Regio hypochondriaca (hypochondrium). Region lateral to the midclavicular line between the pectoral region and the transpyloric plane. B
- 3 **Epigastric region (epigastrium).** Regio epigastrica (epigastrium). Region medial to the midclavicular line between the pectoral region and the transpyloric plane. B
- 4 **Lumbar (lateral) region.** Regio lateralis. Region lateral to the midclavicular line between the transpyloric and intertubercular planes. B
- 5 **Umbilical region.** Regio umbilicalis. Area medial to the midclavicular line between the transpyloric and intertubercular planes. B
- 6 **Inguinal (iliac) region.** Regio inguinalis. Region lateral to the midclavicular line between the intertubercular plane and the inguinal ligament. B
- 7 **Hypogastric (pubic) region.** Regio pubica (hypogastrum). Region medial to the midclavicular line between the intertubercular plane and the inguinal ligament. B
- 8 **Posterior (dorsal) regions.** Regiones dorsales. The various anatomic regions of the back.
- 9 **Vertebral region.** Regio vertebralis. Region overlying the vertebral column. A
- 10 **Sacral region.** Regio sacralis. Region overlying the sacrum. A
- 11 **Scapular region.** Regio scapularis. Region overlying the scapula. A
- 12 **Infrascapular region.** Regio infrascapularis. Area between the scapular region and the lumbar region. A
- 13 **Region cranial to the iliac crest.** Regio lumbaris (lumbalis). A
- 14 **Lumbar (Petit's) trigone.** Trigonum lumbare [[Petiti]]. Triangle above the iliac crest between the margins of the latissimus dorsi and external abdominal oblique.
- 15 **Perineal region.** Regio perinealis. C
- 16 **Anal region.** Regio analis. Area around the anus. It is bordered anteriorly by an imaginary line through the two ischial tuberosities. C
- 17 **Urogenital region.** Regio urogenitalis. Perineal area in front of the imaginary line between the two ischial tuberosities. C
- 18 **Regions of upper limb.** Regiones membri superioris.
- 19 **Deltoid region.** Regio deltoidea. Region overlying the deltoid muscle. B
- 20 **Upper arm.** Brachium.
- 21 **Anterior brachial region.** Regio (facies) brachialis anterior. Anterior surface of the upper arm. B
- 22 **Posterior brachial region.** Regio (facies) brachialis posterior. Posterior surface of the upper arm. A
- 23 **Elbow.** Cubitus.
- 24 **Anterior cubital region.** Regio (facies) cubitalis anterior. Anterior surface of the elbow. B
- 25 **Posterior cubital region.** Regio (facies) cubitalis posterior. Posterior surface of the elbow. A
- 26 **Cubital fossa.** Fossa cubitalis. B
- 27 **Lateral bicipital groove.** Sulcus bicipitalis lateralis (radialis). B
- 28 **Medial bicipital groove.** Sulcus bicipitalis medialis (ulnaris). B
- 29 **Forearm.** Antebrachium.
- 30 **Anterior antebrachial region.** Regio (facies) antebrachialis anterior. Anterior surface of the forearm. A B
- 31 **Posterior antebrachial region.** Regio (facies) antebrachialis posterior. Posterior surface of the forearm. A B
- 32 **Lateral margin.** Margo lateralis (radialis).
- 33 **Medial margin.** Margo medialis (ulnaris).
- 34 **Wrist.** Carpus.
- 35 **Anterior carpal region.** Regio carpalis anterior. Anterior of flexor side of the wrist. A
- 36 **Posterior carpal region.** Regio carpalis posterior. Posterior or extensor side of the wrist. B
- 37 **Hand.** Manus.
- 38 **Dorsum of hand.** Dorsum manus. B
- 39 **Palm of hand.** Palma manus. A
- 40 **Thenar eminence.** Thenar (eminentia thenaris). Ball of the thumb.
- 41 **Hypothenar eminence.** Hypothenar (eminentia hypothenaris). Ball of the little finger.
- 42 **Metacarpus.** Part of the hand between the wrist and digits.
- 43 **Digits (fingers).** Digi.
- 44 **Thumb.** Pollex (digitus primus (I)).
- 45 **Index finger.** Index (digitus secundus (II)).
- 46 **Middle finger.** Digitus medius (tertius (III)).
- 47 **Ring finger.** Digitus anularis (quartus (IV)).
- 48 **Little finger.** Digitus minimus (quintus (V)).
- 49 **Ventral (palmar, flexor) side of fingers.** Facies digitales ventrales (palmares).
- 50 **Dorsal (extensor) side of fingers.** Facies digitales dorsales.

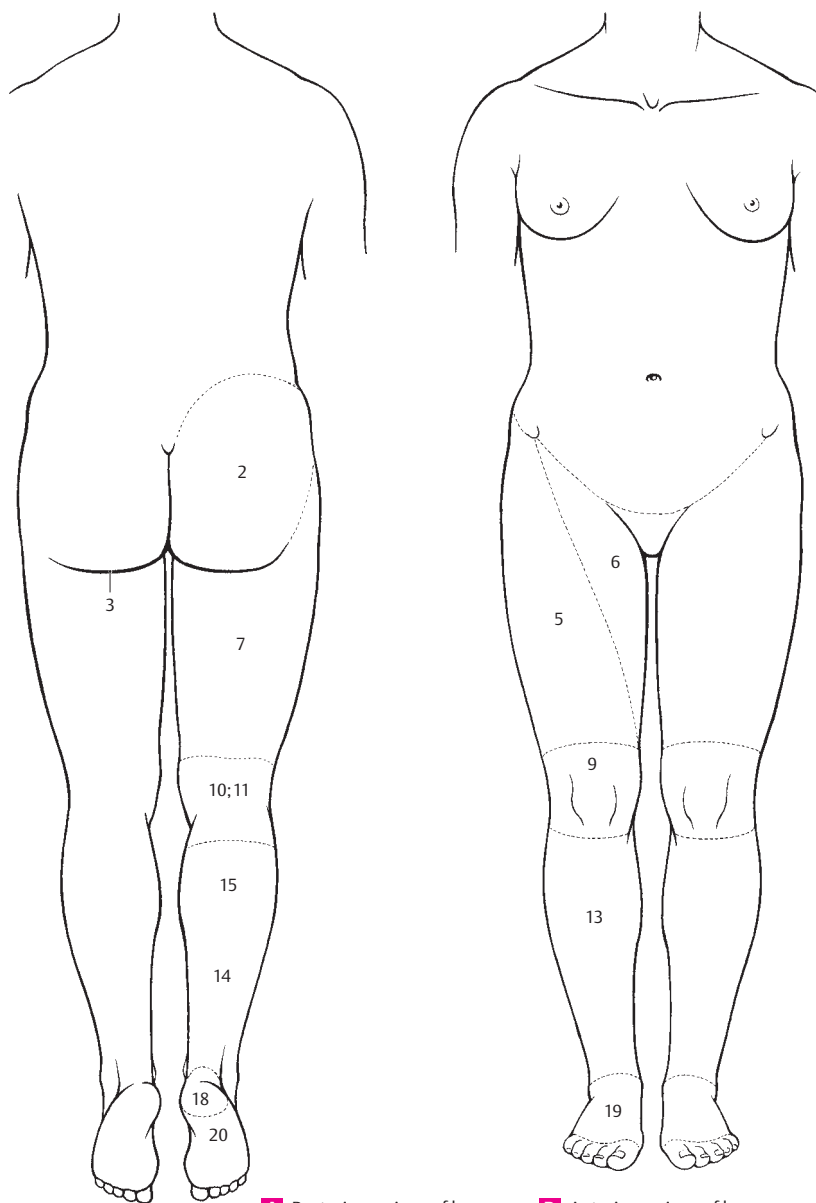


A Posterior regions

C Perineal regions

B Anterior regions

- 1 **Regions of lower limb.** Regiones membri inferioris. The various anatomic regions of the lower limb.
- 2 **Gluteal region.** Regio glutealis. Area over the gluteal muscles. A
- 3 **Gluteal fold.** Sulcus glutealis. Fold passing over the gluteus maximus and bordering the buttocks inferiorly when the hip joint is extended. A
- 3a **Hip joint.** Coxa (regio coxalis).
- 4 **Thigh region.** Femur (regio femoralis).
- 5 **Anterior thigh region.** Regio (facies) femoralis anterior. B
- 6 **Femoral triangle.** Trigonum femorales. Triangular region of the groin bordered by the sartorius and adductor longus muscles and the inguinal ligament. B
- 7 **Posterior thigh region.** Regio (facies) femoralis posterior. A
- 8 **Knee.** Genus.
- 9 **Anterior side of knee.** Regio genus anterior. B
- 10 **Posterior side of knee.** Regio genus posterior. A
- 11 **Popliteal fossa.** Fossa poplitea. A
- 12 **Lower leg.** Crus.
- 13 **Anterior surface of lower leg.** Regio (facies) cruralis anterior. B
- 14 **Posterior surface of lower leg.** Regio (facies) cruralis posterior. A
- 15 **Calf.** Sura (regio suralis). A
- 16 **Anterior and posterior talocrural (malleolar) regions.** Regiones talocrurales anterior et posterior.
- 17 **Foot.** Pes.
- 18 **Heel (calcaneal region).** Calx (regio calcanea). A
- 19 **Dorsum of foot.** Dorsum (regio dorsalis) pedis. B
- 20 **Plantar surface of foot (sole).** Planta (regio plantaris) pedis. A
- 21 **Lateral (fibular, outer) margin of foot.** Margo lateralis (fibularis) pedis.
- 22 **Medial (tibial, inner) margin of foot.** Margo medialis (tibialis) pedis.
- 23 **Ankle.** Tarsus.
- 24 **Metatarsus.** Part of foot between ankle and toes.
- 25 **Toes.** Digiti.
- 26 **Big (great) toe.** Hallux (digitus primus (I)).
- 27 **Second, third, fourth toes.** Digiti secundus, tertius, quartus (II, III, IV).
- 28 **Little toe.** Digitus minimus (quintus) (V).
- 28a **Plantar surface (undersurface) of toe.** Facies digitalis plantaris.
- 28b **Dorsal surface of toe.** Facies digitalis dorsalis.
- 29 **OSTEOLOGY.** Osteologia.
- 30 **SKELETAL SYSTEM.** Systema skeletale.
- 31 **Bony part.** Pars ossea.
- 32 **Periosteum.** External covering of bone.
- 33 **Endosteum.** Internal lining of bone. It also lines the marrow cavity.
- 34 **Cortical substance.** Substantia corticalis. Superficial layer formed by the external main lamellae of the bone.
- 35 **Compact bone.** Substantia compacta. Dense bony substance formed by osteons.
- 36 **Spongy (trabecular) bone.** Substantia spongiosa (trabecularis). Loosely organized bone substance with interstices occupied by bone marrow.
- 37 **Cartilaginous part (of the skeleton).** Pars cartilaginosa.
- 38 **Perichondrium.** Connective tissue covering of cartilage. It contributes to cartilage growth.
- 39 **Axial skeleton.** Skeleton axiale. Skeleton of the trunk.
- 40 **Appendicular skeleton.** Skeleton appendiculare. Skeleton of the limbs.
- 41 **Long bone.** Os longum. Long bone such as the fibula.
- 42 **Short bone.** Os breve. Short bone such as the wrist bone.
- 43 **Flat bone.** Os planum. Flat bone such as the parietal bone.
- 44 **Irregular bone.** Os irregulare. Irregular bone such as the sphenoid bone.
- 45 **Pneumatic bone.** Os pneumaticum. Bone with air-containing cells, e. g., the ethmoid bone.
- 46 **Epiphysis.** End of a long bone temporarily involved in bone growth.
- 47 **Diaphysis.** Middle piece (shaft) of bone.
- 48 **Metaphysis.** Bony region between the epiphysis and diaphysis.
- 49 **Epiphysial cartilage.** Cartilago epiphysialis. Cartilage zone between the diaphysis and epiphysis. It is responsible for the longitudinal growth of long bones.



- 1 **Epiphysial line.** Linea epiphysialis. Line visible in radiograms and in sections of bone marking the former site of the epiphysial cartilage.
- 2 **Joint surface.** Facies articularis.
- 3 **Medullary cavity.** Cavitas medullaris.
- 4 **Yellow bone marrow.** Medulla ossium flava. It contains abundant fat.
- 5 **Red bone marrow.** Medulla ossium rubra. It is hemopoietic.
- 6 **Nutrient foramen.** Foramen nutriens. Macroscopic foramen for nutrient vessels supplying mainly the bone marrow.
- 7 **Nutrient canal.** Canalis nutriens. Canal continuous with the nutrient foramen.
- 8 **Center of ossification.** Centrum ossificationis. Site of onset of ossification of bones preformed in cartilage (endochondral ossification).
- 9 **Primary center of ossification.** Centrum ossificationis primarium. The center situated in the diaphysis (diaphysial ossification).
- 10 **Secondary center of ossification.** Centrum ossificationis secundarium. The center situated in the epiphysis (epiphysial ossification).
- 11 **ARTHROLOGY.** Arthrologia. Study of the joints.
- 12 **FIBROUS JOINTS.** Articulationes fibrosae. They usually have no direct relationship to an articular cavity.
- 13 **Syndesmosis.** Fibrous joint with interosseous membrane or ligament.
- 14 **Suture.** Sutura.
- 15 **Dentate suture.** Sutura serrata. Serrated suture, e. g., the lambdoid suture.
- 16 **Squamous suture.** Sutura squamosa, e. g., on the temporal bone.
- 17 **Flat suture.** Sutura plana. Bony union producing a smooth surface, e. g., between the zygomatic bone and the maxilla.
- 18 **Schindylesis.** Union between a groove in one bone and a ridge in the other, e. g., between the vomer and the sphenoid bone.
- 19 **CARTILAGINOUS JOINTS.** Articulationes cartilagineae.
- 20 **Synchondrosis.** Bony union by means of hyaline cartilage.
- 21 **Symphysis.** Bony union, partly by means of fibrocartilage.
- 22 **SYNOVIAL JOINTS.** Articulationes synoviales. Bony union with an intervening articular cavity.
- 23 **Simple joint.** Articulatio simplex. Joint between only two bones, e. g., the hip joint.
- 24 **Composite joint.** Articulatio composita (complexa). Joint involving more than two bones, e. g., the wrist joint.
- 25 **Plane joint.** Articulatio plana. Joint with almost smooth articular surfaces.
- 26 **Spheroidal joint.** Articulatio sphaeroidea (cotylica). Ball and socket joint, e. g., the shoulder joint.
- 27 **Ellipsoidal (condylar) joint.** Articulatio ellipsoidea (condylaris). Joint with two axes, e. g., the wrist joint.
- 28 **Hinge joint.** Ginglymus. Joint with one axis, e. g., the elbow joint.
- 29 **Bicondylar joint.** Articulatio bicondylaris. Articulation with one main transverse axis and another axis in the longitudinal direction of a skeletal part., e. g., the knee joint.
- 30 **Trochoidal joint.** Articulatio trochoidea. Pivot joint with one axis, e. g., the radio-ulnar joint.
- 31 **Saddle (sellar) joint.** Articulatio sellaris. Joint with two axes, e. g., the metacarpophalangeal joint of the thumb.
- 32 **Ovoidal joint.** [[Articulatio ovoidalis]]. Joint with only weakly curved articular surfaces.
- 33 **Articular cartilage.** Cartilago articularis.
- 34 **Articular cavity.** Cavitas articularis. Joint cavity.
- 35 **Articular disk.** Discus articularis. Disk that divides a joint cavity into two separate chambers.
- 36 **Meniscus.** Meniscus articularis. Ring-like articular disk, e. g., in the knee joint.
- 37 **Articular lip.** Labrum articulare. Rim of fibrocartilage at the margin of a socket.
- 38 **Joint capsule.** Capsula articularis.
- 39 **Fibrous membrane.** Membrana fibrosa (stratum fibrosum). Connective tissue layer of the capsule often reinforced by ligaments.
- 40 **Synovial membrane.** Membrana synovialis (stratum synoviale). Inner layer of the articular capsule comprised of epithelium-like connective tissue cells on loose connective tissue.
- 41 **Synovial fold.** Plica synovialis. Fold projecting from the capsule into the joint space.
- 42 **Synovial villi.** Villi synoviales.
- 43 **Synovia.** Synovial fluid secreted by the synovial membrane of the capsule.
- 44 **Articular ligaments.** Ligamenta.
- 45 **Extracapsular ligaments.** Ligamenta extracapsularia. Ligaments lying outside the capsular wall, e. g., the external collateral ligament of the knee joint.
- 46 **Capsular ligaments.** Ligamenta capsularia. Reinforcing fibers outside a joint capsule, e. g., the collateral ligaments of the interphalangeal joints.
- 47 **Intracapsular ligaments.** Ligamenta intracapsularis. Ligaments located within a joint space, e. g., the cruciate ligaments of the knee joint.

- 1 **MYOLOGY.** Myologia. Study of the muscles.
- 2 **Muscle.** Musculus.
- 3 **Head.** Caput.
- 4 **Belly.** Venter.
- 5 **Fusiform muscle.** Musculus fusiformis. Spindle-shaped muscle.
- 6 **Quadrant muscle.** M. quadratus. Square-shaped muscle.
- 7 **Triangular muscle.** M. triangularis. Triangular muscle.
- 8 **Unipennate muscle.** M. unipennatus. Muscle with fibers approaching the tendon from one side.
- 9 **Bipennate muscle.** M. bipennatus. Muscle with fibers approaching the tendon from two sides.
- 10 **Multipennate muscle.** M. multipennatus. Muscle with fibers approaching the tendon from many sides.
- 11 **Sphincter muscle.** M. sphincter.
- 11 a **Dilator muscle.** M. dilator (dilator).
- 12 **Orbicular muscle.** M. orbicularis. Circular muscle.
- 13 **Cruciate muscle.** M. cruciatus. Muscle with crossing fibers.
- 14 **Articular muscle.** [[M. articularis]]. Muscle which attaches to a joint capsule.
- 15 **Skeletal muscle.** M. skeleti. Muscle with attachment to the skeleton in contrast to a cutaneous muscle.
- 16 **Cutaneous muscle.** M. cutaneus.
- 17 **Tendon.** Tendo.
- 18 **Tendon (synovial) sheath.** Vagina tendinis. Lubricated sheath for easy gliding of a tendon.
- 19 **Fibrous layer.** Stratum fibrosum. Outer, connective tissue portion of a tendon sheath.
- 20 **Synovial layer.** Stratum synoviale. Inner, smooth layer of a tendon sheath. It secretes synovial fluid.
- 20 a **Synovial sheath of tendon.** Vagina synovialis tendinis. The inner gliding capsule of the fibrous sheath of a tendon.
- 21 **Mesotendineum.** Mesentery-like sheath connecting a tendon to its fibrous sheath. It carries blood vessels to the tendon.
- 22 **Peritendineum.** Connective tissue on the surface of a tendon.
- 23 **Aponeurosis.** Flat tendinous expansion.
- 23 a **Epimysium.** Fibrous sheath enveloping an entire muscle.
- 24 **Perimysium.** Fibrous sheath enclosing a bundle of muscle fibers.
- 25 **Endomysium.** Fibrous sheath surrounding a single muscle fiber enclosed by sarcolemma.
- 26 **Fascia.** External sheath investing one or more muscles.
- 26 a **Superficial fascia.** Fascia superficialis.
- 26 b **Deep fascia.** Fascia profunda.
- 27 **Tendinous intersections.** Intersectio tendinea.
- 27 a **Intermediate tendon.** Tendo intermedius.
- 28 **Tendinous arch.** Arcus tendineus. It serves as the origin of muscle fibers.
- 29 **Muscular trochlea.** Trochlea muscularis. Structure that changes the direction of pull of a tendon, e.g., the sustentaculum tali of the flexor hallucis longus tendon.
- 30 **SYNOVIAL BURSAE.** Bursae synoviales.
- 31 **Subcutaneous bursa.** Bursa [synovialis] subcutanea. It lies directly beneath the skin.
- 32 **Submuscular bursa.** Bursa [synovialis] submuscularis. It lies beneath a muscle.
- 33 **Subfascial bursa.** Bursa [synovialis] subfascialis. It lies beneath a fascia.
- 34 **Subtendinous bursa.** Bursa [synovialis] subtendinea. It lies beneath a tendon.
- 35 **SPLANCHNOLOGY.** Splanchnologia. Study of viscera.
- 36 **General terms.** Nomina generalia.
- 37 **Tunica albuginea.** Tough, whitish connective tissue sheath.
- 38 **Tunica fibrosa.** Fine connective tissue layer.
- 39 **Tunica adventitia.** Outermost connective tissue covering.
- 40 **Tunica mucosa.** Mucous membrane with its various layers.
- 41 **Epithelium mucosae.** Epithelial cell layer of the mucosa.
- 42 **Lamina propria mucosae.** Lamina propria of the mucosa. Layer of reticular connective tissue extending up to the muscularis mucosae.
- 43 **Lamina muscularis mucosae.** Layer of smooth muscle fibers between the lamina propria and submucosa. It acts upon the mucosa.
- 44 **Tela submucosa.** Mobile layer of collagen fibers and elastic meshlike tissue between the muscularis mucosae and the muscularis. It is the main conveyer of blood vessels.
- 45 **Tunica muscularis.** Double layer of smooth muscle.
- 46 **Stratum circulare.** Circular muscle layer.
- 47 **Stratum longitudinale.** Longitudinal muscle layer.
- 48 **Tunica serosa.** The smooth, glistening external surface of the intraperitoneal segments of the intestinal tract.

- 1 **Tela subserosa.** Connective tissue substrate for the serosal (peritoneal) epithelium.
- 2 **Parenchyma.** The essential functional elements of an organ.
- 3 **Stroma.** Supporting connective tissue framework of an organ.
- 4 **Gland.** Glandula.
- 5 **Lobe.** Lobus.
- 6 **Lobule.** Lobulus.
- 7 **Mucous gland.** Glandula mucosa.
- 8 **Serous gland.** Glandula serosa. Gland that secretes watery material.
- 9 **Seromucous gland.** Glandula seromucosa. Mixed gland that secretes watery mucous material.
- 10 **ANGIOLOGY.** Angiologia. Study of vessels.
- 11 **Arteriovenous anastomosis.** Anastomosis arterioloventularis (arteriovenosa). Direct connection between an artery and vein.
- 12 **Artery.** Arteria.
- 13 **Nutrient artery.** Arteria nutritica (nutriens). An artery that supplies tissues with nutrients.
- 14 **Arteriole.** Arteriola. Small artery directly preceding a capillary.
- 15 **Arterial circle.** Circulus arteriosus. Circle of anastomosing arteries.
- 16 **Circular connection of vessels.** Circulus vasculosus.
- 17 **Cistern.** Cisterna. Dilatation of a lymphatic vessel.
- 18 **Blood.** Haema (hema).
- 19 **Lymph.** Lympha.
- 20 **Nervi vasorum.** Nerves innervating the wall of blood vessels.
- 21 **Lymph node.** Nodus lymphaticus (lymphonodus).
- 22 **Lymphatic nodule (follicle).** Nodulus (folliculus) lymphaticus. Circular mass of lymphocytes.
- 23 **Lymphatic plexus.** Plexus lymphaticus.
- 24 **Vascular plexus.** Plexus vasculosus.
- 25 **Venous plexus.** Plexus venosus.
- 26 **Arterial plexus.** Plexus arteriosus.
- 27 **Rete mirabile.** Two capillary networks lying one after another.
- 28 **Rete vasculosum articulare.** Network of anastomosing blood vessels around a joint.
- 29 **Rete venosum.** Venous network.
- 30 **Sinus venosus.** Venous segment devoid of a typical venous wall.
- 31 **Tunica externa.** Outer layer of a blood vessel wall.
- 32 **Tunica intima.** Inner layer of a blood vessel wall.
- 33 **Tunica media.** Middle layer of a blood vessel wall.
- 34 **Valve.** Valva. Large flap.
- 35 **Lymphatic valve.** Valvula lymphatica. Valve in lymphatic vessels.
- 36 **Valve of veins.** Valvula venosa.
- 37 **Anastomotic vessel.** Vas anastomoticum.
- 38 **Capillary.** Vas capillare.
- 39 **Collateral vessel.** Vas collaterale. Vessel forming a shunt.
- 40 **Lymphatic vessel.** Vas lymphaticum.
- 41 **Sinusoid.** Vas sinusoideum. Special, thin-walled vascular segment with a large lumen.
- 42 **Vasa vasorum.** Blood vessels supplying the walls of blood vessels.
- 43 **Vein.** Vena.
- 44 **Accompanying vein.** Vena comitans.
- 45 **Cutaneous vein.** Vena cutanea.
- 46 **Emissary vein.** Vena emissaria. Vein passing through a foramen of the skull to the outside.
- 47 **Deep vein.** Vena profunda. Vein situated below the fascia.
- 48 **Superficial vein.** Vena superficialis. Cutaneous vein lying on the fascia of the limbs.
- 49 **Venule.** Venula. Small vein directly following a capillary.
- 50 **CENTRAL NERVOUS SYSTEM.** Systema nervosum centrale. It comprises the brain and spinal cord.
- 51 **Gray matter (nuclei and columns).** Substantia grisea [nuclei et columnae]. It consists of an accumulation of nerve cell bodies and is gray because only a sparse amount of medullary sheath material (myelin) is present in it.
- 52 **White matter.** Substantia alba [tractus et fasciculi]. It is present in the tracts and conduction bundles.
- 53 **Reticular formation.** Formatio (substantia) reticularis. Scarcely definable mixture of cells and fibers that influence movements, circulation and respiration as well as the sleeping-waking rhythm.
- 54 **Substantia gelatinosa.** Glia-rich, weakly pigmented zone near the apex of the posterior horn of the spinal cord. It serves afferent tracts.
- 55 **Ependyma.** Cellular lining of the cavities of the central nervous system.

- 1 **PERIPHERAL NERVOUS SYSTEM.** Pars peripherica (system nervosum periphericum). It begins at the surface of the brain and spinal cord.
- 2 **Nerve.** Nervus.
- 3 **Endoneurium.** Delicate connective tissue sheath attaching directly to the basal membrane of an individual nerve fiber.
- 4 **Perineurium.** Connective tissue sheath enclosing the bundles of fibers of a peripheral nerve. It consists of lamellae made of epithelioid connective tissue cells.
- 5 **Epineurium.** The connective tissue sheath covering a peripheral nerve.
- 6 **Afferent nerve fibers.** Neurofibrae afferentes. Nerve fibers traveling into the central nervous system.
- 7 **Efferent nerve fibers.** Neurofibrae efferentes. Nerve fibers that conduct impulses away from the central nervous system.
- 8 **Somatic nerve fibers.** Neurofibrae somaticae. They oppose the autonomic nerves, i.e., visceral nerves.
- 9 **Autonomic (visceral) nerve fibers.** Neurofibrae autonomicae (viscerales). Fibers of the visceral nerves.
- 10 **Ganglion.** An accumulation of nerve cell bodies and thus a macroscopic thickening of a nerve.
- 11 **Capsule of ganglion.** Capsula ganglii (ganglionica). It is composed of connective tissue.
- 12 **Stroma of ganglion.** Stroma ganglii (ganglionicum). Internal connective tissue of a ganglion.
- 13 **Craniospinal (sensory) ganglia.** Ganglia craniospinalia (encephalospinalia sensoria). Collective term for the following two special cases.
- 14 **Spinal ganglia (sensory).** Ganglia spinalia (sensoria). Dorsal root ganglia.
- 15 **Sensory ganglia of cranial nerves.** Ganglia sensoria neuricum cranialium (gg. encephalica). Spinal ganglia equivalent of cranial nerves.
- 16 **Autonomic (visceral) ganglia.** Ganglia autonómica (visceralia). Ganglia of visceral nerves.
- 17 **Preganglionic nerve fibers.** Neurofibrae praeganglionicae. Myelinated nerve fibers passing to the ganglia of the visceral nerves.
- 18 **Postganglionic nerve fibers.** Neurofibrae postganglionicae. Nonmyelinated nerve fibers passing from the visceral ganglia to the viscera.
- 19 **Sympathetic ganglion.** Ganglion sympatheticum (sympathicum). Represented mainly by the sympathetic trunk.
- 20 **White ramus communicans.** Ramus communicans alba. Connection between the spinal nerve and sympathetic trunk. It appears white on account of its myelinated preganglionic fibers.
- 21 **Gray ramus communicans.** Ramus communicans griseus. Connection between the sympathetic trunk and spinal nerve. It contains postganglionic, nonmyelinated fibers and therefore appears gray.
- 22 **Parasympathetic ganglion.** Ganglion parasympatheticum (parasympathicum). See pp. 338, 28–35.
- 23 **Spinal nerves.** Nervi spinales. They arise from the union of dorsal and ventral roots.
- 24 **Plexus of spinal nerves.** Plexus nervorum spinalium. It is present in the cervical, lumbar and sacral regions and gives rise to the nerves for the limbs.

- 1 **CRANIAL NERVES.** Nervi craniales (encephalici). They are characterized by the fact that they leave the cerebrospinal space through foramina in the base of the skull.
- 2 **Cranial nerve nuclei.** Nuclei nervorum cranialium (encephalicorum).
- 3 **Nuclei of origin.** Nuclei originis. They give rise to the efferent, mostly motor, nerve fibers.
- 4 **Nuclei of termination.** Nuclei terminationis. Sensory nuclei where the afferent nerve fibers terminate and synapse with a second neuron.
- 5 **Mixed nerve.** Nervus mixtus (n. mixtarum neurofibrarum). Considered to be a nerve containing both motor and sensory fibers; it can also refer to a nerve with somatic and visceral components.
- 6 **Cutaneous branches.** Rami cutanei. Cutaneous nerves or rami conducting impulses to the skin.
- 7 **Articular branches.** Rami articulares. Nerves or nerve rami conducting impulses to joints.
- 8 **Muscular branches.** Rami musculares. Nerves or nerve rami extending to the muscles.
- 9 **Motor nerve.** Nervus motorius. Nerve which only has fibers for muscles. Afferent fibers, e. g., from muscle spindles, are not considered when naming such nerves.
- 10 **Sensory nerve.** Nervus sensorius. Nerve containing afferent fibers which convey impulses to the central nervous system from peripheral receptors.
- 11 **Communicating branch.** Ramus communicans.
- 12 **Autonomic (visceral) nerve and ramus.** Nervus et ramus autonomici (viscerales). Nerves and their rami that conduct impulses from the region of nerve supply to the viscera.
- 13 **Autonomic (visceral) plexus.** Plexus autonomicus (visceralis). A plexus situated within an organ.
- 13a **Vascular plexus.** Plexus vascularis. Nerve plexus in the wall of vessels with sensory and autonomic components.
- 14 **Periarterial plexus.** Plexus periarteriales. Nerve plexus within the adventitia of arteries.
- 15 **Nervi vasorum.** Nerves supplying blood vessels.
- 16 **Vasa nervorum.** Blood vessels supplying nerves.
- 17 **NERVOUS TISSUE.** Textus nervosus.
- 18 **Neuron (nerve cell).** Neuron (neurocytus).
- 19 **Nerve cell body (perikaryon).** Corpus neurale. Portion of a neuron containing the nucleus but excluding the cell processes.
- 20 **Axon (axis cylinder).** Axon (neuritum). Usually a long process of a neuron which helps to form the peripheral nerves and can be either nonmyelinated or myelinated.
- 21 **Dendrite.** Dendritum. One of many tree-like branched processes of a neuron. In contrast to the axons, it has no special sheath.

References

- 1 Ahrens, G.: Naturwissenschaftliches und medizinisches Latein, 3. Aufl. Barth, Leipzig 1963
- 2 Alverdes, K.: Grundlagen der Anatomie, 3. Aufl. Edition Leipzig 1963
- 3 Arey, L.B.: Developmental Anatomy, 5th ed. Saunders, Philadelphia 1949
- 4 Bargmann, W.: Histologie und mikroskopische Anatomie des Menschen, 6. Aufl. Thieme, Stuttgart 1967; 7. Aufl. 1977
- 5 Benninghoff, A., K. Goertler: Lehrbuch der Anatomie des Menschen, 7. Aufl. Urban & Schwarzenberg, München 1964
- 6 Benninghoff, A.: Anatomie, 15. Aufl. Urban & Schwarzenberg, München 1994
- 7 Boyden, E.A.: Segmental Anatomy of the Lungs. Mc Graw-Hill, New York 1955
- 8 Braus, H., C. Elze: Anatomie des Menschen, 2. Aufl. Springer, Berlin 1960
- 9 Brodal, A.: Neurological Anatomy, 2nd ed. Oxford University Press, London 1969
- 10 Bucher, O.: Histologie und mikroskopische Anatomie des Menschen, 4. Aufl. Huber, Bern 1965
- 11 Bucher, O., H. Wartenberg: Cytologie, Histologie und mikroskopische Anatomie des Menschen, 12. Aufl. Huber, Bern 1997
- 12 Carpenter, B.M.: Human Neuroanatomy, 7th ed. Williams & Wilkins, Baltimore 1976
- 13 Clara, M.: Das Nervensystem des Menschen, 3. Aufl. Barth, Leipzig 1959
- 14 Corning, H.K.: Lehrbuch der Topographischen Anatomie, 20. und 21. Aufl. Bergmann, München 1942
- 15 Critchley, M.: Butterworths Medical Dictionary, 2nd ed. Butterworths, London 1980
- 16 Crosby, E.C., Tr. Humphrey, E.W. Lauer: Correlative Anatomy of the Nervous System. Macmillan, New York 1962
- 17 Cunningham, D.J.: Textbook of Anatomy, 11th ed. Oxford University Press, London 1972
- 18 Curtis, A., St. Jacobsen, E.M. Marcus. An Introduction to the Neurosciences. Saunders, Philadelphia 1972
- 19 Dauber, W.: Anatomische Grundlagen der Funktionsdiagnostik. In Siebert, G.K.: Atlas der zahnärztlichen Funktionsdiagnostik., 3. Aufl. Hanser Verlag, München 1996: 20–39
- 20 Denker, A., W. Albrecht: Lehrbuch der Krankheiten des Ohres und der Luftwege, 12. u. 13. Aufl. Fischer, Jena 1932
- 21 Donath, T.: Erläuterndes Anatomisches Wörterbuch. Terra, Budapest 1960
- 22 Duus, Peter: Neurologisch-topische Diagnostik. Thieme, Stuttgart 1976; 6. Aufl. 1995
- 23 Duvernoy, H.M.: Human Brainstem Vessels. Springer, Berlin 1978
- 24 Elias, H., D. Petty: Gross anatomy of the blood vessels and ducts within the human liver. Amer. J. Anat. 90 (1952) 59–111
- 25 Fasel, J.: The exit of the chorda tympani nerve through the external surface of the base of the skull. Acta Anat. 126 (1986) 205–207
- 26 Frick, H., H. Leonhardt, D. Starck: Taschenlehrbuch der gesamten Anatomie, Bd. I: Allgemeine Anatomie. Spezielle Anatomie I., 2. Aufl. Thieme, Stuttgart 1980; 4. Aufl. 1992
- 27 Georges, K.E.: Ausführliches lateinisch-deutsches Handwörterbuch. Hahnsche Buchhandlung, Hannover u. Leipzig 1913/1918
- 28 Gottschick, J.: Die Leistungen des Nervensystems. Fischer, Jena 1952
- 29 Gray, H.: Anatomy of the Human Body, 29th ed. Lea & Febiger, Philadelphia 1973
- 30 Gray's Anatomy, 36th ed. Churchill Livingstone, Edinburgh 1980. 38th ed. 1995
- 31 Guntz, M.: Nomenclature anatomique illustrée. Masson, Paris 1975
- 32 Hafferl, A.: Lehrbuch der topographischen Anatomie, 2. Aufl. Springer, Berlin 1957
- 33 Hamilton, W.J.: Textbook of Human Anatomy, Macmillan, London 1958
- 34 Hamilton, W.J., J.D. Boyd, H.W. Mossman: Human Embryology, 3rd. ed. Hefner, Cambridge 1962
- 35 Hjortsjö, C.-H.: The Anatomical Foundations of Liver Surgery. Karger, Basel
- 36 Hoff, H., G. Osler: Neurologie auf den Grundlagen der Physiologie. Maudrich, Wien 1957
- 37 Hollinshead, W.H.: Anatomy for Surgeons. Hoeber-Harper, New York 1961
- 38 Horstmann, E.: Die Haut. In Bargmann, W.: Handbuch der mikroskopischen Anatomie des Menschen, Bd. III/3. Springer, Berlin 1957
- 39 Kägi, J.: Beitrag zur Topographie der A. transversa colli. Eine Untersuchung an 134 Halshälften. Anat. Anz. 107 (1959) 168–186
- 40 Kahle, W., H. Leonhardt, W. Platzer: Taschenatlas der Anatomie, 3 Bde. 6. Aufl. Thieme, Stuttgart 1991
- 41 Kincaid, O.W.: Renal Angiography. Medical Publisher, Chicago 1966
- 42 Knese, K.H.: Nomina Anatomica, 5. Aufl. Thieme, Stuttgart 1957

- 43 Kolmer, W.: Gehörorgan. In Bargmann, W.: Handbuch der mikroskopischen Anatomie des Menschen, Bd. III/1. Springer, Berlin 1927
- 44 Krayenbühl, H., M. G. Yasargil: Zerebrale Angiographie für Klinik und Praxis, 3. Aufl. Thieme, Stuttgart 1979
- 45 Krieg, W.J.S.: Functional Neuroanatomy. Blakiston, Philadelphia 1942
- 46 Krüber, G.: Der Anatomische Wortschatz, 8. Aufl. Hirzel, Leipzig 1964
- 47 Kubik, S.: Klinische Anatomie Bd. III 2. Aufl. Thieme, Stuttgart 1969
- 48 Lazorthes, G.: Le système nerveux central, 2^{me} ed. Masson, Paris 1973
- 49 Lierse, W.: Becken. In v. Lanz Wachsmuth: Praktische Anatomie Bd. II/8a, Springer, Berlin 1984
- 50 Mac Nalty, A.S.: Butterworths Medical Dictionary. Butterworths, London 1965
- 51 Menge, H., O. Güthling: Großwörterbuch Altgriechisch, I. Teil: Altgriechisch-Deutsch, 29. Aufl. Langenscheidt, Berlin 1997
- 52 Menge, H., O. Güthling: Großwörterbuch Lateinisch, I. Teil: Lateinisch-Deutsch, 25. Aufl. Langenscheidt, Berlin 1996
- 53 Meyer, W.: Die Zahn-, Mund- und Kieferheilkunde. Urban & Schwarzenberg, München 1955–1960
- 54 Morris, J., J. Parsons, Schaeffer: Human Anatomy, 12th ed. Blakiston, Philadelphia 1966
- 55 Mühlreiter, E.: Anatomie des menschlichen Gebisses, 5. Aufl. Felix, Leipzig 1928
- 56 Mumenthaler, M., H. Schliack: Läsionen peripherer Nerven. Thieme, Stuttgart 1965, 6. Aufl. 1993
- 57 Netter, F.H.: The Ciba Collection of Medical Illustrations. Ciba, New York 1983–1997
- 58 Neubert, K.: Die Basilarmembran des Menschen und ihr Verankerungssystem. Z. Anat. Entwickl.-Gesch. 114 (1949/50) 539–588
- 59 Nomina anatomica, 4th ed. Excerpta Medica, Amsterdam 1977, 6th ed. Churchill-Livingstone, Edinburgh 1989
- 60 Oelrich, T.M.: The striated urogenital sphincter muscle in the female. Anat. Rec. 205 (1983)
- 61 Oliveros, L.G.: Veins of the Lungs, Salamanca 1959
- 62 Pape, W.: Griechisch-Deutsches Handwörterbuch, 3. Aufl. Braunschweig 1914
- 63 Paturet, G.: Anatomie Humaine. Bd. I, II, III. Masson, Paris 1958
- 64 Peele, T.L.: The Neuroanatomic Basis for Clinical Neurology. Mc Graw-Hill, New York 1977
- 65 Pernkopf, E.: Topographische Anatomie des Menschen. Urban & Schwarzenberg, München 1960
- 66 Pernkopf, E.: Atlas der topographischen und angewandten Anatomie des Menschen. 3. Aufl. Urban & Schwarzenberg, München 1994
- 67 Platzer, W.: Atlas der topographischen Anatomie. Thieme, Stuttgart 1982
- 68 Poirier, P., A. Charpy: D'anatomie humaine, 3^{me} ed. Masson, Paris 1920
- 69 Ranson, St. W., S. L. Clark: The Anatomy of the Nervous System, 10th ed. Saunders, Philadelphia 1964
- 70 Rauber, A., F. Kopsch: Lehrbuch und Atlas der Anatomie des Menschen, 19. Aufl. Thieme, Stuttgart 1955
- 71 Rauber, A., F. Kopsch: Anatomie des Menschen in 4 Bdn., Thieme, Stuttgart 1987–1997
- 72 Rohen, J.: Die funktionelle Gestalt des Auges und seiner Hilfsorgane. Verlag der Akademie der Wissenschaften und der Literatur, Mainz, Jg. 1953, Nr. 4
- 73 Rohen, J.W.: Topographische Anatomie. Schattauer, Stuttgart 1966, 9. Aufl. 1992
- 74 Rohen, J.W., F.J. Rentsch: Zur funktionellen Morphologie des Akkommodationsapparates. In: Neue Ergebnisse zur funktionellen Morphologie. Schattauer, Stuttgart 1969
- 75 Seeger, W.: Atlas of Topographical Anatomy of the Brain and Surrounding Structures, Springer, Wien 1978
- 76 Sicher, H.: Oral Anatomy 4th ed. Mosby, Saint Louis 1965
- 77 Sieglbauer, F.: Lehrbuch der normalen Anatomie des Menschen, 8. Aufl. Urban & Schwarzenberg, München 1958
- 78 Sobotta, J., H. Becher: Atlas der Anatomie des Menschen, 16. Aufl. Urban & Schwarzenberg, München 1962
- 79 Sobotta, J., H. Becher: Atlas der Anatomie des Menschen in 2 Bdn., Urban & Schwarzenberg, München 1993
- 80 Spalteholz, W., R. Spanner: Handatlas der Anatomie des Menschen, 16. Aufl. Scheltema & Holkema, Amsterdam 1961
- 81 Starck, D.: Embryologie, 2. Aufl. Thieme, Stuttgart, 1965, 3. Aufl. 1975
- 82 Stedman, Th. L.: Medical Dictionary, 20th ed. Williams & Wilkins, Baltimore 1961
- 83 Stephens, R. B., D. L. Stillwell: Arteries and Veins of the Human Brain. Thomas Springfield/III. 1969
- 84 Stieve, H.: Nomina Anatomica, 4. Aufl. Fischer, Jena 1949
- 85 Taber, Cl., W.: Cyclopedic Medical Dictionary, 9th ed. Blackwell, Oxford 1962

- 86 Tandler, J.: Lehrbuch der Systematischen Anatomie. Vogel, Leipzig 1926
- 87 Testut, L.: D'anatomie humaine, 4me ed. Paris 1900
- 88 Tondury, G.: Anatomie der Lungengefäße *Ergebn. ges. Tuberk.- u. Lung.-Forsch.* 14 (1958) 61–100
- 89 Töndury, G.: Angewandte und topographische Anatomie, 3. Aufl. Thieme, Stuttgart 1965, 5. Aufl. 1981
- 90 Toldt, C., F. Hochstetter: Anatomischer Atlas, 23. Aufl. Urban & Schwarzenberg, Wien 1961. 27. Aufl. Urban & Schwarzenberg, München 1979
- 91 Truex, R. C., M. B. Carpenter: Strong and Elwyn's Human Neuroanatomy, 5th ed. Williams & Wilkins, Baltimore 1964
- 92 Viamonte jr. M., Ruttimann: Atlas of Lymphography. Thieme, Stuttgart 1980
- 93 Villiger, E., E. Ludwig: Gehirn und Rückenmark, 11.–13. Aufl. Engelmann, Leipzig 1940
- 94 Voss, H., R. Herrlinger: Taschenbuch der Anatomie, 10. Aufl. Fischer, Stuttgart 1959
- 95 Waldeyer, A.: Anatomie des Menschen, 4. u. 5. Aufl. De Gruyter, Berlin 1967
- 96 Waldeyer, A., A. Mayert. Anatomie des Menschen. 16. Aufl. De Gruyter, Berlin 1993
- 97 Woerdemann, M. W.: Nomina anatomica Parisiensia (1955) et B. N. A. (1895). Oosthoek, Utrecht 1957
- 98 Wolf-Heidegger, G.: Atlas der systematischen Anatomie des Menschen. Karger, Basel 1957
- 99 Wolf-Heidegger, G.: Atlas der Human-Anatomie, 4. Aufl. Karger, Basel 1990
- 100 Wyburn, G. M.: The Nervous System. Academic Press, London 1960
- 101 Zenker, R., Heberer, H.-H. Löhr: Die Lungensektionen. Springer, Berlin 1954
- 102 Zöllner, F.: Anatomie, Physiologie, Pathologie und Klinik der Ohrtrompete. Springer, Berlin 1942

- A**
- Abdomen
 parietal lymph nodes 262.1
 visceral lymph nodes 262.13
- Abdominal
 aorta 216.19
 aortic plexus 348.10
 cavity 176.18
 muscles 86.1
 opening of uterine tube 166.30
 part
 of esophagus 120.5
 of pectoralis major 84.6
 of thoracic duct 254.21
 of ureter 156.20
 regions 400.1
 veins, subcutaneous 234.16
- Abducens nerve, nucleus 286.2
- Abducent nerve 326.18
- Aberrant ductules 160.7
 inferior 160.9
 superior 160.8
- Accessory
 carpal bone 40.3
 cephalic vein 244.22
 cuneate nucleus 280.18
 hemiazygos vein 246.4
 lacrimal glands 368.14
 nasal cartilages 134.29
 nerve 332.31
 trunk 332.34
 nodes 258.12
 nucleus of oculomotor nerve 292.29
 obturator
 artery 224.24
 nerve 342.30
 vein 250.24a
 organs of eye 364.1
 pancreas 128.30
 parotid gland 110.10
 phrenic nerves 336.11
 process 2.29
 ramus, middle meningeal
 artery 198.17
 sphenous vein 252.8
 spleen 268.2
 suprarenal glands 182.39
 thymic nodules 182.25
 thyroid glands 182.6
 vertebral
 vein 234.11
- Accompanying
 artery
 of median nerve 214.23
 of sciatic nerve 222.25
 vein 406.44
 of profunda femoris artery 252.9
- Acetabular
 branch
 medial circumflex femoral
 artery 226.7
 obturator artery 222.16
- Acetabular
 fossa 42.7
 ligament, transverse 66.27
 lip 66.26
 notch 42.8
- Acetabulum 42.5
 margin 42.6
- Achilles tendon 96.19
- Acoustic
 meatus
 external 16.3, 386.2
 cartilage 386.5
 cartilaginous part 386.4
 opening 16.4, 386.3
 internal 14.13, 378.5
 opening 14.12
 radiation 300.27, 318.23
- Acromial
 angle 34.12
 articular surface
 of clavicle 34.32
 of scapula 34.11
 branch
 axillary artery 212.13
 suprascapular artery 212.2
 end (clavicle) 34.31
 network 212.14
- Acromioclavicular
 joint 60.16
 ligament 60.17
- Acromion 34.10
- Adductor
 canal 98.17
 tubercle 46.23
- Adenohypophysis 182.14
- Adenoids 116.27
- Adhesio interthalamica 296.21
- Adipose body of ischioanal fossa 176.14
- Aditus
 ad antrum 380.10
 laryngis 142.24
 orbitalis 32.13
- Adrenal
 cortex 182.37
 gland 182.29
 anterior surface 182.30
 posterior surface 182.31
 renal surface 182.32
 medulla 182.38
- Aequator 354.18
- Afferent
 glomerular arteriole 156.5
 lymphatic vessels 254.24
 nerve fibers 407.6
- Agger nasi 136.18
- Aggregated lymphatic follicles (nodules) 122.33
 of vermiform appendix 124.24
- Air cells 384.17
 ethmoidal 20.7
- Ala(-ae)
 cristae galli 20.4
 lobuli centralis (cerebellum) 288.22
- Ala(-ae)
 major ossis sphenoidalis 10.23
 minor ossis sphenoidalis 10.19
 nasi 134.22
 ossis ilii 42.13
 sacralis 4.19
 vomeris 20.29
- Alar
 cartilage
 greater 134.25
 lesser 134.28
 folds 68.11
 ligaments 58.3
 part of nasal muscle 78.15
- Alcock's canal 176.15
- Alimentary canal 120.1
- Alveolar
 arch 24.9, 26.27
 artery
 anterior superior 200.2
 inferior 198.12
 posterior superior 198.28
 bone 112.17
 branches of infraorbital nerve
 anterior 324.5
 middle 324.4
 posterior 324.3
 canals 22.16
 ducts 152.3
 foramina 22.15
 jugula 24.13, 26.31
 nerve
 inferior 326.9
 superior 324.2
 part of mandible 26.26
 process 24.8
 sacs 152.4
- Alveoli
 dentales 24.10, 26.28
 pulmonis 152.5
- Alveus 314.18
- Ambient cistern 270.9
- Amiculus olivare 280.29
- Ampulla(-ae) 124.3
 canaliculi lacrimales 368.20
 ductus deferentis 160.14
 diverticula 160.15
 hepatopancreatica 134.14
 membranaceae 370.18
 anterior 370.19
 lateral 370.21
 posterior 370.20
 osseae 376.10
 anterior 376.11
 lateral 376.13
 posterior 376.12
 recti 126.16
 tubae uterinae 166.34
- Ampullar
 nerve
 anterior 330.10
 lateral 330.11
 posterior 330.13
- Ampullary
 crest 370.23

- Ampullary**
 membranous crura 370.28
 osseous crura 376.17
- Amygdaloid body** 318.1
- Anal**
 canal 126.24
 columns 126.25
 pecten 126.29
 region 400.16
 sinuses 126.26
 sphincter
 external 126.31
 internal 126.20
 valves 126.27
- Anastomosis arteriovenularis (arteriovenosa)** 406.11
- Anastomotic**
 atrial branch of left coronary artery 192.22
 branch
 lacrimal artery 202.4
 superior tympanic artery 198.23
 vein
 inferior 240.20
 superior 240.19
 vessel 406.37
- Angiology (angiologia)** 406.10
- Angle, of rib** 6.16
- Angular**
 artery 196.14
 branch, occipital artery 196.17
 gyrus 208.9
 ligament, of stapes 382.29
 notch 120.20
 spine of sphenoid 10.38
 vein 236.6
- Angulus**
 acromialis 34.12
 costae 6.16
 frontalis 16.35
 inferior (scapula) 34.17
 infrasternalis 6.41
 iridocornealis 360.16
 lateralis (scapula) 34.18
 mandibulae 28.2
 mastoideus 16.38
 occipitalis 16.36
 oculi
 lateralis 366.11
 medialis 366.12
 oris 108.11
 sphenoidalis 16.37
 sterni (sternalis) 6.27
 subpubicus 44.23
 superior (scapula) 34.19
- Ankle** 400.23
 bone 50.3
 joint 70.1
- Annular**
 ligament
 of the radius 62.7
 of trachea 144.22
 part of fibrous sheath 92.28, 100.23
- Anococcygeal**
 ligament 174.12
 nerves 346.26
- Anocutaneous line** 126.30
- Anorectal**
 line 126.28
 lymph nodes 266.12
- Ansa**
 cervicalis 334.23
 thyrohyoid branch 334.26
 hypoglossi 334.23
 lenticularis 302.9
 nucleus of 302.15
 peduncularis 302.10
 subclavia 352.9
- Anserine bursa** 106.1
- Antebrachial**
 fascia 92.20
 median vein 244.25
 region
 anterior 400.30
 posterior 400.31
- Antebrachium** 400.29
- Anterior** 396.13, 396.15
 ampullar nerve 330.10
 amygdaloid area 318.2
 antibrachial region 400.30
 arch of atlas 4.5
 articular surface of dens 4.14
 ascending branch
 left pulmonary artery 190.33
 right pulmonary artery 190.18
- atlanto-occipital**
 ligament 56.28
 membrane 56.27
- auricular**
 branches, transverse facial artery 198.4
 ligament 388.11
 nerves 324.29
 veins 236.27
- axillary line** 396.52
- basal**
 branch
 left inferior pulmonary vein 232.10
 left pulmonary artery 190.40
 right pulmonary artery 190.26
 root 230.23
 segment
 of lower lobe of left lung 150.25
 of lower lobe of right lung 150.13
 segmental bronchus 146.13, 146.25
 border, radius 38.10
 brachial region 400.21
 branch(-es)
 cutaneous 344.3
 iliohypogastric nerve 342.17
 gluteal nerve 342.12
- Anterior**
 branch(-es)
 great auricular nerve 334.30
 left superior pulmonary vein 230.32
 lumbar nerves 342.6
 medial antebrachial cutaneous nerve 338.6
 obturator
 artery 222.17
 nerve 342.26
 portal vein of liver 248.3
 renal artery 220.19
 spinal nerve 334.9, 334.21
 superior
 mesenteric artery 220.2a
 right pulmonary vein 230.8
 ulnar recurrent artery 214.16
 calcaneal facet 50.15
 carpal region 400.35
 cecal artery 220.7
 cerebral
 artery 204.1, 208.14
 veins 240.23
 cervical lymph nodes 256.17
 chamber of eye 360.15
 choroidal artery 202.22
 ciliary
 arteries 202.9
 veins 244.2
 circumflex
 humeral artery 212.23
 scapular vein 244.13a
 clinoid process 10.21
 cochlear nucleus 282.17
 column 274.17
 of rugae 170.15
 commissure 312.20, 318.30
 communicating artery 204.6, 208.15
 conjunctival arteries 202.10
 corticospinal tract 276.22
 cranial fossa 30.2
 cruciate ligament of knee 68.8
 cubital region 400.24
 cusp
 atrioventricular valve 188.27
 pulmonary valve 188.4
 cutaneous branch, intercostal nerve 340.24
 deep temporal artery 198.25
 descending branch
 left pulmonary artery 190.31
 right pulmonary artery 190.17
 divisions, brachial plexus 336.17
 end of spleen 268.9
 epithelium of cornea 356.7
 ethmoidal
 artery 202.15
 foramen 32.21
 nerve 322.5
 external
 arcuate fibers 278.24, 282.23
 vertebral venous plexus 246.17

Anterior

facet for the talus 52.1
 fasciculi proprii 276.20
 fontanelle 32.28
 funiculus 274.2, 276.19
 gastric branches, vagal trunk 332.26
 glandular branch, superior thyroid artery 194.15
 gluteal line 42.26
 gray commissure 276.16a
 horn 274.18, 314.4
 hypothalamic nucleus 302.20
 inferior cerebellar artery 206.18
 intercondylar area 46.32
 intercostal
 branches, internal thoracic artery 210.10
 veins 234.18
 intermuscular septum of leg 100.9
 internal vertebral venous plexus 246.18
 interosseous
 artery 214.22
 nerve of forearm 338.11
 veins 244.19a
 interventricular
 branch, left coronary artery 192.17
 groove 184.18
 vein 232.16
 intraoccipital synchondrosis 56.6
 jugular
 lymph nodes 256.18
 vein 238.4
 labial
 branches, external pudendal arteries 224.34
 commissure 170.27
 nerves 342.20
 veins 252.6
 lacrimal crest 22.26
 ligament
 of head of fibula 68.21
 of malleus 382.23
 limb of internal capsule 318.8
 limiting membrane 356.8
 lingual glands 108.37
 lip of uterine ostium 168.19
 lobe of cerebellum 288.18
 longitudinal ligament 56.19
 lymph nodes 258.5, 258.10
 malleolar fold 384.6, 389.24
 margin
 fibula 48.25
 lung 148.17
 radius 38.13
 testis 158.21
 tibia 48.8
 ulna 38.30
 median
 fissure 272.19, 278.18
 line 396.47

Anterior

mediastinal lymph nodes 260.9
 mediastinum 152.27
 membranous ampulla 370.19
 meningeal branch
 anterior ethmoidal artery 202.16
 vertebral artery 206.9
 meniscofemoral ligament 68.3
 nasal spine 22.12
 notch 386.24
 nucleus(-i)
 of thalamus 198.13
 of trapezoid body 286.15
 obturator tubercle 44.18
 osseous ampulla 376.11
 palpebral surface 366.5
 papillary muscle 188.16, 190.8
 paraventricular nuclei 198.18
 parietal
 arteries 204.33
 peritoneum 180.12
 part
 of anterior commissure 318.31
 of fornix of vagina 170.3
 of midbrain 290.29
 of pons 284.8
 of tongue 112.32
 perforated substance 212.2
 pole 354.16
 of lens capsule 362.17
 pontomesencephalic vein 242.14
 process, malleus 380.17
 radicular artery 216.10d
 ramus, lateral sulcus 306.18
 recess of tympanic membrane 384.8
 region of hypothalamus 302.16
 root 334.5
 sacral foramina 4.27
 sacrococcygeus muscle 88.3
 scalene muscle, tubercle 6.18
 scrotal
 branches, external pudendal arteries 224.33
 nerves 342.19
 veins 252.6
 segment
 of kidney
 lower 154.19
 upper 154.18
 of liver 130.19
 of upper lobe of left lung 150.18
 of upper lobe of right lung 150.5
 segmental
 artery 218.7
 bronchus 146.5, 146.18
 semicircular
 canal 376.7
 duct 370.12
 semilunar cusp of pulmonary valve 188.11

Anterior

septal branches of anterior ethmoidal
 artery 202.16a
 side of knee 402.9
 sinus 138.6
 spinal
 artery 206.11
 veins 246.20a
 spinocerebellar tract 278.3
 spinothalamic tract 276.25
 sternoclavicular ligament 60.24
 superior
 alveolar arteries 200.2
 alveolar branches, infraorbital nerve 324.5
 pancreaticoduodenal artery 218.22
 surface
 of adrenal gland 182.30
 of cornea 356.5
 of iris 358.4
 of kidney 154.8
 of lens 362.19
 of lower leg 402.13
 of maxilla 22.8
 of prostate 162.13
 of scapula 34.4
 of stomach 120.16
 of ulna 38.26
 talocrural region 402.16
 talofibular ligament 70.8
 temporal
 artery 204.26
 branches, lateral occipital artery 208.3
 diploic vein 238.26
 thalamic radiations 302.1, 318.9
 thigh region 402.5
 tibial
 artery 226.22
 node 266.21
 recurrent artery 226.24
 veins 252.16
 tibiofibular ligament 68.25
 tibiotalar part, medial (deltoid) ligament 70.5
 triangle of neck 398.23
 tubercle 2.19
 of atlas 4.7
 of calcaneus 50.26
 of thalamus 296.22
 tympanic artery 198.11
 vagal trunk 332.24
 vein
 of right ventricle 232.22
 of septum pellucidum 242.5
 ventral nucleus 300.4
 vertebral vein 234.10
 wall of vagina 170.6
 white commissure 276.18
 Anteroventral nucleus, thalamus 298.15

- Anterodorsal nucleus, thalamus 298.14
 Anterolateral
 central arteries 204.20
 fontanelle 32.30
 nucleus 274.19
 sulcus 272.22, 278.21
 surface
 arytenoid cartilage 140.13
 humerus 36.13
 Anteromedial
 central arteries 204.3, 208.16
 frontal branch, callosomarginal artery 204.11
 nucleus 274.20
 thalamus 298.16
 surface (humerus) 36.13
 thalamostriate arteries 204.3
 Antihelix (anthelix) 386.15
 crura 386.17
 fossa 388.6
 transverse sulcus 388.4
 Antitragus 386.22
 Antrum
 mastoideum 380.9
 pyloricum 120.28
 Anulus
 conjunctivae 356.2
 femoralis 100.1
 fibrocartilagineus 380.30
 fibrosus 56.11
 dexter/sinister 186.6
 inguinalis
 profundus 86.29
 superficialis 86.14
 iris
 major 358.6
 minor 358.7
 lymphaticus cordiae 262.16
 tendineus communis 364.9
 tympanicus 16.2
 umbilicalis 86.23
 Anus 126.32
 Aorta 192.3
 abdominal 216.19
 arch 194.1
 ascending 192.4
 bifurcation 222.5
 bulb 192.5
 ostium 184.31
 Aortic
 hiatus 84.29
 lymph nodes, lateral 262.3
 sinus 192.6
 valve 190.2
 left semilunar cusp 190.5
 posterior semilunar cusp 190.3
 right semilunar cusp 190.4
 Aortic plexus
 abdominal 348.10
 thoracic 348.4
 Aorticorenal ganglia 348.13
 Apertum ductus nasolacrimalis 136.23a
 Apertura
 externa
 aquaeductus
 cochleae 372.14
 vestibuli 14.16
 canaliculi cochleae 14.22
 inferior 88.23
 lateralis (ventriculi quarti) 288.10
 mediana (ventriculi quarti) 288.9
 pelvis (pelvica)
 inferior 44.28
 superior 44.27
 piriformis (nasalis anterior) 32.3
 sinus
 frontalis 18.29
 sphenoidalis 10.17
 superior 88.23
 thoracis
 inferior 6.37
 superior 6.36
 tympanica canaliculi chordae tympani 380.16
 Apex
 auricularis 386.27
 capitis fibulae 48.18
 cartilagineus arytenoidea 140.21
 of cochlea 376.19
 cordis 184.16
 cuspidis 110.15
 dentis 4.13
 linguae 112.37
 nasi 134.21
 ossis sacri 4.36
 partis petrosae 12.25
 patellae 48.33
 posterior horn 276.3
 prostatae 162.12
 pulmonis (pulmonalis) 148.9
 radicis dentis 110.22
 vesicae (vesicalis) 156.26
 Apical 396.24
 branch
 to inferior lobe of right pulmonary artery 190.23
 left pulmonary artery 190.30
 right pulmonary artery 190.15
 superior right pulmonary vein 230.5
 foramen, of root of tooth 112.4
 ligament of dens 58.4
 lymph nodes 258.17
 segment of upper lobe of right lung 150.3
 segmental bronchus 146.3
 Apicalis 396.24
 Apicoposterior
 branch of pulmonary vein 230.29
 segment of upper lobe of left lung 150.17
 segmental bronchus 146.17
 Aponeurosis 405.23
 epicranialis 78.11
 glutealis 94.8a
 lingualis 114.17
 m. bicipitis brachii (bicipitalis) 88.16
 palatina 116.18
 palmaris 92.24
 plantaris 100.17
 Apophysis anularis 2.3b
 Apparatus
 digestorius 108.1
 lacrimalis 368.9
 respiratorius 134.17
 urogenitalis 154.1
 Appendicular
 artery 220.9
 lymph nodes 264.7
 skeleton 402.40
 vein 248.26
 Appendix(-ces)
 epididymidis 160.11
 epiploicae (omentalis) 124.34
 fibrosa hepatis 130.14
 testis 160.10
 ventriculi laryngis 144.2
 vermiformis 124.22
 vesiculosae 170.20
 Approximal surface, tooth 110.27
 Aquaeductus
 cochleae 372.13
 mesencephali (cerebri) 292.20
 vestibuli 14.15
 apertura externa 14.16
 Aqueous humor 360.17, 362.2
 Arachnoid granulations 270.12
 Arachnoidea mater
 cranialis (encephali) 270.1
 spinalis 270.13
 Arbor
 bronchialis 144.29
 vitae (cerebelli) 290.10
 Archaeocortex 314.20
 Archicerebellum (archaeocerebellum) 290.6
 Archicortex 314.20
 Archipallium 314.20
 Arcuate
 artery(-ies) 156.3
 of foot 228.4
 crest 140.15
 eminence 14.3
 fibers
 anterior external 278.24, 282.23
 cerebrum 316.14
 externae posteriores 282.24
 ligament
 lateral 84.34
 medial 84.33
 median 84.35
 line 42.14, 86.7
 nucleus 282.22, 302.22, 304.5

Arcuate
 palpebrales
 inferior 202.19
 superior 202.18
 plantaris
 profundus 228.22
 superficialis 228.26a
 popliteal ligament 68.15
 pubic ligament 66.17
 veins 156.11

Arcus
 alveolaris 24.9, 26.27
 anterior atlantis 4.5
 aortae 194.1
 cartilagineus cricoideae 140.2
 costalis 6.39
 dentalis
 inferior 112.19
 superior 112.18
 ductus thoracici 254.18
 ilipectineus 98.21
 inguinalis 86.10
 palatoglossus 116.6
 palatopharyngeus 116.7
 palmaris
 profundus 214.11
 superficialis 214.27
 posterior atlantis 4.8
 pubis 44.22
 superciliaris 18.5
 tendineus 405.28
 fasciae pelvis 174.27
 musculi
 levatoris ani 174.11
 solei 96.18
 venae azygos 246.1a
 venosus
 dorsalis pedis 252.18
 jugularis 238.5
 palmaris
 profundus 244.32
 superficialis 244.30
 plantaris 252.24
 vertebrae (vertebrales) 2.4
 zygomatikus 30.12

Area(-ae)
 amygdaloidea, anterior 318.2
 cochleae 378.10
 contingens 110.29a
 cribrosa 154.34
 gastricae 122.14
 intercondylaris
 anterior 46.32
 posterior 46.33
 nervi facialis 378.9
 nuda 128.29
 postrema 286.34
 preoptica 296.31
 prepectalis 296.14
 retro-olivaris 278.26
 subcallosa 312.4
 vestibularis 286.26
 inferior 378.13
 superior 378.12

Areola mammae 394.27

Areolar
 glands (of Montgomery)
 394.28
 venous plexus 244.16

Arteria(-ae) 190.10, 406.12
 alveolaris
 inferior 198.12
 superior
 anterior 200.2
 posterior 198.28
 angularis 196.14
 appendicularis 220.9
 arcuata(-ae) 156.3
 of foot 228.4
 ascendens 220.12a
 auricularis
 posterior 196.22
 profunda 198.10
 axillaris 212.9
 azygoi vaginae 224.3
 basilaris 206.17
 brachialis 212.25
 superficialis 212.26
 buccalis 198.27
 bulbi
 penis 224.14
 vestibuli 224.15
 caecalis
 anterior 220.7
 posterior 220.8
 callosomarginalis 204.10
 canalis pterygoidei 200.4
 capsulares 220.17a
 caroticotypanicae 200.14
 carotis
 communis 194.6
 externa 194.9
 interna 200.10, 208.13
 caudae pancreatis 218.30
 centralis(-es)
 anterolaterales 204.20
 anteromedialis 204.3, 208.16
 brevis 204.4
 longa 204.5
 posterolaterales 206.27
 posteromediales 206.25
 retinae 202.2

cerebri
 anterior 204.1, 208.14
 media 204.18, 208.17
 posterior 206.23, 208.24

cervicalis
 ascendens 210.20
 profunda 212.4
 choroidea, anterior 202.22
 ciliares
 anteriores 202.9
 conjunctivales
 anteriores 202.10
 posteriores 202.11
 posteriores
 breves 202.6
 longae 202.7

circumflexa
 anterior humeri 212.23

Arteria(-ae)
 circumflexa
 femoris
 lateralis 226.8
 medialis 226.3
 iliaca
 profunda 224.27
 superficialis 224.31
 posterior humeri 212.24
 scapulae 212.22

colica
 dextra 220.10
 media 220.11
 sinistra 220.13

collateralis
 media 212.30
 radialis 212.31
 ulnaris
 inferior 212.33
 superior 212.32

combitans
 nervi ischiadici 222.25
 nervi mediani 214.23

communicans
 anterior 204.6, 208.15
 posterior 208.18

coronaria
 dextra 192.7
 sinistra 192.16
 cremasterica 224.25
 cystica 218.5
 descendens genicularis 226.1a
 digitales
 dorsales 214.8, 228.6
 palmares
 communes 214.28
 propriae 214.29
 plantares
 communes 228.25
 propriae 228.26

dorsalis
 clitoridis 224.19
 nasi 202.21
 pedis 228.1
 penis 224.17
 scapulae 210.24a
 ductus deferentis 222.27

epigastrica
 inferior 224.21
 superficialis 224.30
 superior 210.12

episclerales 202.12
 ethmoidalis
 anterior 202.15
 posterior 202.14

facialis 196.7
 femoralis 224.29
 fibularis 228.12
 flexura, dextra 220.10a
 frontobasalis
 lateralis 204.25
 medialis 204.9

gastrica
 dextra 218.3
 sinistra 216.29

Arteria(-ae)

gastrici
 breves 218.34
 posterior 218.35a
 gastro-omentalis
 dextra 218.19
 sinistra 218.31
 gastroduodenalis 218.13
 glutealis
 inferior 222.24
 superior 222.19
 gyri, angularis 204.34
 helicinae 164.18
 hepatica
 communis 218.1
 propria 218.2
 hyaloidea 362.5
 hypophysialis
 inferior 200.23
 superior 200.25
 ileales 220.4
 ileocolica 220.5
 iliaca
 communis 222.6
 externa 224.20
 interna 222.7
 iliolumbalis 222.8
 inferior
 anterior cerebelli 206.18
 lateralis genus 226.18
 medialis genus 226.19
 posterior cerebelli 206.12
 infraorbitalis 200.1
 insulares 204.24
 intercostalis(-es)
 posterior 212.6
 posteriores 216.8
 suprema 212.5
 interlobares 156.2
 interlobulares 132.3, 156.4
 intermesenterica 220.12a
 interossea
 anterior 214.22
 communis 214.19
 posterior 214.20
 recurrens 214.21
 jejunales 220.3
 labialis
 inferior 196.12
 superior 196.13
 labyrinth 374.11
 labyrinthi 206.19
 lacrimalis 202.3
 laryngea superior 194.13
 laryngealis inferior 210.15
 lienalis 218.25
 ligamenti teretis uteri 224.26
 lingualis 196.1
 lobi caudati 218.6, 218.10
 lumbales 216.22
 imae 216.26
 malleolaris anterior
 lateralis 226.25
 medialis 226.26
 marginalis coli 220.11a

Arteria(-ae)

masseterica 198.24
 maxillaris 198.9
 media genus 226.16
 medullaris segmentalis 216.10e
 meningea
 media 198.16
 mediae sulcus 16.26b
 posterior 194.18
 mesencephalicae 206.21
 mesenterica
 inferior 220.12
 superior 220.1
 metacarpales
 dorsales 214.7
 palmares 214.12
 metatarsales, plantares 228.23
 musculophrenica 210.11
 nasales posteriores laterales
 200.9
 nasi externa 202.21
 nutriens (nutricia) 406.13
 fibulae 228.17a
 tibialis 228.11a
 nutrients (nutriciae)
 femoris 226.12a
 humeri 212.28
 obturatoria 222.14
 accessoria 224.24
 occipital sulcus 12.20
 occipitalis 196.15
 lateralis 208.2
 medialis 208.6
 ophthalmica 202.1
 ovarica 222.3
 palatina
 ascendens 196.8
 descendens 200.5
 major 200.6
 minores 200.7
 palpebrales
 laterales 202.5
 mediales 202.17
 pancreatica
 dorsalis 218.27
 magna 218.29
 pancreaticoduodenalis
 inferior 220.2
 superior
 anterior 218.22
 posterior 218.15
 paracentralis 204.15
 parietales
 anterior 204.33
 posterior 204.33
 parieto-occipitalis 204.17
 pericardiophrenica 210.5
 perinealis 224.10
 pharyngea, ascendens 194.17
 phrenica(-ae)
 inferior 216.20
 superiores 216.7
 plantaris
 lateralis 228.21
 medialis 228.18

Arteria(-ae)

plantaris
 profunda 228.7
 pontis 206.20
 poplitea 226.13
 praepancreatica 218.28a
 precunealis 204.16
 princeps pollicis 214.9
 profunda
 brachii 212.27
 clitoridis 224.18
 femoris 226.2
 linguae 196.5
 penis 224.16
 pterygomeningea 198.23a
 pudenda(-ae)
 externae 224.32
 interna 224.8
 pulmonalis
 dextra 190.14
 sinistra 190.29
 radialis 214.1
 indicis 214.10
 radicularis
 anterior 216.10d
 posterior 216.10c
 rectalis
 inferior 224.9
 media 224.7
 superior 220.15
 recurrens 204.5
 radialis 214.2
 tibialis
 anterior 226.24
 posterior 226.23
 ulnaris 214.15
 renalis(-es) 156.1, 220.17
 retroduodenales 218.18
 sacralis(-es)
 laterales 222.12
 mediana 216.25
 segmenti
 anterioris 218.7
 inferioris 220.22
 superioris 220.21
 inferioris 220.23
 medialis 218.11
 posterioris 218.8, 220.25
 superioris 220.20
 sigmoidea 220.14
 sphenopalatina 200.8
 spinalis
 anterior 206.11
 posterior 206.16
 splenica 218.25
 stylo mastoidea 196.23
 subclavia(-ae) 206.1
 sulcus 6.19
 subcostalis 216.16
 sublingualis 196.3
 submental is 196.10
 subscapularis 212.20
 sulci
 centralis 204.30
 postcentralis 204.32

- Arteria(-ae)
 sulci
 precentralis 204.31
 superior
 cerebelli 206.22
 lateralis genus 226.14
 medialis genus 226.15
 supraduodenalis 218.14
 supraorbitalis 202.13
 suprarenalis(-es)
 inferior 220.18
 media 220.16
 superiores 216.21
 suprascapularis 212.1
 supratrochlearis 202.20
 surales 226.17
 tarsalis(-es)
 dorsales 228.5
 lateralis 228.2
 mediales 228.3
 temporalis
 anterior 204.26
 media 198.6, 204.27
 sulcus 16.15
 posterior 198.25a, 204.28
 profunda anterior 198.25
 superficialis 198.1
 testicularis 222.1
 thalamostriatae
 anterolaterales 204.20
 anteromediales 204.3
 thoracica
 interna 210.1
 lateralis 212.18
 superior 212.11
 thoracicoacromialis 212.12
 thoracodorsalis 212.21
 thyroidea
 ima 194.5
 inferior 210.14
 superior 194.10
 tibialis
 anterior 226.22
 posterior 228.8
 transversa
 cervicis 210.22
 faciei (facialis) 198.3
 tympanica
 anterior 198.11
 inferior 194.20
 posterior 196.24
 superior 198.19
 ulnaris 214.14
 umbilicalis 222.26
 urethralis 224.13
 uterina 224.2
 vaginalis 224.6
 vertebralis 206.2
 sulcus 4.9
 vesicalis(-es)
 inferior 224.1
 superiores 222.29
 zygomatico-orbitalis 198.5
- Arterial
 circle 406.15
- Arterial
 glomeruli of cochlea 374.14
 grooves 30.8
 plexus 406.26
- Arteriola(-ae) 406.14
 glomerularis
 afferens 156.5
 efferens 156.6
 macularis
 inferior 360.13
 superior 360.12
 medialis retinae 360.14
 nasalis retinae
 inferior 360.11
 superior 360.10
 rectae 156.8
 temporalis retinae
 inferior 360.9
 superior 360.8
- Arteriole 406.14
 Arteriovenous anastomosis 406.11
- Artery(-ies) 190.10, 406.12
 of angular gyrus 204.34
 of bulb
 of penis 224.14
 of vestibule 224.15
 to caudate lobe 218.6, 218.10
 of central sulcus 204.30
 of ductus deferens 222.27
 of postcentral sulcus 204.32
 of precentral sulcus 204.31
 to right colic flexure 220.10a
 of round ligament of uterus
 224.26
- Arthrology (arthrologia) 404.11
- Articular
 branch(-es) 408.7
 descending genicular artery
 226.1c
 capsule of cricoarytenoid joint
 140.24
 carpal surface (radius) 38.17
 cartilage 404.33
 cavity 404.34
 circumference
 radius 38.4
 ulna 38.33
 corpuscles 390.27
 disc (disk) 60.3, 60.18, 60.23,
 62.13, 404.35
 facet
 of costa tubercle 6.15
 for fibula 46.31
 inferior 4.4
 superior 4.3
 fovea 38.3
 genus (genualis) 66.1
 ligaments 404.44
 lip 404.37
 muscle 405.14
 network
 of elbow 214.18
 of the knee 226.20
 process
 inferior 2.15
- Articular
 process
 superior 2.14, 4.20
 surface
 for arytenoid cartilage 140.4
 of arytenoid cartilage 140.11
 of clavicle 34.27
 acromial 34.32
 of dens
 anterior 4.14
 posterior 4.15
 of malleolus 48.12, 48.28
 of scapula, acromial 34.11
 for thyroid cartilage 140.5
 of tibia
 inferior 48.14
 superior 46.28
 tubercle 16.22
 veins 236.29
- Articulatio(-nes)
 acromioclavicularis 60.16
 atlanto-axialis
 lateralis 58.1
 mediana 58.2
 atlanto-occipitalis 56.26
 bicondylaris 404.29
 calcaneocuboidea 70.17
 capitis costae (costales) 58.11
 carpi 62.15a
 carpometacarpales 64.7
 pollicis 64.10
 cartilagineae 404.19
 cinguli
 pectoralis 60.12
 pelvici 66.1
 columnae vertebrales 56.8
 composita (complexa) 404.24
 condylar 404.27
 costochondrales 58.28
 costotransversaria 58.14
 costovertebrales 58.10
 cotylica 404.26
 coxae 66.20
 cranii 56.8
 cricoarytenoidea 140.23
 cricothyroidea 140.6
 cubiti (cubitalis) 62.1
 cuneocuboidea 70.17a
 cuneonavicularis 70.18
 ellipsoidea 404.27
 fibrosae 404.12
 humeri (glenohumeralis) 60.29
 humeroradialis 62.3
 humeroulnaris 62.2
 iliofemoralis 66.20
 incudomallearis 382.19
 incudostapedialis 382.20
 intercarpales 62.16
 interchondrales 58.27
 intercuneiformes 70.18a
 intermetacarpales 64.11
 intermetatarsales 72.13
 interphalangeales
 manus 64.20
 pedis 72.22

- Articulatio(-nes)
 intertarsae 70.10
 laryngeales 138.13
 lumbosacralis 66.4
 manus 64.1
 mediocarpalis 62.17
 membri
 inferioris liberi 66.19
 superioris liberi 60.28
 metacarpophalangeales 64.16
 metatarsophalangeales 72.18
 ossiculorum auditorium 380.18
 ossis pisiformis 64.3
 ovoidalis 404.32
 pedis 70.11
 plana 404.25
 radiocarpalis 62.15
 radioulnaris 62.9
 distalis 62.12
 proximalis 62.4
 sacrocoecygea 56.21
 sacroiliaca 66.11
 simplex 404.23
 sphaeroidea 404.26
 stellaris 404.31
 sternoclavicularis 60.22
 sternocostales 58.20
 subtalaris 70.13
 synoviales 404.22
 cranii 60.1
 talocalcaneonavicularis 70.12
 talocruralis 70.1
 tarsi transversa 70.16
 tarsometatarsales 72.9
 temporomandibularis 60.2
 thoracic 56.8, 58.9
 tibiofibularis 68.20, 68.23
 trochoidea 404.30
 zygapophysiales 56.14
- Aryepiglottic
 fold 142.25
 part of oblique arytenoid
 muscle 142.21a
- Arytenoid
 cartilage 140.10
 apex 140.21
 articular surface for 140.4
 base 140.12
 muscle
 oblique 142.21
 transverse 142.22
- Ascending
 aorta 192.4
 branch
 deep circumflex iliac artery
 224.28
 lateral circumflex femoral
 artery 226.9
 medial circumflex femoral
 artery 226.5
 transverse cervical artery
 210.23a
 cervical artery 210.20
 colon 124.26
 intermesenteric artery 220.12a
- Ascending
 lumbar vein 246.10
 palatine artery 196.8
 part of duodenum 124.6
 pharyngeal artery 194.17
 ramus, lateral sulcus 306.18
 Association neurofibers 318.33
- Asterion 30.10b
- Atlantal part of vertebral artery
 206.7
- Atlanto-axial joint
 lateral 58.1
 median 58.2
- Atlanto-occipital
 joint 56.26
 membrane
 anterior 56.27
 posterior 56.29
- Atlas 4.1
 anterior
 arch 4.5
 tubercle 4.7
 dental fovea 4.6
 lateral mass 4.2
 posterior arch 4.8
- Atrial
 branches
 left coronary artery 192.27a
 right coronary artery 192.9a
 veins
 left 232.24
 right 232.24
- Atrioventricular
 branches
 left coronary artery 192.22a
 right coronary artery 192.7a
 bundle 186.10
 groove 184.20
 node 186.9
 branch, left coronary artery
 192.27
 opening, right 188.2
 septum 184.25
 valve
 left 188.26
 right 188.3
 veins 232.26
- Atrium
 auricle 184.27
 cordis 184.26
 dextrum 186.14
 meatus medii 136.22
 sinistrum 188.20
- Auditory
 meatus *see* Acoustic meatus
 ossicles 382.1
 articulations 380.18
 ligaments 382.22
 muscles 384.1
 teeth 372.27
 tube 384.13
 glands 384.24
 groove 10.39
 osseous part 384.15
 pharyngeal opening 118.2
- Auditory
 tube
 semicanal 12.30
 tympanic ostium 384.14
- Auerbach's plexus 350.5
- Auricle 386.8
 apex 386.27
 concha 386.19
- Auricula 386.8
 atrialis 184.27
 dextra 186.22
 sinistra 188.21
- Auricular
 artery
 deep 198.10
 posterior 196.22
 branch(-es) 196.27
 posterior auricular nerve
 328.8
 vagus nerve 332.5
 cartilage 386.10
 isthmus 388.1
 ligaments 388.10
 anterior 388.11
 posterior 388.13
 superior 388.12
 nerves
 anterior 324.29
 great 334.28
 posterior 328.6
 sulcus, posterior 386.28
 surface (ilium) 4.22, 42.30
 tubercle 386.26
 vein(-s)
 anterior 236.27
 posterior 238.3
- Auriculotemporal nerve 324.24
- Auris
 externa 386.1
 interna 370.2
 media 378.15
- Autonomic
 column 276.11
 ganglia 407.16
 nerve 408.12
 fibers 407.9
 nervous system 348.1
 plexus 348.2, 408.13
 ganglia 348.3
 ramus 408.12
- Axial skeleton 402.39
- Axialis 396.30
- Axillary
 artery 212.9
 fascia 92.15
 fossa 398.41
 hairs 392.9
 line 396.53
 anterior 396.52
 posterior 396.54
 lymph nodes 258.16
 lymphatic plexus 258.15
 nerve 340.13
 process, mammary gland
 394.22

Axillary
 region 398.40
 vein 244.13

Axis 4.11
 bulbi
 externus 354.20
 internus 354.21
 cylinder 408.20
 dens (odontoid process) 4.12
 lens 362.21
 opticus 354.22
 pelvic 44.29

Axon 408.20

Azygos
 arteries of vagina 224.3
 vein 246.1
 arch 246.1a

B

Barba 392.6

Bartholin's gland 172.3

Basal 396.25
 lamina 356.18, 356.28
 membrane of semicircular duct 370.16
 nuclei 316.20
 part
 of left pulmonary artery 190.38
 of right pulmonary artery 190.24
 tentorial branch of internal carotid 200.17
 vein 240.22
 common 230.21, 232.8
 inferior 232.13
 superior 230.22, 232.9

Basalis 396.25

Basilar 396.26
 artery 206.17
 crest 374.5
 membrane 372.20
 part of pons 284.8
 plexus 238.12
 sulcus of pons 284.4

Basilaris 396.26

Basilic vein 244.23
 median 244.27

Basioccipital bone 8.6

Basion 8.4

Basis
 cartilaginosa arytenoideae 140.12
 cochlea 376.20
 cordis 184.11
 cranii
 externa 30.16
 interna 30.1
 mandibulae 26.13
 metacarpalis 40.18
 metatarsalis 52.18
 modioli 376.23
 ossis sacri 4.17
 patellae 48.32

Basis
 pedunculi 290.29
 cerebri 292.1
 phalangis 40.29, 52.29
 posterior horn 276.6
 prostatae 162.11
 pulmonis (pulmonalis) 148.8
 pyramidis 154.32
 stapedis 382.6

Basivertebral vein 246.19

Basolateral part of amygdaloid body 318.3

Biceps muscle 88.12

Bicipital
 aponeurosis 88.16
 groove
 lateral 400.27
 medial 400.28

Bicipitoradial bursa 102.18

Bicondylar joint 404.29

Bifurcate ligament 70.28

Bifurcation
 aortae 222.5
 carotica 194.8a
 trachea (trachealis) 144.24
 trunci pulmonalis 190.13

Big toe 402.26

Bile duct
 common 134.12
 sphincter muscle 134.13

Biliary glands 134.16

Bipennate muscle 405.9

Biventral lobule 288.37

Bladder *see* Urinary bladder

Blood 406.18

Body
 of caudate nucleus 316.24
 of cerebellum 288.15
 of clavicle 34.29
 of epididymis 160.3
 of gallbladder 134.3
 of humerus 36.11
 of hyoid 28.17
 of ilium 42.11
 of incus 382.8
 of ischium 44.2
 of mammary gland 394.20
 of mandible 26.12
 of maxilla 22.3
 of metacarpal bone 40.19
 of nail 392.26
 of pancreas 128.5
 of penis 162.29
 of phalanx 40.30
 of pubis 44.9
 of radius 38.6
 of rib 6.13
 of sphenoid bone 10.2
 of sternum 6.31
 of stomach 120.25
 of talus 50.6
 of tongue 112.29
 of ulna 38.24
 of urinary bladder 156.27
 of uterus 168.7

Body
 of vertebra 2.3

Bones
 thoracic 6.1
 of upper limb 34.1
see also Os(-sa)

Bony
 nasal septum 32.2
 palate 30.22
 part 402.31
 spinal lamina 378.1
 hook 378.2

Bowman's
 capsule 154.39
 membrane 356.8

Brachial
 artery 212.25
 superficial 212.26
 fascia 92.17
 lymph nodes 258.18, 258.24
 plexus 336.12
 region
 anterior 400.21
 posterior 400.22
 veins 244.17

Brachiocephalic
 trunk 194.4
 veins
 left 232.28
 right 232.28

Brachium 400.20
 colliculi
 inferioris 292.16, 294.20, 300.26
 superioris 292.17, 294.23, 300.28
 conjunctivum 290.26
 pontis 290.25

Brain 278.14

Brainstem 278.15

Branch(-es)
 to atrioventricular node (right coronary artery) 192.14
 to carotid sinus (glossopharyngeal nerve) 330.28
 communicating with facial nerve 324.28
 to conus arteriosus (right coronary artery) 192.8
 to isthmus of fauces (lingual nerve) 326.2
 to maxillary sinus (nasopalatine nerve) 322.20e
 to nasal septum (nasopalatine nerve) 322.20b
 to sinuatrial node (right coronary artery) 192.9
 to tail of caudate nucleus 208.23
 to trigeminal ganglion (inter-nal carotid) 200.20

Breast 394.18
 suspensory ligaments 394.31

Bregma 28.29

Broad ligament of uterus 180.24

- Bronchial
branches
aorta 216.3
internal thoracic artery 210.4
segmental 148.1
vagus nerve 332.21
glands 148.5
tree 144.29
veins 234.5, 246.6
- Bronchioles 152.1
respiratory 152.2
- Bronchioli 152.1
respiratorii 152.2
- Bronchoesophageal muscle 120.9
- Bronchomediastinal trunk, right/left 254.12
- Bronchopulmonary segments 150.1
- Bronchus(-i) 144.28
lingularis
inferior 146.20
superior 146.19
lobaris(-es) 146.1
inferior
dexter 146.9
sinister 146.21
medius dexter 146.6
superior
dexter 146.2
sinister 146.16
principalis (dexter/sinister) 144.30
segmentalis(-es) 146.1
anterior 146.5, 146.18
apicalis 146.3
apicoposterior 146.17
basalis
anterior 146.13, 146.25
lateralis 146.14, 146.26
medialis 146.12, 146.24
posterior 146.15, 146.27
lateralis 146.7
medialis 146.8
posterior 146.4
subapicalis 146.11, 146.23
superior 146.10, 146.22
- Bruch's membrane 356.18
- Brunner's glands 124.14
- Bucca 108.12
- Buccal
artery 198.27
branches of facial nerve 328.15
fat pad 108.13
glands 108.33
nerve 324.23
region 398.20
surface of tooth 110.25a
- Buccinator node 256.11
- Buccopharyngeal fascia 80.18, 118.34a
- Bulbar conjunctiva 368.1
- Bulboid corpuscles 290.22
- Bulbopontine sulcus 284.3
- Bulboreticulospinal tract 276.30
- Bulbourethral gland 162.24
duct 162.25
- Bulbus
aortae 192.5
cornus occipitalis (posterioris) 314.12
duodeni 124.3
inferior venae jugularis 234.24
oculi 354.15
olfactorius 310.27
penis 164.10
pili 392.15
superior venae jugularis 234.22
vestibuli 170.34
- Bulla ethmoidalis 20.10, 138.9
- Bundle of His 186.11
- Bursa(-ae)
anserina 106.1
bicipitoradialis 102.18
cubitalis interossea 102.19
iliopectinea 104.14
infrahyoidea 102.5
infrapatellaris profunda 104.22
intermusculares mm.
gluteorum 104.12
intratendinea olecrani 102.16
ischiadica (sciatica)
m. glutei maximi 104.13
m. obturatoris interni 104.10
- membri
inferioris 104.4a
superioris 102.5a
- musculi
bicipitis femoris superior 104.16
coracobrachialis 102.10
piriformis 104.9
poplitei 106.3
semimembranosi 106.6
tensoris veli palatini 102.2
omentalis 176.30
pharyngealis 118.1
retrohyoidea 102.4
subacromialis 102.8
subcutanea 405.31
acromialis 102.7
calcanea 106.17
infrapatellaris 104.21
malleoli
lateralis 106.7
medialis 106.8
olecrani 102.15
prepatellaris 104.17
prominentiae laryngealis 102.3
trochanterica 104.5
tuberositas tibiae 104.23
subdeltoidea 102.9
subfascialis 405.33
subfascialis prepatellaris 104.18
submuscularis 405.32
- Bursa(-ae)
subtendinea 405.34
iliaca 104.15
musculi
bicipitis femoris inferior 106.2
gastrocnemii
lateralis 106.4
medialis 106.5
infraspinati 102.11
latissimi dorsi 102.14
obturatoris interni 104.11
sartorii 104.24
subscapularis 102.12
tertius majoris 102.13
tibialis anterioris 106.16
trapezii 102.6
tricipitis brachii 102.17
prepatellaris 104.19
suprapatellaris 104.20
synovialis(-es) 405.30
trochlearis 364.12
tendinis calcanei (Achilles) 106.18
trochanterica
musculi glutei
maximi 104.6
medii 104.7
minimi 104.8

C

- Caecum
cupulare 372.16
vestibulare 372.17
- Calcaneal region 402.18
- Calcanean
branches
peroneal artery 228.16
posterior tibial artery 228.11
- facet
anterior 50.15
middle 50.14
posterior 50.12
network 228.17
process 52.15
- Calcaneocuboid
joint 70.17
ligament 70.30
dorsal 70.31a
plantar 72.3
- Calcaneofibular ligament 70.9
- Calcaneonavicular ligament 70.29
plantar 72.4
- Calcaneus 50.22
anterior tubercle 50.26
lateral process 50.25
medial process 50.24
- Calcar avis 314.13
- Calcarine
branch
medial occipital artery 208.10
sulcus 310.12

Calf 402.15
 Calices
 renales 156.16
 majores 156.17
 minores 156.18
 Calculus gustatorius 388.27
 Callosomarginal artery 204.10
 Calx 402.18
 Camerae
 anterior 360.15
 bulbi 360.14a
 posterior 362.1
 vitrea 362.3
 Canal of Schlemm 354.30
 Canaliculus(-i)
 caroticotypanici 12.27
 chordae tympani 12.24
 cochleae 14.21
 apertura externa 14.22
 innominatus 10.37
 lacrimalis 368.19
 mandibulae 28.8
 mastoideus 14.25
 tympanicus 14.28
 Canalis(-es)
 adductorius 98.17
 alimentarius 120.1
 alveolares 22.16
 analis 126.24
 caroticus 12.26
 carpi (carpalis) 64.6
 centralis 274.12
 cervicis uteri 168.21
 condylaris 8.15
 diploici 28.24
 facialis 12.22
 genu 12.23
 femoralis 98.24
 gastricus (ventricularis)
 120.26
 hyaloideus 362.6
 hypoglossalis 8.16
 incisivus 24.4, 30.25
 infraorbitalis 22.5
 inguinalis 86.30
 longitudinales
 modioli 376.26
 musculotubarius 12.28
 septum 12.31
 nasolacrimalis 32.7
 nervus
 petrosi majoris, hiatus 14.4
 petrosi minoris, hiatus 14.5
 nutriens 404.7
 obturatorius 66.3
 opticus 10.20
 palatini minores 24.22
 palatinus major 30.17
 palatovaginalis 30.28
 paraurethrales 164.36
 pterygoideus (vidii) 12.12
 pudendalis (Alcock) 176.15
 pyloricus 120.29
 radicis dentis 112.3
 sacralis 4.34

Canalis(-es)
 semicirculares
 anterior 376.7
 lateralis 376.9
 ossei 376.6
 posterior 376.8
 spiralis
 cochleae 376.21
 modioli 376.25
 vertebralis 2.2
 vomero-rostralis 30.30
 vomero-vaginalis 30.29
 Canine
 fossa 22.10
 teeth 112.21
 Capillary 406.38
 Capilli 392.3
 Capitate 40.12
 Capitulum humeri 36.23
 Capsula
 adiposa 154.14
 articularis 66.21, 404.38
 cricoaerenoidea 140.24
 cricothyroidea 140.7
 externa 318.6
 extrema 318.5
 fibrosa 154.15
 perivascularis 132.2
 (thyroid gland) 182.7
 ganglii (ganglionica) 407.11
 glomerularis (Bowman's)
 154.39
 interna 318.7
 lentis 362.16
 pancreatis 128.24
 prostatica 162.19
 tonsillaris 116.12
 Capsular
 arteries 220.17a
 branches, interlobular arteries
 156.7
 ligaments 404.46
 veins 246.20a
 Caput
 breve
 (biceps brachii) 88.15
 (biceps femoris) 96.4
 costae 6.8
 epididymidis 160.2
 femoris 46.3
 fibulae (fibulare) 48.16
 humerales
 (extensor carpi ulnaris)
 90.19
 (flexor carpi ulnaris) 90.4
 (pronator teres) 88.27
 humeri (humerales) 36.3
 humeroulnare (flexor digi-
 torum superficialis) 90.7
 laterale
 (flexor hallucis brevis) 98.2b
 (gastrocnemius) 96.15
 (triceps) 88.21
 longum
 (biceps brachii) 88.13

Caput
 longum
 (biceps femoris) 96.3
 (triceps) 88.20
 lymph nodes 256.2
 mallei 382.14
 mandibulae 28.13
 mediale
 (flexor hallucis brevis)
 98.2a
 (gastrocnemius) 96.16
 (triceps) 88.22
 metacarpale 40.20
 metatarsale 52.20
 muscle 405.3
 nuclei caudati 316.23
 obliquum
 (adductor hallucis) 98.4
 (adductor pollicis) 92.7
 pancreatis 128.2
 phalangis
 fingers 40.31
 toes 52.31
 posterior horn 276.4
 profundum (flexor pollicis
 brevis) 92.4
 radiale (flexor digitorum su-
 perficialis) 90.8
 radii 38.2
 stapedis 382.3
 superficiale (flexor pollicis
 brevis) 92.3
 tali (talare) 50.4
 transversum
 (adductor hallucis) 98.5
 (adductor pollicis) 92.8
 ulnae 38.32
 ulnare
 (extensor carpi ulnaris)
 90.20
 (flexor carpi ulnaris) 90.5
 (pronator teres) 88.28
 Cardiac
 ganglia 348.6
 impression 128.25
 of lung 148.14
 nerve
 cervical
 inferior 352.10
 middle 352.7
 superior 352.4
 notch 120.24, 148.18
 orifice 120.22
 part of stomach 120.21
 plexus 348.5
 veins 232.14
 small 232.21
 smallest 232.23
 Carina
 tracheae 144.25
 urethralis vaginae 170.16
 Caroticotypanic
 arteries 200.14
 canaliculi 12.27
 nerves 330.24

- Carotid**
 artery
 common 194.6
 external 194.9
 internal 200.10, 208.13
 bifurcation 194.8a
 body 194.7
 canal 12.26
 groove 10.11
 nerve
 external 350.31
 internal 350.29
 plexus
 common 352.2
 external 352.1
 internal 350.30
 sheath 82.25
 sinus 194.8, 200.12
 triangle 398.25
 inferior 398.26
 tubercle 2.21
 wall 380.19
- Carpal**
 bones 40.2
 accessory 40.3
 canal/tunnel 64.6
 groove 40.15
 joints 62.15a
 ligament, radiate 62.21
 region
 anterior 400.35
 posterior 400.36
 surface, articular (radius) 38.17
- Carpometacarpal**
 joint of thumb 64.10
 ligaments
 dorsal 64.8
 palmar 64.9
- Carpus** 40.1, 400.34
- Cartilaginous**
 joints 404.19
 lamina
 lateral 384.21
 medial 384.20
 nasal septum 134.30, 136.5a
 part
 of auditory tube 384.18
 of skeleton 402.37
- Cartilago(-ines)**
 alaris
 major 134.25
 minores 134.28
 articularis 404.33
 arytenoidea 140.10
 auricularis 386.10
 corniculata 140.28
 costalis 6.6
 cricoidea 140.1
 cuneiformis 142.1
 epiglottica 142.6
 epiphysialis 402.49
 laryngeales 138.13
 meatus acustici 386.5
- Cartilago(-ines)**
 nasi (nasalis) 134.23
 accessoriae 134.29
 lateralis 134.24
 septi nasi 134.30
 sesamoidea 140.27
 thyroidea 138.14
 tracheales 144.20
 triticea 138.28
 vomeronasalis 134.32
- Caruncula(-ae)**
 hymenales 170.9
 lacrimalis 366.26
 sublingualis 108.26
- Cauda**
 epididymidis 160.4
 equina 334.13
 helices 386.14
 nuclei caudati 316.25
 pancreatis 128.13
- Caudal** 396.22
 retinaculum 390.8
- Caudalis** 396.22
- Caudate**
 branches, portal vein of liver 248.7
 lobe of liver 130.26
 left duct of 132.16
 right duct of 132.15
 nucleus 316.22
 body 316.24
 head 316.23
 tail of 316.25
 process, liver 130.28
- Caval lymph nodes, lateral** 262.8
- Cavernae**
 corporis spongiosi 164.17
 corporum cavernosorum 164.16
- Cavernous**
 nerves
 of clitoris 350.20
 of penis 350.19
 part of internal carotid 200.16
 plexus of concha 136.17
 sinus 200.22, 238.21
 veins 164.19
- Cavitas(-tes)**
 abdominalis 176.18
 articularis 404.34
 conchalis 386.21
 coronae 112.2
 cranii 28.20a
 dentis (pulpalis) 112.1
 glandularis 34.20
 infraglottica 144.8
 laryngis 142.23
 intermedia 142.29a
 medullaris 404.3
 nasi (nasalis) 32.1, 136.1
 oris 108.2
 propria 108.14
 pelvis (pelvica) 44.21a
 pericardialis 184.7
 peritonealis 176.19
- Cavitas(-tes)**
 pharyngis 116.24
 pleuralis 152.11
 thoracis (thoracica) 6.35a, 152.6
 trigeminalis 268.29
 tympanica 14.30, 378.16
 uteri 168.12
- Cavum**
 Retzii 176.16
 septi pellucidi 312.28
- Cecal**
 artery, anterior 220.7
 fold 180.7
 vascular 180.3
- Cecum (caecum)** 124.18
- Celiac**
 branches, vagus nerve 332.29
 ganglia 348.12
 lymph nodes 262.14
 plexus 348.11
 trunk 216.28
- Cellulae**
 ethmoidales 20.7, 138.4
 mastoideae 380.17
 pneumaticae 384.17
 tympanicae 380.18
- Cementum** 112.16
- Central** 396.35
 artery(-ies)
 anteromedial 204.3, 208.16
 long 204.5
 posterolateral 206.27
 posteromedial 206.25
 short 204.4
 canal 274.12
 fovea 360.4
 gray matter 292.11
 intermediate 276.12
 lobule, cerebellum 288.20
 lymph nodes 258.21, 264.3
 nervous system 272.12, 406.50
 nucleus 274.24
 lateral 298.28
 medial 298.29
 part of lateral ventricle 314.2
 retinal artery 202.2
 sulcus 306.16
 of insula 308.30
 tegmental tract 294.26
 tendon 84.31
 of perineum 174.4
 thalamic radiations 302.2, 318.20
 vein 132.5, 182.36
 of retina 244.4
- Centralis** 396.35
- Centromedian nucleus** 298.25
- Centrum**
 ossificationis 404.8
 primarium 404.9
 secundarium 404.10
 tendineum 84.31
 perinei 174.4

- Cephalic vein 244.20
 accessory 244.22
 median 244.26
- Ceratocricoid
 ligament 140.7a
 muscle 142.16
- Cerebellar
 anterior lobe 288.18
 artery
 anterior inferior 206.18
 posterior inferior 206.12
 superior 206.22
 cortex 290.13
 fissure 288.13
 fossa 8.34b
 hemisphere 288.17
 peduncles 290.23
 inferior 280.2, 282.4, 290.24
 middle 284.5, 290.25
 superior 290.26, 292.19
 sections 290.9
 veins 242.18
 precentral 242.23
- Cerebellum 288.11
 body 288.15
 folia 288.12
 nucleus 290.17
 tonsil 288.38
 vermis 288.16
- Cerebellomedullary cistern 270.5
- Cerebral
 aqueduct 292.20
 arterial circle 208.12
 artery
 anterior 204.1, 208.14
 middle 204.18, 208.17
 posterior 206.23, 208.24
 cortex 306.3, 316.2
 crus 290.29
 fossa 8.34a
 gyri 306.4
 hemisphere 306.14
 lobes 306.6
 part of internal carotid 200.24
 peduncle 290.28
 sulci 306.5
 surface 10.24, 16.23
 veins 240.9
 anterior 240.23
 deep 240.21
 middle 240.24
 great 242.1
 inferior 240.16
 internal 242.2
 superficial 240.10
 middle 240.18
 superior 240.11
- Cerebrospinal fluid 270.3, 270.15
- Cerebrum 306.2
 arcuate fibers 316.14
 lateral fossa 306.9
 longitudinal fissure 306.7
 transverse fissure 306.8
- Ceruminous glands 394.16
- Cervical
 artery
 ascending 210.20
 deep 212.4
 transverse 210.22
 branch of facial nerve 328.18
 canal 168.21
 enlargement 272.14
 fascia 82.12
 ganglion
 middle 352.5
 superior 350.27
 glands 168.23
 lymph nodes
 anterior 256.17
 inferior deep 258.7
 lateral 258.1
 nerves 334.14
 transverse 336.1
 part
 of esophagus 120.3
 of internal carotid 200.11
 of thoracic duct 254.19
 of trachea 144.18
 plexus 334.22
 regions 398.22
 rib 6.22
 segment of spinal cord 274.6
 septum, intermediate 272.10
 veins
 deep 234.12
 transverse 238.7
 vertebrae 2.16
- Cervicothoracic ganglion 352.8
- Cervix
 dentis 110.20
 posterior horn 276.5
 uteri 168.15
 vesicae 156.29
- Chambers of the eye 360.14a
 anterior 360.15
 posterior 362.1
 vitreous 362.3
- Cheek 108.12
 muscle 80.10
- Chiasma
 opticum 296.32
 tendinum 92.34
- Chiasmatic
 branch, posterior communicat-
 ing artery 208.19
 cistern 270.7
- Choanae 32.10, 136.3
 Choanal crest of vomer 20.30a
- Chondrocranium 8.1a
- Chopart's joint 70.16
- Chorda(-ae)
 obliqua 62.11
 tendineae 186.4
 tympani nerve 328.21
 canaliculus 12.24
 utero-ovarica 166.28
- Choriocapillaris 356.17
- Choroid 356.13
- Choroid
 branch of posterior inferior
 cerebellar
 artery 206.13
 fissure 314.9
 glomus 272.7
 plexus 298.10
 fourth ventricle 272.3, 288.6
 lateral ventricle 272.6, 314.11
 third ventricle 272.5
 vein
 inferior 240.29
 superior 242.3
- Choroidal
 artery, anterior 202.22
 veins of eye 242.29
- Choroidea 356.13
- Cilia 366.15, 392.5
- Ciliary
 arteries
 anterior 202.9
 long posterior 202.7
 short posterior 202.6
 body 356.19
 folds 356.22
 ganglion 320.8, 352.29
 glands (of Moll) 368.6
 margin 358.3
 muscle 356.24
 nerves
 long 322.3
 short 320.10
 processes 356.21
 veins 244.1
 anterior 244.2
 zonule 362.24
- Cingular branch, callosomarginal
 artery 204.14
- Cingulate
 gyrus 310.3
 isthmus 310.4
 sulcus 310.5
- Cingulum 110.30, 316.15
 membrum
 inferioris (pelvicum) 42.2
 superioris (pectorale) 34.2
- Circle of Willis 208.12
- Circular
 connection of vessels 406.16
 fibers 356.26
 folds, small intestine 122.29
 layer
 of colon 126.7
 of small intestine 122.25
 of stomach 122.7
 of tympanic membrane 380.32
 sulcus of insula 308.31
- Circulus
 arteriosus 406.15
 cerebri 208.12
 iridis
 major 358.15
 minor 358.16
 vasculosus 406.16
 nervi optici 360.7

- Circumanal glands 394.15
 Circumferentia articularis (radius) 38.4 (ulna) 38.33
 Circumflex
 branch of left coronary artery 192.21
 scapular
 artery 212.22
 vein 244.13a
 Circumvallate papillae 114.7
 Cistern 406.17
 ambient 270.9
 Cisterna(-ae) 406.17
 ambiens 270.9
 cerebellomedullaris 270.5
 chiasmatica 270.7
 chyli 254.22
 fossae lateralis cerebri 270.6
 interpeduncularis 270.8
 magna 270.5
 pericallosa 270.10
 pontocerebellaris 270.11
 subaracnoideae 270.4
 Claustrum 316.32
 Clavicle (clavicula) 34.25
 body (shaft) 34.29
 Clavicular
 branch of axillary artery 212.15
 notch 6.25
 part of pectoralis major 84.4
 Clavipectoral
 fascia 84.10
 triangle 398.36
 Clinical
 crown of tooth 110.19
 root of tooth 110.23
 Clinoid process
 anterior 10.21
 middle 10.7
 posterior 10.10
 Clitoris 172.4
 body 172.6
 cavernous nerves of 350.20
 corpus cavernosum 172.10
 crus 172.5
 dorsal nerve of 346.23
 frenulum 172.8
 glans 172.7
 prepuce 172.9
 suspensory ligament 86.25
 Clival branch of internal carotid 200.26
 Clivus 8.6a, 30.5
 Clunial nerves
 inferior 344.15
 medial 342.11
 superior 342.5
 Coccygeal
 body 216.27
 bone 4.37
 cornu (horn) 4.38
 foveola 390.7
 muscles 88.1
 nerve 342.7, 346.24
 Coccygeal
 plexus 346.25
 segment of spinal cord 274.10
 Cochlea 376.18
 apex 376.19
 base 376.20
 Cochlear
 aqueduct 372.13
 branch of labyrinthine artery 374.13
 canaliculus 14.21
 external opening 14.22
 duct 372.15
 tympanic wall 372.18
 ganglion 330.16
 labyrinth 372.9
 nerve 330.3, 330.15
 area 378.10
 nuclei 282.16, 286.13
 anterior 282.17
 posterior 282.18
 recess 376.1
 Cochleariform process 380.5
 Colic
 artery
 left 220.13
 marginal 220.11a
 middle 220.11
 right 220.10
 branch of ileocolic artery 220.6
 flexure
 left 124.29
 right 124.27
 impression 130.11
 lymph nodes
 left 264.10
 middle 264.10
 right 264.10
 surface of spleen 268.7
 vein
 left 248.34
 middle 248.28
 right 248.27
 Collar bone 34.25
 Collateral
 artery
 inferior ulnar 212.33
 middle 212.30
 radial 212.31
 superior ulnar 212.32
 branch of posterior intercostal arteries 216.13
 eminence 314.14
 ligaments 64.17, 72.19, 72.23
 fibular 68.12
 of interphalangeal joints 64.21
 radial 62.6
 carpal 62.23
 tibial 68.13
 ulnar 62.5
 carpal 62.22
 sulcus 310.18
 trigone 314.15
 vessel 406.39
 Colliculus 140.16
 facialis 286.24
 inferior 292.14
 seminalis 164.26
 superior 292.15
 Collum
 anatomicum (humerus) 36.4
 chirurgicum (humerus) 36.5
 costae 6.11
 dentis 110.20
 femoris 46.5
 fibulae 48.19
 glandis 164.4
 lymph nodes 256.2
 mallei 382.15
 mandibulae 28.14
 radii 38.5
 scapulae 34.23
 tali 50.5
 vesicae biliaris 134.4
 Colon 124.25
 ascendens 124.26
 descendens 124.30
 sigmoideum 124.31
 transversum 124.28
 Columna(-ae)
 anales 126.25
 anterior 274.17
 autononica 276.11
 fornix 312.25
 griseae 274.16
 interomediolateral 276.11
 lateralis 276.9
 posterior 276.1
 renales 154.36
 rugarum 170.13
 anterior 170.15
 posterior 170.14
 thoracica 276.14
 vertebralis 2.1
 Commissura
 alba
 anterior 276.18
 posterior 276.18a
 anterior 312.20, 318.30
 colliculorum
 inferiorum 294.21
 superiorum 294.24
 epithalamica 296.8, 296.16
 fornix 312.26
 grisea anterior/posterior 276.16a
 habenularum (habenularis) 296.7, 296.13
 labiorum 108.10
 anterior 170.27
 posterior 170.28, 232.8
 palpebralis
 lateralis 366.9
 medialis 366.10
 supraoptica
 dorsalis 304.12
 ventralis 304.13
 Commissural
 neurofibers 318.34
 nucleus 282.19

Common

annular tendon 364.9
 basal vein 230.21, 232.8
 bile duct 134.12
 carotid
 artery 194.6
 plexus 352.2
 digital nerves 338.15
 hepatic artery 218.1
 iliac
 artery 222.6
 lymph nodes 264.15
 vein 248.37
 integument 390.1
 interosseous artery 214.19
 membranous crus 370.29
 osseous crus 376.15
 palmar
 digital arteries 214.28
 digital nerves 338.23
 peroneal (fibular) nerve 344.18
 communicating branch 344.20
 plantar digital
 arteries 228.25
 nerves 346.10, 346.14
 sheath of flexor muscles 104.2
 tendinous ring 364.9
 tendon sheath for peroneal muscles 106.15
 Communicating
 artery
 anterior 204.6, 208.15
 posterior 208.18
 branch(-es) 350.25, 408.11
 with auriculotemporal nerve 330.34
 of auriculotemporal nerve
 with facial nerve 324.28
 with chorda tympani 330.35
 with cochlear nerve 330.6
 of facial nerve
 with glossopharyngeal nerve 328.11
 with tympanic plexus 328.4
 with vagus nerve 328.5
 of glossopharyngeal nerve
 with branch
 of vagus nerve 330.25
 inferior laryngeal nerve 332.19
 with meningeal branch of mandibular nerve 330.33
 of nasociliary nerve with ciliary ganglion 322.2
 peroneal artery 228.14
 peroneal (fibular) nerve, common 344.20
 with recurrent laryngeal nerve 332.13
 spinal nerve 334.11
 to ulnar nerve 338.14, 340.9
 of vagus nerve with glossopharyngeal nerve 332.6

Communicating

ramus(-i)
 to chorda tympani nerve 326.4
 to hypoglossal nerve 326.3
 with zygomatic nerve 320.22
 Compact
 bone 402.35
 part of substantia nigra 292.8
 Compages thoracis 6.35
 Companion vein of hypoglossal nerve 234.30
 Composite joint 404.24
 Concha(-ae)
 auricularis 386.19
 cavity 386.21
 eminence 388.7
 nasalis
 inferior 20.17, 136.13
 media 20.15, 136.12
 superior 20.14, 136.11
 suprema 20.13
 sphenoidalis 10.18
 Conchal crest 22.20, 24.23
 Condylar
 canal 8.15
 emissary vein 240.4
 fossa 8.17
 joint 404.27
 process 28.12
 Condylus(-i)
 humeri 36.22
 lateralis
 (femur) 46.24
 (tibia) 46.30
 medialis
 (femur) 46.21
 (tibia) 46.29
 occipitalis 8.14
 Confluence of sinuses 238.10
 Confluens sinuum 238.10
 Conical papillae 114.5
 Conjoined tendon 86.21
 Conjugate diameter (pelvis) 44.30
 Conjunctival
 arteries
 anterior 202.10
 posterior 202.11
 glands 368.8
 ring 356.2
 sac 368.5
 veins 244.7
 Connective tissue capsule of spleen 268.14
 Connexus intertendineus 90.16
 Conoid
 ligament 60.21
 tubercle 34.33
 Conus
 arteriosus 188.8
 elasticus 144.12
 medullaris 272.16
 Convoluted
 part of renal cortex 154.27
 seminiferous tubules 158.29

Convoluted

uriniferous tubules 154.23
 Cor 184.10
 Coracocromial ligament 60.13
 Coracobrachial bursa 102.10
 Coracoclavicular ligament 60.19
 tuberosity for 34.31a
 Coracohumeral ligament 60.31
 Coracoid process 34.24
 Coras (brachial plexus) 336.18a
 lateral 336.25
 medial 336.26
 posterior 336.27
 Corium 390.15
 Cornea 356.1
 Corneoscleral
 junction 354.26, 356.3
 part of trabecular meshwork 354.28
 Corniculate
 cartilage 140.28
 tubercle 140.29, 142.9
 Cornu
 anterius 274.18, 314.4
 coccygeus 4.38
 frontale 314.4
 inferius 314.6
 (margo falciformis) 100.6
 (thyroid) 138.23
 laterale 276.10
 majus 28.19
 minor 28.18
 occipitale 314.5
 posterius 276.2, 314.5
 sacrale 4.33
 superius
 (margo falciformis) 100.5
 (thyroid) 138.22
 temporale 314.6
 uteri dextrum/sinistrum 168.9
 Corona
 ciliaris 356.20
 clinica 110.19
 dentis 110.13
 glandis 164.2
 radiata 318.29
 Coronary 396.5
 suture 54.2
 Coronalis 396.5
 Coronary
 artery
 left 192.16
 right 192.7
 groove 184.20
 ligament 178.21
 sinus 232.15
 opening 186.27a
 vein
 left 232.16a
 right 232.20b
 Coronoid
 fossa 36.26
 process
 mandible 28.10
 ulna 38.20

- Corpus(-ora)
 adiposum
 buccae 108.13
 fossae ischioanalis 176.14
 infrapatellare 68.19
 pararenale 154.13
 prae-epiglotticum 138.26a
 adiposum orbitae 364.23
 albicans 166.27
 amygdaloideum 318.1
 callosus 312.6
 radiation of 312.11, 316.19
 sulcus 310.2
 cavernosum
 clitoridis 172.10
 penis 164.8
 tunica albuginea 164.11
 cerebelli 288.15
 ciliare 356.19
 claviculae (claviculare) 34.29
 clitoridis 172.6
 costae 6.13
 epididymidis 160.3
 femoris 46.12
 fibulae 48.20
 of fornix 312.23
 gastricum (ventriculare)
 120.25
 geniculatum
 laterale 296.28
 mediale 296.27
 humeri 36.11
 ilii 42.11
 incudis 382.8
 lingulae 112.29
 luteum 166.26
 Luyssii 300.17
 mamillare 296.36
 mammae 394.20
 mandibulae 26.12
 maxillae 22.3
 medullare 290.11
 metacarpale 40.19
 metatarsale 52.19
 neurale 408.19
 nuclei caudati 316.24
 ossis
 hyoidea 28.17
 ischii 44.2
 pubis 44.9
 sphenoidalis 10.2
 pancreatis 128.5
 para-aortica 194.3
 penis 162.29
 phalangis
 fingers 40.30
 toes 52.30
 pineale 182.22, 296.9, 296.17
 radii 38.6
 spongiosum penis 164.9
 tunica albuginea 164.12
 sterni 6.31
 striatum 316.21
 tali 50.6
 tibiae (tibiale) 48.1
- Corpus(-ora)
 trapezoideum 286.14
 ulnae 38.24
 unguis 392.26
 uteri 168.7
 vertebrae 2.3
 vesicae 156.27
 biliaris 134.3
 vitreum 362.4
 Corpusculum(-a)
 articularia 390.27
 lamellosa 390.23
 bulboidea 390.22
 genitalia 390.25
 nervosa terminalia 390.21
 renale 154.37
 tactus 390.24
- Cortex
 adrenal 182.37
 cerebellaris 290.13
 cerebri (pallium) 306.3,
 316.2
 lentis 362.12
 lymph node 254.26
 ovarii 166.16
 renalis 154.26
 thymi 182.27
- Cortical
 labyrinth 154.27
 lobules 154.29
 substance 402.34
 Corticobulbar fibers 292.2
 Corticomedial part of amygdaloid body 318.4
 Corticonuclear
 fibers 280.12, 284.11, 292.3
 tract 318.12
 Corticopontine fibers 284.13,
 292.4
 Corticoreticular fibers 284.12,
 292.23, 318.17
 Corticorubral fibers 318.16
 Corticospinal
 fibers 280.11, 284.10, 292.2,
 318.15
 tract
 anterior 276.22
 lateral 276.28
 Corticotectal fibers 318.24
 Corticothalamic fibers 318.18
 Costa(-ae) 6.2
 cervicalis 6.22
 fluitantes 6.5
 prima 6.17a
 secunda 6.20a
 spuriae 6.4
 verae 6.3
- Costal
 arch 6.39
 cartilage 6.6
 fovea
 inferior 2.26
 superior 2.25
 transverse 2.27
 groove 6.17
- Costal
 notches 6.33
 part
 of diaphragm 84.27
 of parietal pleura 152.16
 pleura 152.17
 process 2.13
 surface
 of lung 148.10
 of scapula 34.4
 tubercle 6.14
 articular facet 15
- Costocervical trunk 212.3
 Costochondral joints 58.28
 Costoclavicular
 ligament 60.26
 impression for 34.28
 Costodiaphragmatic recess 152.20
 Costomediastinal recess 152.21
 Costotransverse
 foramen 58.19
 joint 58.14
 ligament 58.15
 lateral 58.17
 superior 58.16
 Costovertebral joints 58.10
 Costoxiphoid ligaments 58.24
 Cowper's gland 162.24
 Coxa 402.3a
- Cranial 396.21
 arachnoid 270.1
 bones 8.1
 cavity 28.20a
 dura mater 268.23
 fontanelles 32.27
 fossa
 anterior 30.2
 middle 30.3
 posterior 30.4
 nerves 320.2, 408.1
 nuclei 408.2
 part of parasympathetic system 352.26a
 pia mater 272.1
 roots of accessory nerve 332.32
 synchondroses 56.1
 Cranialis 396.21
 Craniospinal ganglia 407.13
 Cranium 28.20
 internal base of 30.1
- Cremasteric
 artery 224.25
 fascia 160.29
- Cribriform
 fascia 100.7
 foramina 20.2
 plate 20.2
- Cricoaeroid
 joint 140.23
 articular capsule 140.24
 ligament 140.25
- Cricoaeroid muscle
 lateral 142.17
 posterior 142.15

- Cricoesophageal tendon 120.8
 Cricoid
 cartilage 140.1
 arch 140.2
 lamina 140.3
 Cricopharyngeal ligament 140.26
 Cricothyroid
 branch of superior thyroid artery 194.14
 joint 140.6
 capsule 140.7
 ligament, median 140.8
 Cricotracheal ligament 140.9
 Crista(-ae)
 ampullaris 370.23
 arcuata 140.15
 basilaris 374.5
 capitis costae 6.10
 choanalis vomeris 20.30a
 colli costae 6.12
 conchalis 22.20, 24.23
 cutis 390.4
 ethmoidalis 22.28, 24.24
 fenestrae cochleae 380.4
 frontalis 18.15
 galli 20.3
 ala 20.4
 iliaca 42.15
 infratemporalis 10.32
 intertranchaerica 46.11
 lacrimalis
 anterior 22.26
 posterior 20.22
 marginalis (tooth) 110.31
 matricis unguis 392.22
 medialis 48.24
 musculi supinatoris 38.31
 nasalis 24.2, 24.32
 obturatoria 44.16
 occipitalis
 externa 8.24
 interna 8.30
 palatina 24.33
 pubica 44.12
 sacralis
 intermedia 4.31
 lateralis 4.32
 mediana 4.29
 sphenoidalis 10.13
 spiralis 372.21
 supracondylaris
 lateralis 36.20
 medialis 36.17
 supramastoidea 16.17
 supraventricularis 188.7
 temporalis 28.10a
 terminalis 186.17
 transversa 378.8
 transversalis (tooth) 110.17
 triangularis (tooth) 110.18
 tuberculi
 majoris 36.9
 minoris 36.10
 urethralis 164.25, 172.21
 vestibuli 374.24
- Crown
 of head 28.30
 pulp 112.6
 of tooth 110.13
 Cruces pilorum 392.19
 Cruciate
 ligaments of knee 68.7
 anterior 68.8
 posterior 68.9
 part of fibrous sheath 92.29, 100.24
 Cruciate muscle 405.13
 Cruciform
 eminence 8.28
 ligament of dens 58.5
 longitudinal fasciculi 58.6
 Crural fascia 100.8
 Crus(-ra) 402.12
 anterior capsulae internae 318.8
 anterior (stapes) 382.4
 anthelialis 386.17
 breve (incus) 382.11
 cerebri 290.29
 clitoridis 172.5
 of conducting system of heart 186.12
 dextrum 84.25
 of fornix 312.22
 helix 386.12
 laterale
 (alar cartilage) 134.27
 (inguinal ring) 86.16
 longum (incus) 382.9
 mediale
 (alar cartilage) 134.26
 (inguinal ring) 86.15
 membranacea 370.26
 ampullaria 370.28
 commune 370.29
 simplex 370.27
 osseum(-a) 376.14
 ampullaria 376.17
 commune 376.15
 simplex 376.16
 penis 162.30
 posterior
 capsulae internae 318.13
 (stapes) 382.5
 sinistrum 84.26
 Cryptae tonsillares 116.11, 116.29
 Cubital
 fossa 400.26
 lymph nodes 258.25
 region
 anterior 400.24
 posterior 400.25
 vein, median 244.24
 Cubitus 400.23
 Cuboid
 bone 52.12
 tuberosity 52.14
 Cuboideonavicular ligament
 dorsal 70.27
 plantar 72.6
- Culmen 288.21
 pulmonis sinistri 148.22a
 Cumulus oophorus (ovifer) 166.24
 Cuneate
 fasciculus 280.4, 280.16
 nucleus 280.17
 accessory 280.18
 tubercle 280.5
 Cuneiform
 bone
 intermediate 52.10
 lateral 52.11
 medial 52.9
 cartilage 142.1
 part of vomer 20.30b
 tubercle 142.2
 Cuneocuboid
 joint 70.17a
 ligament
 dorsal 70.26
 interosseous 70.21
 plantar 72.8
 Cuneometatarsal ligaments, interosseous 72.12
 Cuneonavicular
 joint 70.18
 ligaments
 dorsal 70.31
 plantar 72.5
 Cuneus 310.11
 Cupula 370.25
 cochlea 376.19
 pleurae 152.13
 Cupular
 cecum 372.16
 part of epitympanic recess 378.18
 Curvatura gastrica (ventricularis)
 major 120.18
 minor 120.19
 Cusp of tooth 110.14
 Cuspis
 anterior
 atrioventricular valve 188.27
 pulmonary valve 188.4
 commissurales 188.28a
 dentis 110.14
 posterior
 atrioventricular valve 188.28
 pulmonary valve 188.5
 septalis 188.6
 Cutaneous
 branch(-es) 408.6
 anterior
 femoral nerve 344.3
 iliohypogastric nerve 342.17
 intercostal nerve 340.24
 lateral
 iliohypogastric nerve 342.16
 intercostal nerve 340.21
 medial, of the leg 344.6
 obturator nerve 342.27

Cutaneous
 branch(-es)
 posterior, thoracic nerves
 340.19
 glands 394.9
 layer of tympanic membrane
 380.29
 muscle 405.16
 nerve
 intermediate dorsal 344.24
 lateral
 antebrachial 338.3
 brachial 340.3
 dorsal 346.6
 femoral 342.24
 sural 344.19
 medial
 antebrachial 338.5
 brachial 338.4
 dorsal 344.23
 sural 346.4
 perforating 344.16a
 posterior
 antebrachial 340.4
 brachial 340.2
 femoral 344.14
 superior lateral brachial
 340.14
 vein 406.45
 Cuticle 394.4
 Cutis 390.2
 Cymba conchalis 386.20
 Cystic
 artery 218.5
 duct 134.10
 node 262.30
 vein 248.15

D

Dartos muscle 166.4
 Darwin's tubercle 386.26
 Decidua
 basalis 172.26
 capsularis 172.25
 parietalis 172.24
 Decidual membranes 172.23
 Deciduous teeth 112.25
 Declive 288.26
 Decussatio(-nes)
 lemniscorum medialium 280.20
 pedunculorum cerebellarium
 superiorum 294.8
 pyramidum 278.20, 280.13
 tegmenti (tegmentales) 294.7
 trochlearis 25, 294, 320.14
 Deep 396.32
 artery
 of clitoris 224.18
 of penis 224.16
 auricular artery 198.10
 branch
 medial circumflex femoral
 artery 226.4
 medial plantar artery 228.19

Deep
 branch
 plantar nerve 346.16
 radial nerve 340.6
 superior gluteal artery
 222.21
 transverse cervical artery
 210.24
 ulnar nerve 338.25
 cerebral veins 240.21
 cervical
 artery 212.4
 vein 234.13
 circumflex iliac
 artery 224.27
 vein 250.25
 dorsal
 sacrococcygeal ligament
 56.23
 vein
 of clitoris 250.12
 of penis 250.11
 facial vein 236.14
 fascia 405.26b
 of penis 164.21
 head of flexor pollicis brevis
 92.4
 infrapatellar bursa 104.22
 inguinal
 lymph nodes 266.18
 ring 86.29
 lamina of levator tendon
 364.16
 layer, temporal fascia 80.22
 lingual
 artery 196.5
 vein 234.32
 lymph nodes 256.19, 258.28
 superior 258.3
 lymphatic vessel 254.8
 middle cerebral vein 240.24
 palmar
 arch 214.11
 branch, ulnar artery 214.26
 venous arch 244.32
 parotid lymph nodes 256.6
 part
 of external anal sphincter
 174.17
 of masseter muscle 80.14
 of parotid gland 110.9
 perineal space 176.2
 peroneal (fibular) nerve 344.26
 petrosal
 nerve 328.25
 plantar
 arch 228.22
 artery 228.7
 popliteal lymph nodes 266.20
 temporal
 nerves 324.16
 veins 236.25
 transverse
 metacarpal ligament 64.19
 metatarsal ligament 72.21

Deep
 vein(-s) 406.47
 of clitoris 250.18
 of penis 250.17
 Deferential plexus 350.15
 Deltoid
 branch
 axillary artery 212.16
 brachial artery 212.29
 fascia 92.16
 ligament, talocrural joint 70.2
 region 400.19
 tuberosity 36.21
 Deltopectoral lymph nodes 258.23
 Dendrite 408.21
 Dendritum 408.21
 Dens(-tes) 110.12
 acustici 372.27
 apex 4.13
 articular surface
 anterior 4.14
 posterior 4.15
 axis 4.12
 canini 112.21
 decidui 112.25
 incisivi 112.20
 molares 112.23
 permanentes 112.26
 premolares 112.22
 serotinus 112.24
 Dental
 alveoli 24.10, 26.28
 arch
 inferior 112.19
 superior 112.18
 branches (rami)
 anterior superior alveolar ar-
 teries 200.3
 inferior alveolar artery 198.13
 posterior superior alveolar
 artery 198.28
 fovea of atlas 4.5
 papilla 112.8
 plexus
 inferior 326.11
 superior 324.6
 tubercle 110.16
 Dentate
 gyrus 310.13
 nucleus 290.18
 hilum 290.19
 suture 404.15
 Dentatorubral fibers 294.9
 Dentatohalamic tract 302.4
 Denticle ligament 272.9
 Dentine (dentinum) 112.9
 Dermal ridges 390.4
 Dermis 390.15
 Descemet's membrane 356.10
 Descending
 aorta 216.1
 branch
 lateral circumflex femoral
 artery 226.10
 medial circumflex femoral
 artery 226.6

- Descending branch
 occipital artery 196.21
 transverse cervical artery 210.23b
 colon 124.30
 genicular artery 226.1a
 palatine artery 200.5
 part of duodenum 124.4
 Descensus testis 162.7
 Desmodontium 112.15
 Detrusor muscle of bladder 158.4
 Dexter 396.7
 Diagonal stria of Broca 312.3
 Diameter (pelvis)
 conjugata 44.30
 obliqua 44.32
 transversa 44.31
 Diaphragm 84.23
 urogenitale 176.1
 Diaphragma
 pelvis 174.5
 sellae 268.28
 Diaphragmatic
 part of parietal pleura 152.18
 pleura 152.18
 surface
 of heart 184.13
 of liver 128.23
 of lung 148.15
 of spleen 268.3
 Diaphysis 402.47
 Diastema 112.27
 Diencephalon 296.2
 Digastric
 branch of facial nerve 328.9
 fossa 26.20
 triangle 398.24
 Digestive system 108.1
 tract 120.1
 Digital arteries
 common
 palmar 214.28
 plantar 228.25
 dorsal 214.8
 proper
 palmar 214.28
 plantar 228.26
 impressions 30.6
 nerves
 common 338.15
 palmar 338.23
 plantar 346.10, 346.14
 dorsal
 of the foot 344.25
 of hand 338.20, 340.10
 of lateral surface of great toe 344.28
 of medial surface of second toe 344.28
 proper
 palmar 338.16
 plantar 346.11, 346.15
 Digital veins
 palmar 244.31
 plantar 252.26
 Digits 40.23, 400.43
 Digitus(-i) 400.43, 402.25
 anularis 400.47
 medius 400.46
 minimus 400.48, 402.28
 primus 400.44, 402.26
 quartus 400.47, 402.27
 quintus 400.48, 402.28
 secundus 400.45, 402.27
 tertius 400.46, 402.27
 Dilator muscle 405.11a
 Diploë 28.23
 Diploic
 branch 202.13a
 canals 28.24
 veins 238.24
 anterior temporal 238.26
 frontal 238.25
 occipital 238.28
 posterior temporal 238.27
 Discus
 articularis 60.3, 60.18, 60.23, 62.13, 404.35
 interpubicus 66.18
 intervertebralis 56.10
 nervi optici 360.1
 Distal 396.34
 end of phalanx 40.31
 phalanx
 fingers 40.27
 toes 52.27
 tuberosity 40.28, 52.28
 radioulnar joint 62.12
 surface, tooth 110.29
 Distalis 396.34
 Diverticula ampullae 160.15
 Divisiones
 anteriores 336.17
 posteriores 336.18
 Dorsal 396.16
 artery
 of clitoris 224.19
 of penis 224.17
 branch(-es)
 abdominal aorta 216.23
 azygos vein 246.14
 to corpus callosum, medial occipital artery 208.7
 great auricular nerve 334.29
 posterior intercostal arteries 212.7, 216.9, 216.17
 spinal nerve 334.10, 334.15
 ulnar nerve 338.19
 calcaneocuboid ligament 70.31a
 carpal
 branch
 radial artery 214.5
 ulnar artery 214.25
 network 214.6
 carpometacarpal ligaments 64.8
 Dorsal
 cuneonavicular ligaments 70.31
 digital
 arteries 214.8, 228.6
 nerves
 of foot 344.25
 of hand 338.20, 340.10
 of lateral surface of great toe 344.28
 of medial surface of second toe 344.28
 veins of foot 252.19
 hypothalamic
 nucleus 304.3
 region 302.14
 intercarpal ligaments 62.24
 lateral nucleus 300.3
 ligaments of tarsus 70.23
 lingual vein 234.29
 longitudinal fasciculus 304.14
 medial nucleus 298.22
 mesentery 178.1
 metacarpal
 arteries 214.7
 ligaments 64.12
 veins 244.33
 metatarsal
 ligaments 72.15
 veins 252.20
 muscles 74.1
 nasal artery 202.21
 nerve
 of the clitoris 346.23
 of the penis 346.22
 pancreatic artery 218.27
 radiocarpal ligament 62.18
 regions 400.8
 root 334.6
 ganglion 334.7
 sacroccygeus muscle 88.4
 sacroiliac ligaments 66.14
 scapular
 artery 210.24, 210.24a
 nerve 336.20
 vein 244.11
 side of finger 400.50
 supraoptic commissure 304.12
 surface
 of sacrum 4.28
 of toe 402.28b
 tarsal arteries 228.5
 tarsometatarsal ligaments 72.10
 thalamus 296.20
 tubercle 38.15
 vagal nucleus 282.7
 vein of corpus callosum 242.12
 venous
 arch of foot 252.18
 network of foot 252.17
 plexus of hand 244.28
 Dorsalis 396.16
 Dorsolateral tract 278.5
 Dorsomedial hypothalamic nucleus 304.2

- Dorsum
linguae 112.31
manus 400.38
nasi 134.20
pedis 402.19
penis 162.31
sellae 10.9
of tongue 112.31
- Ductulus(-i)
aberrantes 160.7
 inferior 160.9
 superior 160.8
alveolares 152.3
biliferi 132.7
efferentes testis 158.32
excretorii 368.13
interlobulares 132.6
prostatici 162.21
transversi epoophorontis 170.19
- Ductus(-i)
arteriosus 192.1
choledochus (biliaris) 134.12
cochlearis 372.15
cysticus 134.10
deferens 160.13
 ampulla 160.14
 diverticula 160.15
 vestigialis 170.22
ejaculatorius 160.19
endolymphaticus 370.7
epididymidis 160.6
epoophorontis longitudinalis 170.18
excretorius (seminal vesicle) 160.24
glandula bulbourethralis 162.25
hepaticus
 communis 132.8
 dexter 132.9
 sinister 132.12
incisivus 136.25
lactiferi 39.25
lobi caudati
 dexter 132.15
 sinister 132.16
lymphaticus(-i) 254.15
 dexter 254.16
mesonephricus 172.32
nasolacrimalis 368.23
pancreaticus 128.17
 accessorius 128.19
paramesonephricus 172.33
paraurethrales 164.36, 172.20
parotideus 110.11
reuniens 372.1
semicirculares 370.11
 anterior 370.12
 lateral 370.14
 posterior 370.13
sublingulis
 major 110.3
 minor 110.4
- Ductus(-i)
submandibularis 110.6
sudorifer 394.13
thoracicus 254.17
 dexter 254.16
thyroglossalis 114.13
utriculosaccularis 370.9
venosus 248.9
- Duodenal
branches
 anterior superior pancreaticoduodenal
 artery 218.24
 posterior superior pancreaticoduodenal
 artery 218.17
flexure
 inferior 124.8
 superior 124.7
fold
 inferior 178.30
 superior 178.28
glands 124.14
impression 130.10
papilla
 greater 124.12
 lesser 124.13
recess
 inferior 178.31
 superior 178.29
- Duodenojejunal
flexure 124.9
fold 178.28
- Duodenomesocolic fold 178.30
- Duodenum 124.1
- Dura mater
cranial 268.23
spinal 268.31
- Dural sinuses 238.8
- E**
- Ear
external 386.1
internal 370.2
lobe 386.9
middle 378.15
- Eardrum 380.21
- Eccrine sweat glands 394.11
- Efferent
ductules of testis 158.32
glomerular arteriole 156.6
lymphatic vessel 254.25
nerve fibers 407.7
- Ejaculatory duct 160.19
- Elbow 400.23
joint 62.1
- Ellipsoidal joint 404.27
- Elliptical recess of vestibule 374.23
- Emboliform nucleus 290.20
- Embryological terminology 172.22
- Eminentia
arcuata 14.3
collateralis 314.14
- Eminentia
conchae 388.7
cruciformis 8.28
fossae triangularis 388.9
frontalis 18.4
hypothenaris 400.41
iliopectinea (iliopectinea) 44.14
intercondylaris 46.34
maxillaris 22.17
medialis 286.23
orbitalis 26.6a
pyramidalis 380.13
scapulae 388.8
thenaris 400.40
- Emisary
veins 240.1, 406.46
 condylar 240.4
 mastoid 240.3
 occipital 240.5
 parietal 240.2
- Enamel (enamelum) 112.10
- Encephalon 278.14
- End bulbs of Krause 390.22
- Endocardium 186.13
- Endocrine
glands 182.1
 pancreas 128.21
- Endolymph 370.4
- Endolymphatic
duct 370.7
sac 370.8
- Endomysium 405.25
- Endoneurium 407.3
- Endopeduncular nucleus 294.6
- Endopelvic fascia 174.21
- Endosteum 402.33
- Endothoracic fascia 152.8
- Enteric plexus 350.3
- Ependyma 406.55
- Epicanthus 366.6
- Epicondylus
lateralis
 (femur) 46.25
 (humerus) 36.30
medialis
 (femur) 46.22
 (humerus) 36.28
- Epidermis 390.9
- Epididymal branches of testicular artery 222.2a
- Epididymis 160.1
body 160.3
duct 160.6
head 160.2
inferior ligament 162.5
lobules (cone) 160.5
sinus 162.6
superior ligament 162.4
tail 160.4
- Epidural space 268.33
- Epigastric
artery
 inferior 224.21
 superficial 224.30
 superior 210.12

- Epigastric
 fold 180.18
 lymph nodes, inferior 262.12
 region 400.3
 vein(-s)
 inferior 250.24
 superficial 252.4
 superior 234.15
- Epigastrum 400.3
- Epiglottis 142.3
 stalk 142.4
- Epimysium 405.23a
- Epineurium 407.5
- Epiphysal
 cartilage 402.49
 line 404.1
- Epiphysis 296.9, 402.46
- Epiploic foramen 176.29
- Episclera 354.31
- Episcleral
 arteries 202.12
 space 364.22
 veins 244.5
- Epistropheus 4.11
- Epithalamic commissure 296.8, 296.16
- Epithalamus 296.3
 sections 296.10
- Epithelium
 anterior, of cornea 356.7
 ductus semicircularis 370.17
 folliculare 166.23
 lentis 362.15
 mucosae 405.41
 pigmentosum (iris) 358.13
 posterior (cornea) 356.11
- Epitympanic recess (attic) 378.18
- Epo-ophoron 170.17
 duct 170.18
- Eponychium 394.4
- Eptiglottic
 cartilage 142.6
 tubercle 142.5
- Equator 354.18
 of lens 362.22
- Esophageal
 branches 352.15b
 aorta 216.4
 inferior thyroid artery 210.18
 left gastric artery 216.30
 vagus nerve 332.17
 glands 120.14
 hiatus 84.30
 impression 130.8
 plexus 332.23, 348.7
 veins 234.7, 246.5
- Esophagus 120.2
- Ethmoid
 bone 20.1
 notch 18.27
- Ethmoidal
 air cells 20.7
 artery
 anterior 202.15
 posterior 202.14
- Ethmoidal
 bulla 138.9
 crest 22.28, 24.24
 foramina 18.25, 20.12
 anterior 32.21
 posterior 32.22
 infundibulum 20.8
 labyrinth 20.6
 nerve
 anterior 322.5
 posterior 322.4
 process 20.20
 sinus 138.5
 sulcus 20.27
 veins 242.27
- Ethmoidolacrimal suture 54.21
- Ethmoidomaxillary suture 54.20
- Eustachian tube 384.13
- Excavatio
 disci 360.2
 rectouterina 180.31
 rectovesicalis 180.33
 vesicouterina 180.32
- Excretory duct(-s)
 of lacrimal glands 368.13
 of seminal vesicle 160.24
- Exocrine pancreas 128.15
- Extensor 396.45
 retinaculum 92.22
 inferior 100.13
 superior 100.11
 side of fingers 400.50
- External 396.30a
 abdominal oblique muscle
 86.9
 acoustic (auditory) meatus
 16.3, 386.2
 cartilaginous part 386.4
 hairs 392.7
 opening 16.4
 anal sphincter 126.31
 aperture, perilymphatic duct
 372.14
 axis of eyeball 354.20
 branch
 accessory nerve 332.36
 superior laryngeal nerve
 332.11
 capsule 318.6
 carotid
 artery 194.9
 nerves 350.31
 plexus 352.1
 ear 386.1
 filum terminale 268.32
 granular layer, cerebral cortex
 316.4
 iliac
 artery 224.20
 lymph nodes 264.21
 vein 250.23
 intercostal
 membrane 58.25, 84.16
 muscles 84.15
 jugular vein 238.1
- External
 laryngeal nerve 332.11
 lip of iliac crest 42.16
 male genitalia 162.26
 medullary laminae 296.23, 298.23
 nasal
 branch(-es)
 of anterior ethmoidal
 nerve 320.10
 of infraorbital nerve
 324.10
 veins 236.10
 nose 134.18
 occipital
 crest 8.24
 protuberance 8.22
 opening
 of acoustic canal 386.3
 of cochlear canaliculus 14.22
 of female urethra 172.14
 of vestibular aqueduct 14.16
 palatine vein 236.16
 pudendal
 arteries 224.32
 veins 252.2
 pyramidal layer, cerebral cortex 316.5
 sheath, optic nerve 354.12
 spermatic fascia 160.27
 spiral sulcus 372.29
 surface
 frontal bone 18.3
 parietal bone 16.27
 table (lamina) 28.22
 urethral orifice 164.33
 wall of cochlear duct 374.4
- Externus 396.30a
- Extracapsular ligaments 404.45
- Extraperitoneal
 fascia 176.21
 organ 176.22
 space 176.19a
- Extreme capsule 318.5
- Extremities
 acromialis 34.31
 anterior (spleen) 268.9
 inferior (testis) 158.18
 posterior (spleen) 268.8
 sternalis 34.26
 superior (testis) 158.17
 tubaria (tubalis) 166.12
 uterina 166.13
- Eye 354.3
 accessory organs 364.1
 muscles 364.2
- Eyeball 354.15
- Eyebrow 366.1
 hairs 392.4
- Eyelashes 366.15, 392.5
- Eyelids 366.2
 lower 366.4
 upper 366.3

F

Facial

- artery 196.7
 - transverse 198.3
- bones 22.1
- canal 12.22
 - genu 12.23
- colliculus 286.24
- ganglion 328.20
- lymph nodes 256.10
- muscles 78.5
- nerve 328.1
 - area 378.9
 - genu 286.4, 328.2
 - nucleus 286.3
 - sensory root 328.19
- regions 398.14
- vein 236.5
 - deep 236.14

Facies

- antebrachialis
 - anterior 400.30
 - posterior 400.31
- anterior
 - (adrenal gland) 182.30
 - (cornea) 356.5
 - (iris) 358.4
 - (kidney) 154.8
 - (lens) 362.19
 - (maxilla) 22.8
 - palpebralis 366.5
 - (pancreas) 128.6
 - partis petrosae 14.1
 - (patella) 48.35
 - (prostate) 162.13
 - (radius) 38.10
 - (scapula) 34.4
 - (ulna) 38.26
- anterolateralis
 - (arytenoid cartilage) 140.13
 - (humerus) 36.13
- anteromedialis (humerus) 36.12
- approximalis (tooth) 110.27
- articularis 404.2
 - acromii
 - (clavicle) 34.32
 - (scapula) 34.11
 - anterior (axis) 4.14
 - (arytenoid cartilage) 140.11
 - arytenoidea 140.4
 - calcanea
 - anterior 50.15
 - media 50.14
 - posterior 50.12
 - capitis
 - costae (rib) 6.9
 - fibulae 48.17
 - carpalis (radius) 38.17
 - cuboidea 52.6
 - fibularis 46.31
 - inferior
 - (atlas) 4.4
 - (tibia) 48.14

Facies

- articularis
 - malleoli 48.12, 48.28
 - navicularis (talus) 50.16
 - (patella) 48.34
 - posterior (axis) 4.15
 - sternalis (clavicle) 34.27
- superior
 - (atlas) 4.3
 - (tibia) 46.28
- talaris
 - anterior 52.1
 - media 52.2
 - posterior 52.3
- (temporal bone) 16.21
- thyroidea 140.5
- tuberculi costae (rib) 6.15
- auricularis (ilium) 4.22, 42.30
- brachialis
 - anterior 400.21
 - posterior 400.22
- cerebralis 10.24, 16.23
- colica (spleen) 268.7
- costalis
 - (lung) 148.10
 - (scapula) 34.4
- cruralis
 - anterior 402.13
 - posterior 402.14
- cubitalis
 - anterior 400.24
 - posterior 400.25
- diaphragmatica
 - (heart) 184.13
 - (liver) 128.23
 - (lung) 148.15
 - (spleen) 268.3
- digitalis(-es)
 - dorsales 400.50, 402.28b
 - plantaris 28a
 - ventrales 400.49
- distalis (tooth) 110.29
- dorsalis ossis sacri 4.28
- externa
 - (frontal bone) 18.3
 - (parietal bone) 16.27
- facilis dentis 110.25
- femoralis
 - anterior 402.5
 - posterior 402.7
- gastrica (spleen) 268.6
- glutealis (ilium) 42.25
- inferior
 - hemispherii cerebri 310.1
 - linguae 112.34
 - (pancreas) 128.8
 - partis petrosae 14.23
- inferolateralis 162.15
- infratemporalis (maxilla) 22.14
- interlobaris (lung) 148.16
- interna
 - (frontal bone) 18.14
 - (parietal bone) 16.25
- intervertebralis 2.3a
- intestinalis (uterus) 168.11

Facies

- lateralis
 - (fibula) 48.21
 - (ovary) 166.9
 - (radius) 38.11
 - (testis) 158.19
 - (tibia) 48.6
 - (zygomatic bone) 26.2
- lingualis (tooth) 110.26
- lunata (acetabulum) 42.9
- malleolaris
 - lateralis (talus) 50.10
 - medialis (talus) 50.9
- masticatoria dentis 110.24
- maxillaris
 - (palatine bone) 24.18
 - (sphenoid) 10.26
- medialis
 - (arytenoid cartilage) 140.19
 - (fibula) 48.22
 - (hemispherii cerebri) 310.1
 - (lung) 148.11
 - (ovary) 166.8
 - (testis) 158.19
 - (tibia) 48.3
 - (ulna) 38.27
- mediastinalis (lung) 148.13
- mesialis (tooth) 110.28
- nasalis 24.17
 - (maxilla) 22.18
 - (palatine bone) 24.17
- occlusalis dentis 110.24
- orbitalis
 - (frontal bone) 18.22
 - (maxilla) 22.4
 - (sphenoid) 10.27
 - (zygomatic bone) 26.4
- palatini 24.29
- patellaris (femur) 46.26
- pelvica (sacrum) 4.24
- poplitea (femur) 46.20
- posterior
 - (adrenal gland) 182.31
 - (arytenoid cartilage) 140.20
 - (cornea) 356.6
 - (fibula) 48.23
 - (humerus) 36.14
 - (iris) 358.5
 - (kidney) 154.9
 - (lens) 362.20
 - palpebralis 366.7
 - (pancreas) 128.7
 - partis petrosae 14.11
 - (prostate) 162.14
 - (radius) 38.9
 - (scapula) 34.6
 - (tibia) 48.4
 - (ulna) 38.25
- pulmonalis (heart) 184.14
- renalis
 - (adrenal gland) 182.32
 - (spleen) 268.5
- sacrospinalis (ilium) 42.29
- sternocostalis (heart) 184.12
- superior (talus) 50.8

Facies

- superolateralis hemispherii 306.15
 - symphysialis (pubis) 44.11
 - temporalis
 - (frontal bone) 18.10
 - (sphenoid) 10.25
 - (temporal bone) 16.14
 - (zygomatic bone) 26.3
 - urethralis (penis) 162.32
 - vesicalis (uterus) 168.13
 - vestibularis dentis 110.25
 - visceralis
 - (liver) 130.1
 - (spleen) 268.4
- Falciform
- ligament of liver 178.22
 - margin 100.4
 - process 66.7
- Fallopian tube 166.29
- False ribs 6.4
- Falx
- cerebelli 268.27
 - cerebri 268.24
 - inguinalis 86.21
 - septi 188.22
- Fascia(-ae) 405.26
- antebrachii 92.20
 - axillaris 92.15
 - brachii (brachialis) 92.17
 - buccopharyngea 80.18, 118.34a
 - bulbi 364.21
 - cervicalis 82.12
 - clavipectoralis 84.10
 - clitoridis 172.12
 - cremasterica 160.29
 - cribrosa 100.7
 - cruris 100.8
 - deltoidea 92.16
 - diaphragmatica
 - pelvis
 - inferior 174.29
 - superior 174.26
 - urogenitalis
 - inferior 176.6
 - superior 176.5
 - dorsalis
 - manus 92.21
 - pedis 100.16
 - endopelvina 174.21
 - endothoracica 152.8
 - extraperitonealis 176.21
 - iliaca 98.19
 - lata femoris 98.13
 - masseterica 80.19
 - musculares 364.20
 - nuchae 76.21
 - obturatoria 174.20
 - orbitales 364.17
 - parotidea 80.20
 - pectoralis 84.9
 - pelvis
 - parietalis 174.19
 - visceralis 174.21

Fascia(-ae)

- penis
 - profunda 164.21
 - superficialis 164.20
 - perinei superficialis 176.12
 - peritoneoperinealis 174.23
 - pharyngobasilaris 118.15
 - phrenicopleuralis 152.10
 - profundus 405.26b
 - prostaticae 174.22
 - renalis 154.12
 - retinens rostralis 178.27
 - spermatICA
 - externa 160.27
 - interna 160.30
 - superficialis 405.26a
 - temporalis 80.21
 - thoracica 84.22
 - thoracolumbalis 76.20
 - transversalis 86.28
- Fasciculus(-i)
- atrioventricularis 186.10
 - brachial plexus 336.18a
 - cuneatus 278.13, 280.4, 280.16
 - gracilis 278.12, 280.6, 280.14
 - hypothalamici 304.10
 - interfascicularis 278.11
 - lateralis 336.25
 - lenticularis 302.9
 - longitudinalis(-es)
 - (cruciform ligament) 58.6
 - dorsalis 304.14
 - inferior 316.17
 - medialis 280.23, 284.19, 292.24
 - posterior 280.24, 284.20, 292.25
 - superior 316.16
 - mamillothalamicus 302.7, 304.16
 - mamillogementalis 304.15
 - medialis 336.26
 - parieto-occipitopontinus 318.28
 - peduncularis 302.10
 - posterior 336.27
 - proprii
 - anteriores 276.20
 - laterales 276.27
 - posteriores 278.8
 - prosencephalicus
 - medialis 304.19
 - pyramidalis 280.10
 - septomarginalis 278.10
 - subthalamicus 302.6
 - sulcomarginalis 276.21
 - thalamicus(-i) 300.21, 302.5
 - transversi 92.25, 100.18
 - uncinatus 316.18
- Fastigial nucleus 290.22
- Fat pad, infrapatellar 68.19
- Fatty capsule 154.14
- Fauces 116.2
- isthmus 116.3
 - muscles of 116.17

Female pudendum 170.24

Femoral

- artery 224.29
 - lateral circumflex 226.8
 - medial circumflex 226.3
 - branch of genitofemoral nerve 342.23
 - canal 98.24
 - cutaneous nerve
 - lateral 342.24
 - posterior 344.14
 - nerve 344.1
 - plexus 350.8
 - ring 100.1
 - septum 100.2
 - triangle 98.23, 402.6
 - veins 252.1
 - lateral circumflex 252.11
 - medial circumflex 252.10
- Femur 46.2, 402.4
- head 46.3
 - ligament of 66.28
 - pit (fovea) 46.4
 - neck 46.5
 - shaft 46.12
- Fenestra
- cochleae (rotunda) 380.1
 - vestibuli (ovalis) 378.23
- Fetal part of placenta 172.29
- Fibrae
- arcuatae
 - cerebri 316.14
 - externae
 - anteriores 278.24, 282.23
 - posteriores 282.24
 - internae 280.19
 - circulares 356.26
 - corticonucleares 280.12, 284.11, 292.3
 - corticopontinae 284.13, 292.4
 - corticoreticulares 284.12, 292.23, 318.17
 - corticorubrales 318.16
 - corticospinales 280.11, 284.10, 292.2, 318.15
 - corticotectales 318.24
 - corticothalamicae 318.18
 - dentatorubrales 294.9
 - frontopontinae 292.6
 - intercruales 86.17
 - intrathalamicae 302.11
 - lentic 362.14
 - longitudinales 356.25
 - meridionales 356.25
 - obliquae (stomach) 122.9
 - paraventriculares 304.22
 - parietotemporopontinae 292.5
 - periventriculares 302.12, 304.11
 - pontis
 - longitudinales 284.9
 - transversae 284.14
 - pontocerebellares 284.15
 - radiales 356.27
 - striae terminalis 304.18

- Fibrae**
 supraopticae 304.21
 temporopontinae 318.25
 thalamoparietales 318.19
 zonulares 362.25
Fibroelastic membrane of larynx
 144.9
Fibrous
 capsule 154.15
 of thyroid gland 182.7
 joints 404.12
 layer, tendon sheath 405.19
 membrane 404.39
 pericardium 184.2
 ring 186.6
 sheaths
 of digits of foot 100.22
 of fingers 92.27
 trigone 186.5
 tunic of eyeball 354.23
Fibula 48.15
 articular facet for 46.31
 head 48.16
 anterior ligament 68.21
 apex 48.18
 posterior ligament 68.22
 neck 48.19
 shaft 48.20
Fibular 396.39
 artery 228.12
 circumflex branch, posterior tibial artery 228.9
 collateral ligament 68.12
 margin of foot 402.21
 nerve 344.18
 communicating branch 344.20
 deep 344.26
 superficial 344.21
 node 266.23
 notch 48.13
 retinaculum
 inferior 100.15
 superior 100.14
 veins 252.22
Fibularis 396.39
Fila radicularia 334.4
Filiform papillae 114.4
Filum terminale 272.17
 externum 268.32
 internum (pia) 272.11
Fimbria(-ae) 314.19
 ovarica 166.33
 tubae 166.32
Fimbriated fold 112.35
Fingers 40.23, 400.43
 fibrous sheaths 92.27
 index 400.45
 little 400.48
 middle 400.46
 ring 400.47
 synovial sheaths 92.30
First rib 6.17a
Fissura
 antitragohelicina 388.3
Fissura
 cerebelli 288.13
 choroidea 314.9
 horizontalis
 (cerebellum) 288.34
 (pulmonis dextri) 148.27
 ligamenti
 teretis 130.3
 venosi 128.31
 limitans 306.13
 longitudinalis
 cerebralis 306.7
 mediana anterior 272.19, 278.18
 obliqua (lung) 148.26
 orbitalis
 inferior 32.24
 superior 10.22, 32.23
 petro-occipitalis 30.20
 petrosquamosa 14.32
 petrotympanica 14.31
 posterolateralis 288.39
 prima 288.24
 pterygomaxillaris 30.15
 secunda 288.30
 sphenopetrosa 30.19
 telodiencephalica 306.8
 transversa cerebralis 306.8
 tympanomastoidea 14.34
 tympanosquamosa 14.33
Flat
 bone 402.43
 suture 404.17
Flexor 396.44
 retinaculum 92.26, 100.12
 side of fingers 400.49
Flexura(-ae)
 coli
 dextra 124.27
 sinistra 124.29
 duodeni
 inferior 124.8
 superior 124.7
 duodenojejunalis 124.9
 perinealis 126.15
 sacralis 126.14
Floating ribs 6.5
Flocculonodular lobe 290.1
Flocculus 290.3
 peduncle 290.4
Flumina pilorum 392.17
Foliate papilla 114.9
Folium(-a)
 cerebelli 288.12
 of vermis 288.27
Follicular epithelium 166.23
Folliculus(-i)
 linguales 114.15
 lymphatici 406.22
 aggregati 122.33
 appendicis vermiformis 124.24
 gastrici 122.19
 solitarii 122.32
 splenici (lienales) 268.20
Folliculus(-i)
 ovarici
 primarii 166.18
 vesiculosi 166.19
 pili 392.11
Fonticulus(-i)
 anterior 32.28
 cranii 32.27
 mastoideus (posterolateralis) 32.31
 posterior 32.29
 sphenoidalis (anterolateral) 32.30
Foot 402.17
 dorsal digital nerves 344.25
 dorsum 402.19
 joints 70.11, 72.22
 lateral margin 402.21
 medial margin 402.22
 plantar surface 402.20
Foramen(-ina)
 alveolaria 22.15
 apicis radialis dentalis 112.4
 caecum (cecum) 18.17
 linguae 114.12
 costotransversarium 58.19
 cribrosa 20.2
 epiploicum 176.29
 ethmoidale 18.25, 20.12
 anterior 32.21
 posterior 32.22
 frontale 18.9
 incisivum 24.14, 30.26
 infraorbitale 22.9
 interventriculare 298.3, 314.3
 intervertebrale 2.7, 4.26
 jugulare 30.18
 lacerum 30.21
 of Luschka 288.10
 of Magendie 288.9
 magnum 8.3
 mandibulae 28.6
 mastoideum 12.21
 mentale 26.18
 nasalia 20.27a
 nervosa 372.22
 nutriens 404.6
 obturarium (obturatorium) 42.4
 omentale 176.29
 ovale 10.34, 186.21
 valve 188.22
 palatine minora 24.30
 palatinum majus 30.23
 papillaria 154.35
 parietale 16.39
 petrosum 10.37
 rotundum 10.33
 sacralia
 anteriora (pelvica) 4.27
 posteriora 4.30
 sciaticum (ischiadicum) majus 66.9
 minus 66.10
 singulare 378.14
 sphenopalatinum 32.11

Foramen(-ina)
 spinosum 10.36
 styломastoideum 14.27
 supraorbitale 18.8
 thyroideum 138.24
 transversarium 2.18
 venae cavae 84.32
 venarum minimarum 186.28
 venosum 10.35
 vertebrale 2.10
 zygomatico-orbitale 26.8
 zygomaticofaciale 26.9
 zygomaticotemporale 26.10
 Foraminal node 262.31
 Foraminous spiral tract 378.11
 Forceps
 frontalis 312.12
 major 312.14
 minor 312.12
 occipitalis 312.13
 Forearm 400.29
 Forebrain 296.1
 Forehead 28.33
 Formatio reticularis 276.16,
 280.27, 284.23, 292.22, 406.53
 Fornix 304.17, 312.21
 body of 312.23
 conjunctivae
 inferior 368.4
 superior 368.3
 crus of 312.22
 gastricus (ventricularis)
 120.23a
 of lacrimal sac 368.22
 pharyngis 116.25
 sacci lacrimales 368.22
 of stomach 120.23a
 vaginae 170.2
 Fossa(-ae) 178.26
 acetabuli (acetabularis) 42.7
 antheleis 388.6
 axillaris 398.41
 canina 22.10
 cerebellaris 8.34b
 cerebrralis 8.34a
 condylaris 8.17
 conoidea 36.26
 cranii (cranialis)
 anterior 30.2
 media 30.3
 posterior 30.4
 cubitalis 400.26
 digastrica 26.20
 glandulae lacrimales 18.26
 hyaloidea 362.7
 hypophysialis 10.8
 iliaca 42.24
 incisiva 30.24
 incudis 380.14
 infraclavicularis 398.35
 infraspinata (infraspinoza) 34.9
 infratemporalis 30.13
 inguinalis
 lateralis 180.19
 medialis 180.16

Fossa(-ae)
 intercondylaris 46.18
 interpeduncularis 290.32
 ischioanal 176.13
 jugularis 14.24
 lateralis cerebrralis 306.9
 malleoli lateralis 48.30
 mandibularis 16.20
 navicularis urethrae 164.31
 olecrani 36.25
 ovalis 186.19
 ovarica 180.29
 paravesicalis 180.21
 poplitea 402.11
 pterygoidea 12.5
 pterygopalatina 30.14
 radialis 36.27
 rhomboidea 286.20
 sacci lacrimales 20.25, 32.22b
 scaphoid 12.6
 subarcuata 14.14
 subscapularis 34.5
 supraclavicularis
 major 398.31
 minor 398.29
 supraspinata (supraspinosa)
 34.8
 supratonsillar 116.16
 supravesicalis 180.14
 temporalis 30.11
 tonsillar 116.15
 triangularis 386.16
 trochanterica 46.7
 vesicae biliaris 130.2
 vestibuli vaginae 170.33
 Fossula(-ae)
 fenestrae cochleae 380.3
 fenestrae vestibuli 378.24
 petrosa 14.29
 tonsillae 116.10, 116.28
 Fourth
 ventricle 286.19
 choroid plexus 272.3, 288.6
 lateral aperture 288.10
 median aperture 288.9
 tegmen 288.1
 tela choroidea 272.2, 288.5
 tenia 288.7
 Fovea(-ae)
 articularis 38.2
 capitis femoris 46.4
 centralis 360.4
 costalis
 inferior 2.26
 processus transversi 2.27
 superior 2.25
 dentis atlantis 4.5
 inferior 286.29
 oblonga 140.17
 pterygoidea 28.15
 sublingualis 26.24
 submandibularis 26.25
 superior 286.27
 triangularis 140.18
 trochlearis 18.24

Foveola(-ae) 360.5
 coccygea 390.7
 gastricae 122.16
 granulares 28.27
 suprameatica (suprameatalis)
 16.18
 Free margin
 nail 394.2
 ovary 166.10
 Frenulum(-a)
 of clitoris 172.8
 labii
 inferioris 108.21
 superioris 108.20
 labiorum pudendi 170.31
 linguae 114.2
 preputii 164.6
 valvae ilealis 124.21
 veli medullaris superioris
 288.3
 Frons 28.33
 Frontal 396.17
 angle 16.35
 bone 18.1
 external surface 18.3
 nasal part 18.18
 orbital part 18.21
 squama 18.2
 zygomatic process 18.13
 border
 parietal bone 16.34
 sphenoid 10.29
 branch
 superficial temporal artery
 198.7
 superior tympanic artery
 198.20
 crest 18.15
 diploic vein 238.25
 gyrus
 inferior 306.30
 medial 310.7
 middle 306.28
 superior 306.26
 lobe 306.22
 nerve 320.23
 notch/foramen 18.9
 operculum 306.31
 pole 306.23
 process 26.6
 of maxilla 22.25
 region 398.10
 sinus 18.28, 138.4
 opening 18.29
 septum 18.30
 sulcus
 inferior 306.29
 superior 306.27
 suture 18.6a, 54.11
 temporal line of 18.12
 tuber (tuberosity) 18.4
 veins 240.13
 Frontalis 396.17
 Frontoethmoidal suture 54.15
 Frontolacrimal suture 54.17

Frontomaxillary suture 54.16
 Frontonasal suture 54.14
 Frontoparietal operculum 308.7
 Frontopontine
 fibers 292.6
 tract 318.10
 Frontozygomatic suture 54.18
 Fundic stomach 120.23
 Fundiform ligament of penis 86.26
 Fundus
 gastricus (ventricularis) 120.23
 of internal auditory meatus 378.7
 meatus
 acustici interni 378.7
 of urinary bladder 156.28
 uteri 168.8
 vesicae 156.28
 biliaris 134.2
 Fungiform papillae 114.6
 Funiculus(-i)
 anterior 274.2, 276.19
 lateralis 274.3, 276.26, 278.22
 medullae spinalis 274.1
 posterior 274.4, 278.8
 separans 286.32
 spermaticus 160.25
 umbilicalis 172.30
 Fusiform
 layer
 cerebral cortex 316.8
 muscle 405.5

G

Galea aponeurotica 78.11
 Gallbladder 134.1
 body 134.3
 fundus 134.2
 neck 134.4
 Ganglion(-a) 407.10
 aorticorenalis 348.13
 autonomica 407.16
 capsule 407.11
 cardiaca 348.6
 cell layer (retina) 358.25
 cervicale
 medium 352.5
 superius 350.27
 cervicothoracicum (stellatum) 352.8
 ciliare 320.8, 352.29
 cochleare 330.16
 coelica 348.12
 craniospinalia 407.13
 extracranialia 330.19
 geniculi (geniculatum) 328.20
 impar 352.25
 inferius 330.19, 332.3
 intermedia 350.26
 intracranialia 330.18
 lumbalia (lumbaria) 352.21
 mesentericum
 inferius 348.16
 superius 348.14

Ganglion(-a)
 oticum 324.19, 326.17, 330.31, 352.31
 parasympatheticum (parasympatheticum) 407.22
 pelvica 352.35
 phrenica 348.17
 plexuum autonomicorum (visceralium) 348.3
 pterygopalatinum 322.16, 328.22, 352.30
 renalis 348.24
 sacralia 352.23
 sensorium(-a) 334.7
 neuricum cranialium 407.15
 spinale(-ia) 334.7, 407.14
 spirale cochlearis 374.9
 stroma 407.12
 sublinguale 328.29, 352.33
 submandibulare 326.8, 328.26, 352.32
 superius 330.18, 332.2
 sympatheticum (sympatheticum) 407.19
 terminale 352.28
 thoracicum(-a) 352.14
 splanchnicum 352.17
 trigeminale 320.17
 trunci sympathetici 350.23
 tympanicum 330.21
 vertebrale 352.6
 vestibulare 330.5
 visceralia 407.16
 Ganglionic branches
 lingual nerve 326.7
 maxillary nerve 322.15
 Gasserian ganglion 320.17
 Gaster 120.15
 Gastric
 areas 122.14
 artery(-ies)
 posterior 218.35a
 right 218.3
 short 218.34
 branches
 gastroepiploic artery 218.20, 218.32
 vagal trunk
 anterior 332.26
 posterior 332.27
 canal 120.26
 folds 122.12
 glands, proper 122.17
 impression 130.9
 lymph nodes 262.15
 pits (foveolae) 122.16
 plexus 348.20
 surface of spleen 268.6
 vein(-s)
 left 248.17
 right 248.18
 short 248.31
 Gastro-omental
 artery, left 218.31
 lymph nodes (left/right) 262.17

Gastro-omental
 vein
 left 248.32
 right 248.22
 Gastrocolic ligament 178.17
 Gastrooduodenal artery 218.13
 Gastroepiploic artery 218.19
 Gastrolienal ligament 178.16
 Gastropancreatic folds 176.35
 Gastrophrenic ligament 178.15
 Gastrosplenic ligament 178.16
 Gemma gustatoria 388.27
 General terminology 396.1, 405.36
 Genicular
 artery
 descending 226.1a
 lateral
 inferior 226.18
 superior 226.14
 medial
 inferior 226.19
 superior 226.15
 middle 226.16
 veins 252.14
 Geniculate
 body
 lateral 296.28
 medial 296.27
 ganglion 328.20
 Geniculum canalis facialis 12.23
 Genital
 branch of genitofemoral nerve 342.22
 corpuscles 390.25
 Genitalia
 female
 external 170.23
 internal 166.5
 male
 external 162.26
 internal 158.15
 Genitofemoral nerve 342.21
 Genitoinguinal ligament 162.9
 Genu 312.9
 capsulae internae 318.11
 nervi facialis 286.4, 328.2
 Genus 402.8
 Gingiva(-ae) 108.22, 112.13
 Gingival
 branches of inferior alveolar nerve 326.16a
 margin 108.23
 papilla 108.24
 sulcus 108.25
 Ginglymus 404.28
 Glabella 18.6
 Gland 406.4
 Glandula(-ae) 406.4
 adrenalis 182.29
 areolares 394.28
 biliares 134.16
 bronchiales 148.5
 buccales 108.33
 bulbourethralis (Cowper's) 162.24

- Glandula(-ae)
 ceruminosae 394.16
 cervicalis (uteri) 168.23
 ciliares (Molli) 368.6
 circumanales 394.15
 conjunctivales 368.8
 cutis 394.9
 duodenales 124.14
 endocrinae 182.1
 esophageae 120.14
 gastrica propria 122.17
 glomiformes 394.10
 intestinales 122.31, 126.11
 labiales 108.32
 lacrimalis 368.10
 accessoriae 368.14
 fossa for 18.26
 laryngeales 144.15
 linguales 108.36
 anterior 108.37
 mammaria 394.21
 molares 108.34
 mucosa 406.7
 nasales 136.16a
 olfactoriae 388.25
 oris 108.30a
 palatinae 108.35
 parathyroidea
 inferior 182.12
 superior 182.11
 parotideae 110.7
 accessoria 110.10
 pharyngis 118.18
 pinealis 182.22, 296.9, 296.17
 pituitaria 182.13
 preputiales 164.22
 prostatica 162.10
 pylorica 122.18
 salivariae
 maiores 110.1
 minores 108.31
 sebaceae (Zeiss) 368.7, 394.17
 seromucosa 406.9
 serosa 406.8
 sublingualis 110.2
 submandibularis 110.5
 sudorifer merocrina (eccrina)
 394.11
 suprarenalis(-es) 182.29
 accessoriae 182.39
 tarsales 366.21
 thyroidea 182.2
 accessoriae 182.6
 tracheales 144.27
 tubariae 384.23
 urethrales 164.35, 172.18
 uterinae 168.30
 vestibularis(-es)
 major 172.3
 minores 172.2
- Glandular branches
 inferior thyroid artery 210.16
 submandibular ganglion
 328.28
 submental artery 196.11
- Glans
 clitoridis 172.7
 penis 164.1
 Glaserian fissure 14.31
- Glenohumeral
 joint 60.29
 ligaments 60.32
- Glenoid
 cavity 34.20
 lip 60.30
- Globose nucleus 290.21
- Globus pallidus
 lateralis 316.29
 medialis 316.31
- Glomerular
 arteriole
 afferent 156.5
 efferent 156.6
 capsule 154.39
- Glomerulus(-i) 154.38
 arteriosi cochleae 374.14
- Glomus
 caroticum 194.7
 choroideum 272.7
 coccygeum 216.27
- Glossoepiglottic fold
 lateral 118.11
 median 118.10
- Glossopharyngeal nerve 330.17
- Glottis 144.3
- Gluteal
 aponeurosis 94.8a
 artery
 inferior 222.24
 superior 222.19
 fold 402.3
 line
 anterior 42.26
 inferior 42.28
 posterior 42.27
 lymph nodes
 inferior 266.3
 superior 266.2
 nerves
 inferior 344.13, 344.15
 medial 342.11
 superior 342.5, 344.12
 region 402.2
 surface, ilium 42.25
 tuberosity 46.17
 veins
 inferior 250.3
 superior 250.2
- Gnathion 26.17
- Gomphosis 112.11
- Gonion 28.3
- Graafian follicles 166.19
- Gracile
 lobule 288.36
 tubercle 280.7
- Granular pits 28.27
- Granulationes arachnoideae
 270.12
- Gray
 columns 274.16
- Gray
 commissure, anterior/posterior
 276.16a
 communicating ramus 334.11a
 matter 274.13, 406.51
 central intermediate 276.12
 lateral intermediate 276.13
 ramus communicans 407.21
- Great
 auricular nerve 334.28
 cerebral
 vein 242.1
- Greater
 alar cartilage 134.25
 arterial circle of iris 358.15
 curvature of stomach 120.18
 duodenal papilla 124.12
 horn (cornu) 28.19
 occipital
 nerve 334.19
 omentum 178.14
 palatine
 artery 200.6
 canal 30.17
 foramen 30.23
 nerve 322.22
 sulcus 22.23, 24.20
 pelvis 44.24
 petrosal nerve 328.24
 groove for 14.6
 hiatus of canal 14.4
 ring (circle) of iris 358.6
 saphenous vein 252.7
 sciatic
 foramen 66.9
 notch 44.6
 splanchnic nerve 352.16
 trochanter 46.6
 tubercle (humerus) 36.6
 crest 36.9
 tympanic spine 16.5
 vestibular glands 172.3
 wing of sphenoid 10.23
- Groove
 for auditory tube 10.39
 for greater petrosal nerve
 14.6
 for inferior petrosal sinus 8.7,
 14.18
 for lesser petrosal nerve 14.7
 for middle meningeal artery
 16.26b
 for middle temporal artery
 16.15
 for occipital artery 12.20
 for occipital sinus 8.33a
 for peroneus longus tendon
 52.4, 52.13
 for popliteus 46.25a
 for radial nerve 36.15
 for sigmoid sinus 8.33, 12.19,
 16.26
 for spinal nerve 2.22
 for subclavian artery 6.19
 for subclavian vein 6.20

Groove
 for superior petrosal sinus 14.10
 for superior sagittal sinus 8.31,
 16.26a, 18.16, 28.26
 for transverse sinus 8.32
 for ulnar nerve 36.29
see also Sulcus
 Gubernaculum testis 162.8
 Gums 108.22
 Gustatory organ 388.26
 Gyrus(-i)
 angularis 308.9
 breves insulae 308.27
 cerebrales 306.4
 cinguli (cingulatum) 310.3
 dentatus 310.13
 fasciolaris 312.18
 frontalis
 inferior 306.30
 medialis 310.7
 medius 306.28
 superior 306.26
 hippocampi (parahippocampalis) 310.15
 insulae 308.26
 lingualis 310.17
 longus insulae 308.28
 occipitotemporalis
 lateralis 310.22
 medialis 310.20
 olfactorii
 lateralis 310.31
 medialis 310.31
 orbitales 310.25
 paraterminalis 312.5
 postcentralis 308.2
 precentralis 306.25
 rectus 310.23
 supramarginalis 308.8
 temporalis(-es)
 inferior 308.24
 medius 308.22
 superior 308.19
 transversi 308.18

H

Habenula 296.4
 commissure 296.7, 296.13
 trigone 296.6
 Habenular
 nuclei (medial/lateral) 296.11
 sulcus 296.5
 Habenulointerpeduncular tract
 296.12
 Haema (hema) 406.18
 Hair(-s)
 axillary 392.9
 of beard 392.6
 bulb of 392.15
 cruciate pattern of growth
 392.19
 of external acoustic meatus
 392.7
 of eyebrow 392.4

Hair(-s)
 follicle 392.11
 of nasal vestibule 392.8
 papilla 392.12
 pubic 392.10
 root 392.14
 scalp 392.3
 shaft 392.13
 streams 392.17
 whorled pattern of growth
 392.18
 Hallux 402.26
 Hamate 40.13
 hamulus (hook) of 40.14
 Hamulus
 lacrimalis 20.24
 laminae spiralis 378.2
 ossis hamati 40.14
 pterygoideus 12.10
 sulcus 12.11
 Hand 400.37
 dorsum 400.38
 fascia of 92.21
 joints 64.1, 64.20
 palm 400.39
 Hard palate 30.22, 108.16
 Haustra coli 124.33
 Head
 of caudate nucleus 316.23
 crown of 28.30
 of epididymis 160.2
 of femur 46.3
 pit (fovea) 46.4
 of fibula 48.16
 apex 48.18
 of humerus 36.3
 lymph nodes 256.2
 of mandible 28.13
 of metacarpal bone 40.20
 of metatarsal bone 52.20
 of muscle 405.3
 muscles of 76.22
 of pancreas 128.2
 of posterior horn 276.4
 of radius 38.2
 regions 398.9
 of rib 6.8
 joints 58.11
 of stapes 382.3
 of talus 50.4
 of ulna 38.32
 Heart 184.10
 base 184.11
 conducting system 186.7a
 vortex 186.2
 Heel 402.18
 bone 50.22
 Helicine
 arteries 164.18
 branches of uterine artery
 224.2a
 Helicotrema 378.3
 Helix 386.11
 crus 386.12
 groove of 388.5

Helix
 spine 386.13
 tail 386.14
 Hemiazzygos vein 246.3
 accessory 246.4
 Hemisphaerium
 cerebelli 288.17
 cerebrialis 306.14
 Hemorrhoidal plexus 250.7
 Hepar 128.22
 Hepatic
 artery
 common 218.1
 proper 218.2
 branches of vagus nerve
 332.28
 duct
 left 132.12
 right 132.9
 ligaments 178.20
 lobules 132.1
 lymph nodes 262.29
 plexus 348.18
 veins 246.24
 intermediate 246.26
 left 246.27
 right 246.25
 Hepatocolic ligament 178.13
 Hepatoduodenal ligament 178.12
 Hepatogastric ligament 178.11
 Hepatopancreatic
 ampulla 134.14
 fold 176.35a
 Hepatorenal
 ligament 178.25
 recess 180.11
 Hiatus
 adductorius 98.18
 aorticus 84.29
 canalis
 nervus petrosi majoris 14.4
 nervus petrosi minoris 14.5
 maxillaris 22.22
 oesophageus 84.30
 sacralis 4.35
 saphenus 100.3
 semilunaris 20.9, 138.11
 tendineus 98.18
 Highest
 intercostal artery 212.5
 nuchal line 8.26
 Hilum
 adrenal gland 182.35
 liver 130.6
 lung 148.20
 lymph node 254.28
 nuclei
 dentati 290.19
 olivaris inferioris 280.30
 ovarii 166.7
 pulmonis 148.20
 renale 154.6
 splenicum 268.12
 Hindbrain 278.16
 Hinge joint 404.28

- Hip
bone 42.3
joint 66.20
capsule 66.21
socket 42.5
region 402.3a
- Hippocampal sulcus 310.14
- Hippocampus 314.16
- Hirci 392.9
- His' bundle 186.11
- Horizontal 396.3
fissure
of cerebellum 288.34
of right lung 148.27
part of duodenum 124.5
plate 24.27
- Horizontalis 396.3
- Humeral
artery
anterior circumflex 212.23
posterior circumflex 212.24
head
of extensor carpi ulnaris 90.19
of flexor carpi ulnaris 90.4
of pronator teres 88.27
- Humeroradial joint 62.3
- Humeralnlar
head of flexor digitorum superficialis 90.7
joint 62.2
- Humerus 36.2
body 36.11
capitulum 36.23
condyle 36.22
head 36.3
neck
anatomical 36.4
surgical 36.5
trochlea 36.24
- Humor
aqueus 360.17, 362.2
vitreus 362.9a
- Hyaloid
artery 362.5
canal 362.6
fossa 362.7
membrane 362.8
- Hymen 170.8
- Hymenal caruncle 170.9
- Hyoid
body 28.17
bone 28.16
- Hypochondriac region 400.2
- Hypochondrium 400.2
- Hypoepiglottic ligament 142.8
- Hypogastric
nerve, right/left 350.10
plexus
inferior 350.11
superior 350.9
region 400.7
vein 250.1
- Hypoglossal
canal 8.16
- Hypoglossal
nerve 334.1
trigone 386.31
nucleus 282.5
- Hyponychium 394.5
- Hypophysial
fossa 10.8
portal veins 240.8a
- Hypophysis 182.13
- Hypothalamic
branch of posterior communicating artery 208.22
fasciculi 304.10
nucleus
anterior 302.20
dorsal 304.3
dorsomedial 304.2
posterior 304.8
ventromedial 304.1
- region
anterior (ventral) 302.16
dorsal (posterior) 302.14, 304.6
intermediate 302.21
lateral 302.24
sulcus 298.2
tract 304.10
- Hypothalamohypophysial tract 304.20
- Hypothalamus 296.30
sections 302.13
- Hypothenar eminence 400.41
- I**
- Ileal branch(-es)
ileocolic artery 220.9a
superior mesenteric artery 220.4
vein 248.21a
- Ileocecal
fold 180.5
recess
inferior 180.4
superior 180.2
valve 124.19
opening 124.20
- Ileocolic
artery 220.5
lymph nodes 264.4
vein 248.25
- Ileum 124.16
- Iliac
artery
common 222.6
deep circumflex 224.27
external 224.20
internal 222.7
superficial circumflex 224.31
branch of iliolumbar artery 222.11
crest 42.15
external lip 42.16
internal lip 42.19
tubercle 42.17
- Iliac
fascia 98.19
fossa 42.24
lymph nodes
common 264.15
external 264.21
interiliac external 264.28
intermediate
common 264.17
external 264.23
internal 266.1
lateral
common 264.18
external 264.24
medial
common 264.16
external 264.22
obturator external 264.29
promontory common 264.20
subaortic common 264.19
plexus 350.7
region 400.6
spine
anterior
inferior 42.21
superior 42.20
posterior
inferior 42.23
superior 42.22
tuberosity 42.31
vein
common 248.37
deep circumflex 250.25
external 250.23
internal 250.1
superficial circumflex 252.3
- Iliofemoral ligament 66.23
- Iliohypogastric nerve 342.15
- Ilioinguinal nerve 342.18
- Iliolumbar
artery 222.8
ligament 66.5
vein 348.39
- Iliopectineal
arch 98.21
bursa 104.14
eminence 44.14
- Iliopubic eminence 44.14
- Iliotibial tract 98.14
- Ilium 42.10
body 42.11
wing (ala) 42.13
- Impressio(-nes)
cardiaca 128.25, 148.14
colica 130.11
digitatae (gyrorum) 30.6
duodenalis 130.10
gastrica 130.9
ligamenti costoclavicularis 34.28
oesophagea 130.8
renalis 130.12
suprarenalis 130.13
trigeminalis 12.8
- Incisal margin 110.32

- Incisive**
 bone 24.3
 canal 24.4, 30.25
 duct 136.25
 foramen 24.14, 30.26
 fossa 30.24
 papilla 108.30
 scapulae (scapularis) 34.16
 suture 24.5
Incisor teeth 112.20
Incisura (-ae)
 acetabuli (acetabularis) 42.8
 angularis 120.20
 anterior (auris) 386.24
 apicis cordis 184.17
 cardiaca 120.24, 148.18
 cartilagineus meatus acustici 386.6
 clavicularis 6.25
 costales 6.33
 ethmoidalis 18.27
 fibularis 48.13
 frontale 18.9
 interarytenoidea 142.26
 intertragica 386.25
 ischiadica (ischialis)
 major 44.6
 minor 44.7
 jugularis 6.26, 8.19, 14.19
 lacrimalis 22.27
 ligamenti teretis 130.16
 mandibulae 28.11
 mastoidea 12.18
 nasalis 22.11
 pancreatis 128.4
 parietalis 16.12
 preoccipitalis 308.14
 pterygoidea 12.4
 radialis 38.23
 sphenopalatina 24.19
 supraorbitalis 18.8
 tentorii 268.26
 terminalis auricularis 388.2
 thyroidea
 inferius 138.18
 superior 138.17
 trochlearis 38.22
 tympanica 16.8, 386.3a
 ulnaris 38.16
 vertebralis
 inferior 2.9
 superior 2.8
Inclinatio pelvis 44.33
Incudal
 fold 384.11
 fossa 380.14
Incudomalleolar joint 382.19
Incudostapedial articulation 382.20
Incus 382.1, 382.7
 body 382.8
Index finger 400.45
Indicis artery, radialis 214.10
Indusium griseum 312.15
Inferior 396.20
- Inferior**
 aberrant ductules 160.9
 alveolar
 artery 198.12
 nerve 326.9
 anastomotic vein 240.20
 angle (scapula) 34.17
 anterior segmental artery 220.22
 aperture 88.23
 articular
 facet 4.4
 process 2.15
 surface, tibia 48.14
 basal
 segment 230.26
 vein 232.13
 branch(-es)
 superior gluteal artery 222.23
 transverse cervical nerve 336.3
 bulb of jugular vein 234.24
 carotid triangle 398.26
 cerebellar peduncle 24, 290, 280.2, 282.4
 cerebral veins 240.16
 cervical
 cardiac branches of vagus nerve 332.14
 cardiac nerve 352.10
 choroid vein 240.29
 clunial (gluteal) branch 344.15
 colliculus 292.14
 brachium 292.16, 294.20, 300.26
 commissure 294.21
 nucleus 294.19
 costal fovea 2.26
 deep cervical lymph nodes 258.7
 dental
 arch 112.19
 branches, inferior alveolar nerve 326.12
 plexus 326.11
 duodenal
 flexure 124.8
 fold 178.30
 recess 178.31
 end of testis 158.18
 epigastric
 artery 224.21
 lymph nodes 262.12
 vein 250.24
 extensor retinaculum 100.13
 fascia
 of pelvic diaphragm 174.29
 of urogenital diaphragm 176.6
 fornix of conjunctiva 368.4
 fovea 286.29
 frontal
 gyrus 306.30
 sulcus 306.29
- Inferior**
 ganglion 330.19, 332.3
 gingival branches of inferior alveolar nerve 326.13
 gluteal
 artery 222.24
 line 42.28
 lymph nodes 266.3
 nerve 344.13
 veins 250.3
 horn 314.6
 falciform margin 100.6
 thyroid cartilage 138.23
 hypogastric plexus 350.11
 hypophysial artery 200.23
 ileocecal recess 180.4
 labial
 artery 196.12
 veins 236.13
 laryngeal
 artery 210.15
 nerve 332.18
 vein 232.31
 ligament of epididymis 162.5
 lingular
 bronchus 146.20
 segment of upper lobe of left lung 150.19
 longitudinal
 fasciculus 316.17
 muscle of tongue 114.24
 lymph nodes 266.17
 macular arteriole/venule 360.13
 margin
 of cerebral hemisphere 306.11
 of liver 130.15
 of lung 148.19
 mediastinum 152.26
 medullary velum 288.4
 mesenteric
 artery 220.12
 ganglion 348.16
 lymph nodes 264.11
 plexus 350.1
 vein 248.33
 nasal
 arteriole/venule of retina 360.11
 concha 20.17, 136.13
 meatus 32.6, 136.23
 nuchal line 8.27
 oblique muscle 364.13
 olivary nucleus 280.28
 ophthalmic vein 244.8
 orbital fissure 32.24
 palpebral
 arch 202.19
 branches, infraorbital nerve 324.9
 pancreatic lymph nodes 262.24
 pancreaticoduodenal
 artery 220.2
 lymph nodes 262.28

- Inferior
 parathyroid gland 182.12
 parietal lobule 308.6
 part
 of duodenum 124.5
 of left superior pulmonary vein 232.3
 peroneal (fibular) retinaculum 100.15
 petrosal sinus 238.18
 groove for 8.7, 14.18
 pharyngeal constrictor muscle 118.32
 phrenic artery 216.20
 lymph nodes 262.11
 veins 246.22
 ramus
 of oculomotor nerve 320.7
 of pubis 44.20
 rectal artery 224.9
 nerves 346.18
 veins 250.20
 rectus muscle 364.5
 right pulmonary vein 230.17
 sagittal sinus 238.16
 salivary nucleus 282.21
 segment of kidney 154.20
 segmental artery 220.23
 semilunar lobule 288.35
 subtendinous bursa of biceps femoris 106.2
 suprarenal artery 220.18
 surface
 of petrous temporal 14.23
 of tongue 112.34
 synovial membrane 60.7
 tarsal muscle 366.23
 plate 366.17
 temporal arteriole/venule of retina 360.9
 gyrus 308.24
 line 16.29
 sulcus 308.23
 thalamic peduncle 302.8
 thalamostriate veins 240.26
 thoracic aperture 6.37
 thyroid artery 210.14
 notch 138.18
 tubercle 138.20
 veins 232.30
 tracheobronchial lymph nodes 260.15
 transverse scapular ligament 60.15
 tympanic artery 194.20
 ulnar collateral artery 212.33
 vein(-s)
 of cerebellum 242.22
 of vermis 242.20
- Inferior
 vena cava 246.21
 foramen 84.32
 opening 186.24
 valve 186.26
 ventricular vein 240.28
 vesical artery 224.1
 vestibular area 378.13
 nucleus 282.13
 wall 32.18
 Inferolateral surface 162.15
 Infra-auricular lymph nodes 256.8
 Infraclavicular fossa 398.35
 lymph nodes 258.23
 part
 brachial plexus 336.24
 Infraglenoid tubercle 34.21
 Infraglottic cavity 144.8
 Infrahyoid branch of superior thyroid artery 194.11
 bursa 102.5
 lymph nodes 256.19a
 muscles 82.13
 Infralobar part of superior right pulmonary vein 230.12
 Inframammary region 398.39
 Infraorbital artery 200.1
 canal 22.5
 foramen 22.9
 groove 22.6
 margin
 maxilla 22.7
 orbit 32.16
 nerve 324.1
 region 398.19
 Infrapatellar branch of saphenous nerve 344.5
 fat pad 68.19
 synovial fold 68.10
 Infrascapular region 400.12
 Infraspinosus fossa 34.9
 Infrasternal angle 6.41
 Infratemporal crest 10.32
 fossa 30.13
 surface 22.14
 Infratrochlear nerve 322.11
 Infundibular nucleus 304.5
 Infundibulum 182.20, 188.8, 296.38
 ethmoidale 20.8, 138.10
 recess 298.5
 tendon 186.6a
 tubae uterinae 166.31
- Inguinal
 branches of external pudendal arteries 224.35
 canal 86.30
 fossa
 lateral 180.19
 medial 180.16
- Inguinal
 ligament 86.10
 lymph nodes
 deep 266.18
 superficial 266.14
 region 400.6
 ring
 deep 86.29
 superficial 86.14
 trigone 180.17
 Inion 8.23, 32.25a
 Inner 396.30a
 ear, vessels 374.10
 margin of foot 402.22
 Insula
 central sulcus 308.30
 circular sulcus 308.31
 long gyrus 308.28
 short gyri 308.27
 Insular arteries 204.24
 lobe 308.25
 part of middle cerebral artery 204.23
 veins 240.25
 Integumentum commune 390.1
 Intervalveolar septa 24.11, 26.29
 Interarytenoid fold 144.7a
 notch 142.26
 Interatrial septum 184.28
 Intercapitular veins 244.29, 252.26a
 Intercarpal joints 62.16
 ligaments
 dorsal 62.24
 interosseous 64.2
 palmar 62.25
 Intercartilaginous part of rima glottidis 144.7
 Intercavernous sinus 238.22
 Interchondral joints 58.27
 Interclavicular ligament 60.27
 Intercondylar area
 anterior 46.32
 posterior 46.33
 eminence 46.34
 fossa 46.18
 line 46.19
 tubercle
 lateral 46.36
 medial 46.35
- Intercostal artery(-ies)
 highest 212.5
 posterior 212.6, 216.8
 lymph nodes 260.4
 membrane
 external 58.25, 84.16
 internal 58.26, 84.18
 muscles
 external 84.15
 innermost 84.19

- Intercoastal muscles
 internal 84.17
 nerves 340.20
 vein(-s)
 anterior 234.18
 left superior 234.20
 posterior 246.13
 right superior 246.2
 supreme 234.19
 Intercoastal space 6.40
 Intercostobrachial nerves 340.23
 Interocrural fibers 86.17
 Intercuneiform joints 70.18a
 ligament
 dorsal 70.25
 interosseous 70.22
 plantar 72.7
 Interdental papilla 108.24
 Interfascicular fasciculus 278.11
 Interfoveolar ligament 86.31
 Interganglionic branches 350.24
 Interiliac external iliac lymph nodes 264.28
 Interlobar arteries 156.2
 sulci 306.21
 surface of lung 148.16
 veins 156.10
 Interlobular arteries 132.3, 156.4
 ductules 132.6
 veins 132.4, 156.12
 Intermaxillary suture 54.30
 Intermediate 396.11
 atrial branch
 left coronary artery 192.24
 right coronary artery 192.11
 branch of medial segmental artery 218.12a
 cervical septum 272.10
 common iliac lymph nodes 264.17
 cuneiform 52.10
 dorsal cutaneous nerve 344.24
 external iliac lymph nodes 264.23
 ganglia 350.26
 hepatic veins 246.26
 hypothalamic region 302.21
 lacunar node 264.26
 laryngeal cavity 142.29a
 lumbar lymph nodes 262.6
 part of bulb of vestibule 170.35
 sacral crest 4.31
 supraclavicular nerves 336.6
 tendon 405.27a
 ventral nucleus 300.5
 Intermembranous part of rima glottidis 144.6
 Intermesenteric plexus 348.15
 Intermetacarpal joints 64.11
 Intermetatarsal joints 72.13
 Intermuscular bursae of gluteal muscles 104.12
 Internal 396.30a
 abdominal oblique muscle 86.18
 acoustic (auditory) meatus 14.13, 378.5
 fundus 378.7
 opening 14.12
 anal sphincter 126.20
 arcuate fibers 280.19
 axis of eyeball 354.21
 branch of accessory nerve 332.35
 capsule 318.7
 anterior limb 318.8
 genu 318.11
 posterior limb 318.13
 carotid
 artery 200.10, 208.13
 cavernous part 200.16
 cerebral part 200.24
 cervical part 200.11
 petrous part 200.13
 nerve 350.29
 plexus 350.30
 cerebral veins 242.2
 ear 370.2
 female genitalia 166.5
 filum terminale 272.11
 granular layer, cerebral cortex 316.6
 iliac
 artery 222.7
 lymph nodes 266.1
 vein 250.1
 intercostal
 membrane 58.26, 84.18
 muscles 84.17
 jugular vein 234.21
 laryngeal nerve 332.12
 lip of iliac crest 42.19
 male genitalia 158.15
 medullary laminae 296.23, 298.23
 nasal branches
 of anterior ethmoidal nerve 322.7
 of infraorbital nerve 324.11
 nuclear layer, retina 358.24
 occipital
 crest 8.30
 protuberance 8.29
 puddental
 artery 224.8
 vein 250.16
 pyramidal layer, cerebral cortex 316.7
 sheath optic nerve 354.13
 spermatic fascia 160.30
 spiral sulcus 372.28
 surface
 frontal bone 18.14
 parietal bone 16.25
 table (lamina) 28.25
 Internal thoracic
 artery 210.1
 veins 234.14
 tunic of eyeball 358.18
 Internasal suture 54.26
 Internus 396.30a
 Interomediolateral column 276.11
 Interosseous artery
 anterior 214.22
 common 214.19
 posterior 214.20
 recurrent 214.21
 border, ulna 38.28
 cuneometatarsal ligaments 72.12
 intercarpal ligaments 64.2
 ligaments of tarsus 70.19
 margin
 fibula 48.26
 radius 38.8
 tibia 48.9
 membrane
 forearm 62.10
 tibiofibular joint 68.24
 metacarpal ligaments 64.14
 metatarsal ligaments 72.14
 nerve of forearm, anterior 338.11
 sacroiliac ligaments 66.13
 spaces
 metacarpal 64.15
 metatarsal 72.17
 veins
 anterior 244.19a
 posterior 244.19b
 Interosseous nerve of the leg 346.3
 Interparietal bone 8.13
 Interpectoral lymph nodes 258.22
 Interpeduncular cistern 270.8
 fossa 290.32
 nucleus 292.31
 perforated substance 290.33
 Interphalangeal joints of foot 72.22
 joints of hand 64.20
 collateral ligaments 64.21
 Interpubic disc 66.18
 Interradicular septa 24.12, 26.30
 Intersectiones tendineae 86.3, 405.27
 Intersegmental part
 inferior right pulmonary vein 230.20, 230.25
 left inferior pulmonary vein 232.7
 left superior pulmonary vein 230.31, 230.34
 superior basal vein 232.12
 superior right pulmonary vein 230.7, 230.10

- Intersigmoid recess 180.1
 Interspinal
 ligaments 56.16
 plane 398.6
 Interstitial nucleus of Cajal 294.1
 Intertarsal joints 70.10
 Intertendinous connections 90.16
 Interthalamic adhesion 296.21
 Intertragic incisure 386.25
 Intertrochanteric
 crest 46.11
 line 46.10
 Intertubercular
 groove 36.8
 plane 398.5
 tendon sheath 88.14
 Interureteric ridge 158.11
 Intervaginal spaces 354.14
 Intervenous tubercle 186.25
 Interventricular
 foramen 298.3, 314.3
 groove
 anterior 184.18
 posterior 184.19
 septum 184.22
 vein
 anterior 232.16
 posterior 232.20
 Intervertebral
 disc 56.10
 foramen 2.7, 4.26
 symphysis 56.9
 vein 246.15
 Intestinal
 glands 122.31, 126.11
 surface of uterus 168.11
 trunks 254.11
 villi 122.30
 Intestinum
 crassum 124.17
 tenuis 122.20
 Intra-articular
 ligament of head of rib 58.13
 sternocostal ligament 58.21
 Intracanalicular part of optic
 nerve 354.6
 Intracapsular ligaments 404.47
 Intracranial part
 of optic nerve 354.5
 of vertebral artery 206.8
 Intraglandular lymph nodes
 256.9
 Intrajugular process 14.20
 of occipital bone 8.21
 Intralaminar nuclei of thalamus
 298.24
 Intralobar part of superior right
 pulmonary vein 230.13
 Intraoccipital
 synchondrosis 56.4a
 Intraoccipital synchondrosis
 anterior 56.6
 posterior 56.5
 Intraocular part of optic nerve
 354.8
 Intraparietal sulcus 308.5
 Intraparotid plexus 328.12
 Intrasegmental part
 inferior right pulmonary vein
 230.19, 230.24
 left inferior pulmonary vein
 232.6
 left superior pulmonary vein
 230.30, 230.33
 superior basal vein 232.11
 superior right pulmonary
 vein 230.6, 230.9
 Intratendinous bursa, of
 olecranon 102.16
 Intrathalamic fibers 302.11
 Intratransverse ligaments 56.15
 Intumescencia
 cervicalis 272.14
 lumbosacralis 272.15
 tympanica 330.21
 Iridial folds 358.8
 Iridocorneal angle 360.16
 Iris 358.1
 Irregular bone 402.44
 Ischial
 bursa
 of gluteus maximus muscle
 104.13
 of obturator internus muscle
 104.10
 spine 44.5
 tuberosity 44.4
 Ischioanal fossa 176.13
 adipose body 176.14
 Ischiofemoral ligament 66.24
 Ischium 44.1
 body 44.2
 ramus 44.3
 Isthmus
 aortae 194.2
 cartilaginosis auricularis
 388.1
 faucium 116.3
 glandulae thyroidea 182.4
 gyri cinguli (cingulatus) 310.4
 prostateae 162.17
 tubae auditoriae 384.16
 tubae uterinae 166.35
 uteri 168.14
J
 Jacobson's
 cartilage 134.32
 organ 136.7
 Jejunal
 branches of superior mesen-
 teric artery 220.3
 veins 248.21
 Jejunum 124.15
 Joint(-s)
 bicondylar 404.29
 capsule 66.21, 404.38
 cartilaginous 404.19
 composite 404.24
 condylar 404.27
 ellipsoidal 404.27
 fibrous 404.12
 of foot 70.11
 of free lower limb 66.19
 of free upper limb 60.28
 of hand 64.1
 hinge 404.28
 ovoidal 404.32
 of pelvic girdle 66.1
 plane 404.25
 saddle 404.31
 seller 404.31
 of shoulder girdle 60.12
 simple 404.23
 of skull 56.8
 spheroidal 404.26
 surface 494.2
 synovial 404.22
 of thorax 56.8, 58.9
 trochoidal 404.30
 of vertebral column 56.8
 Juga alveolaria 24.13, 26.31
 Jugular
 foramen 30.18
 fossa 14.24
 ganglion 330.18, 332.2
 nerve 350.28
 notch 6.26, 8.19, 14.19
 process 8.20
 trunk, right/left 254.14
 tubercle 8.18
 vein
 anterior 238.4
 external 238.1
 inferior bulb 234.24
 internal 234.21
 superior bulb 234.22
 venous arch 238.5
 wall 378.20
 Jugulo-omohyoid node 258.8
 Jugulodigastric node 258.6
 Jugum sphenoidale 10.3
 Junctio neurocentralis 2.6a
 Juxtarticular tendineum 90.16
 Juxtaintestinal lymph nodes
 264.2
K
 Keith-Flack sinus node 186.8
 Kerkring's folds 122.29
 Kidney 154.3
 lower pole 154.11
 upper pole 154.10
 Knee 402.8
 anterior side 402.9
 cap 48.31
 joint 68.1
 posterior side 402.10

L

Labial

- artery
 - inferior 196.12
 - superior 196.13
- branches of inferior alveolar nerve 326.16
- commissure
 - anterior 170.27
 - posterior 170.28
- glands 108.32
- nerves
 - anterior 342.20
 - posterior 346.20
- part of m. orbicularis oris 78.28
- surface of tooth 110.25b
- vein(-s)
 - anterior 252.6
 - inferior 236.13
 - posterior 250.21
 - superior 236.12

Labium(-a)

- anterius (uterine ostium) 168.19
- externum (iliac crest) 42.16
- inferius 108.9
- internum (iliac crest) 42.19
- laterale (linea aspera) 46.14
- limbi
 - tympanicum 372.25
 - vestibulare 372.24
- majus pudendi 170.26
- mediale (linea aspera) 46.15
- minus pudendi 170.30
- oris 108.5
- posterius (uterine ostium) 168.20
- superius 108.6

Labrum

- acrotabulare 66.26
- articulare 404.37
- glenoidale 60.30

Labyrinthine

- artery 206.19, 374.11
- veins 238.19, 374.15
- wall 378.22

Labyrinthus

- cochlearis 372.9
- ethmoidalis 20.6
- membranaceus 370.3
- osseus 374.20
- vestibularis 370.6

Lacerate foramen 30.21

Lacertus

- fibrosus 88.16
- musculi recti lateralis 364.8

Lacrimal

- apparatus 368.9
- artery 202.3
- bone 20.21
- canaliculus 368.19
- ampulla 368.20
- caruncle 366.26

Lacrimal

- crest
 - anterior 22.26
 - posterior 20.22
 - fold 368.24
 - gland 368.10
 - accessory 368.14
 - fossa for 18.26
 - hamulus 20.24
 - lake 368.16
 - margin of maxilla 22.21
 - nerve 320.21
 - notch 22.27
 - nucleus 286.6
 - part of m. orbicularis oculi 78.20
 - process 20.18
 - punctum 368.18
 - sac 368.21
 - fossa 20.25, 32.22b
 - sulcus 20.23, 22.19, 32.22a
 - vein 242.28
- Lacrimoconchal suture 54.29
- Lacrimomaxillary suture 54.28
- Lactiferous
- ducts 394.25
 - sinus 394.26
- Lacuna(-ae)
- laterales 238.15
 - musculorum 98.20
 - urethrales 164.34, 172.19
 - vasorum 98.22
- Lacunar
- ligament 86.11
 - node
 - intermediate 264.26
 - lateral 264.27
 - medial 264.25
- Lacus lacrimalis 368.16
- Lambda 32.26
- Lambdoid margin of occipital bone 8.12
- Lambdoidal suture 54.4
- Lamellated corpuscles 390.23
- Lamina(-ae) 2.6
- affixa 314.8
 - alba 290.12
 - anterior (rectus sheath) 86.5
 - arcus vertebrae (vertebralis) 2.6
 - basalis 356.28, 372.20
 - cartilagineis
 - cricoideae 140.3
 - lateralis 384.21
 - medialis 384.20
 - choroidocapillaris 356.17
 - cribrosa 20.2, 354.34
 - dextra (larynx) 138.16
 - episcleralis 354.31
 - externa 28.22
 - fusca 356.14
 - sclerae 354.33
 - ganglionaris (cerebral cortex) 316.7

Lamina(-ae)

- granularis
 - externa (cerebral cortex) 316.4
 - interna (cerebral cortex) 316.6
- horizontalis 24.27
- interna 28.25
- lateralis (processus pterygoidei) 12.2
- limitans anterior (Bowman) 356.8
- limitans posterior (Descemet) 356.10
- medialis (processus pterygoidei) 12.3
- medullaris(-es)
 - interna/externa 296.23, 298.23
 - lateralis 316.28
 - medialis 316.30
- membranacea 384.22
- modioli 374.24
- molecularis (cerebral cortex) 316.3
- multiformis (cerebral cortex) 316.8
- muscularis mucosae 405.43 (colon) 126.10 (esophagus) 120.13 (small intestine) 122.28 (stomach) 122.13
- orbitalis 20.11
- parietalis 184.5
 - (tunica vaginalis testis) 162.2
- perpendicularis 20.5, 24.16
- plexiformis (cerebral cortex) 316.3
- posterior (rectus sheath) 86.6
- pretrachealis (fascia cervicalis) 82.23
- prevertebralis (fascia cervicalis) 82.24
- profunda 364.16
 - (fascia temporalis) 80.23
- propria mucosae 405.42
- pyramidalis
 - externa (cerebral cortex) 316.5
 - interna (cerebral cortex) 316.7
- quadrigemina 292.13, 294.18
- septi pellucidi 312.29
- sinistra (larynx) 138.16
- spiralis
 - ossea 378.1
 - secundaria 378.4
- superficialis 364.15
 - (fascia cervicalis) 82.22
 - (fascia temporalis) 80.22
- suprachoroidea 356.14
- tectalis 292.13, 294.18
- terminalis 312.19
- tragi 386.7
- vasculosa 356.16

Lamina(-ae)
 visceralis 184.6
 (tunica vaginalis testis) 162.3
 Lanugo 392.2
 Large intestine 124.17
 Laryngeal
 artery
 inferior 210.15
 superior 194.13
 cartilages 138.13
 cavity 142.23
 intermediate 142.29a
 glands 144.15
 inlet (aditus) 142.24
 joints 138.13
 musculature 142.10
 nerve
 external 332.11
 inferior 332.18
 internal 332.12
 recurrent 332.15
 superior 332.10
 prominence 138.15
 vein
 inferior 232.1
 superior 236.4
 Laryngopharyngeal branches 352.3
 Laryngopharynx 118.12
 Larynx 138.12
 fibroelastic membrane 144.9
 lymph nodes 144.15
 sacculae 144.2
 ventricle 144.1
 vestibule 142.27
 Lateral 396.12
 ampullar nerve 330.11
 angle
 of eye 366.11
 of scapula 34.18
 antebrachial cutaneous nerve 338.3
 anterior
 malleolar artery 226.25
 nasal branches of anterior ethmoidal artery 202.16b
 aortic lymph nodes 262.3
 aperture of fourth ventricle 288.10
 arcuate ligament 84.34
 atlanto-axial joint 58.1
 atlanto-occipital membrane 56.30
 atrial vein of lateral ventricle 242.8
 basal
 branch
 left pulmonary artery 190.41
 right pulmonary artery 190.27
 segment
 of lower lobe of left lung 150.26
 of lower lobe of right lung 150.14

Lateral
 basal
 segmental bronchus 146.14, 146.26
 bicipital groove 400.27
 border, radius 38.11
 brachial cutaneous nerve 340.3
 branch(-es)
 cutaneous, iliohypogastric nerve 342.16
 left coronary artery 192.19
 lumbar nerves 342.4
 middle cerebral artery 204.22
 portal vein of liver 248.11
 posterior ramus, spinal nerve 334.17
 right pulmonary artery 190.21
 sacral/coccygeal nerves 342.10
 supraorbital nerve 320.25
 calcaneal branches 346.7
 tibial nerve 346.7
 cartilaginous lamina 384.21
 caval lymph nodes 262.8
 central nucleus 298.28
 cervical lymph nodes 258.1
 circumflex
 femoral artery 226.8
 femoral veins 252.11
 column 276.9
 common iliac lymph nodes 264.18
 condyle
 femur 46.24
 tibia 46.30
 cord 336.25
 corticospinal (pyramidal) tract 276.28
 costal branch of internal thoracic artery 210.9
 costotransverse ligament 58.17
 cricoarytenoid muscle 142.17
 crus
 alar cartilage 134.27
 inguinal ring 86.16
 cuneiform 52.11
 cutaneous branch
 intercostal nerve 340.21
 posterior intercostal arteries 216.12, 216.14
 direct veins 242.10
 dorsal cutaneous nerve 346.6
 epicondyle
 femur 46.25
 humerus 36.30
 external iliac lymph nodes 264.24
 fasciculi proprii 276.27
 femoral cutaneous nerve 342.24
 flattened surface of testis 158.19
 fossa of cerebrum 306.9
 frontobasal artery 204.25

Lateral
 funiculus 274.3, 276.26, 278.22
 geniculate
 body 296.28
 nucleus
 dorsal part 300.12
 ventral part 300.15
 glandular branch of superior thyroid artery 194.16a
 globus pallidus 316.29
 glossoepiglottic fold 118.11
 habenular nucleus 296.11
 head
 of flexor hallucis brevis 98.2b
 of gastrocnemius 96.15
 of triceps 88.21
 horn 276.10
 hypothalamic region 302.24
 inferior genicular artery 226.18
 inguinal fossa 180.19
 intermediate gray matter 276.13
 intermuscular septum
 of arm 92.19
 of thigh 98.15
 lacunae 238.15
 lacunar node 264.27
 lemniscus 286.17, 294.13, 300.22
 nucleus 286.18
 ligament
 of malleus 382.25
 temporomandibular joint 60.4
 lip of linea aspera 46.14
 longitudinal stria, corpus callosum 312.17
 lymph nodes 258.4, 258.9
 malleolar
 branches of peroneal artery 228.15
 fossa 48.30
 network 226.27
 surface, talus 50.10
 malleolus 48.28
 mammary branches
 axillary artery 212.19
 intercostal nerve 340.22
 posterior intercostal arteries 216.15
 margin
 foot 402.21
 forearm 400.32
 humerus 36.19
 kidney 154.4
 nail 394.1
 orbit 32.16a
 scapula 34.14
 tongue 112.36
 marginal vein 252.26b
 mass
 of atlas 4.2
 of sacrum 4.21
 medullary
 branch of posterior inferior cerebellar artery 206.15
 lamina 316.28

- Lateral
 membranous ampulla 380.21
 meniscus 68.2
 muscular branches of thoracic nerves 340.18
 nasal
 branches
 anterior ethmoidal nerve 322.8
 nasopalatine nerve 322.20d
 cartilage 134.24
 nuclei of mamillary body 304.7
 occipital artery 208.2
 occipitotemporal gyrus 310.22
 olfactory
 gyri 310.31
 striae 310.30
 osseous ampulla 376.13
 palpebral
 arteries 202.5
 commissure 366.9
 ligament 366.20
 raphe 366.19
 part
 of fornix of vagina 170.5
 of superior right pulmonary vein 230.15
 pectoral nerve 336.29
 pericardial lymph nodes 260.8
 plantar
 artery 228.21
 nerve 346.12
 posterior
 nasal branches of sphenopalatine artery 200.9
 superior nasal branches of pterygopalatine ganglion 322.18
 preoptic nucleus 302.17
 process
 calcaneus 50.25
 malleus 382.16
 mammary gland 394.22
 nasal septum 134.30a
 talus 50.11
 pterygoid
 muscle 80.16
 plate 12.2
 recess 286.21
 rectus muscle 364.7
 retinaculum of patella 68.18
 root 296.34, 338.10
 sacral
 arteries 222.12
 branches 216.26a
 crest 4.32
 veins 250.5
 sacrococcygeal ligament 56.25
 segment
 of liver 130.24
 of middle lobe of right lung 150.7
 segmental bronchus 146.7
- Lateral
 semicircular
 canal 376.9
 duct 370.14
 subtendinous bursa of gastrocnemius muscle 106.5
 sulcus 306.17
 superior genicular artery 226.14
 supraclavicular nerves 336.7
 supracondylar
 line 46.20b
 ridge 36.20
 sural cutaneous nerve 344.19
 surface
 of fibula 48.21
 of ovary 166.9
 of tibia 48.6
 of zygomatic bone 26.2
 talocalcaneal ligament 70.14
 tarsal artery 228.2
 thoracic
 artery 212.18
 vein 244.14
 thyrohyoid ligament 138.27
 tract 74.10a
 tubercle, talus 50.20
 umbilical fold 180.18
 ventricle 314.1
 choroid plexus 272.6, 314.11
 vesicular lymph nodes 266.9
 vestibular nucleus 282.15, 286.11
 wall of orbit 32.19
 Lateralis 396.12
 Lateropharyngeal space 118.37
 Left 396.8
 atrial veins 232.24
 atrium of heart 184.26, 188.20
 auricle 188.21
 brachiocephalic veins 232.28
 branch
 to conus arteriosus (left coronary artery) 192.18
 hepatic artery proper 218.9
 portal vein of liver 248.5
 bronchomediastinal trunk 254.12
 colic
 artery 220.13
 flexure 124.29
 lymph nodes 264.10
 vein 248.34
 coronary
 artery 192.16
 vein 232.16a
 duct of caudate lobe 132.16
 fibrous
 ring 186.6
 trigone 186.5
 gastric
 artery 216.29
 vein 248.17
 gastro-omental
 artery 218.31
 vein 248.32
- Left
 hepatic
 artery 218.9
 duct 132.12
 veins 246.27
 horn of uterus 168.9
 inferior
 lobar bronchus 146.21
 pulmonary vein 232.4
 jugular trunk 254.14
 lamina, larynx 138.16
 lobe
 of liver 130.21
 of prostate 162.16
 lumbar
 lymph nodes 262.2
 trunk 254.10
 lung 148.7
 culmen 148.22a
 lingula 148.22
 lower lobe 150.21
 upper lobe 150.16
 main bronchus 144.30
 margin of uterus 168.10
 marginal branch 192.23
 ovarian vein 246.31
 posterior ventricular branch of left coronary artery 192.25
 pulmonary
 artery 190.29
 veins 230.27
 superior 230.27, 230.28
 semilunar cusp
 of aortic valve 190.3
 of pulmonary valve 188.13
 subclavian trunk 254.13
 superior
 intercostal vein 234.20
 lobar bronchus 146.16, 146.21
 suprarenal vein 246.29
 testicular vein 246.30
 triangular ligament 178.24
 umbilical vein 248.12
 ventricle of heart 184.21, 188.24
 Lemniscus
 lateralis 286.17, 294.13, 300.22
 medialis 280.21, 284.21, 294.14, 300.23
 spinalis 284.24, 294.15, 300.24
 trigeminalis 284.28, 294.16, 300.25
 trigone 292.18
 Lens 362.10
 capsule 362.16
 cortex 362.12
 epithelium 362.15
 fibers 362.14
 nucleus 362.13
 radii 362.23
 Lenticular
 fossa 362.7
 papillae 114.8
 process, incus 382.10

Lentiform nucleus 316.24

Lesser

- alar cartilages 134.28
- arterial circle of iris 358.16
- curvature of stomach 120.19
- duodenal papilla 124.13
- horn (cornu) 28.18
- occipital nerve 334.27
- omentum 178.10
- palatine
 - arteries 200.7
 - canals 24.22
 - foramina 24.30
 - nerves 322.24
- pelvis 44.25
- petrosal nerve 330.32
 - groove for 14.7
 - hiatus of canal 14.5
- ring (circle) of iris 358.7
- sac of peritoneum 176.30
- sciatic
 - foramen 66.10
 - notch 44.7
- supraclavicular fossa 398.29
- trochanter 46.8
- tubercle (humerus) 36.7
 - crest 36.10
- tympanic spine 16.6
- vestibular glands 172.2
- wing of sphenoid 10.19

Lien 268.1

Lienal

- lymph nodes 262.25
- plexus 348.19

Lienorenal ligament 178.19

Ligamentum(-a) 404.44

acromioclaviculare 60.17

alaria 58.3

anococcygeum 174.12

anulare

- radii 62.7
- stapediale 382.29

anularia, tracheae 144.22

apicis dentis 58.4

arcuatum

- laterale 84.34
- mediale 84.33
- medianum 84.35
- pubis 66.17

arteriosum 192.2

- node 260.10

atlanto-occipitale

- anterior 56.27
- laterale 56.30

auricularia 388.10

- anterior 388.11
- posterior 388.13
- superius 388.12

bifurcatum 70.28

calcaneocuboideum 70.30

- dorsale 70.31a
- plantare 72.3

calcaneofibulare 70.9

- calcaneonavicularia 70.29
- plantaria 72.4

Ligamentum(-a)

capitis

costae

intra-articulare 58.13

radiatum 58.12

femoris 66.28

fibulae

anterior 68.21

posterior 68.22

capsularia 404.46

carpi

dorsum 92.22

transversum 92.26

carpometacarpalia

dorsalia 64.8

palmaria 64.9

ceratrocricoidum 140.7a

collaterale

carpi

radiale 62.23

ulnare 62.22

fibulare 68.12

radiale 62.6

tibiale 68.13

ulnare 62.5

collateralia 64.17, 64.21, 72.19,

72.23

conoideum 60.21

coracoacromiale 60.13

coracoclaviculare 60.19

coracohumerale 60.31

coronarum 178.21

costoclaviculare 60.26

costotransversarium 58.15

laterale 58.17

superius 58.16

costoxiphoida 58.24

cricocarytenoideum

140.25

cricopharyngeum 140.26

cricothyroideum medianum

140.8

cricotracheale 140.9

cruciata genus (genualia) 68.7

anterior 68.8

posterior 68.9

cruciforme atlantis 58.5

cuboideonaviculare

dorsale 70.27

plantare 72.6

cuneocuboideum

dorsale 70.26

interosseum 70.21

plantare 72.8

cuneometatarsalia interossea

72.12

cuneonavicularia

dorsalia 70.31

plantaria 72.5

deltoideum articulationis

talocruralis 70.2

denticulatum 272.9

epididymidis

inferius 162.5

superius 162.4

Ligamentum(-a)

extracapsularia 404.45

falciforme (hepatis) 178.22

flava 56.13

fundiforme penis 86.26

gastrocolicum 178.17

gastrophrenicum 178.15

gastrosplenicum (gastrol-

ienale) 178.16

genitoinguinale 162.9

glenohumeralia 60.32

hepatis 178.20

hepatocolicum 178.13

hepatoduodenale 178.12

hepatogastricum 178.11

hepatorenale 178.25

hypoepiglotticum 142.8

iliofemorale 66.23

iliofemorale 66.5

incudis

posterior 382.27

superius 382.26

inguinale 86.10

intercarpalia

dorsalia 62.24

interossea 64.2

palmaria 62.25

interclaviculare 60.27

intercuneiformia

dorsalia 70.25

interossea 70.22

plantare 72.7

interfoveolare 86.31

interspinalia 56.16

intertransversaria 56.15

intracapsularis 404.47

ischiofemorale 66.24

lacunare 86.11

laterale (temporomandibular

joint) 60.4

latum uteri 180.24

lienorenale 178.19

longitudinale

anterior 56.19

posterior 56.20

lumbocostale 58.18

mallei

anterior 382.23

laterale 382.25

superius 382.24

mediale

articulationis talocruralis

70.2

(temporomandibular joint)

60.5

meniscomemorale

anterior 68.3

posterior 68.4

metacarpale transversum

profundum 64.19

superficiale 92.23

metacarpalia

dorsalia 64.12

interossea 64.14

palmaria 64.13

Ligamentum(-a)
 metatarsale transversum
 profundum 72.21
 superficiale 100.19
 metatarsalia
 dorsalia 72.15
 interossea 72.14
 plantaria 72.16
 nuchal 56.18
 ossiculorum auditoriorum
 382.22
 ovarii proprium 166.28
 palmaria 64.18, 64.22
 palpebrale
 laterale 366.20
 mediale 366.18
 patellae 68.16
 pectinatum 354.27
 pectineale 86.12
 phrenicocolicum 178
 phrenocolicum 178.19
 pishohamatum 64.4
 pisometacarpale 64.5
 plantare longum 72.2
 plantaria 72.20, 72.24
 popliteum
 arcuatum 68.15
 obliquum 68.14
 pterygospinale 60.10
 pubicum superius 66.16
 pubofemorale 66.25
 puboprostaticum 174.28
 pubovesicale 174.28
 pulmonale 152.23
 quadratum 62.8
 radiocarpale
 carpi radiatum 62.21
 dorsale 62.18
 palmare 62.19
 ulnocarpale palmare 62.20
 reflexum 86.13
 sacrococcygeum
 anterius (ventrale) 56.24
 laterale 56.25
 posterius (dorsale)
 profundum 56.23
 superficiale 56.22
 sacroiliaca
 anteriora (ventralia) 66.12
 interossea 66.13
 posteriora (dorsalia) 66.14
 sacrospinale 66.8
 sacrotuberale 66.6
 sphenomandibulare 60.8
 spirale 372.21
 splenorenale 178.19
 sternoclaviculare
 anterius 60.24
 posterius 60.25
 sternocostale intra-articulare
 58.12
 sternocostalia radiata 58.22
 sternopericardiaca 184.3
 stylohyoideum 60.11
 stylomandibulare 60.9

Ligamentum(-a)
 supraspinalis 56.17
 suspensorium(-a)
 mammaria 394.31
 ovarii 180.28
 penis/clitoridis 86.25
 talocalcaneum
 interosseum 70.20
 laterale 70.14
 mediale 70.15
 posterius 70.15a
 talofibulare
 anterius 70.7
 posterius 70.8
 talonaviculare 70.24
 tarsi
 dorsalia 70.23
 interossea 70.19
 plantaria 72.1
 tarsometatarsalia
 dorsalia 72.10
 plantaria 72.11
 teres
 hepatis 130.4
 uteri 168.32
 thyroepiglotticum 142.7
 thyrohyoideum
 laterale 138.27
 medianum 138.26
 tibiofibulare
 anterius 68.25
 posterius 68.26
 transversum
 acetabuli 66.27
 atlantis 58.7
 genus (genuale) 68.6
 perinei 176.7
 scapulae
 inferius 60.15
 superius 60.14
 trapezoideum 60.20
 triangulare
 dextrum 178.23
 sinistrum 178.24
 umbilicale
 mediale (laterale)
 222.30
 medianum 156.30
 venae cavae 130.32
 venosum 130.5, 248.10
 vestibulare 144.11
 vocale 144.13
 Limbus(-i) 354.26
 acetabuli 42.6
 corneae 356.3
 fossae ovalis 186.20
 laminae spiralis osseae
 372.23
 palpebrales
 anteriores 366.13
 posteriores 366.14
 Limen
 insulae 308.29
 nasi 136.9
 Limiting sulcus 286.26

Linea(-ae)
 alba 86.22
 adminiculum 86.24
 anocutanea 126.30
 anorectalis 126.28
 arcuata 42.14, 86.7
 aspera 46.13
 lateral lip 46.14
 medial lip 46.15
 axillaris
 anterior 396.52
 media 396.53
 posterior 396.54
 epiphysialis 404.1
 glutealis
 anterior 42.26
 inferior 42.28
 posterior 42.27
 intercondylaris 46.19
 intermedia 42.18
 intertrochanterica 46.10
 mammillaris 396.51
 mediana
 anterior 396.47
 posterior 398.1
 medioclavicularis 396.50
 musculi solei (tibia) 48.5
 mylohyoidea 26.22
 nuchalis
 inferior 8.27
 superior 8.26
 suprema 8.25
 obliqua 26.19, 138.21
 parasternalis 396.49
 paravertebralis 396.56
 pectinea 46.16
 postaxillaris 398.8
 preaxillaris 398.7
 scapularis 396.55
 semilunaris 86.33
 sternalis 396.48
 supracondylaris
 lateralis 46.20b
 medialis 46.20a
 temporalis
 inferior 16.29
 ossis frontalis 18.12
 superior 16.28
 terminalis 44.26
 transversae 4.25
 trapezoidea 34.34
 Lineal artery 218.25
 Lingua 112.28
 Lingual
 aponeurosis 114.17
 artery 196.1
 deep 196.5
 branch(-es)
 facial nerve 328.16
 glossopharyngeal nerve
 330.30
 hypoglossal nerve 334.2
 left pulmonary artery 190.34
 lingual nerve 326.6
 follicles 114.15

- Lingual
glands 108.36
anterior 108.37
gyrus 310.17
lymph nodes 256.14a
nerve 326.1
papillae 114.3
septum 114.16
surface (tooth) 110.26
tonsil 114.14
vein 234.28
deep 234.32
dorsal 234.29
- Lingula 288.19
mandibulae 28.7
pulmonis sinistri 148.22
sphenoidalis 10.12
- Lingular
branch of left superior pulmonary vein 232.1
bronchus
inferior 146.20
superior 146.19
- Linguofacial trunk 196.6
- Lips 108.5
commissure 108.10
lower 108.9
upper 108.6
- Liquor cerebrospinalis 270.3, 270.15
- Little
finger 400.48
toe 402.28
- Liver 128.22
hilum 130.6
lobes of 130.17
left 130.21
right 130.18
- Lobar bronchus(-i) 146.1
left
inferior 146.21
superior 146.16
right
inferior 146.9
middle 146.6
superior 146.2
- Lobe 406.5
- Lobule 406.6
- Lobulus(-i) 406.6
auricularis 386.9
biventer 288.37
centralis (cerebellum) 288.20
coni epididymidis 160.5
corticales 154.29
glandulae mammae 394.24
gracilis 288.36
hepatis 132.1
insularis 308.25
pancreaticus 128.16
paracentralis 310.8
parietalis
inferior 308.6
superior 308.4
quadrangularis 288.23, 288.32
- Lobulus(-i)
semilunaris superior 288.33
simplex 288.32
testis 158.27
thymi 182.26
thyroid gland 182.10
- Lobus(-i) 406.5
anterior cerebelli 288.18
caudatus (liver) 130.26
cerebrales 306.6
dexter
(liver) 130.18
(prostate) 162.16
flocculonodularis 290.1
frontalis 306.22
glandulae
mammae 394.23
thyroidea (dexter/sinister) 182.3
hepatis (liver) 130.17
inferior (lung) 148.25
pulmonis dextri 150.9
pulmonis sinistri 150.21
medius
(lung) 148.24
pulmonis dextri 150.6
(prostate) 162.18
nervosus 182.21
occipitalis 308.10
parietalis 308.1
posterior cerebelli 288.25
pyramidalis 182.5
quadratus (liver) 130.25
renales 154.25
sinister
(liver) 130.21
(prostate) 162.16
superior (lung) 148.23
pulmonis dextri 150.2
pulmonis sinistri 150.16
temporalis 308.15
thymus 182.24
- Locus caeruleus 286.28
- Long
bone 402.41
central artery 204.5
ciliary nerves 322.3
gyrus of insula 308.28
head
of biceps brachii 88.13
of biceps femoris 96.3
of triceps 88.20
nasopalatine nerve 322.20a
plantar ligament 72.2
posterior ciliary arteries 202.7
thoracic nerve 336.21
- Longitudinal 396.29
canals of molliolus 376.26
fissure of cerebrum 306.7
folds of duodenum 124.11
layer
colon 126.2
small intestine 122.24
stomach 122.6
- Longitudinal
ligament
anterior 56.19
posterior 56.20
pontine fibers 284.9
- Longitudinalis 396.29
- Lower 396.20
anterior segment of kidney 154.19
eyelid 366.4
leg 402.12
anterior surface 402.13
posterior surface 402.14
lingular branch of left pulmonary artery 190.36
lip 108.9
lobe of lung 148.25
left lung 150.21
right lung 150.9
margin of spleen 268.11
omental recess 176.33
pelvic aperture 44.28
pole of kidney 154.11
trunk 336.16
- Lowest lumbar arteries 216.26
- Lumbar
arteries 216.22
lowest 216.26
branch of iliolumbar artery 222.9
ganglion 352.21
lymph nodes
intermediate 262.6
left 262.2
right 262.7
nerves 342.1
part of diaphragm 84.24
plexus 342.14
region 400.4
segment of spinal cord 274.8
splanchnic nerves 352.22
triangle 86.27
trigone 400.14
trunk, right/left 254.10
vein(-s) 246.11, 246.23
ascending 246.10
vertebrae 2.28
- Lumbocostal ligament 58.18
- Lumbosacral
enlargement 272.15
joint 66.4
plexus 342.13
trunk 344.7
- Lunate 40.6
sulcus 308.13
surface of acetabulum 42.9
- Lungs 148.6
apex 148.9
base 148.8
hilum 148.20
root 148.21
- Lunula(-ae) 392.28
valvularum semilunarium 188.15, 190.7

Lymph

- nodes 254.23, 406.21
- anorectal 266.12
- anterior 258.5, 258.10
 - cervical 256.17
 - jugular 256.18
 - mediastinal 260.9
- apical 258.17
- appendicular 264.8
- axillary 258.16
- brachial 258.18, 258.24
- celiac 262.14
- central 258.21, 264.3
- colic 264.10
- common iliac 264.15
- cubital 258.25
- deep 256.19, 258.28
 - inguinal 266.18
 - parotid 256.6
 - popliteal 266.20
- deltpectoral 258.23
- external, iliac 264.21
- facial 256.10
- gastric 262.15
- gastro-omental 262.17
- hepatic 262.29
- ileocolic 264.4
- inferior 266.17
 - deep cervical 258.7
- epigastric 262.12
- gluteal 266.3
- mesenteric 264.11
- pancreatic 262.24
- pancreaticoduodenal 262.28
- phrenic 262.11
- tracheobronchial 260.15
- infra-auricular 256.8
- infraclavicular 258.23
- infrahyoid 256.19a
- intercostal 260.4
- interiliac external iliac 264.28
- intermediate
 - common iliac 264.17
 - external iliac 264.23
 - lumbar 262.6
- internal iliac 266.1
- interpectoral 258.22
- intraglandular 256.9
- juxtaintestinal 264.2
- of larynx 144.16
- lateral 258.4, 258.9
 - aortic 262.3
 - caval 262.8
 - cervical 258.1
 - common iliac 264.18
 - external iliac 264.24
 - pericardial 260.8
 - vesicular 266.9
- left lumbar 262.2
- lienal 262.25
- lingual 256.14a
- mastoid 256.4
- medial
 - common iliac 264.16
 - external iliac 264.22

Lymph

- nodes
 - mesenteric 264.1
 - mesocolic 264.8
 - obturator external iliac 264.29
 - occipital 256.3
 - pancreatic 262.22
 - pancreaticoduodenal 262.26
 - paracolic 264.9
 - paramammary 260.2
 - pararectal 266.12
 - parasternal 260.3
 - paratracheal 256.23, 260.16
 - parauterine 266.10
 - paravaginal 266.11
 - paravertebral 260.5
 - parietal 262.1
 - pectoral 258.20
 - perivesicular 266.6
 - postaortic 262.5
 - postcaval 262.10
 - posterior mediastinal 260.11
 - postvesicular 266.8
 - pre-aortic 262.4
 - preauricular 256.7
 - precaval 262.9
 - prececal 264.5
 - prelaryngeal 256.20
 - prepericardial 260.7
 - pretracheal 256.22
 - prevesicular 266.7
 - promontory common iliac 264.20
 - pulmonary juxtaesophageal 260.12
 - pyloric 262.18
 - regional 256.1
 - retroauricular 256.4
 - retrocecal 264.6
 - retropharyngeal 256.23a, 258.13
 - right lumbar 262.7
 - sacral 266.4
 - sigmoid 264.12
 - splenic 262.25
 - subaortic common iliac 264.19
 - submandibular 256.16
 - submental 256.15
 - subscapular 258.19
 - superficial 256.18, 258.2, 258.27
 - inguinal 266.14
 - parotid 256.5
 - popliteal 266.19
 - superior 264.3
 - deep 258.3
 - gluteal 266.2
 - pancreatic 262.23
 - pancreaticoduodenal 262.27
 - phrenic 260.6
 - rectal 264.13
 - tracheobronchial 260.14

Lymph

- nodes
 - superolateral 266.16
 - superomedial 266.15
 - supraclavicular 258.11
 - supratrochlear 258.26
 - thyroid 256.21
 - tracheobronchial 260.13
- Lymph (lymph) 406.19
- Lymphatic
 - capillary network 254.4
 - ducts 254.15
 - right 254.16
 - nodules (follicles) 122.19, 254.29, 406.22
 - aggregated 122.33
 - of vermiform appendix 124.24
 - solitary 122.32, 126.12
 - plexus 254.6, 406.23
 - axillary 258.15
 - system 254.1
 - trunks 254.9
 - valve 406.35
 - vessels 254.2, 254.5, 406.40
 - afferent 254.24
 - deep 254.8
 - efferent 254.25
 - superficial 254.7
- Lymphocapillary vessel 254.3

M

- Macula(-ae) 360.3, 372.3
 - cribrosae 376.2
 - inferior 376.5
 - media 376.4
 - superior 376.3
 - sacculi 372.5
 - utriculi 372.4
- Macular arteriole/venule
 - inferior 360.13
 - superior 360.12
- Magnocellular part of red nucleus 294.5
- Main bronchus (right and left) 144.30
- Major
 - calices of kidney 156.17
 - sublingual duct 110.3
- Malar node 256.13
- Male urethra 164.23
- Mallear
 - fold
 - anterior 380.24, 384.6
 - posterior 380.25, 384.5
 - prominence 380.26
- Malleolar
 - artery
 - lateral 226.25
 - medial 226.26
 - fossa, lateral 48.30
 - groove 48.11
 - network, lateral 226.27

- Malleolar region
 anterior 402.16
 posterior 402.16
 surface of talus
 lateral 50.10
 medial 50.6
- Malleolus
 articular surface 48.12, 48.28
 lateralis 48.28
 medialis 48.10
- Malleus 382.1, 382.12
 head 382.14
 manubrium 382.13
 neck 382.15
- Mamillary
 body 296.36
 lateral nuclei 304.7
 medial nuclei 304.7
 process 2.30
- Mamillated areas 122.14
- Mamillotegmental fasciculus 304.15
- Mamillothalamic fasciculus 302.7, 304.16
- Mamma(-ae) 394.18
 accessoriae 394.30
 masculina 394.29
- Mammary gland 394.21
 body 394.20
 lobes 394.23
 lobules 394.24
 line 396.50, 396.51
 region 398.38
- Mandible (mandibula) 26.11
 angle 28.2
 base 26.13
 body 26.12
 head 28.13
 lingula 28.7
 neck 28.14
 ramus 28.1
- Mandibular canal 28.8
 foramen 28.6
 fossa 16.20
 nerve 324.13
 node 256.14
 notch 28.11
- Manubriosternal synchondrosis 6.29
- Manubrium
 mallei 382.13
 sterni 6.24
- Manus 400.37
- Marginal
 colic artery 220.11a
 crest, tooth 110.31
 mandibular branch of facial nerve 328.17
 part of m. orbicularis oris 78.27
 sinus 238.10a
- Marginal
 tentorial branch of internal carotid 200.18
 tubercle 26.7
 vein
 lateral 252.26b
 medial 252.26c
 right 232.20a
- Margo
 acetabularis 42.6
 anterior
 (fibula) 48.25
 (lung) 148.17
 (pancreas) 128.10
 (radius) 38.13
 (testis) 158.21
 (tibia) 48.8
 (ulna) 38.30
 ciliaris 358.3
 dexter (heart) 184.15
 falciformis 100.4
 fibularis pedis 402.21
 frontalis
 (parietal bone) 16.34
 (sphenoid) 10.29
 gingivalis 108.23
 incisalis 110.32
 inferior
 (cerebral hemisphere) 306.11
 (liver) 130.15
 (lung) 148.19
 (spleen) 268.11
 inferioris (pancreas) 128.11
 infraorbitalis
 (maxilla) 22.7
 (orbit) 32.16
 interosseus
 (fibula) 48.26
 (radius) 38.8
 (tibia) 48.9
 (ulna) 38.28
 lacrimalis (maxilla) 22.21
 lambdoideus (occipital bone) 8.12
 lateralis
 (forearm) 400.32
 (humerus) 36.19
 (kidney) 154.4
 (nail) 394.1
 (orbit) 32.16a
 pedis 402.21
 (scapula) 34.14
 liber
 (nail) 394.2
 (ovary) 166.10
 linguae 112.36
 mastoideus (occipital bone) 8.11
 medialis
 (adrenal gland) 182.34
 (cerebral hemisphere) 306.12
 (forearm) 400.33
 (humerus) 36.16
 (kidney) 154.5
- Margo
 medialis
 (orbit) 32.16b
 pedis 402.22
 (scapula) 34.13
 (tibia) 48.7
 mesoovarius 166.11
 nasalis (frontal bone) 18.20
 occipitalis
 (parietal bone) 16.31
 (temporal bone) 12.16
 orbitalis (orbit) 32.14
 parietalis
 (frontal bone) 18.11
 (sphenoid) 10.30
 (temporal bone) 16.11
 posterior
 (fibula) 48.27
 partis petrosae 14.17
 (radius) 38.12
 (testis) 158.22
 (ulna) 38.29
 pupillaris 358.2
 radialis 400.32
 sagittalis (parietal bone) 16.33
 sphenoidal (temporal bone) 16.13
 squamosus
 (parietal bone) 16.32
 (sphenoid) 10.31
 superior
 (adrenal gland) 182.33
 (cerebral hemisphere) 306.10
 (pancreas) 128.9
 partis petrosae 14.9
 (scapula) 34.15
 (spleen) 268.10
 supraorbitalis
 (frontal bone) 18.7
 (orbit) 32.15
 tibialis pedis 402.22
 ulnaris 400.33
 uteri dexter/sinister 168.10
 zygomaticus (sphenoid) 10.28
- Massa
 intermedia 296.21
 lateralis atlantis 4.2
- Masseteric
 artery 198.24
 fascia 80.19
 nerve 324.15
 tuberosity 28.4
- Masticatory muscles 78.5
 surface of tooth 110.24
- Mastoid
 air cells 380.17
 angle 16.38
 antrum 380.9
 branches
 occipital artery 196.16
 posterior tympanic artery 196.25
 canaliculus 14.25

- Mastoid**
 emissary vein 240.3
 fontanelle 32.31
 foramen 12.21
 lymph nodes 256.4
 margin of occipital bone 8.11
 notch 12.18
 process 12.17
 wall 380.7
 posterior 380.8
Matrix unguis 392.21
Maxilla 22.2
 body 22.3
 frontal process 22.25
 tuber 22.17
Maxillary
 artery 198.9
 hiatus 22.22
 nerve 322.13
 process 20.19
 sinus 22.24, 138.2
 surface 10.26
 palatine bone 24.18
 veins 236.22
Meatus
 acusticus
 externus 16.3, 386.2
 cartilage 386.5
 cartilagineus 386.4
 internus 14.13, 378.5
 nasi (nasalis)
 inferior 32.6, 136.23
 medius 32.5, 136.21
 superior 32.4, 136.20
 nasopharyngeus 32.9, 136.24
Mebranous lamina 384.22
Medial 396.10
 accessory olivary nucleus
 280.31
 angle of eye 366.11
 antebrachial cutaneous nerve
 338.5
 anterior malleolar artery
 226.26
 aperture of fourth ventricle
 288.9
 arcuate ligament 84.33
 arteriole of retina 360.14
 atrial vein of lateral ventricle
 242.7
 basal
 branch
 left pulmonary artery
 190.39
 right pulmonary artery
 190.25
 segment
 lower lobe of left lung
 150.24
 lower lobe of right lung
 150.12
 segmental bronchus 146.12,
 146.24
 bicipital groove 400.28
 brachial cutaneous nerve 338.4
 branch(-es)
 lumbar nerves 342.3
 middle cerebral artery 204.21
 portal vein of liver 248.14
 posterior ramus, spinal
 nerve 334.16
 sacral/coccygeal nerves
 342.9
 supraorbital nerve 320.26
 calcaneal branches (tibial
 nerve) 346.8
 cardiac branch of right pulmo-
 nary artery 190.25
 cartilaginous lamina 384.20
 central nucleus 298.29
 circumflex femoral
 artery 226.3
 veins 252.10
 common iliac lymph nodes
 264.16
 condyle
 femur 46.21
 tibia 46.29
 cord 336.26
 crest 48.24
 crus
 alar cartilage 134.26
 inguinal ring 86.15
 cuneiform 52.9
 cutaneous branch(-es)
 of the leg 344.6
 of posterior intercostal
 artery 216.11
 dorsal cutaneous nerve 344.22
 epicondyle
 femur 46.22
 humerus 36.28
 external iliac lymph nodes
 264.22
 flattened surface of testis
 158.20
 frontal gyrus 310.7
 frontobasal artery 204.9
 geniculate
 body 296.27
 nucleus
 dorsal part 300.13
 ventral part 300.16
 globus pallidus 316.31
 habenular nucleus 296.11
 head
 of flexor hallucis brevis 98.2a
 of gastrocnemius 96.16
 of triceps 88.22
 inferior genicular artery 226.19
 inguinal fossa 180.16
 intercondylar tubercle 46.35
 intermuscular septum
 of arm 92.18
 of thigh 98.16
 lacunar node 264.25
 lemniscus 280.21, 284.21,
 300.23
 decussation 280.20
Medial
 ligament
 talocrural joint 70.2
 temporomandibular joint
 60.5
 lip of linea aspera 46.15
 longitudinal
 fasciculus 280.23, 284.19,
 292.24
 stria, corpus callosum 312.16
 malleolar
 branches of posterior
 tibial artery 228.10
 network 228.10a
 surface of talus 50.9
 malleolus 48.10
 mammary branches
 intercostal nerve 340.25
 internal thoracic artery 210.8
 margin
 adrenal gland 183.34
 cerebral hemisphere 306.12
 foot 402.22
 forearm 400.33
 humerus 36.16
 kidney 154.5
 orbit 32.16b
 scapula 34.13
 tibia 48.7
 marginal vein 252.26c
 medullary
 branch of posterior inferior
 cerebellar artery 206.15
 lamina 316.30
 meniscus 68.5
 muscular branches of thoracic
 nerves 340.18
 nasal branches of anterior eth-
 moidal nerve 322.9
 nuclei
 of mamillary body 304.7
 of thalamus 298.21
 occipital artery 208.6
 occipitotemporal gyrus 310.20
 olfactory
 gyri 310.31
 striae 310.30
 orbitofrontalis branch of ante-
 rior cerebral
 artery 204.9
 palpebral
 arteries 202.17
 commisure 366.10
 ligament 366.18
 part of superior right pulmo-
 nary vein 230.16
 pectoral nerve 336.28
 plantar
 artery 228.18
 nerve 346.9
 posterior superior nasal
 branches of
 pterygopalatine ganglion
 322.19
 preoptic nucleus 302.17

Medial

- process of calcaneus 50.24
 - prosencephalic fasciculus 304.19
 - pterygoid
 - muscle 80.17
 - plate 12.3
 - rectus muscle 364.6
 - retinaculum of patella 68.17
 - root 296.35, 338.9
 - sacral vein 248.38
 - segment
 - of liver 130.22
 - of middle lobe of right lung 150.8
 - segmental
 - artery 218.11
 - bronchus 146.8
 - subtendinous bursa of
 - gastrocnemius muscle 106.5
 - superior genicular artery 226.15
 - supraclavicular nerves 336.5
 - supracondylar
 - line 46.20a
 - ridge 36.17
 - sural cutaneous nerve 346.4
 - surface
 - of arytenoid cartilage 140.19
 - of fibula 48.22
 - of lung 148.11
 - of ovary 166.8
 - of tibia 48.3
 - of ulna 38.27
 - talocalcaneal ligament 70.15
 - tarsal arteries 228.3
 - tract 76.1
 - tubercle, talus 50.19
 - umbilical
 - fold 180.15
 - ligament 222.30
 - ventral nucleus 300.6
 - venule of retina 360.14
 - vestibular nucleus 282.14, 286.10
 - wall of orbit 32.20
- Medialis 396.10
- Medial 396.3
- antebrachial vein 244.25
 - arcuate ligament 84.35
 - atlanto-axial joint 58.2
 - basilic vein 244.27
 - cephalic vein 244.26
 - cricothyroid ligament 140.8
 - cubital vein 244.24
 - eminence 286.23
 - glossopiglotic fold 118.10
 - groove of tongue 114.10
 - line, posterior 398.1
 - nerve 338.8
 - nuclei of thalamus 298.17
 - palatine suture 54.33
 - sacral
 - artery 216.25
 - crest 4.29

Median

- sulcus 286.22
 - thyrohyoid membrane 138.26
 - umbilical
 - fold 180.13
 - ligament 156.30
- Medianus 396.3
- Mediastinal
- branches
 - aorta 216.6
 - (internal thoracic artery) 210.2
 - lymph nodes
 - anterior 260.9
 - posterior 260.11
 - part of parietal pleura 152.16
 - pleura 152.16
 - surface of lung 148.13
 - veins 234.4, 246.8
- Mediastinum 152.24
- anterior 152.27
 - inferior 152.26
 - middle 152.28
 - posterior 152.29
 - superior 152.25
 - testis 158.25
- Mediomedial frontal branch of callosomarginal artery 204.12
- Medius 396.27
- Medulla
- adrenal 182.38
 - lymph node 254.27
 - oblongata 278.17
 - raphe 282.25
 - sections through 280.9
 - ossium
 - flava 404.4
 - rubra 404.5
 - ovarii 166.17
 - renalis 154.30
 - spinalis 272.13
 - thymi 182.28
- Medullary
- body 290.11
 - cavity 404.3
 - lamina(-ae)
 - internal/external 296.23, 298.23
 - lateral 316.28
 - medial 316.30
 - rays, renal cortex 154.28, 154.29a
 - stria(-ae) 286.30
 - of thalamus 296.24
 - velum
 - inferior 388.4
 - superior 288.2
- Meissner's corpuscles 390.24
- plexus 350.6
- Meibomian glands 366.21
- Membrana
- atlanto-occipitalis
 - anterior 56.27
 - posterior 56.29

Membrana

- basalis, ductus semicircularis 370.16
 - cricovocalis 144.12
 - deciduae 172.23
 - elastica laryngis 144.9
 - fibroelastica laryngis 144.9
 - fibrosa 404.39
 - intercostalis
 - externa 58.25, 84.16
 - interna 58.26, 84.18
 - interossea
 - antebrachii 62.10
 - cruris 68.24
 - obturatoria 66.2
 - perinei 176.6
 - propria ductus semicircularis 370.15
 - pupillaris 358.17
 - quadrangularis 144.10
 - reticularis 374.1
 - spiralis 372.18
 - stapedialis 382.28
 - statoconiorum 372.7
 - sterni 58.23
 - suprapleuralis 152.9
 - synovialis 404.40
 - inferior 60.7
 - superior 60.6
 - tectoria 58.8, 372.26
 - thyrohyoidea 138.25
 - tympani secundaria 380.6
 - tympanica 380.21
 - vestibularis 374.3
 - vitrea 362.8
- Membranous
- ampullae 370.18
 - anterior 370.19
 - lateral 370.21
 - posterior 370.20
 - crura 370.26
 - ampullary 370.28
 - common 370.29
 - simple 370.27
 - labyrinth 370.3
 - part
 - of nasal septum 136.5
 - of urethra 164.29
 - wall 380.20
 - of trachea 144.23
- Meningeal
- artery
 - middle 198.16
 - groove for 16.26b
 - posterior 194.18
 - branch
 - internal carotid 200.19
 - mandibular nerve 324.14
 - occipital artery 196.19
 - ophthalmic nerve 320.20
 - spinal nerve 334.12
 - vagus nerve 332.4
 - nerve 322.14
 - veins 234.27
 - middle 236.24

- Meninges 268.22
 Meniscifemoral ligament
 anterior 68.3
 posterior 68.4
 Meniscus(-i) 404.36
 articularis 404.36
 lateralis 68.2
 medialis 68.5
 tractus 390.26
 Mental
 branch(-es)
 inferior alveolar artery
 198.15
 inferior alveolar nerve
 326.15
 foramen 26.18
 nerve 326.14
 protuberance 26.15
 region 398.18
 spine 26.21
 tubercle 26.16
 Meridians 354.19
 Meridians 354.19
 Meridional fibers 356.25
 Merkel's corpuscles 390.26
 Merocrine sweat glands 394.12
 Mesencephalic
 aqueduct 292.20
 arteries 206.21
 nucleus of trigeminal nerve
 284.30
 tectum 292.12, 294.17
 tegmentum 292.10
 tract of trigeminal nerve
 284.29, 292.26
 nucleus 292.27
 Mesencephalon 290.27
 sections 292.21
 Mesenteric
 artery
 inferior 220.12
 superior 220.1
 ganglion
 inferior 348.16
 superior 348.14
 lymph nodes 264.1
 inferior 264.11
 plexus
 inferior 350.1
 superior 348.28
 vein
 inferior 248.33
 superior 248.20
 Mesenterium 178.9
 Mesenterium 178.2
 dorsale commune 178.1
 Mesentery 178.2
 dorsal 178.1
 root 178.3
 Mesial surface of tooth 110.28
 Meso-appendix 178.9
 Mesocolic lymph nodes 264.8
 Mesocolon 178.4
 of ascending colon (ascendens)
 178.6
 Mesocolon
 of descending colon (descen-
 dens) 178.7
 sigmoideum 178.8
 transversum 178.5
 Mesocortex 314.22a
 Mesometrium 180.25
 Mesonephric duct 172.32
 Mesonephros 172.31
 Mesosalpinx 180.26
 Mesotendineum 405.21
 Mesovarian border 166.11
 Mesovarium 180.27
 Metacarpal
 arteries
 dorsal 214.7
 palmar 214.12
 articulations 64.7
 bones 40.17
 base 40.18
 body 40.19
 head 40.20
 third 40.21
 ligaments
 deep transverse 64.19
 dorsal 64.12
 interosseous 64.14
 palmar 64.13
 superficial transverse 92.23
 veins
 dorsal 244.33
 palmar 244.34
 Metacarpophalangeal joints
 64.16
 Metacarpus 40.16, 400.42
 interosseous spaces 64.15
 Metaphysis 402.48
 Metatarsal
 arteries, plantar 228.23
 bones 52.17
 base 52.18
 head 52.20
 shaft 52.19
 tuberosity
 fifth metatarsal 52.22
 first metatarsal 52.21
 interosseous spaces 72.17
 ligaments
 deep transverse 72.21
 dorsal 72.15
 interosseous 72.14
 plantar 72.16
 superficial transverse 100.19
 veins
 dorsal 252.20
 plantar 252.25
 Metatarsophalangeal joints 72.18
 Metatarsus 52.16, 402.24
 Metathalamus 296.26
 sections 298.11
 Metencephalon 284.1
 Metopic suture 54.11
 Midaxillary line 396.53
 Midbrain 290.27
 Midcarpal joint 62.17
 Midclavicular line 396.50
 Middle 396.27
 calcaneal facet 50.14
 cerebellar peduncle 284.5,
 290.25
 cerebral artery 204.18, 208.17
 cervical
 cardiac nerve 352.7
 ganglion 352.5
 clinoid process 10.7
 colic
 artery 220.11
 lymph nodes 264.10
 vein 248.28
 collateral artery 212.30
 cranial fossa 30.3
 ear 378.15
 cavity 14.30
 facet for the talus 52.2
 finger 400.46
 frontal gyrus 306.28
 genicular artery 226.16
 lobe
 branch of superior right pul-
 monary
 vein 230.14
 of lung 148.24
 right lung 150.6
 of prostate 162.18
 mediastinum 152.28
 meningeal
 artery 198.16
 groove for 16.26b
 veins 236.24
 nasal
 concha 20.15, 136.12
 meatus 32.5, 136.21
 phalanx
 fingers 40.26
 toes 52.26
 pharyngeal constrictor muscle
 118.29
 rectal
 artery 224.7
 plexus 350.13
 veins 250.19
 sinus 138.7
 superior alveolar branch of in-
 fraorbital
 nerve 324.4
 suprarenal artery 220.16
 temporal
 artery 198.6, 204.27
 groove for 16.15
 branches of lateral occipital
 artery 208.4
 gyrus 308.22
 temporal vein 236.20
 thyroid veins 236.2
 trunk 336.15
 Midtarsal joint, transverse 70.16
 Milk teeth 112.25
 Minor
 calices of kidney 156.18
 sublingual ducts 110.4

Mitral valve 188.26
 Mixed nerve 408.5
 Mobile part of nasal septum 134.33
 Modiolus 80.9a, 376.22
 base 376.23
 lamina 376.24
 Molar
 glands 108.34
 teeth 112.23
 Molecular layer
 cerebellum 290.14
 cerebral cortex 316.3
 Mongolian fold 366.6
 Mons pubis 170.25
 Motor
 nerve 408.9
 nucleus of trigeminal nerve 286.1
 root 334.5
 trigeminal nerve 320.18
 Mouth
 angle 108.11
 vestibule 108.3
 Mucosa 118.17
 Mucosal layer of tympanic membrane 380.33
 Mucous
 gland 406.7
 membrane of tongue 114.1
 Müllerian duct 172.33
 Multiform layer of cerebral cortex 316.8
 Multipennate muscle 405.10
 Muscle 405.2
 Muscular
 arteries 202.8
 branches 408.8
 accessory nerve 332.37
 axillary nerve 340.14
 femoral nerve 344.2
 median nerve 338.12
 musculocutaneous nerve 338.2
 obturator nerve 342.29
 perineal nerves 346.21
 peroneal (fibular) nerve 344.22,
 344.26
 radial nerve 340.5
 tibial nerve 346.2
 ulnar nerve 338.18
 of vertebral artery 206.6
 fasciae 364.20
 lacuna 98.20
 process, arytenoid cartilage 140.22
 triangle 398.26
 trochlea 405.29
 Musculocutaneous nerve 338.1
 Musculophrenic
 artery 210.11
 veins 234.17
 Musculotubal canal 12.28
 septum 12.31

Musculus(-i) 405.2
 abdominis 86.1
 abductor
 digiti minimi 92.9, 98.6
 hallucis 98.1
 pollicis
 brevis 92.1
 longus 90.22
 adductor
 brevis 94.24
 hallucis 98.3
 longus 94.23
 magnus 94.25
 minimus 94.25a
 pollicis 90.6
 anconaeus 88.24
 antitragicus 388.19
 arrectores pilorum 392.16
 articularis 405.14
 cubiti 88.25
 genus 94.21
 aryepiglotticus 142.11
 arytenoideus
 obliquus 142.21
 transversus 142.22
 auricularis(-es) 388.14
 anterior 78.23
 posterior 78.25
 superior 78.24
 biceps
 brachii 88.12
 femoris 96.2
 bipennatus 405.9
 brachialis 88.18
 brachioradialis 90.12
 bronchoesophageus 120.9
 buccinator 80.10
 bulbi 364.2
 bulbospongiosus 176.11
 capitis 76.22
 ceratrocricoides 142.16
 chondroglossus 114.21
 ciliaris 356.24
 coccygei 88.1
 coccygeus 88.2, 174.13
 colli (cervicalis) 80.24
 compressor urethrae 176.4a
 constrictor pharyngis
 inferior 118.32
 medius 118.29
 superior 118.22
 coracobrachialis 88.17
 corrugator supercilii 78.21
 cremaster 86.19, 160.28
 cricoarytenoideus
 lateralis 142.16
 posterior 142.15
 cricothyroideus 142.12
 cruciatus 405.13
 cutaneus 405.16
 deltoideus 88.6
 depressor
 anguli oris 80.1
 labii inferioris 80.8
 septi 78.16

Musculus(-i)
 depressor
 supercilii 78.22
 detrusor vesicae 158.4
 digastricus 82.7
 dilator (dilator) 405.11a
 pupillae 358.11
 dorsi 74.1
 epicranii 78.6
 erector spinae 74.10
 extensor
 carpi
 radialis
 brevis 90.14
 longus 90.13
 ulnaris 90.18
 digiti minimi 90.17
 digitorum 90.15
 brevis 96.26
 longus 96.8
 hallucis
 brevis 96.25
 longus 96.10
 indicis 90.25
 pollicis
 brevis 90.23
 longus 90.24
 faciales 78.5
 faucium 116.17
 fibularis
 brevis 96.12
 longus 96.11
 tertius 96.9
 flexor
 accessorius 98.9
 carpi
 radialis 90.1
 ulnaris 90.3
 digiti minimi, brevis 92.10,
 98.7
 digitorum
 brevis 98.8
 longus 96.23
 profundus 90.9
 superficialis 90.6
 hallucis
 brevis 98.2
 longus 96.24
 pollicis
 brevis 92.2
 longus 90.10
 fusiformis 405.5
 gastrocnemius 96.14
 gemellus
 inferior 94.13
 superior 94.12
 genioglossus 114.19
 geniohyoideus 82.12
 gluteus
 maximus 94.6
 medius 94.7
 minimus 94.8
 gracilis 94.26
 helicis
 major 388.15
 minor 388.16

- Musculus(-i)**
 hyoglossus 114.20
 iliacus 94.3
 iliococcygeus 174.10
 iliocostalis 74.15
 cervicis 74.18
 lumborum 74.16
 thoracis 74.17
 iliopsoas 94.2
 incisurae helicis 388.22
 infrahyoidei 82.13
 infraspinalis 88.8
 intercostales
 externi 84.15
 interni 84.17
 intimi 84.19
 interossei
 dorsales 92.13
 pedis 98.11
 palmares 92.14
 plantares 98.12
 interspinales 76.6
 cervicis 76.7
 lumborum 76.9
 thoracis 76.8
 intertransversarii 74.21
 anteriores cervicis 74.28
 laterales lumborum 74.22
 mediales lumborum 74.23
 posteriores cervicis 74.25
 thoracis 74.24
 ischiocavernosus 176.10
 laryngis 142.10
 latissimus dorsi 74.4
 levator
 anguli oris 80.9
 ani 174.6
 glandulae thyroideae 82.20
 labii superioris 80.6
 alaeque nasi 80.7
 palpebrae superioris 364.14
 prostatae 174.8
 scapulae 74.7
 veli palatini 116.19
 levatores costarum 84.12
 breves 84.14
 longi 84.13
 linguae (linguales) 114.18
 longissimus 74.11
 capitis 74.14
 cervicis 74.13
 thoracis 74.12
 longitudinalis
 inferior 114.24
 superior 114.23
 longus
 capitis 78.4
 colli 82.1
 lumbricales 92.12
 pedis 98.10
 masseter 80.12
 masticatorii 78.5
 membri
 inferioris 94.1
 superioris 88.5
- Musculus(-i)**
 mentalis 80.11
 multifidi 76.15
 multipennatus 405.10
 mylohyoideus 82.11
 nasalis 78.13
 obliquus
 auricularis 388.21
 capitis superior 78.2
 externus abdominis 86.9
 inferior 78.3, 364.13
 internus abdominis 86.18
 superior 364.10
 obturator
 externus 96.1
 internus 94.11
 occipitofrontalis 78.7
 omohyoideus 82.15
 opponens
 digiti minimi 92.11, 98.7a
 pollicis 92.5
 orbicularis 405.12
 labial part 78.28
 marginal part 78.27
 oculi 78.17
 oris 78.26
 orbitalis 364.3
 ossiculorum auditoriorum 384.1
 palati 116.17
 palatoglossus 116.22
 palatopharyngeus 116.23
 palmaris
 brevis 90.26
 longus 90.2
 papillaris(-es) 186.3
 anterior 188.16, 190.8
 posterior 188.17, 190.9
 septales 188.18
 pectinati 186.15, 188.21a
 pectineus 94.22
 pectoralis
 major 84.3
 minor 84.7
 perinei (perineales) 174.3
 peroneus
 brevis 96.12
 longus 96.11
 tertius 96.9
 pharyngopalatinus 116.23
 piriformis 94.10
 plantaris 96.20
 pleuroesophageus 120.10
 popliteus 96.21
 procerus 78.12
 pronator
 quadratus 90.11
 teres 88.26
 psoas
 major 94.4
 minor 94.5
 pterygoideus
 lateralis 80.16
 medialis 80.17
 pubococcygeus 174.7
- Musculus(-i)**
 puboprostaticus 162.23
 puborectalis 174.9
 pubovaginalis 174.8
 pubovesicalis 158.5
 pyramidalis 86.8
 auricularis 388.18
 quadratus 405.6
 femoris 94.14
 lumborum 86.32
 plantae 98.9
 quadriceps femoris 94.16
 recto-uterinus 168.31
 rectococcygeus 126.21
 rectourethralis 126.22, 158.7
 rectovesicalis 158.6
 rectus
 abdominis 86.2
 capitis
 anterior 76.24
 lateralis 78.1
 posterior
 major 76.25
 minor 76.26
 femoris 94.17
 inferior 364.5
 lateralis 364.7
 medialis 364.6
 superior 364.4
 rhomboideus
 major 74.5
 minor 74.6
 risorius 80.3
 rotatores 76.16
 cervicis 76.17
 lumborum 76.19
 thoracis 76.18
 sacrococcygeus
 dorsalis 88.4
 ventralis 88.3
 salpingopharyngeus 118.28
 sartorius 94.15
 scalenus
 anterior 82.2
 tuberculum 6.18
 medius 82.3
 minimus 82.5
 posterior 82.4
 semimembranosus 96.6
 semispinalis 76.11
 capitis 76.14
 cervicis 76.13
 thoracis 76.12
 semitendinosus 96.5
 serratus
 anterior 84.11
 posterior
 inferior 74.8
 superior 74.9
 skeleti 405.15
 soleus 96.17
 sphincter 405.11
 ampullae hepatopancreat-
 icae 134.15

Musculus(-i)
 sphincter
 ani
 externus 126.31, 174.14
 internus 126.20
 ductus
 choledochi 134.13
 pancreatici 128.18
 pupillae 358.10
 pyloricus 122.8
 urethrae 176.4
 urethrovaginalis 176.4b
 spinalis 76.2
 capitis 76.5
 cervicis 76.4
 thoracis 76.3
 splenus
 capitis 74.20
 cervicis 74.19
 stapedius 384.3
 sternalis 84.2
 sternocleidomastoideus 80.26
 sternohyoideus 82.14
 sternothyroideus 82.18
 styloglossus 114.22
 stylohyoideus 82.10
 stylopharyngeus 118.27
 subclavius 84.8
 subcostales 84.20
 suboccipitales 76.23
 subscapularis 88.11
 supinator 90.21
 suprahyoidei 82.6
 supraspinatus 88.7
 suspensorius duodeni 124.10
 tarsalis
 inferior 366.23
 superior 366.22
 temporalis 80.15
 temporoparietalis 78.10
 tensor
 fasciae latae 94.9
 tympani 384.2
 veli palatini 116.20
 tensoris tympani semicanalis 12.29
 teres
 major 88.10
 minor 88.9
 thoracis 84.1
 thyroarytenoideus 142.20
 thyroepiglotticus 142.19
 thyrohyoideus 82.19
 tibialis
 anterior 96.7
 posterior 96.22
 trachealis 144.21
 tragicus 388.17
 transversospinales 76.10
 transversus
 abdominis 86.20
 auricularis 388.20
 linguae 114.25
 menti 80.2
 nuchae 74.3

Musculus(-i)
 transversus
 perinei
 profundus 176.3
 superficialis 176.9
 thoracis 84.21
 trapezius 74.2
 triangularis 405.7
 triceps
 brachii 88.19
 surae 96.13
 unipennatus 405.8
 uvulae 116.21
 vastus
 intermedius 94.19
 lateralis 94.18
 medialis 94.20
 verticalis linguae 114.26
 vocalis 142.18
 zygomatikus
 major 80.4
 minor 80.5
 Myenteric plexus 350.5
 Mylohyoid
 branch of inferior alveolar
 artery 198.14
 groove 28.9
 line 26.22
 nerve 326.10
 Myocardium 186.7
 Myology (myologia) 405.1

N

Nail(-s) 392.20
 body 392.26
 groove 392.23
 matrix 392.21
 crest of 392.22
 root 392.27
 sinus 392.24
 wall 392.25
 Nares 136.2
 Nasal
 arteriole of retina
 inferior 360.11
 superior 360.10
 artery, dorsal 202.21
 bone 20.26
 border, frontal bone 18.20
 branches
 anterior ethmoidal nerve
 322.6
 external 322.10
 internal 322.7
 lateral 322.8
 medial 322.9
 infraorbital nerve
 external 324.10
 internal 324.11
 pterygopalatine ganglion
 322.23
 lateral posterior superior
 322.18
 medial posterior superior
 322.19

Nasal
 cartilages 134.23
 accessory 134.29
 lateral 134.24
 cavity 32.1, 136.1
 concha
 highest, rudimentary 20.13
 inferior 20.17, 136.13
 middle 20.15, 136.12
 superior 20.14, 136.11
 crest 24.2, 24.32
 foramina 20.27a
 glands 136.16a
 meatus
 inferior 32.6, 136.23
 middle 32.5, 136.21
 superior 32.4, 136.20
 mucosa of olfactory region
 388.24
 muscle, alar part 78.15
 notch 22.11
 openings 136.2
 part of frontal bone 18.18
 region 398.16
 septum 136.4
 bony 32.2, 136.6
 cartilaginous 134.30,
 136.5a
 lateral process 134.30a
 membranous part 136.5
 mobile part 134.33
 posterior process 134.31
 spine 18.19
 anterior 22.12
 posterior 24.31
 surface 24.28
 maxilla 22.18
 palatine bone 24.17
 veins, external 236.10
 venule of retina
 inferior 360.11
 superior 360.10
 vestibule, hairs 392.8
 Nasion 28.34
 Nasociliary nerve 322.1
 Nasofrontal vein 242.26
 Nasolabial node 256.12
 Nasolacrimal
 canal 32.7
 duct 368.23
 aperture 136.23a
 Nasomaxillary suture 54.27
 Nasopalatine nerve 322.20
 long 322.20a
 short 322.20c
 Nasopharyngeal
 meatus 32.9, 136.24
 tonsil 116.27
 Nasopharynx 116.26
 Nasus externus 134.18
 Navicular
 bone 52.7
 tuberosity 52.8
 fossa, urethra 164.31
 valve 164.32

Neck

- of femur 46.5
- of fibula 48.19
- of gallbladder 134.4
- of humerus
 - anatomical 36.4
 - surgical 36.5
- lymph nodes 256.2
- of mandible 28.14
- muscles 80.24
- of radius 38.5
- of ribs 6.11
- of scapula 34.23
- of talus 50.5
- of tooth 110.20
- of urinary bladder 156.29
- Neocerebellum 290.8
- Neocortex 314.22
- Nephros 154.3
- Nerve 407.2
 - branches, internal carotid 200.21
 - cell 408.18
 - body 408.19
 - to external acoustic meatus 324.25
 - fibers
 - afferent 407.6
 - autonomic 407.9
 - effluent 407.7
 - postganglionic 407.18
 - preganglionic 407.17
 - somatic 407.8
 - visceral 407.9
 - foramina 372.22
 - to lateral pterygoid 324.17
 - to medial pterygoid 324.18
 - to obturator internus muscle 344.9
 - of pterygoid canal 328.23
 - to pyriformis muscle 344.10
 - to quadratus femoris 344.11
 - roots 336.12a
 - to stapedius 328.3
 - to subclavius 336.22
 - to tensor tympani muscle 324.22
 - to tensor veli palatini muscle 324.21
- Nervus
 - part of retina 358.22
 - system 268.21
 - tissue 408.17
- Nervus(-i) 407.2
 - abducens 326.18
 - accessorius 332.31
 - alveolaris(-es)
 - inferior 326.9
 - superiores 324.2
 - ampullaris
 - anterior 330.10
 - lateralis 330.11
 - posterior 330.13
 - anococcygei 346.26

Nervus(-i)

- antebrachii
 - anterior 338.11
 - posterior 340.7
- auricularis(-es)
 - anteriores 324.29
 - magnus 334.28
 - posterior 328.6
- auriculotemporalis 324.24
- autonomicus 408.12
- axillaris 340.13
- buccalis 324.23
- canalis pterygoidei 328.23
- cardiacus cervicalis
 - inferior 352.10
 - medius 352.7
 - superior 352.4
- caroticocotympanici 330.24
- caroticus
 - externi 350.31
 - internus 350.29
- cavernosi
 - clitoridis 350.20
 - penis 350.19
- cervicales 334.14
- chordae tympani canaliculus 12.24
- ciliares
 - breves 320.10
 - longi 322.3
- coccygeus 342.7, 346.24
- cochlearis 330.3, 330.15
- craniales 320.2, 408.1
- cutaneus
 - antebrachii
 - lateralis 338.3
 - medialis 338.5
 - posterior 340.4
 - brachii
 - lateralis
 - inferior 340.3
 - superior 340.15
 - medialis 338.4
 - posterior 340.2
 - dorsalis
 - intermedius 344.24
 - lateralis 346.6
 - medialis 344.23
 - femoris
 - lateralis 342.24
 - posterior 344.14
 - perforans 344.16a
 - surae
 - lateralis 344.19
 - medialis 346.4
- digitales
 - communes 338.15
 - dorsales
 - digiti secundi medialis 344.28
 - hallucis lateralis 344.28
 - (hand) 338.20, 340.10
 - pedis 344.25
- palmares
 - communes 338.23
 - proprii 338.16, 338.24

Nervus(-i)

- digitales
 - plantares
 - communes 346.10, 346.14
 - proprii 346.11, 346.15
- dorsalis
 - clitoridis 346.23
 - penis 346.22
 - scapulae 336.20
- encephalici 320.2, 408.1
- ethmoidalis
 - anterior 322.5
 - posterior 322.4
- facialis 328.1
- femoralis 344.1
- fibularis
 - communis 344.18
 - profundus 344.26
 - superficialis 344.21
- frontalis 320.23
- genitofemoralis 342.21
- glossopharyngeus 330.17
- gluteus
 - inferior 344.13
 - superior 344.12
- hypogastricus, dexter/sinister 350.10
- hypoglossus 334.1
- iliohypogastricus 342.15
- ilioinguinalis 342.18
- incisivus 322.20
- infraorbitalis 324.1
- infratrochlearis 322.11
- intercostales 340.20
- intercostobrachiales 340.23
- intermediofacialis 328.1
- intermedius 328.19
- interosseus
 - anterior 338.11
 - cruris 346.3
 - posterior 340.7
- ischiadicus 344.17
- jugularis 350.28
- labiales
 - anteriores 342.20
 - posteriores 346.20
- lacrimalis 320.21
- laryngealis
 - recurrens 332.15
 - superior 332.10
- laryngeus, inferior 332.18
- lingualis 326.1
- lumbales (lumbares) 342.1
- mandibularis 324.13
- massetericus 324.15
- maxillaris 322.13
- meatus acustici externi 324.25
- medianus 338.8
- mentalis 326.14
- mixtarum neurofibrarum 408.5
- mixtus 408.5
- motorius 408.9
- musculi
 - obturatorii interni 344.9
 - piriformis 344.10

- Nervus(-i)
 musculi
 quadrati femoris 344.11
 tensoris
 tympani 324.22
 veli palatini 324.21
 muscucutaneus 338.1
 mylohyoideus 326.10
 nasociliaris 322.1
 nasopalatinus 322.20
 breves 322.20c
 longus 322.20a
 nervorum 408.16
 obturatorius 342.25
 accessorius 342.30
 occipitalis
 major 334.19
 minor 334.27
 tertius 334.20
 oculomotorius 320.5
 olfactorii 320.3
 ophthalmicus 320.19
 opticus 320.4, 354.4
 palatinus
 major 322.22
 minores 322.24
 pectoralis
 lateralis 336.29
 medialis 336.28
 pelvici splanchnici 352.34
 perineales 346.19
 petrosus
 major 328.24
 majoris, hiatus of canal 14.4
 minor 330.32
 hiatus of canal 14.5
 profundus 328.25
 pharyngeus 322.21
 phrenici accessorii 336.11
 phrenicus 336.8
 plantaris
 lateralis 346.12
 medialis 346.9
 pterygoideus
 lateralis 324.17
 medialis 324.18
 pudendus 346.17
 radialis 340.1
 rectales (anales) inferiores 346.18
 saccularis 330.14
 sacrales 342.7
 saphenus 344.4
 sciaticus 344.17
 scrotales
 anteriores 342.19
 posteriores 346.20
 sensorius 408.10
 spinalis(-es) 334.3, 407.23
 sulcus 2.22
 spinosus 324.14
 splanchnicus
 imus 352.20
 lumbales (lumbares) 352.22
 major 352.16
- Nervus(-i)
 splanchnicus
 minor 352.18
 sacrales 352.24
 stapedius 328.3
 subclavius 336.22
 subcostalis 340.26
 sublingualis 326.5
 suboccipitalis 334.18
 subscapularis 340.11
 supraclaviculares 336.4
 intermedii 336.6
 laterales (posteriores) 336.7
 mediales 336.5
 supraorbitalis 320.24
 suprascapularis 336.23
 supratrochlearis 320.27
 suralis 346.5
 temporales profundi 324.16
 terminalis 352.27
 thoracici 340.16
 longus 336.21
 thoracodorsalis 340.12
 tibialis 346.1
 transversus colli 336.1
 trigeminus 320.15
 trochlearis 320.13
 tympanicus 330.20
 ulnaris 338.17
 utricularis 330.9
 utriculoampullaris 330.8
 vaginales 350.17
 vagus 332.1
 vasorum 406.20, 408.15
 vertebralis 352.12
 vestibularis 330.2, 330.4
 vestibulocochlearis 330.1
 zygomaticus 322.25
- Neural lobe of pituitary gland 182.21
- Neurium 408.20
- Neurocentral junction (synchondrosis) 2.6a
- Neurocranium 8.1a
- Neurocytus 408.18
- Neuroepithelial layer of retina 358.23
- Neuroepithelium 370.24, 372.8
- Neurofibræ
 afferentes 407.6
 associationes 318.33
 autonomicae 407.9
 commissurales 318.34
 efferentes 407.7
 postganglionicae 407.18
 praeganglionicae 407.17
 projectiones 318.35
 somaticae 407.8
 tangentiales 316.9
- Neurohypophysis 182.19, 296.39, 304.9
- Neuron 408.18
- Nipple 394.19
- Node of Aschoff-Tawara 186.9
- Nodose ganglion 332.3
- Nodus(-i) 290.2
 lymphaticus (lymphonodus) 254.29, 406.22
 thymici accessorii 182.25
 valvularum semilunarium 188.14, 190.6
- Nodus(-i)
 accessorii 258.12
 arcus venae azygos 260.17
 arcuotricularis 186.9
 buccinatorius 256.11
 cysticus 262.30
 fibularis 266.23
 foraminialis 262.31
 juglodigasticus 258.6
 juguloomohyoideus 258.8
 lacunaris
 intermedius 264.26
 lateralis 264.27
 medialis 264.25
 ligamenti arteriosi 260.10
 lymphaticus(-i) 254.23, 406.21
 anorectales 266.12
 anteriores 258.5, 258.10
 aortici laterales 262.3
 apicales 258.17
 appendiculares 264.7
 axillares 258.16
 brachiales 258.18, 258.24
 caavales laterales 262.8
 centrales 258.21, 264.3
 cervicales
 anteriores 256.17
 laterales 258.1
 coeliaci 262.14
 colici (dextra/media/sinistra) 264.10
 cubitales 258.25
 deltopectoriales 258.23
 epigastrici inferiores 262.12
 faciales 256.10
 gastrici (dextri/sinistri) 262.15
 gastro-omentales (dextri/sinistri) 262.17
 gluteales inferiores 266.3
 hepatici 262.29
 ileocolici 264.4
 iliaci
 communes 264.15
 intermedii 264.17
 laterales 264.18
 mediales 264.16
 promontorii 264.20
 subaortici 264.19
 externi 264.21
 interiliaci 264.28
 intermedii 264.23
 laterales 264.24
 mediales 264.22
 obturatorii 264.29
 interni 266.1
 inferiores 266.17
 infra-auriculares 256.8
 infraclaviculares 258.23
 infrahyoidei 256.19a

- Nodus(-i)
 lymphaticus(-i)
 inguinales
 profundi 266.18
 superficiales 266.14
 intercostales 260.4
 interpectorales 258.22
 intraglandulares 256.9
 jugulares anteriores 256.18
 juxtaintestinales 264.2
 juxtaoesophageales pulmonales 260.12
 laryngis 144.16
 laterales 258.4, 258.9
 linguales 256.14a
 lumbales (lumbares)
 dextri 262.7
 intermedii 262.6
 sinistri 262.2
 mastoides 256.4
 mediastinales anteriores 260.9
 mesenterici 264.1
 inferiores 264.11
 mesocolici 264.8
 occipitales 256.3
 pancreatici 262.22
 inferiores 262.24
 superiores 262.23
 pancreaticoduodenales 262.26
 inferiores 262.28
 superiores 262.27
 paracolicus 264.9
 pararectales 266.12
 parasternales 260.3
 paratracheales 256.23, 260.16
 parauterini 266.10
 paravaginales 266.11
 paravesiculares 266.6
 parietales 262.1, 264.14
 parotidei
 profundi 256.6
 superficiales 256.5
 pectorales 258.20
 pericardiales laterales 260.8
 phrenici
 inferiores 262.11
 superiores 260.6
 popliteales
 profundi 266.20
 superficiales 266.19
 postaortici 262.5
 postcavales 262.10
 posteriores 260.11
 postvesiculares 266.8
 prae-auriculares 256.7
 praelaryngeales 256.20
 praevertebrales 260.5
 preaortici 262.4
 precaecales 264.5
 precavales 262.9
 prepericardiales 260.7
 pretracheales 256.22
 prevesiculares 266.7
- Nodus(-i)
 lymphaticus(-i)
 profundi 256.19, 258.28
 inferiores 258.7
 superiores 258.3
 pylorici 262.18
 rectales superiores 264.13
 regionales 256.1
 retroauriculares 256.4
 retrocaecales 264.6
 retropharyngeales 256.23a, 258.13
 sacrales 266.4
 sigmoidei 264.12
 solitarii 126.12
 splenici (linales) 262.25
 submandibulares 256.16
 submentales 256.15
 subscapulares 258.19
 superficiales 256.18, 258.2, 258.27
 superiores 264.3
 superolaterales 266.16
 superomediales 266.15
 supraclaviculares 258.11
 supratrochlearis 258.26
 thyroidei 256.21
 tracheobronchiales 260.13
 inferiores 260.15
 superiores 260.14
 vesiculares laterales 266.9
 viscerales 262.13
 malaris 256.13
 mandibularis 256.14
 nasolabialis 256.12
 retropylorici 262.21
 sinuatralis 186.8
 subpylorici 262.20
 suprapyloricus 262.19
 tibialis
 anterior 266.21
 posterior 266.22
- Nomina generalia 405.36
 Norma
 basilaris 30.16
 facialis 28.32
 lateralis 30.10
 occipitalis 32.25
 verticalis (calvaria) 28.28
- Nose 134.18
 alae (wings) 22, 134
 dorsum (bridge) 134.20
 posterior apertures of 32.10
 root 134.19
 tip 134.21
 vestibule 136.8
- Nostrils 136.2
 Notch see Incisura
- Nuchal
 fascia 76.21
 line
 highest 8.25
 inferior 8.27
 superior 8.26
 region 398.32
- Nuclear regions 300.20
 Nucleus(-i)
 ambiguus 282.20
 ansae lenticularis 302.15
 anteriores (thalami) 298.13
 anterodorsalis (anterosuperior), (thalamus) 298.14
 anterolateralis 274.19
 anteromedialis 274.20
 (thalamus) 298.16
 anteroventralis (anteroinferior), (thalamus) 298.15
 arcuatus(-i) 282.22, 302.22, 304.5
 basales 316.20
 caudatus 316.22
 centralis 274.24
 lateralis 298.28
 medialis 298.29
 centromedianus 298.25
 cerebellaris 290.17
 cochleares 282.16, 286.13
 colliculi inferioris 294.19
 commissuralis 282.19
 corporis geniculati
 lateralis
 pars dorsalis 300.12
 pars ventralis 300.15
 medialis
 pars dorsalis 300.13
 pars ventralis 300.16
 corporis mamillarum
 laterales 304.7
 mediales 304.7
 corporis trapezoidei
 anterior 286.15
 posterior 286.16
 cuneatus 280.17
 accessorius 280.18
 dentatus 290.18
 dorsalis, nervi vagi 282.7
 emboliformis 290.20
 endopeduncularis 294.6
 fastigii 290.22
 globosus 290.21
 gracilis 280.15
 habenulares (medialis/lateralis) 296.11
 hypoglossalis 282.5
 hypothalamicus
 anterior 302.20
 dorsalis 304.3
 dorsomedialis 304.2
 posterior 304.8
 ventromedialis 304.1
 infundibularis 304.5
 intercalatus 282.8
 interpeduncularis 292.31
 interstitialis (Cajal) 294.1
 lacrimalis 286.6
 lateralis
 dorsalis 300.3
 posterior 300.2

Nucleus(-i)
 lemnisci lateralis 286.18
 lentiformis (lenticularis) 316.26
 lentis 362.13
 medialis(-es)
 dorsalis 298.22
 thalami 298.21
 mediani thalami 298.17
 mesencephalicus, nervi trigeminalis 284.30
 motorius, nervi trigeminalis 286.1
 nervi
 abducentis 286.2
 accessorii 274.25
 facialis 286.3
 oculomotorii 292.28
 accessorius 292.29
 phrenici 274.26
 trochlearis 292.30
 nervorum cranialium 408.2
 olivaris
 accessorius
 medialis 280.31
 posterior 280.32
 inferior 280.28
 superioris 286.7
 originis 408.3
 paracentralis 298.26
 parafascicularis 298.27
 paramedianus posterior 282.6
 parasolitaris 282.11
 parasymphathici sacrales 276.15
 parataenialis (thalami) 298.20a
 paraventricularis(-es) 302.19
 anteriores/posteriores 298.18
 periventricularis posterior 304.4
 pontinus, nervi trigeminalis 284.27
 pontis 284.16
 posteriores (thalami) 300.10
 posterolateralis 274.21
 posteromedialis 274.23
 preopticus
 lateralis 302.17
 medialis 302.17
 preteales 296.15
 pulposus 56.12
 pulvinares 300.11
 raphae 282.26
 regionum 300.20
 reticulatus (thalami) 298.12, 298.24, 300.18
 retroposterolateralis 274.22
 reuniens 298.20
 rhomboidalis 298.19
 ruber 294.3
 salivarius
 inferior 282.21
 superior 286.5
 solitarius 282.10
 spinalis, nervi trigeminalis 280.26, 284.26

Nucleus(-i)
 subthalamicus 300.17
 supraopticus 302.18
 tegmenti (tegmentales) 294.2
 terminationis 408.4
 thalami 300.1
 tractus mesencephalici, nervi trigeminalis 292.27
 tuberales 302.23
 vagalis dorsalis 282.7
 ventralis
 anterior 300.4
 intermedius 300.5
 medialis 300.6
 posterior 300.7
 posterolateralis 300.8
 posteromedialis 300.9
 ventrolaterales 300.1
 vestibularis(-es) 282.12, 286.9
 inferior 282.13
 lateralis 282.15, 286.11
 medialis 282.14, 286.10
 superior 286.12

Nutrient

artery(-ies) 406.13
 of femur 226.12a
 of fibula 228.17a
 of humerus 212.28
 of tibia 229.11a
 canal 404.7
 foramen 404.6

O

Obex 288.8

Oblique

arytenoid muscle 142.21
 cord 62.11
 diameter, pelvis 44.32
 fibers, stomach 122.9
 fissure, lung 148.26
 head
 of adductor hallucis 98.4
 of adductor pollicis 92.7
 line 26.19, 138.21
 muscle
 external abdominal 86.9
 internal abdominal 86.18
 part of m. cricothyroideus 142.14
 popliteal ligament 68.14
 sinus of pericardium 184.9
 vein of left atrium 232.18

Oblong fovea 140.17

Obturator

artery 222.14
 accessory 224.24
 branch of inferior epigastric artery 224.23
 canal 66.3
 crest 44.16
 external iliac lymph nodes 264.29
 fascia 174.20
 foramen 42.4

Obturator

groove 55.17
 membrane 66.2
 nerve 342.25
 accessory 342.30
 tubercle
 anterior 44.18
 posterior 44.19
 veins 250.4
 accessory 250.24a

Occipital 396.18
 angle 16.36
 artery 196.15
 groove for 12.20
 lateral 208.2
 medial 208.6
 bone 8.2
 basilar part 8.6
 groove for inferior petrosal sinus 8.7
 intrajugular process 8.21
 lateral (condylar) part 8.9
 squamous part 8.10
 border
 parietal bone 16.31
 temporal bone 12.16
 branch(-es)
 occipital artery 196.20
 posterior auricular artery 196.28
 nerve 328.7
 condyle 8.14
 crest
 external 8.24
 internal 8.30
 diploic vein 238.28
 emissary vein 240.5
 lobe 308.10
 lymph nodes 256.3
 nerve
 greater 334.19
 lesser 334.27
 third 334.20
 plane 8.27a
 pole 308.11
 protuberance
 external 8.22
 internal 8.29
 region 398.12
 sinus 238.11
 groove for 8.33a
 sulcus, transverse 308.12
 vein(-s) 234.9, 238.2, 240.15

Occipitalis 396.18
 Occipitomastoid suture 54.5
 Occipitotemporal
 branch of medial occipital artery 208.11
 gyrus
 lateral 310.22
 medial 310.20
 sulcus 310.21
 Occiput 28.31
 Occluded part of umbilical artery 222.29a

- Occlusal surface of tooth 119.24
- Oculomotor
nerve 320.5
 branch of posterior communicating artery 208.20
 nucleus 292.28
 sulcus 290.31
- Oculus 354.3
- Oesophagus 120.2
- Olecranon 38.19
 fossa 36.25
- Olfactory
brain 310.26a, 312.1
bulb 310.27
glands 136.16a
glands (of Bowman) 388.25
gyri
 lateral 310.31
 medial 310.31
nerve 320.3
organ 388.23
region of nose 136.16
striae
 lateral 310.30
 medial 310.30
sulcus 136.10, 310.24
tract 310.28
trigone 310.29
- Olivary nucleus
inferior 280.28
medial accessory 280.31
posterior accessory 280.32
superior 286.7
- Olive (oliva) 278.23
- Olivocerebellar tract 282.3
- Olivocochlear tract 286.8
- Olivospinal tract 276.33, 282.1
- Omental
branches of gastroepiploic artery 218.21, 218.33
bursa 176.30
 vestibule 176.31
foramen 176.29
recess
 lower 176.33
 upper 176.32
- Omentum
major 178.14
minor 178.10
- Omoacclavicular triangle 398.31
- Opercular part of inferior frontal gyrus 306.31
- Operculum
frontoparietale 308.7
temporale 308.20
- Ophthalmic
artery 202.1
nerve 320.19
vein
 inferior 244.8
 superior 242.25
- Opisthion 8.5
- Optic
axis 354.22
canal 10.20
- Optic
chiasma 296.32
disc (papilla) 360.1
nerve 320.4, 354.4
radiation 300.29, 318.22
recess 298.4
tract 296.33
- Ora serrata 358.26
- Oral
cavity 108.2
 proper 108.14
 small glands 108.31
fissure 108.4
mucosa 108.19
region 398.17
- Orbicular
muscle 405.12
 zone 66.22
- Orbicular ciliaris 356.23
- Orbit(-a) 32.12
- Orbital
aditus 32.13
branch(-es)
 pterygopalatine ganglion 322.17
 superior tympanic artery 198.22
eminence 26.6a
fasciae 364.17
fat body 364.23
fissure
 inferior 32.24
 superior 10.22, 32.23
gyri 310.25
margin 32.14
muscle 364.3
part
 of frontal bone 18.21
 of inferior frontal gyrus 306.32
 of lacrimal gland 368.11
 of m. orbicularis oculi 78.19
 of optic nerve 354.7
plate 20.11
process 24.25
region 398.15
septum 364.19
sulci 310.26
surface
 frontal bone 18.22
 maxilla 22.4
 sphenoid 10.27
 zygomatic bone 26.4
 veins 242.24a
- Orchis 158.16
- Organ of Corti 372.19
- Organum(-a)
extraperitoneale 176.22
genitalia
 femina
 externa 170.23
 interna 166.5
 masulina
 externa 162.26
 interna 158.15
- Organum(-a)
gustatorium 388.26
oculi accessoria 364.1
olfactorium (olfactus) 388.23
sensoria (sensuum) 354.1
spirale (Corti) 372.19
subcommissurale 296.19
subfornicale 296.18
urinaria 154.2
vestibulocochleare 370.1
visus (visuale) 354.2
vomeronasale 136.7
- Orifice of vagina 172.1
- Oropharynx 118.8
- Os(-sa)
alveolare 112.17
breve 402.42
capitatum 40.12
carpi (carpalia) 40.2
centrale 40.3
coccygis 4.37
costale (costa) 6.7
coxae (pelvicum) 42.3
cranii 8.1
cuboideum 52.12
cuneiforme
 intermedium 52.10
 laterale 52.11
 mediale 52.9
digitorum 40.23
 pedis 52.23
ethmoidale 20.1
faciei 22.1
femoris 46.2
frontale 18.1
 squama 18.2
hamatum 40.13
hyoideum 28.16
ilii (iliacum) 42.10
incisivum 24.3
interparietale 8.13
irregularare 402.44
ischii 44.1
lacrimale 20.21
longum 402.41
lunatum 40.6
membri
 inferioris 42.1
 superioris 34.1
metacarpi (metacarpalia) 40.17
 tertium 40.21
metatarsi (metatarsalia) 52.17
multangulum
 majus 40.9
 minus 40.11
nasale 20.26
naviculare 40.4, 52.7
occipitale 8.2
 pars basilaris 8.6
 pars lateralis 8.9
 processus intrajugularis 8.21
palatinum 24.15
parietale 16.24
pisiforme 40.8
planum 402.43

Os(-sa)
 pneumaticum 402.45
 pubis 44.8
 sacrum (sacrale) 4.16
 pars lateralis 4.21
 scaphoideum 40.4
 sesamoidea
 fingers 40.32
 toes 52.32
 sphenoidale 10.1
 ala major 10.23
 ala minor 10.19
 spina 1–38
 suprasternalia 6.34
 suturalia 30.9
 tarsi (tarsalia) 50.2
 temporale 12.14
 thoracis 6.1
 trapezium 40.9
 trapezoideum 40.11
 trigonum 50.21
 triquetrum 40.7
 zygomaticum 26.1

Osseous
 ampullae 376.10
 anterior 376.11
 lateral 376.13
 posterior 376.12
 crus 376.14
 ampullary 376.17
 common 376.15
 simple 376.16
 labyrinth 374.20
 part of auditory tube 384.15
 semicircular canals 376.6

Ossicle 40.3

Ossicula auditoria (auditus)
 382.1

Osteology (osteologia) 402.29

Ostium(-a)
 abdominale tubae uterinae
 166.30
 aortae 184.31, 190.1
 appendicis vermiformis 124.23
 atrioventriculare 184.29
 dextrum 188.2
 sinistrum 188.25
 cardiacum (cardia) 120.27
 papillae ilealis 124.21a
 pharyngeum tubae auditivae
 (auditoriae) 118.2, 384.25
 pyloricum 122.2
 sinus coronarii 186.27a
 trunci pulmonalis 184.30,
 188.9
 tympanicum tubae auditoriae
 384.14
 ureteris 158.12
 urethrae
 externum 164.33
 feminae 172.14
 internum 158.13
 uteri 168.18
 uterinum tubae 166.37
 vaginae 172.1

Ostium(-a)
 valvae ilealis 124.20
 venae cavae
 inferioris 186.24
 superioris 186.23
 venarum pulmonalium 188.23

Otic ganglion 324.19, 326.17,
 330.31, 352.31

Outer 396.30a
 margin of foot 402.21

Oval window 378.23

Ovarian
 artery 222.3
 branch of uterine artery 224.4
 fimbria 166.33
 follicles
 primary 166.18
 vesicular (Graafian) 166.19
 fossa 180.29
 ligament 166.28
 plexus 348.27
 vein
 left 246.31
 right 246.34

Ovary (ovarium) 166.6
 cortex 166.16
 hilum 166.7
 medulla 166.17
 stroma 166.15
 suspensory ligament 180.28

Oviduct 166.29

Ovoidal joint 404.32

Ovum (oocyte) 166.25

P

Pacchionian granulations 28.27

Pacinian corpuscles 390.23

Palaeocortex 314.21

Palate 108.15
 hard 30.22, 108.16
 muscles of 116.17
 soft 108.17, 116.4

Palatine
 aponeurosis 116.18
 artery
 ascending 196.8
 descending 200.5
 greater 200.6
 lesser 200.7
 bone 24.15
 canals
 greater 30.17
 lesser 24.22
 crest 24.33
 folds, transverse 108.29
 foramina
 greater 30.23
 lesser 24.30
 glands 108.35
 grooves 24.7
 nerves
 greater 322.22
 lesser 322.24
 process 24.1

Palatine
 raphe 108.18
 spines 24.6
 sulcus, greater 22.23, 24.20
 surface 24.29
 tooth 110.26
 suture
 median 54.33
 transverse 54.34
 tonsil 116.9
 vein, external 236.16

Palatoethmoidal suture 54.32

Palatoglossal arch 116.6

Palatomaxillary suture 54.31

Palatopharyngeal arch 116.7

Palatovaginal
 canal 30.28
 groove 12.8

Palatum 108.15
 durum 108.16
 molle 108.17, 116.4
 osseum 30.22

Paleocerebellum 290.7

Paleocortex 314.21

Palma manus 400.39

Palmar 396.41
 aponeurosis 92.24
 arch
 deep 214.11
 superficial 214.27
 branch
 median nerve 338.13
 ulnar nerve 338.21
 carpal branch
 radial artery 214.3
 ulnar artery 214.24

carpometaacarpal ligaments
 64.9
 digital veins 244.31
 intercarpal ligaments 62.25
 ligaments 64.18, 64.22
 metacarpal
 arteries 214.12
 ligaments 64.13
 veins 244.33
 radiocarpal ligament 62.19
 side of fingers 400.49
 ulnocarpal ligament 62.20

Palmaris 396.41

Palmate folds 168.22

Palpebra(-ae) 366.2
 inferior 366.4
 superior 366.3

Palpebral
 arch
 inferior 202.19
 superior 202.18
 arteries
 lateral 202.5
 medial 202.17
 branches of infratrochlear
 nerve 322.12
 commissure, lateral 366.9
 conjunctiva 368.2
 fissure 366.8

- Palpebral ligament
lateral 366.20
medial 366.18
- part
of lacrimal gland 368.12
of m. orbicularis oculi 78.18
- raphe, lateral 366.19
- surface
anterior 366.5
posterior 366.7
- veins 244.6
inferior 236.11
superior 236.9
- Pampiniiform plexus 246.35
- Pancreas 128.1
accessorium 128.20
capsule 128.14
endocrine 128.21
exocrine 128.15
head 128.2
tail 128.13
- Pancreatic artery, dorsal 218.27
branches
anterior superior pancreaticoduodenal artery 218.22
posterior superior pancreaticoduodenal artery 218.16
splenic artery 218.26
- duct 128.17
accessory 128.19
lobule 128.16
lymph nodes 262.22
inferior 262.24
superior 262.23
- notch 128.4
plexus 348.21
veins 248.23, 248.30
- Pancreaticoduodenal artery
anterior superior 218.22
inferior 220.2
posterior superior 218.15
lymph nodes 262.26
inferior 262.28
superior 262.27
- veins 248.24
- Panniculus adiposus 390.20
- Papilla(-ae) 390.17
conicae 114.5
dentis 112.8
ductus parotidei 108.28
duodeni
major 124.12
minor 124.13
filiformes 114.4
foliatae 114.9
fungiformes 114.6
gingivalis 108.24
ilealis 124.19a
incisiva 108.30
lacrimalis 168.17
- Papilla(-ae)
lentiformes 114.8
linguales 114.3
mammae 394.19
nervi optici 360.1
pili 392.12
renales 154.33
vallatae 114.7
- Papillary foramina 154.35
layer 390.17
muscles 186.3
anterior 188.16, 190.8
posterior 188.17, 190.8
septal 188.18
process 130.27
Para-aortic bodies 194.3
- Paracentral artery 204.15
lobule 310.8
nucleus 298.26
- Paracervix 168.25
- Paracolic lymph nodes 264.9
sulci 180.8
- Paradidymis 160.12
- Paraduodenal fold 178.32
recess 178.33
- Parafascicular nucleus 298.27
- Paraflocculus 290.5
- Parahippocampal gyrus 310.15
- Paramammary lymph nodes 260.2
- Paramastoid process 8.34
- Paramedian lobule 288.36
- Paramesonephric duct 172.33
- Parametrium 168.24
- Paranasal sinuses 138.1
- Pararectal lymph nodes 266.12
- Pararectal fatty body 154.13
- Parasternal line 396.49
lymph nodes 260.3
- Parasympathetic ganglion 407.22
nuclei, sacral 276.15
root
oculomotor nerve 320.9
pterygopalatine ganglion 322.16a
system 352.26
- Paratenial nucleus of thalamus 298.20a
- Paraterminal gyrus 312.5
- Parathyroid gland
inferior 182.12
superior 182.11
- Paratracheal lymph nodes 256.23, 260.16
- Paraumbilical veins 248.16
- Paraurethral duct 164.36, 172.20
- Paraurthral lymph nodes 266.10
- Paravaginal lymph nodes 266.11
- Paraventricular fibers 304.22
nuclei 302.19
anterior/posterior 298.18
- Paraventriculohypophysial tract 304.24
- Paravertebral line 396.56
lymph nodes 260.5
- Paravesical fossa 180.21
- Parenchyma 182.9, 406.2
prostate 162.20
testis 158.28
- Paries anterior
(stomach) 120.16
(vagina) 170.6
caroticus 380.19
externus ductus cochlearis 374.4
inferior 32.18
jugularis 378.20
labyrinthicus 378.22
lateralis 32.19
mastoideus 380.7, 380.8
medialis 32.20
membranaceus 380.20
(trachea) 144.23
posterior
(stomach) 120.17
(vagina) 170.7
superior 32.17
tegmental 378.17
tympanicus ductus cochlearis 372.18
vestibularis ductus cochlearis 374.3
- Parietal arteries
anterior 204.33
posterior 204.33
bone 16.24
border
frontal bone 18.11
sphenoid 10.30
temporal bone 16.11
branch
medial occipital artery 208.8
superficial temporal artery 198.8
superior tympanic artery 198.21
emissary vein 240.2
foramen 16.39
layer 184.5
of tunica vaginalis testis 162.2
lobe 308.1
lobule
inferior 308.6
superior 308.4
lymph nodes 262.1
nodes of pelvis 264.14
notch 16.12
pelvic fascia 174.19

Parietal

- peritoneum 176.23
- pleura 152.15
- region 398.11
- tuber 16.30
- veins 240.14
- Parieto-occipital
 - artery 204.17
 - branch of medial occipital artery 208.9
 - fasciculus 318.28
 - sulcus 310.10
- Parietomastoid suture 54.12
- Parietotemporopontine fibers 292.5
- Paroophoron 170.21
- Parotid
 - branch(-es)
 - auriculotemporal nerve 324.27
 - facial vein 236.15
 - posterior auricular artery 196.28a
 - superficial temporal artery 198.2
 - duct 110.11
 - fascia 80.20
 - gland 110.7
 - accessory 110.10
 - lymph nodes
 - deep 256.6
 - superficial 256.5
 - papilla 108.28
 - veins 236.28
- Pars(-tes)
 - abdominalis
 - aortae 216.19
 - (m. pectoralis major) 84.6
 - (oesophagus) 120.5
 - (thoracic duct) 254.21
 - (ureter) 156.20
 - affixa (liver) 128.29
 - alaris (m. nasalis) 78.15
 - alveolaris 26.26
 - anterior
 - (anterior commissure) 318.31
 - (cerebellum) 288.23
 - (fornix of vagina) 170.3
 - (liver) 128.26
 - (midbrain) 290.29
 - pontis 284.8
 - anularis vaginae fibrosae 92.28, 100.23
 - aryepiglottica (m. arytenoideus obliquus) 142.21a
 - ascendens
 - aortae 192.4
 - (duodenum) 124.6
 - atlantica (vertebral artery) 206.7
 - autonomica 348.1
 - abdominalis 348.9a
 - pelvica 350.8a
 - thoracica 348.3a

Pars(-tes)

- basalis
 - (left pulmonary artery) 190.38
 - (right pulmonary artery) 190.24
- basilaris
 - ossis occipitalis 8.6
 - pontis 284.8
- basolateralis (amygdaloid body) 318.3
- buccopharyngea 118.24
- cardiaca (stomach) 120.21
- cartilaginea
 - (nasal septum) 136.5a
 - (tubae auditoriae) 384.18
- cartilaginosa 402.37
- cavernosa (internal carotid) 200.16
- centralis (lateral ventricle) 314.2
- ceratopharyngea 118.31
- cerebralis (internal carotid) 200.24
- cervicalis
 - (internal carotid) 200.11
 - (oesophagus) 120.3
 - (thoracic duct) 254.19
 - (trachea) 144.18
- chondropharyngea 118.30
- ciliaris retinae 358.27
- circopharyngea 118.34
- clavicularis (m. pectoralis major) 84.4
- compacta (substantia nigra) 292.8
- convoluta (renal cortex) 154.27
- corneoscleralis (trabecular meshwork) 354.28
- corporis 396.46
- corticalis
 - (middle cerebral artery) 204.29
 - (posterior cerebral artery) 208.1
- corticomedialis (amygdaloid body) 318.4
- costalis
 - diaphragmatis 84.27
 - (parietal pleura) 152.17
- cranialis (parasympathetic system) 352.26a
- cruciformis vaginae fibrosae 92.29, 100.24
- cuneiformis vomeris 20.30b
- cupularis 378.19
- descendens
 - aortae 216.1
 - (duodenum) 124.4
 - dextra (liver) 128.27
- diaphragmatica (parietal pleura) 152.18
- distalis (adenohypophysis) 182.17
- endocrina pancreatis 128.21

Pars(-tes)

- exocrina pancreatis 128.15
- fetalis (placenta) 172.29
- flaccida 380.22
- glossopharyngea 118.26
- horizontalis (inferior), (duodenum) 124.5
- inferior
 - (left superior pulmonary vein) 232.3
 - (vestibular ganglion) 330.12
- inferoposterior (cerebellum) 288.32
- infraclaviculares (brachial plexus) 336.24
- infralobaris (superior right pulmonary vein) 230.12
- insularis (middle cerebral artery) 204.23
- intercartilaginea (rima glottidis) 144.7
- intermedia
 - (adenohypophysis) 182.16
 - bulborum 170.35
- intermembranacea (rima glottidis) 144.6
- intersegmentalis
 - (inferior right pulmonary vein) 230.20, 230.25
 - (left inferior pulmonary vein) 232.7
 - (left superior pulmonary vein) 230.31, 230.34
 - (superior basal vein) 232.12
 - (superior right pulmonary vein) 230.7, 230.10
- intracranicularis (optic nerve) 354.6
- intracranialis
 - (optic nerve) 354.5
 - (vertebral artery) 206.8
- intralaminaris (optic nerve) 354.10
- intraobaris (superior right pulmonary vein) 230.13
- intraocularis (optic nerve) 354.8
- intrasegmentalis
 - (inferior right pulmonary vein) 230.19, 230.24
 - (left inferior pulmonary vein) 232.6
 - (left superior pulmonary vein) 230.30, 230.33
 - (superior basal vein) 232.11
 - (superior right pulmonary vein) 230.6, 230.9
- iridica retinae 358.28
- labialis (m. orbicularis oris) 78.28
- lacrimalis (m. orbicularis oculi) 78.20
- laryngea pharyngis 118.12
- lateralis
 - (fornix of vagina) 170.5

- Pars(-tes)
 lateralis
 omiss occipitalis 8.9
 omiss sacri 4.21
 (superior right pulmonary vein) 230.15
 libera membri
 inferioris 46.1
 superioris 36.1
 lumbalis diaphragmatis 84.24
 marginalis (m. orbicularis oris) 78.27
 magnocellularis (red nucleus) 294.5
 medialis (superior right pulmonary vein) 230.16
 mediastinalis (parietal pleura) 152.16
 membranacea
 (interventricular septum) 184.24
 (nasal septum) 136.5
 (urethra) 164.29
 mobilis septi nasi 134.33
 muscularis (interventricular septum) 184.23
 mylopharyngea 118.25
 nasalis
 omiss frontalis 18.18
 pharyngis 116.26
 nervosa (retina) 358.22
 obliqua (m. cricothyroideus) 142.14
 omissa (umbilical artery) 222.29a
 opercularis (inferior frontal gyrus) 306.31
 optica retinae 358.20
 oralis pharyngis 118.8
 orbitalis 18.21
 (inferior frontal gyrus) 306.32
 (lacrima gland) 368.11
 (m. orbicularis oculi) 78.19
 (optic nerve) 354.7
 ossea 402.31
 (nasal septum) 136.6
 tubae auditoriae 384.15
 palpebralis
 (lacrima gland) 368.12
 (m. orbicularis oculi) 78.18
 parasymphathetica 352.26
 parvocellularis (red nucleus) 294.4
 patens (umbilical artery) 222.26a
 pelvica
 (ganglion sublinguale) 352.33a
 (ureter) 156.21
 peripherica (nervous system) 320.1, 407.1
 petrosa
 (internal carotid) 200.13
- Pars(-tes)
 petrosa
 omiss temporalis 12.15
 apex 12.25
 facies anterior 14.1
 facies inferior 14.23
 facies posterior 14.11
 margo posterior 14.17
 pharyngea (adenohypophysis) 182.18
 pigmentosa (retina) 358.21
 plana 356.23
 plicata 356.20
 postcommunicalis
 (anterior cerebral artery) 204.8
 (posterior cerebral artery) 206.26
 posterior
 (anterior commissure) 318.32
 (fornix of vagina) 170.4
 (liver) 128.28
 (midbrain) 290.30
 pontis 284.17
 postlaminaris (optic nerve) 354.9
 postsulcalis (tongue) 112.33
 precommunicalis
 (anterior cerebral artery) 204.2
 (posterior cerebral artery) 206.24
 preliminaris (optic nerve) 354.11
 presulcalis (tongue) 112.32
 prevertebralis (vertebral artery) 206.3
 profunda
 (glandula parotidea) 110.9
 (m. masseter) 80.14
 (m. sphincter ani externus) 174.17
 prostatica (urethra) 164.24
 pterygopharyngea 118.23
 pyloricum (stomach) 120.27
 quadrata (liver) 130.23
 radiata (renal cortex) 154.28
 recta (m. cricothyroideus) 142.13
 reticularis (substantia nigra) 292.9
 retrolentiformis (internal capsule) 318.26
 sphenoidalis (middle cerebral artery) 204.19
 spongiosa (urethra) 164.30
 squamosa 16.10
 sternalis diaphragmatis 84.28
 sternocostalis (m. pectoralis major) 84.5
 subcutanea (m. sphincter ani externus) 174.15
 sublentiformis (internal capsule) 318.21
- Pars(-tes)
 superficialis
 (glandula parotidea) 110.8
 (m. masseter) 80.13
 (m. sphincter ani externus) 174.16
 superior
 (duodenum) 124.2
 (left superior pulmonary vein) 232.2
 (liver) 128.24
 (vestibular ganglion) 330.7
 supraclavicularis (brachial plexus) 336.19
 sympathetica 350.21
 tensa 380.23
 terminalis (middle cerebral artery) 204.29
 thalamolentiformis (internal capsule) 318.14
 thoracica
 aortae 216.2
 (oesophagus) 120.4
 (thoracic duct) 254.20
 (trachea) 144.19
 thyroepiglottica (m. thyroarytenoidea) 142.20a
 thyropharyngea 118.33
 tibioalcanea 70.4
 tibioavicularis 70.3
 tibiotalaris
 anterior 70.5
 posterior 70.6
 transversa
 (m. nasalis) 78.14
 (portal vein of liver) 248.6
 transversaria (vertebral artery) 206.4
 triangularis (inferior frontal gyrus) 306.33
 tuberalis (adenohypophysis) 182.15
 tympanica 16.1
 umbilicus (portal vein of liver) 248.8
 uterina
 (placenta) 172.28
 (uterine tube) 166.36
 uvealis (trabecular meshwork) 354.29
 vertebralis (lung) 148.12
 Parvicellular part of red nucleus 294.4
 Patella 48.31
 apex 48.33
 base 48.32
 retinaculum
 lateral 68.18
 medial 68.17
 Patellar
 fossa 362.7
 ligament 68.16
 network 226.21
 surface (femur) 46.26

- Patent part of umbilical artery
222.26a
- Pecten
 analís 126.29
 ossis pubis 44.15
- Pectinate
 ligament 354.27
 muscles 186.15
- Pectineal
 ligament 86.12
 line 46.16
 of the pubis 44.15
- Pectoral
 branches of thoracoacromial
 artery 212.17
 fascia 84.9
 girdle 34.2
 lymph nodes 258.20
 nerve
 lateral 336.29
 medial 336.28
 regions 398.33, 398.37
 veins 244.10
- Pedicle 2.5
- Pediculus
 arcus vertebrae 2.5
 pulmonis 148.21
- Peduncular
 branches of posterior cerebral
 artery 206.31
 veins 240.30
- Pedunculus(-i)
 cerebellaris(-es) 290.23
 inferior 280.2, 282.4, 290.24
 medius (pontinus) 284.5,
 290.25
 superior 290.26, 292.19
 cerebri (cerebralis) 290.28
 flocularis 290.4
 thalamicus, inferior 302.8
- Pelvic
 aperture
 lower 44.28
 upper 44.27
 axis 44.29
 cavity 44.21a
 diaphragm 174.5
 inferior fascia 174.29
 superior fascia 174.26
 tendinous arch 174.27
 fascia 174.18
 parietal 174.19
 visceral 174.21
 ganglia 352.35
 girdle 42.2
 joints 66.1
 inclination 44.33
 inlet 44.27
 outlet 44.28
 part
 of sublingual ganglion 352.33a
 of ureter 145.21
 plexus 350.11
 splanchnic nerves 352.34
 surface of sacrum 4.24
- Pelvis 44.21
 major 44.24
 minor 44.25
 renalis 156.15
- Penicilli 268.19
- Penis 162.27
 body (shaft) 162.29
 bulb 164.10
 cavernous nerves of 350.19
 deep fascia 164.21
 dorsal nerve of 346.22
 fundiform ligament 86.26
 prepuce (foreskin) 164.5
 frenulum 164.6
 root 162.28
 septum 164.13
 superficial fascia 164.20
 suspensory ligament 86.25
- Perforated substance, anterior
312.2
- Perforating
 branch(-es)
 dorsal metacarpal arteries
 214.13
 internal thoracic artery 210.7
 lateral circumflex femoral
 artery 226.12
 peroneal artery 228.13
 plantar metatarsal arteries
 228.24
 cutaneous nerve 344.16a
 veins 252.12, 252.27
- Periarterial plexus 408.14
- Pericardiac veins 234.2
- Pericardiacophrenic
 artery 210.5
 veins 234.3
- Pericardial
 branch(-es)
 aorta 216.5
 phrenic nerve 336.9
 cavity 184.7
 lymph nodes, lateral 260.8
 veins 246.7
- Pericardium 184.1
 fibrosum 184.2
 oblique sinus 184.9
 serosum 184.4
 transverse sinus 184.8
- Perichondrium 402.38
- Perichoroidal space 356.15
- Pericranium 28.21
- Peridental branches
 anterior superior alveolar ar-
 teries 200.3a
 inferior alveolar artery 198.13a
 posterior superior alveolar
 artery 198.28a
- Perikaryon 408.19
- Perilymph 370.5
- Perilymphatic
 duct 372.13
 external aperture 372.14
 space 372.10
- Perimysium 405.24
- Perineal
 artery 224.10
 body 174.4
 branches of gluteal nerve 344.16
 fascia, superficial 176.12
 flexure 126.15
 ligament, transverse 176.7
 membrane 176.6
 muscles 174.3
 nerves 346.19
 raphe 174.2
 region 400.15
 space
 deep 176.2
 superficial 176.8
- Perineum 174.1
- Perineurium 407.4
- Periodontal ligament 112.15
- Periodontium 112.12
 insertionis 112.14
 protectoris 112.13
- Perionyx 394.3
- Periorbita 364.18
- Periosteum 402.32
 of external skull surface 28.21
 of orbit 364.18
- Peripharyngeal space 118.35
- Peripheral 396.36
 nervous system 320.1, 407.1
- Peripheralis 396.36
- Periphrericus 396.36a
- Periphery 396.36a
- Peritendineum 405.22
- Peritoneal
 cavity 176.19
 covering of spleen 268.13
- Peritoneoperineal fascia 174.23
- Peritoneum 176.17
 parietale 176.23
 anterior 180.12
 urogenitale 180.22
 vaginal process 168.33, 180.23
 viscerale 176.26
- Perivascular fibrous capsule
132.2
- Periventricular
 fibers 302.12, 304.11
 nucleus, posterior 304.4
- Perivascular lymph nodes 266.6
- Permanent teeth 112.26
- Peroneal
 artery 228.12
 nerve
 common 344.18
 communicating branch
 344.20
 deep 344.26
 superficial 344.21
 retinaculum
 inferior 100.15
 superior 100.14
 trochlea 52.5
 veins 252.22
- Peroneus longus tendon, groove
for 52.4, 52.13

- Perpendicular 396.2
 plate 20.5, 24.16
 Pes 314.17, 402.17
 Petiolus epiglottidis 142.4
 Petit's trigone 400.14
 Petro-occipital
 fissure 30.20
 synchondrosis 56.4
 Petrosal
 branch of middle meningeal
 artery 198.18
 fossula 14.29
 nerve
 deep 328.25
 greater 328.24
 groove for 14.6
 hiatus of canal 14.4
 lesser 330.32
 groove for 14.7
 hiatus of canal 14.5
 sinus
 inferior 238.18
 groove for 8.7, 14.18
 superior 238.20
 groove for 14.10
 vein 242.24
 Petrosquamous fissure 14.32
 Petrotympenic fissure 14.31
 Petrous
 ganglion 330.19
 part of internal carotid 200.13
 Peyer's patches 122.33
 Phalanges
 fingers 40.23, 40.24
 toes 52.23, 52.24
 Phalanx
 base
 fingers 40.29
 toes 29, 52
 body (shaft)
 fingers 40.30
 toes 52.30
 distal end (trochlea), fingers
 40.31
 distalis
 fingers 40.27
 toes 52.27
 head, fingers 52.31
 media
 fingers 40.26
 toes 52.26
 proximalis
 fingers 40.25
 toes 52.25
 Pharyngeal
 artery, ascending 194.17
 branches
 artery of pterygoid canal
 200.4a
 ascending pharyngeal artery
 194.19
 descending palatine artery
 200.7a
 glossopharyngeal nerve
 330.26
 Pharyngeal
 branches
 inferior thyroid artery
 210.17
 vagus nerve 332.7, 332.17a
 bursa 118.1
 cavity 116.24
 fornix 116.25
 glands 118.18
 nerve 322.21
 opening of auditory tube 118.2,
 384.25
 plexus 234.25, 332.8
 raphe 118.20
 recess 118.7
 tubercle 8.8
 veins 234.26
 Pharyngobasilar fascia 118.15
 Pharynx 116.1
 Pharyngeal glands 118.18
 Philtrum 108.7
 Phrenic
 arteries
 inferior 216.20
 superior 216.7
 ganglia 348.17
 lymph nodes
 inferior 262.11
 superior 260.0
 nerve 336.8
 accessory 336.11
 veins
 inferior 246.22
 superior 246.9
 Phrenicoabdominal branches of
 phrenic nerve 336.10
 Phrenicocolic ligament 178.18
 Phrenicomediastinal recess
 152.22
 Phrenicopleural fascia 152.10
 Phrenicosplenic ligament 178.19
 Physiological cup, optic disc
 360.2
 Pia mater
 cranialis 272.1
 spinalis 272.8
 Pigmented
 epithelium (iris) 358.13
 part of retina 358.21
 Pili 392.1
 Pineal
 body (gland) 182.22, 296.9,
 296.17
 recess 298.6
 Pinna 386.8
 Piriform
 aperture 32.3
 recess 118.13
 Pisiform 40.8
 Pisohamate ligament 64.4
 Pisometacarpal ligament 64.5
 Pisotriquetral joint 64.3
 Pit
 in head of femur 46.4
 suprameatal 16.18
 Pituitary gland 182.13
 anterior lobe 182.14
 posterior lobe 182.19
 Placenta 172.27
 Plane joint 404.25
 Plantar 396.43
 aponeurosis 100.17
 arch, superficial 228.26a
 artery
 deep 228.7
 lateral 228.21
 medial 228.18
 digital veins 252.26
 ligaments 72.20, 72.24
 of tarsus 72.1
 long 72.2
 short 72.3
 metatarsal
 arteries 228.23
 ligaments 72.16
 veins 252.25
 nerve
 lateral 346.12
 medial 346.9
 surface
 of foot 402.20
 of toe 402.28a
 tarsometatarsal ligaments 72.11
 venous
 arch of foot 252.24
 network of foot 252.23
 Plantaris 396.43
 Planum
 interspinale 398.6
 intertuberculare 398.5
 occipitale 8.27a
 subcostale 398.2
 supracristale 398.4
 transpyloricum 398.3
 Platysma 80.25
 Pleura 152.12
 parietalis 152.15
 visceralis (pulmonalis) 152.14
 Pleural
 cavity 152.11
 recesses 152.19
 Pleuroesophageal muscle 120.10
 Pleuropulmonary regions 152.7
 Plexiform layer
 cerebellum 290.14
 cerebral cortex 316.3
 Plexus
 aorticus
 abdominalis 348.10
 thoracicus 348.4
 arteriosum 406.26
 autonomici 348.2
 autonomicus 408.13
 basilaris 238.12
 brachialis 336.12
 cardiacus 348.5
 caroticus
 communis 352.2
 externus 352.1
 internus 350.30

Plexus

- cavernosi concharum 136.17
- cervicalis 334.22
- choroideus 298.10
 - ventriculi
 - lateralis 272.6, 314.11
 - quarti 272.3, 288.6
 - tertii 272.5
- coccygeus 346.25
- coeliacus 348.11
- deferentialis 350.15
- dentalis
 - inferior 326.11
 - superior 324.6
- entericus 350.3
- femoralis 350.8
- gastrici 348.20
- hepaticus 348.18
- hypogastricus
 - inferior 350.11
 - superior 350.9
- iliaci 350.7
- intermesentericus 348.15
- intraparotideus 328.12
- lumbalis (lumbaris) 342.14
- lumbosacralis 342.13
- lymphaticus 254.6, 406.23
 - axillaris 258.15
- mesentericus
 - inferior 350.1
 - superior 348.28
- myentericus (Auerbach) 350.5
- nerorum spinalium 407.24
- oesophagealis 332.23, 348.7
- ovaricus 348.27
- pampiniformis 246.35
- pancreaticus 348.21
- pelvicus 350.11
- periarteriales 408.14
- pharyngeus (pharyngealis)
 - 234.25, 332.8
- prostaticus 350.14
- pterygoideus 236.23
- pulmonalis 332.22, 348.9
- rectalis
 - inferior 350.13
 - medius 350.12
 - superior 350.2
- renal 348.23
- sacralis 344.8
- splenicus (lienalis) 348.19
- subclavius 352.11
- submucosus (Meissner) 350.6
- subserosus 350.4
- suprarenalis 348.22
- testicularis 348.26
- thyroideus
 - impar 232.30
- tympanicus 330.22
- utericus 348.25
- uterovaginalis 350.16
- vasculosus (vascularis) 406.24, 408.13a
- venosus 406.25
- areolaris 244.16

Plexus

- venosus
 - canalis hypoglossi 240.6
 - caroticus internus 240.8
 - foraminis ovalis 240.7
 - haemorrhoidalis 250.7
 - prostaticus 250.10
 - rectalis 250.7
 - sacralis 250.6
 - suboccipitalis 12, 234
 - uterinus 250.14
 - vaginalis 250.15
 - vertebralis
 - externus anterior/posterior 246.17
 - internus anterior/posterior 246.18
 - vesicalis 250.9
 - vertebralis 352.13
 - vesicalis 350.18
 - viscerales 348.2, 408.13
- Plica(-ae) 178.26
- alares 68.11
 - aryepiglottica 142.25
 - caecalis(-es) 180.7
 - vascularis 180.3
 - chordae tympani 384.7
 - circulares 122.29
 - duodenalis
 - inferior 178.30
 - superior 178.28
 - duodenojejunalis 178.28
 - duodenomesocolica 178.30
 - epicanthus 366.6
 - epigastrica 180.18
 - fimbriata 112.35
 - gastricae 122.12
 - gastropancreaticae 176.35
 - glossoepiglottica
 - lateralis 118.11
 - mediana 118.10
 - hepatopancreatica 176.35a
 - ileocaecalis 180.5
 - incudialis 384.11
 - interarytenoidea 144.7a
 - interureterica 158.11
 - iris 358.8
 - lacrimalis 368.24
 - longitudinales duodeni 124.11
 - mallearis
 - anterior 380.24, 384.6
 - posterior 380.25, 384.5
 - mucosae 134.9
 - nervi laryngei 118.14
 - palatinae transversae 108.29
 - palmatae 168.22
 - palpebronasalis 366.6
 - paraduodenalis 178.32
 - rectouterina 180.30
 - salpingopalatina 116.8
 - salpingopharyngea 118.4
 - semilunaris 116.14
 - coli 124.32
 - conjunctivae 366.25
 - spiralis 134.11

Plica(-ae)

- stapedialis 384.12
 - sublingualis 108.27
 - synovialis 404.41
 - infrapatellaris 68.10
 - transversae recti 126.23
 - triangularis 116.13
 - tubariae (tubales) 168.5
 - umbilicalis
 - lateralis 180.18
 - medialis (lateralis) 180.15
 - mediana (media) 180.13
 - venae cavae, sinistrae 232.19
 - ventricularis 142.29
 - vesicalis transversa 180.20
 - vestibularis 142.29
 - villosae 122.15
 - vocalis 144.5
- Plicatae ciliares 356.22
- Pneumatic bone 402.45
- Pollex 400.44
- Pollicis artery, princeps 214.9
- Polus
 - anterior
 - (eyeball) 354.16
 - (lens) 362.17
 - frontalis 306.23
 - occipitalis 308.11
 - posterior
 - (eyeball) 354.17
 - (lens) 362.18
 - temporalis 308.16
- Pons 284.2
- sections of 284.7
- Pontine
 - arteries 206.20
 - fibers
 - longitudinal 184.9
 - transverse 284.14
 - nucleus(-i) 284.16
 - of trigeminal nerve 284.27
 - raphe 284.18
 - veins 242.15
- Pontocerebellar
 - cistern 270.11
 - fibers 284.15
 - trigone 284.6
- Pontomesencephalic vein, anterior 242.14
- Pontoreticulospinal tract 276.31
- Popliteal
 - artery 226.13
 - fossa 402.11
 - ligament
 - arcuate 68.15
 - oblique 68.14
 - lymph nodes
 - deep 266.20
 - superficial 266.19
 - surface of femur 46.20
 - vein 252.13
- Popliteus, groove for 46.25a
- Porus acusticus 378.6
- Porta hepatis 130.6
- Portal vein of liver 248.1

- Portio
 supravaginalis cervicis
 168.16
 terminalis (sweat glands)
 394.12
 vaginalis cervicis 168.17
- Porus
 acusticus
 externus 16.4, 386.3
 internus 14.12
 gustatorius 38.28
 sudorifer 394.14
- Postaortic lymph nodes 262.5
 Postaxillary line 398.8
 Postcaval lymph nodes 262.10
 Postcentral
 branch of posterior intercostal
 artery 216.10a
 gyrus 308.3
 sulcus 308.2
- Postcommuncial part
 of anterior cerebral artery
 204.8
 of posterior cerebral artery
 206.26
- Posterior 396.14, 396.16
 accessory olivary nucleus
 280.32
 ampullar nerve 330.13
 antebrachial
 cutaneous nerve 340.4
 region 400.31
 apertures of the nose 32.10
 arch of atlas 4.8
 articular surface of dens
 4.15
 ascending branch of right pul-
 monary artery 190.19
 atlanto-occipital membrane
 56.29
 auricular
 artery 196.22
 ligament 388.13
 nerve 328.6
 sulcus 386.28
 vein 238.3
 axillary line 396.54
 basal
 branch
 left pulmonary artery
 190.42
 right pulmonary artery
 190.28
 segment
 lower lobe of left lung
 150.27
 lower lobe of right lung
 150.15
 segmental bronchus 146.15
 border
 petrous temporal 14.17
 radius 38.9
 brachial
 cutaneous nerve 340.2
 region 400.22
- Posterior
 branch(-es)
 great auricular nerve 334.29
 left pulmonary artery 190.32
 lumbar nerves 342.2
 medial antebrachial cu-
 taneous nerve 338.7
 obturator
 artery 222.18
 nerve 342.28
 portal vein of liver 248.4
 renal artery 220.24
 sacral/coccygeal nerves
 342.8
 spinal nerve 334.10, 334.15
 superior
 mesenteric artery 220.2b
 right pulmonary vein
 230.11
 thoracic nerves 340.17
 ulnar recurrent artery 214.17
 calcaneal facet 50.12
 carpal region 400.36
 cerebral artery 206.23, 208.24
 chamber of eye 362.1
 circumflex
 humeral artery 212.24
 scapular vein 244.13a
 clinoïd process 10.10
 cochlear
 nucleus 282.18
 column 276.1
 of rugae 170.14
 commisure 296.8, 296.16
 communicating artery 208.18
 conjunctival arteries 202.11
 cord 336.27
 cranial fossa 30.4
 cricoaerthyenoid muscle 142.15
 cruciate ligament of knee 68.9
 cubital region 400.25
 cusp
 atrioventricular valve 188.28
 pulmonary valve 188.5
 cutaneous branch of thoracic
 nerves 340.19
 descending branch of right
 pulmonary artery 190.16
 divisions, brachial plexus
 336.18
 end of spleen 268.8
 epithelium
 cornea 356.11
 iris 358.13
 ethmoidal
 artery 202.14
 foramen 32.22
 nerve 322.4
 external
 arcuate fibers 282.24
 vertebral venous plexus
 246.17
 facet for the talus 52.3
 fasciculi proprii 278.9
 fontanelle 32.29
- Posterior
 funiculus 274.4, 278.8
 gastric
 artery 218.35a
 branches of vagal trunk
 332.27
 glandular branch of superior
 thyroid artery 194.16
 gluteal line 42.27
 gray commissure 276.16a
 horn 276.2, 314.5
 bulb of 314.12
 hypothalamic
 nucleus 304.8
 region (area) 302.14, 304.6
 inferior
 cerebellar artery 206.12
 nasal branches, pterygo-
 palatine
 ganglion 322.23
 intercondylar area 46.33
 intercostal
 arteries 212.6, 216.8
 veins 246.13
 intermediate sulcus 272.24
 intermuscular septum
 of leg 100.10
 internal vertebral venous
 plexus 246.18
 interosseous
 artery 214.20
 nerve of forearm 340.7
 veins 244.19b
 interventricular
 branch (right coronary
 artery) 192.12
 groove 184.19
 vein 232.20
 intraoccipital synchondrosis
 56.5
 labial
 branches (internal pudendal
 artery) 224.12
 commissure 170.28
 veins 250.21
 lacrimal crest 20.22
 lateral nucleus 300.2
 ligament
 of head of fibula 68.22
 of incus 382.27
 limb of internal capsule 318.13
 limiting (Descemet's) mem-
 brane 356.10
 lip of uterine ostium 168.20
 lobe of cerebellum 288.25
 longitudinal
 fasciculus 280.24, 284.20,
 292.25, 304.14
 ligament 56.20
 malleal fold 380.25, 384.5
 margin
 fibula 48.27
 radius 38.12
 testis 158.22
 ulna 38.29

- Posterior
 median
 line 398.1
 septum 272.21
 sulcus 272.20, 280.8
 mediastinal lymph nodes 260.11
 mediastinum 152.29
 membranous ampulla 370.20
 meningeal
 artery 194.18
 branch of vertebral artery 206.10
 meniscofemoral ligament 68.4
 nasal spine 24.31
 nucleus(-i)
 of thalamus 300.10
 of trapezoid body 286.16
 obturator tubercle 44.19
 osseous ampulla 376.12
 palpebral surface 366.7
 papillary muscle 188.17, 190.9
 paramedian nucleus 282.6
 paraventricular nuclei 198.18
 parietal arteries 204.33
 part
 of anterior commissure 318.32
 of fornix of vagina 170.4
 of pons 284.17
 of tongue 112.33
 periventricular nucleus 304.4
 pole 354.17
 of lens capsule 362.18
 process
 nasal septum 134.31
 talus 50.17
 radicular artery 216.10c
 ramus, lateral sulcus 306.20
 recess of tympanic membrane 384.10
 region(-s) 400.8
 of the neck 398.32
 root 334.6
 sacral foramina 4.30
 sacrococcygeus muscle 88.4
 scrotal
 branches (internal pudendal artery) 224.11
 nerves 346.20
 veins 250.21
 segment
 of kidney 154.21
 of liver 130.20
 of upper lobe of right lung 150.4
 segmental
 artery 218.8, 220.25
 bronchus 146.4
 semicircular
 canal 376.8
 duct 370.13
 semilunar cusp of aortic valve 190.3
 septal branches of sphenopalatine artery 200.9a
- Posterior
 side of knee 402.10
 sinus 138.8
 spinal
 artery 206.16
 veins 246.20a
 spinocerebellar tract 278.4
 sternoclavicular ligament 60.25
 superior
 alveolar artery 198.28
 alveolar branches, infraorbital nerve 324.3
 pancreaticoduodenal artery 218.15
 supraclavicular nerves 336.7
 surface
 of arytenoid cartilage 140.20
 of cornea 356.6
 of fibula 48.23
 of humerus 36.14
 of iris 358.5
 of kidney 154.9
 of lens 362.20
 lower leg 402.14
 of prostate 162.14
 of scapula 34.6
 of stomach 120.17
 of tibia 48.4
 of ulna 38.25
 surface of adrenal gland 182.31
 talocalcaneal ligament 70.15a
 talocrural region 402.16
 talofibular ligament 70.9
 temporal
 artery 198.25a, 204.28
 branches of lateral occipital artery 208.5
 diploic vein 238.27
 thalamic radiations 302.3, 318.27
 thigh region 402.7
 tibial
 artery 228.8
 node 266.22
 recurrent artery 226.23
 veins 252.21
 tibiofibular ligament 68.26
 tibiotalar part of medial (deltoid) ligament 70.6
 triangle of neck 398.30
 tubercle 2.20, 4.10
 tympanic artery 196.24
 vagal trunk 332.25
 vein
 of corpus callosum 242.11
 of left ventricle 232.17
 of septum pellucidum 242.6
 ventral nucleus 300.7
 wall of vagina 170.7
 white commissure 276.18a
- Posterolateral
 central arteries 206.27
 choroid branches of posterior cerebral artery 206.30
- Posterolateral
 fissure 288.39
 fontanelle 32.31
 nucleus 274.21
 sulcus 272.23, 280.1
 ventral nucleus 300.8
- Posteromedial
 central arteries 206.25
 choroid branches of posterior cerebral
 artery 206.29
 frontal branch of callosomarginal artery 204.13
 nucleus 274.23
 ventral nucleus 300.9
- Postganglionic nerve fibers 407.18
- Postlaminar part of optic nerve 354.9
- Postpyramidal fissure 288.30
- Postvesicular lymph nodes 266.8
- Pouch of Douglas 180.31
- Pre-aortic lymph nodes 262.4
- Pre-epiglottic fat body 138.26a
- Preauricular lymph nodes 256.7
- Preaxillary line 398.7
- Precaval lymph nodes 262.9
- Precerebral lymph nodes 264.5
- Precentral
 cerebellar vein 242.23
 gyrus 306.25
 sulcus 306.24
- Prechiasmatic groove 10.4
- Precommissural septum 312.30
- Precommunical part
 of anterior cerebral artery 204.2
 of posterior cerebral artery 206.24
- Precuneal artery 204.16
- Precuneus 310.11
- Prefrontal veins 240.12
- Preganglionic nerve fibers 407.17
- Prelaminar branch of posterior intercostal
 artery 216.10b
- Prelingual lymph nodes 256.20
- Premaxilla 24.3
- Premolar teeth 112.22
- Preopercular incisure 308.14
- Preoptic
 area 296.31
 nucleus
 lateral 302.17
 medial 302.17
- Prepancreatic artery 218.28a
- Prepericardial lymph nodes 260.7
- Prepuce of penis 164.5
 frenulum 164.6
- Preputial glands 164.22
- Preputium
 clitoridis 172.9
 penis 164.5
- Prepyloric vein 248.19

- Presternal region 398.34
- Pretectal
area 296.14
nuclei 296.15
- Pretracheal
layer of cervical fascia 82.23
lymph nodes 256.22
- Prevertebral
layer of cervical fascia 82.24
part of vertebral artery 206.3
- Prevesicular lymph nodes 266.7
- Primary
center of ossification 404.9
fissure 288.24
ovarian follicles 166.18
- Primitive urogenital sinus 172.34
- Princeps pollicis artery 214.9
- Processus(-i)
accessorius 2.29
alveolaris 24.8
anterior (malleus) 380.17
articularis
inferior 2.15
superior 2.14, 4.20
axillaris (mammary gland)
394.22
calcaneus 52.15
caudatus (liver) 130.28
ciliares 356.21
clinoideus
anterior 10.21
medius 10.7
posterior 10.10
cochleariformis 380.5
condylaris 28.12
coracoideus 34.24
coronoideus
(mandible) 28.10
(ulna) 38.20
costalis 2.13
ethmoidalis 20.20
falciiformis 66.7
frontalis 22.25, 26.6
intrajugularis 14.20
ossis occipitales 8.21
jugularis 8.20
lacrimalis 20.18
lateralis
(malleus) 382.16
(mammary gland) 394.22
(nasal septum) 134.30a
tali 50.11
tuberis calcanei 50.25
lenticularis 382.10
mamillaris 2.30
mastoides 12.17
maxillaris 20.19
medialis tuberis calcanei
50.24
muscularis (arytenoid car-
tilage) 140.22
orbitalis 24.25
palatinus 24.1
papillaris (liver) 130.27
paramastoides 8.34
- Processus(-i)
posterior
(sphenoidalis) 134.31
tali 50.17
pterygoideus 12.1
pterygospinosus 12.13
pyramidalis 24.21
sphenoidalis 24.26
spinosus 2.11
styloideus
(metacarpal bone) 40.22
(radius) 38.14
(temporal bone) 14.26, 16.9
(ulna) 38.34
supracondylaris 36.18
temporalis 26.5
transversus 2.11
uncinatus 20.16, 128.3
vaginalis 12.7
peritonei 168.33, 180.23
vocalis 140.14
xiphoideus 6.32
zygomatikus 16.16, 22.29
ossis frontalis 18.13
- Profundus 396.32
- Projecting neurofibers 318.35
- Prominentia
canalis
facialis 380.12
semicircularis lateralis 380.11
laryngea 138.15
spiralis 374.6
styloidea 378.21
- Promontorium 378.25
ossis sacri 4.18
- Promontory 378.25
common iliac lymph nodes
264.20
of sacrum 4.18
- Pronator tuberosity 38.11a
- Proper
membrane of semicircular
duct 370.15
- palmar
digital arteries 214.29
digital nerves 338.16
- plantar
digital arteries 228.26
digital nerves 346.11, 346.15
- Prosencephalon 296.1
- Prostate (prostata) 162.10
apex 162.12
base 162.11
capsule 162.19
isthmus 162.17
- Prostatic
branches of inferior vesical
artery 224.1a
ductules 162.21
fascia 174.22
part of urethra 164.24
plexus 350.14
sinus 164.28
utricle 164.27
venous plexus 250.10
- Protuberantia
mentalis 26.15
occipitalis
externa 8.22
internal 8.29
- Proximal 396.33
phalanx
fingers 40.25
toes 52.25
radioulnar joint 62.4
- Proximalis 396.33
- Prussak's pouch 384.9
- Pterion 30.10a
- Pterygoid
branches
internal carotid 200.15
maxillary artery 198.26
canal 12.12
artery 200.4
fossa 12.5
fovea 28.15
hamulus 12.10
sulcus 12.11
muscle
lateral 80.16
medial 80.17
notch (fissure) 12.4
plate
lateral 12.2
medial 12.3
plexus 235.23
process of sphenoid bone 12.1
tuberosity 28.5
- Pterygomandibular raphe 118.21
- Pterygomaxillary fissure 30.15
- Pterygomeningeal artery 198.23a
- Pterygopalatine
fossa 30.14
ganglion 322.16, 328.22,
352.30
sulcus 22.23, 24.20
- Pterygospinal ligament 60.10
- Pterygospinosus process 12.13
- Pubes 392.10
- Pubic
arch 44.22
branch
external iliac vein 250.24a
inferior epigastric artery
224.22
obturator artery 222.15
crest 44.12
ligament
arcuate 66.17
superior 66.16
region 400.7
symphysis 66.15
tubercle 44.10
- Pubis 44.8
body 44.9
pecten (pectineal line) of 44.15
ramus
inferior 44.20
superior 44.13
- Pubofemoral ligament 66.25

Puboprostatic ligament 174.28

Pubovesical ligament 174.28

Pudendal

artery(-ies)

external 224.32

internal 224.8

canal 176.15

fissure 170.29

nerve 346.17

veins

external 252.2

internal 250.16

Pudendum femininum 170.24

Pulmo

dexter 148.7

lobus inferior 150.9

lobus medius 150.6

lobus superior 150.2

sinister 148.7

Pulmonary

alveoli 152.5

artery

left 190.27

right 190.14

branches 348.8

juxtaesophageal lymph nodes
260.12

ligament 152.23

pleura 152.14

plexus 332.22, 348.9

sulcus of thorax 6.38

surface 184.14

trunk 190.11

bifurcation 190.13

opening 184.30, 188.9

sinuses 190.12

valve 188.10

anterior semilunar cusp 188.11

left semilunar cusp 188.13

right semilunar cusp 188.12

veins 230.2

left 230.27

inferior 232.4

superior 230.27, 230.28

right 230.3

inferior 230.17

superior 230.4

Pulmones 148.6

Pulp

cavity of tooth 112.1

chamber in crown 112.2

of tooth 112.5

Pulpa

coronalis 112.6

dentis 112.5

radicularis 112.7

splenica (lienalis) 268.16

Pulvinar 296.25

nuclei 300.11

Punctum lacrimale 368.18

Pupil (pupilla) 358.9

Pupillary

margin 358.2

membrane 358.17

Purkinje cell layer 290.15

Putamen 316.27

Pyloric

antrum 120.28

canal 120.29

glands 122.17

lymph nodes 262.18

opening 122.2

part of stomach 120.27

sphincter 122.8

Pylorus 122.1

Pyramid 278.19

of temporal bone 12.15

of vermis 288.29

Pyramidal

cell layer, cerebral cortex 316.5

decussation 278.20, 280.13

eminence 380.13

fasciculus 280.10

lobe of thyroid gland 182.5

process 24.21

tract 276.22, 280.10

Pyramides renales 154.31

Pyramis 278.19

vermis 288.29

vestibuli 374.25

Q

Quadrangular

lobule 288.23

membrane 144.10

Quadrate

ligament 62.8

lobe of liver 130.25

muscle 405.6

part of liver 130.23

tubercle 46.10a

Quadrigeminal plate 292.13

R

Radial 396.37

artery 214.1

collateral

artery 212.31

ligament 62.6

carpal 62.23

fibers 356.27

fossa 36.27

head of flexor digitorum su-

perficialis 90.7

nerve 340.1

groove for 36.15

notch 38.23

recurrent artery 214.2

tuberosity 38.7

veins 244.19

Radialis 396.37

indicis artery 214.10

Radiate

carpal ligament 62.21

layer of tympanic membrane

380.31

ligament of head of rib 58.12

sternocostal ligament 58.22

Radiating part of renal cortex
154.28

Radiatio(-nes)

acustica 300.27, 318.23

corporis callosi 312.11, 316.19

optica 300.29, 318.22

thalamicae

anteriores 302.1, 318.9

centrales 302.2, 318.20

posteriores 302.3, 318.27

Radii

of lens 362.23

medullares 154.29a

Radiocarpal

joint 62.15

ligament

dorsal 62.18

palmar 62.19

Radioulnar

joint 62.9

distal 62.12

proximal 62.4

syndesmosis 62.9

Radius 38.1

annular ligament 62.7

body 38.6

head 38.2

neck 38.5

Radiix(-ces) 336.12a

anterior 334.5, 334.24

basalis anterior 230.23

clinica 110.23

craniales (vagus nerve) 332.32

dentis 110.21

facialis 328.23

lateralis 296.34, 338.10

linguae 112.30

medialis 296.35, 338.9

mesenterii 178.3

motoria 334.5

(trigeminal nerve) 330.18

nasi (nasalis) 134.19

parasympathetica

(oculomotoria) 320.9

(pterygopalatine ganglion)

322.16a

penis 162.28

pili 392.14

posterior 334.6, 334.25

pulmonis 148.21

sensoria 334.6

(nasociliaris) 320.12

(pterygopalatine ganglion)

322.16c

(trigeminal nerve) 320.16

spinales (vagus nerve) 332.33

sympathetica

(internal carotid plexus)

320.11

(pterygopalatine ganglion)

322.16b

unguis 392.27

Ramus(-i)

accessorius (middle meningeal

artery) 198.17

- Ramus(-i)
 acetabularis
 (medial circumflex femoral artery) 226.7
 (obturator artery) 222.16
 acromialis
 (axillary artery) 212.13
 (suprascapular artery) 212.2
 albus (spinal nerve) 334.11b
 alveolares superiores
 anteriores 324.5
 medius 324.4
 posteriores 324.3
 anastomoticus 198.23
 (lacrimal artery) 202.4
 anterior(-es)
 ascendens
 (left pulmonary artery) 190.33
 (right pulmonary artery) 190.18
 descendens
 (left pulmonary artery) 190.31
 (right pulmonary artery) 190.17
 (gluteal nerve) 342.12
 (great auricular nerve) 334.30
 (hepatic duct) 132.10
 (lateral sulcus) 306.18
 (left superior pulmonary vein) 230.32
 (lumbar nerve) 342.6
 (medial antebrachial cutaneous nerve) 338.6
 (obturator artery) 222.17
 (obturator nerve) 342.26
 (portal vein of liver) 248.3
 (renal artery) 220.19
 (spinal nerve) 334.9, 334.21
 (superior mesenteric artery) 220.1
 (superior right pulmonary vein) 230.8
 (thoracic nerves) 340.20
 (ulnar recurrent artery) 214.16
 apicalis
 (left pulmonary artery) 190.30
 (right pulmonary artery) 190.15
 (superior right pulmonary vein) 230.5
 apicoposterior (left superior pulmonary vein) 230.29
 articularis(-es) 408.7
 (descending genicular artery) 226.1c
 ascendens
 (deep circumflex iliac artery) 224.28
 (lateral circumflex femoral artery) 226.9
- Ramus(-i)
 ascendens
 (lateral sulcus) 306.19
 (medial circumflex femoral artery) 226.5
 (transverse cervical artery) 210.23a
 atriales
 (left coronary artery) 192.27a
 (right coronary artery) 192.9a
 atrialis
 anastomoticus (left coronary artery) 192.22
 intermedius
 (left coronary artery) 192.24
 (right coronary artery) 192.11
 atrioventriculares
 (left coronary artery) 192.22a
 (right coronary artery) 192.7a
 auricularis
 anteriores (transverse facial artery) 198.4
 (occipital artery) 196.17
 (posterior auricular artery) 196.27
 (posterior auricular nerve) 328.8
 (vagus nerve) 332.5
 autonomicus 408.12
 basalis
 anterior
 (left inferior pulmonary vein) 232.10
 (left pulmonary artery) 190.40
 (right pulmonary artery) 190.26
 lateralis
 (left pulmonary artery) 190.41
 (right pulmonary artery) 190.27
 medialis
 (left pulmonary artery) 190.39
 (right pulmonary artery) 190.25
 posterior
 (left pulmonary artery) 190.42
 (right pulmonary artery) 190.28
 tentorii (internal carotid) 200.17
 bronchiales
 (internal thoracic artery) 210.4
 segmentorum 148.1
 (thoracic aorta) 216.3
 (vagus nerve) 332.21
- Ramus(-i)
 buccales (facial nerve) 328.15
 calcanei
 laterales 346.7
 mediales 346.8
 (peroneal artery) 228.16
 (posterior tibial artery) 228.11
 calcarinus (medial occipital artery) 208.10
 capsulae internae (anterior choroidal artery) 202.28
 capsulares (interlobular arteries) 156.7
 cardiaci
 cervicales
 inferiores 332.14
 superiores (vagus nerve) 332.9
 thoracici
 (thoracic ganglia) 352.15
 (vagus nerve) 332.20
 carpalis
 dorsalis
 (radial artery) 214.5
 (ulnar artery) 214.25
 palmaris
 (radial artery) 214.3
 (ulnar artery) 214.24
 caudae nuclei caudati
 (anterior choroidal artery) 202.30
 (posterior communicating artery) 208.23
 caudati (portal vein of liver) 248.7
 centrales anteromediales 204.7
 cervicalis (facial nerve) 328.18
 chiasmaticus (posterior communicating artery) 208.19
 choroidei
 posteriores
 laterales (posterior cerebral artery) 206.30
 mediales (posterior cerebral artery) 206.29
 ventriculi
 lateralis (anterior choroidal artery) 202.23
 tertii (anterior choroidal artery) 202.24
 choroideus ventriculi quarti
 (posterior inferior cerebellar artery) 206.13
 cingularis (callosomarginal artery) 204.14
 circumflexus
 fibularis (posterior tibial artery) 228.9
 (left coronary artery) 192.21
 clavicularis (axillary artery) 212.15
 clivi (internal carotid) 200.26

Ramus(-i)
 clunium (gluteales)
 inferiores 344.15
 mediales 342.11
 superiores 342.5
 cochlearis (labyrinthine artery)
 374.13
 coeliaci (vagus nerve) 332.29
 colicus (ileocolic artery) 220.6
 collateralis (posterior intercostal arteries) 216.13
 colli (facial nerve) 328.18
 communicans(-tes) 350.25, 408.11
 alba 407.20
 cochlearis 330.6
 cum chorda tympani 326.4, 330.35
 cum ganglio ciliari 322.2
 cum nervi auriculotemporalis 330.34
 cum nervi facialis 324.28
 cum nervi laryngeali recurrenti 332.13
 cum nervi ulnari 338.14
 cum nervo glossopharyngeo 328.11, 332.6
 cum nervo hypoglosso 326.3
 cum nervo pterygoideo mediali 324.20
 cum nervo vago 328.5
 cum nervo zygomatico 320.22
 cum plexus tympanico 328.4
 cum ramo articulari nervi vagi 330.25
 cum ramo laryngeo interno 332.19
 cum ramo meningeo 330.33
 fibularis 344.20
 griseus 407.21
 (peroneal artery) 228.14
 (spinal nerve) 334.11
 ulnaris 340.9
 conus arteriosus
 (left coronary artery) 192.18
 (right coronary artery) 192.8
 corporis
 callosi dorsalis 208.7
 geniculati lateralis (anterior choroidal artery) 202.27
 costalis lateralis (internal thoracic artery) 210.9
 cricothyroideus (superior thyroid artery) 194.14
 cutanei cruris mediales 344.6
 cutaneus 408.6
 anterior
 (iliohypogastric nerve) 342.17, 344.3
 (intercostal nerve) 340.24
 lateralis
 (iliohypogastric nerve) 342.16
 (intercostal nerve) 340.21
 (posterior intercostal arteries) 216.12, 216.14

Ramus(-i)
 cutaneus
 medialis (posterior intercostal arteries) 216.11
 (obturator nerve) 342.27
 posterior (thoracic nerves) 340.19
 deltoideus
 (axillary artery) 212.16
 (brachial artery) 212.29
 dentales
 (anterior superior alveolar arteries) 198.3
 (inferior alveolar artery) 198.13
 inferiores (inferior alveolar nerve) 326.12
 (posterior superior alveolar artery) 198.28
 descendens
 (lateral circumflex femoral artery) 226.10
 (medial circumflex femoral artery) 226.6
 (occipital artery) 196.21
 (transverse cervical artery) 210.23b
 dexter
 (hepatic artery proper) 218.4
 (portal vein of liver) 248.2
 digastricus (facial nerve) 328.9
 diploicus 202.13a
 dorsalis(-es)
 linguae 196.4
 (posterior intercostal arteries) 212.7, 216.9, 216.17
 (ulnar nerve) 338.19
 duodenales
 (anterior superior pancreaticoduodenal artery) 218.24
 (posterior superior pancreaticoduodenal artery) 218.17
 epididymales (testicular artery) 222.2a
 externus
 (accessory nerve) 332.36
 (superior laryngeal nerve) 332.11
 fauciales (lingual nerve) 326.2
 femoralis (genitofemoral nerve) 342.23
 frontalis
 anteromedialis (callosomarginal artery) 204.11
 mediomedialis (callosomarginal artery) 204.12
 posteromedialis (callosomarginal artery) 204.13
 (superficial temporal artery) 198.7
 (superior tympanic artery) 198.20

Ramus(-i)
 ganglionici (ganglionares)
 (lingual nerve) 326.7
 (maxillary nerve) 322.15
 ganglionis trigeminalis (internal carotid) 200.20
 gastrici
 (gastroepiploic artery) 218.20, 218.32
 (vagus nerve)
 anterior 332.26
 posterior 332.27
 genitales (genitofemoral nerve) 342.22
 gingivales
 (inferior alveolar nerve) 326.16a
 inferiores (inferior alveolar nerve) 326.13
 superiores (infraorbital nerve) 324.8
 glandularis(-es)
 anterior (superior thyroid artery) 194.15
 (inferior thyroid artery) 210.16
 lateral (superior thyroid artery) 194.16a
 posterior (superior thyroid artery) 194.16
 (submandibular ganglion) 328.28
 (submental artery) 196.11
 globi pallidi (anterior choroidal artery) 202.29
 griseus (spinal nerve) 334.11a
 heliicini (uterine artery) 224.2a
 hepatici (vagus nerve) 332.28
 hypothalamicus (posterior communicating artery) 208.22
 ilealis (ileocolic artery) 220.9a
 iliacus (iliolumbar artery) 222.11
 inferior(-es)
 (oculomotor nerve) 320.7
 ossis pubis 44.20
 (superior gluteal artery) 222.23
 (transverse cervical nerve) 336.3
 infrahyoideus (superior thyroid artery) 194.9
 infrapatellaris (saphenous nerve) 344.5
 inguinales (external pudendal arteries) 224.35
 intercostales anteriores (internal thoracic artery) 210.10
 interganglionares 350.24
 intermedius (medial segmental artery) 218.12a
 internus
 (accessory nerve) 332.35
 (superior laryngeal nerve) 332.12

- Ramus (-i)
 interventricularis
 anterior (left coronary artery) 192.17
 posterior (right coronary artery) 192.12
 septales
 (left coronary artery) 192.20
 (right coronary artery) 192.13
 isthmi faucium (lingual nerve) 326.2
 labiales
 anteriores (external pudendal arteries) 224.34
 (inferior alveolar nerve) 326.16
 posteriores (internal pudendal artery) 224.12
 superiores (infraorbital nerve) 324.12
 laryngopharyngeales 352.3
 lateralis(-es)
 (hepatic duct) 132.13
 (left coronary artery) 192.19
 (lumbar nerves) 342.4
 (middle cerebral artery) 204.22
 nasi 196.13b
 (portal vein of liver) 248.11
 (right pulmonary artery) 190.21
 (sacral/coccygeal nerves) 342.10
 (spinal nerve) 334.16
 (supraorbital nerve) 320.25
 linguales(-es)
 (facial nerve) 328.16
 (glossopharyngeal nerve) 330.30
 (hypoglossal nerve) 334.2
 (lingual nerve) 326.6
 lingularis
 (left pulmonary artery) 190.34
 inferior 190.36
 superior 190.35
 (left superior pulmonary vein) 232.1
 lobi
 inferioris
 (left pulmonary artery) 190.36a
 (right pulmonary artery) 190.22a
 medii
 (right pulmonary artery) 190.20
 (superior right pulmonary vein) 230.14
 superioris
 (left pulmonary artery) 190.29a
 (right pulmonary artery) 190.14a
- Ramus (-i)
 lumbalis (iliolumbar artery) 222.9
 malleolares
 laterales (peroneal artery) 228.15
 mediales (posterior tibial artery) 228.10
 mammarii
 laterales 340.22
 (lateral thoracic artery) 212.19
 (posterior intercostal arteries) 216.15
 mediales
 (intercostal nerve) 340.25
 (internal thoracic artery) 210.8
 mandibulae 28.1
 marginalis
 dexter (right coronary artery) 192.10
 mandibularis (facial nerve) 328.17
 sinister (left coronary artery) 192.23
 tentorii (internal carotid) 200.18
 mastoideus
 (occipital artery) 196.16
 (posterior tympanic artery) 196.25
 medialis(-es)
 (hepatic duct) 132.14
 (lumbar nerves) 342.3
 (middle cerebral artery) 204.21
 (portal vein of liver) 248.14
 (right pulmonary artery) 190.22
 (sacral/coccygeal nerves) 342.9
 (spinal nerve) 334.15
 (supraorbital nerve) 320.26
 mediastinales
 (internal thoracic artery) 210.2
 (thoracic aorta) 216.6
 medullares
 lateralis (posterior inferior cerebellar artery) 206.15
 medialis (posterior inferior cerebellar artery) 206.15
 membranae tympani
 (auriculotemporal nerve) 324.26
 meningeus
 anterior
 (anterior ethmoidal artery) 202.16
 (vertebral artery) 206.9
 (internal carotid) 200.19
 (mandibular nerve) 324.14
 (maxillary nerve) 322.14
- Ramus (-i)
 meningeus
 (occipital artery) 196.19
 posterior (vertebral artery) 206.10
 recurrens (lacrimal artery) 202.5a
 (spinal nerve) 334.12
 (vagus nerve) 332.4
 mentalis(-es)
 (inferior alveolar artery) 198.15
 (inferior alveolar nerve) 326.15
 musculares 408.8
 (accessory nerve) 332.37
 (axillary nerve) 340.14
 (femoral nerve) 344.2
 lateralis (thoracic nerves) 340.17
 medialis (thoracic nerves) 340.17
 (median nerve) 338.12
 (musculocutaneous nerve) 338.2
 (obturator nerve) 342.29
 (perineal nerves) 346.21
 (peroneal nerve) 244.27, 344.22
 (radial nerve) 340.5
 (tibial nerve) 346.2
 (ulnar nerve) 338.18
 (vertebral artery) 206.6
 muscoli stylopharyngei 330.27
 mylohyoideus (inferior alveolar artery) 198.14
 nasales
 (anterior ethmoidal nerve) 322.6
 anteriores lateralis (anterior ethmoidal artery) 202.16b
 externus(-i)
 (anterior ethmoidal nerve) 322.10
 (infraorbital nerve) 324.10
 interni
 (anterior ethmoidal nerve) 322.7
 (infraorbital nerve) 324.11
 laterales 322.20d
 (anterior ethmoidal nerve) 322.8
 mediales (anterior ethmoidal nerve) 322.9
 posteriores inferiores
 (pterygopalatine ganglion) 322.23
 (pterygopalatine ganglion) 322.23
 posteriores superiores
 laterales 322.18
 mediales 322.19
 nervi oculomotorii (posterior communicating artery) 208.20

- Ramus (-i)
 nervorum (internal carotid)
 200.21
 nodi
 atrioventricularis
 (left coronary artery)
 192.27
 (right coronary artery)
 192.14
 sinuatrialis
 (left coronary artery)
 192.26
 (right coronary artery)
 192.9
 nucleorum hypothalamicorum
 (anterior choroidal artery)
 202.32
 obturatorius (inferior epigastric artery) 224.23
 occipitalis
 (occipital artery) 196.20
 (posterior auricular artery)
 196.28
 (posterior auricular nerve)
 328.7
 occipitotemporalis (medial occipital artery) 208.11
 oesophageales 216.30, 352.15b
 (inferior thyroid artery)
 210.18
 (thoracic aorta) 216.4
 (vagus nerve) 332.17
 omentales (gastroepiploic artery) 218.21, 218.33
 orbitalis (superior tympanic artery) 198.22
 ossis ischii 44.3
 ovaricus (uterine artery) 24.4
 palmaris
 (median nerve) 338.13
 nervi ulnaris 338.21
 profundus (ulnar artery)
 214.26
 superficialis, (ulnar artery)
 214.27
 palpebrales
 inferiores (infraorbital nerve) 324.9
 (infraorbital nerve) 322.12
 pancreatici
 (anterior superior pancreaticoduodenal artery)
 218.23
 (posterior superior pancreaticoduodenal artery) 218.16
 (splenic artery) 218.23
 parietalis
 (medial occipital artery)
 208.8
 (superficial temporal artery)
 198.8
 (superior tympanic artery)
 198.21
 parieto-occipitalis (medial occipital artery) 208.9
- Ramus (-i)
 parotideus(-i)
 (auriculotemporal nerve)
 324.27
 (facial vein) 236.15
 (posterior auricular artery)
 196.28a
 (superficial temporal artery)
 198.2
 pectorales (axillary artery)
 212.17
 pedunculares (posterior cerebral artery) 206.23
 perforans(-tes)
 (dorsal metacarpal arteries)
 214.13
 (internal thoracic artery)
 210.7
 (lateral circumflex femoral artery) 226.12
 (peroneal artery) 228.13
 (plantar metatarsal arteries)
 228.24
 pericardiacus(-i)
 (phrenic nerve) 336.9
 (thoracic aorta) 216.5
 peridentales
 (anterior superior alveolar arteries) 198.3a
 (inferior alveolar artery)
 198.13a
 (posterior superior alveolar artery) 198.29a
 perineales (femoral cutaneous nerve) 344.16
 petrosus (middle meningeal artery) 198.18
 pharyngealis(-es)
 (glossopharyngeal nerve)
 330.26
 (inferior thyroid artery)
 210.17
 (vagus nerve) 332.7, 332.17a
 pharyngeus (pharyngeales)
 (artery of pterygoid canal)
 200.4a
 (ascending pharyngeal artery) 194.19
 (descending palatine artery)
 200.7a
 phrenicoabdominales (phrenic nerve) 336.10
 postcentralis (posterior intercostal arteries) 216.10a
 posterior(-es)
 ascendens (right pulmonary artery) 190.19
 descendens (right pulmonary artery) 190.16
 (great auricular nerve)
 334.29
 (hepatic duct) 132.11
 (lateral sulcus) 306.20
 (left pulmonary artery)
 190.32
- Ramus (-i)
 posterior(-es)
 (lumbar nerve) 342.2
 (medial antebrachial cutaneous nerve) 338.7
 (obturator artery) 222.18
 (obturator nerve) 342.28
 (portal vein of liver) 248.4
 (renal artery) 220.24
 (sacral/coccygeal nerves)
 342.8
 (spinal nerve) 334.10, 334.15
 (superior mesenteric artery)
 220.2
 (superior right pulmonary vein) 230.11
 (thoracic nerves) 340.17
 (ulnar recurrent artery)
 214.17
 ventriculi sinistri (left coronary artery) 192.25
 posterolateralis dexter (right coronary artery) 192.15
 praelaminaris (posterior intercostal arteries) 216.10b
 profundus
 (medial circumflex femoral artery) 226.4
 (medial plantar artery)
 228.19
 (plantar nerve) 346.16
 (radial nerve) 340.6
 (superior gluteal artery)
 222.21
 (transverse cervical artery)
 210.24
 (ulnar nerve) 338.25
 prostatici (inferior vesical artery) 224.1a
 pterygoideus
 (internal carotid) 200.15
 (maxillary artery) 198.26
 pubicus
 (external iliac vein)
 250.24a
 (inferior epigastric artery)
 224.22
 (obturator artery) 222.15
 pulmonales 348.8
 thoracici 352.15a
 radicales (vertebral artery)
 206.5
 renalis(-es)
 (n. splanchnicus minor)
 352.19
 (vagus nerve) 332.30
 sacrales laterales 216.26a
 saphenus (descending genicular artery) 226.1b
 scrotales
 anteriores (external pudendal arteries) 224.33
 posteriores (internal pudendal artery) 224.11

- Ramus (-i)
 septales
 anteriores (anterior ethmoidal artery) 202.17
 nasales 322.20b
 posteriores (sphenopalatine artery) 200.9a
 septi nasi 196.13a
 sinister
 (hepatic artery proper) 218.9
 (portal vein of liver) 248.5
 sinus
 carotici (glossopharyngeal nerve) 330.28
 cavernosi (internal carotid) 200.22
 maxillaris (nasopalatine nerve) 322.20e
 spinalis(-es)
 (ascending cervical artery) 210.21
 (iliolumbar artery) 222.10
 (lateral sacral arteries) 222.13
 (posterior intercostal arteries) 212.8, 216.10, 216.18
 (vertebral artery) 206.5
 splenici (splenic artery) 218.35, 268.18
 stapediales 196.26
 sternales (internal thoracic artery) 210.6
 sternocleidomastoideus
 (occipital artery) 196.18
 (superior thyroid artery) 194.12
 stylohyoideus (facial nerve) 328.10
 subendocardiales 186.12a
 subscapulares (axillary artery) 212.10
 substantiae perforatae anterioris (anterior choroidal artery) 202.25
 superficiales
 (lateral plantar nerve) 346.13
 (medial circumflex femoral artery) 226.3a
 (medial plantar artery) 228.20
 (radial nerve) 340.8
 (superior gluteal artery) 222.20
 (transverse cervical artery) 210.23
 (ulnar nerve) 338.22
 superior
 (inferior right pulmonary vein) 230.18
 (left inferior pulmonary vein) 232.4
 lobi inferioris
 (left pulmonary artery) 190.37
 (right pulmonary artery) 190.23
- Ramus (-i)
 superior
 (oculomotor nerve) 320.6
 ossis pubis 44.13
 (superior gluteal artery) 222.22
 superior (transverse cervical nerve) 336.2
 supracostalis (posterior intercostal arteries) 216.13
 suprahyoideus (lingual artery) 196.2
 sympathetic (ad ganglion submandibulare) 328.27
 temporales
 anteriores (lateral occipital artery) 208.3
 (facial nerve) 328.13
 intermedii mediales (lateral occipital artery) 208.4
 posteriores (lateral occipital artery) 208.5
 superficialis 324.30
 tentorii (ophthalmic nerve) 320.20
 thalamicus(-i)
 (posterior cerebral artery) 206.28
 (posterior communicating artery) 208.21
 thymici (internal thoracic artery) 210.3
 thyrohyoideus (ansa cervicalis) 334.26
 tonsillae cerebelli (posterior inferior cerebellar artery) 206.14
 tonsillaris(-es)
 (ascending palatine artery) 196.9
 (glossopharyngeal nerve) 330.29
 (lesser palatine nerves) 322.24a
 tracheales
 (inferior thyroid artery) 210.19
 (internal thoracic artery) 210.4a
 (vagus nerve) 332.16
 tractus optici (anterior choroidal artery) 202.26
 transversus (lateral circumflex femoral artery) 226.11
 tubarius (tubalis)
 (ovarian artery) 222.4a, 224.5
 (tympanic plexus) 330.23
 tuberis cinerei (anterior choroidal artery) 202.31
 ulnaris (medial antebrachial cutaneous nerve) 338.7
 ureterici (artery of ductus deferens) 222.28
- Ramus (-i)
 uterici
 (ovarian artery) 222.4
 (renal artery) 220.26
 (testicular artery) 222.2
 vaginales
 (uterine artery) 224.3
 (vaginal artery) 224.7a
 vestibulares (labyrinthine artery) 374.12
 zygomatici (facial nerve) 328.14
 zygomaticofacialis (zygomatic nerve) 322.27
 zygomaticotemporalis (zygomatic nerve) 322.26
- Raphe
 medullae oblongatae 282.25
 palati 108.18
 palpebralis lateralis 366.19
 penis 164.7
 perinealis 174.2
 pharyngis 118.20
 pontis 284.18
 pterygomandibularis 118.21
 scroti (scrotalis) 166.2
- Recessus(-i) 178.26
 cochlearis 376.1
 costodiaphragmaticus 152.20
 costomediastinalis 152.21
 duodenalis
 inferior 178.31
 superior 178.29
 ellipticus 374.23
 epitympanicus 378.18
 hepatorenalis 180.11
 ileocaecalis
 inferior 180.4
 superior 180.2
 inferior omentalis 176.33
 infundibuli (infundibularis) 298.5
 intersigmoideus 180.1
 lateralis 286.21
 membranae tympanicae 384.7a
 anterior 384.8
 posterior 384.10
 superior 384.9
 opticus 298.4
 paraduodenalis 178.33
 pharyngeus 118.7
 phrenicomedialistinalis 152.22
 pinealis 298.6
 piriformis 118.13
 pleurales 152.19
 retrocaecalis 180.6
 retroduodenalis 178.34
 sacciformis 62.14
 sphenothmoidalis 32.8, 136.18
 sphericus 374.22
 splenicus (lienalis) 176.34
 subhepatici 180.10
 subphrenici 180.9
 subpopliteus 106.3

- Recessus(-i)
 superior omentalis 176.32
 suprascapularis 298.7
- Rectal
 artery
 inferior 224.9
 middle 224.7
 superior 220.15
 lymph nodes, superior 264.13
 nerves, inferior 346.18
 plexus
 middle 350.12
 superior 350.2
 veins
 inferior 250.20
 middle 250.19
 superior 248.36
 venous plexus 250.7
- Rectouterine
 fold 180.30
 pouch 180.31
- Rectovaginal septum 174.25
- Rectovesical
 pouch 180.33
 septum 174.24
- Rectum 126.13
- Rectus sheath 86.4
 anterior layer 86.5
 posterior layer 86.6
- Recurrent
 artery 204.5
 anterior tibial 226.24
 posterior tibial 226.23
 radial 214.3
 ulnar 214.15
 interosseous artery 214.21
 laryngeal nerve 332.15
 meningeal branch of lacrimal
 artery 202.5a
- Red
 bone marrow 404.5
 nucleus 294.3
- Reflected ligament 86.13
- Regio(-nes)
 abdominales 400.1
 anal 400.16
 antebrachialis
 anterior 400.30
 posterior 400.31
 axillaris 398.40
 brachialis
 anterior 400.21
 posterior 400.22
 buccalis 398.20
 calcanea 402.18
 capitis 398.9
 carpalis
 anterior 400.35
 posterior 400.36
 cervicalis(-es) 398.22
 anterior 398.23
 lateralis 398.30
 posterior 398.32
 corporis 396.46
 coxalis 402.3a
- Regio(-nes)
 cruralis
 anterior 402.13
 posterior 402.14
 cubitalis anterior 400.24
 deltoidea 400.19
 dorsalis(-es) 400.8
 pedis 402.19
 epigastrica (epigastrium) 400.3
 faciales 398.14
 femorales 402.4
 anterior 402.5
 posterior 402.7
 frontalis 398.10
 genus
 anterior 402.9
 posterior 402.10
 glutealis 402.2
 hypochondriaca (hypo-
 chondrium) 400.2
 hypogastrium 400.7
 hypothalamica
 anterior 302.16
 dorsalis (posterior) 302.14,
 304.6
 intermedia 302.21
 lateralis 302.24
 inframammaria 398.39
 infraorbitalis 398.19
 infrascapularis 400.12
 inguinalis 400.6
 lateralis 400.4
 lumbaris (lumbalis) 400.13
 mammaria 398.38
 membri
 inferioris 402.1
 superioris 400.18
 mentalis 398.18
 nasalis 398.16
 nuchalis 398.32
 occipitalis 398.12
 olfactoria (nose) 136.16
 tunicae mucosae nasi 388.24
 oralis 398.17
 orbitalis 398.15
 parietalis 398.11
 pectorales 398.33, 398.37
 perinealis 400.15
 plantaris pedis 402.20
 pleuropulmonales 152.7
 presternalis 398.34
 pubica 400.7
 respiratoria (nose) 136.15
 sacralis 400.10
 scapularis 400.11
 sternocleidomastoidea 398.28
 suralis 402.15
 talocrurales
 anterior 402.16
 posterior 402.16
 temporalis 398.13
 umbilicalis 400.5
 urogenitalis 400.17
 vertebralis 400.9
 zygomatrica 398.21
- Regional lymph nodes 256.1
- Reissner's membrane 374.3
- Ren 154.3
- Renal
 arteries 156.1
 artery 220.17
 branch(-es)
 lesser splanchnic nerve 352.19
 vagus nerve 332.30
 calices 156.16
 major 156.17
 minor 156.18
 columns 154.36
 corpuscule 154.37
 cortex 154.26
 fascia 154.12
 ganglia 348.24
 hilum 154.6
 impression 130.12
 lobes 154.25
 medulla 154.30
 papillae 154.33
 pelvis 156.15
 plexus 348.23
 pyramids 154.31
 base 154.32
 segments 154.16
 sinus 154.7
 surface
 of adrenal gland 182.32
 of spleen 268.5
 tubule (nephron) 154.22
 straight segments 154.24
 veins 156.9, 246.28
- Respiratory
 region of nose 136.15
 system 134.17
- Restiform body 290.24
- Rete
 acromiale 212.14
 articular(-e)
 cubiti 214.18
 genus 226.20
 calcaneum 228.17
 carpal dorsale 214.6
 lymphocapillare 254.4
 malleolare
 laterale 226.27
 mediale 228.10a
 mirabile 406.27
 patellare 226.21
 testis 158.31
 vasculosum articulare 406.28
 venosum 406.29
 dorsale
 manus 244.28
 pedis 252.17
 plantare 252.23
- Reticular
 formation 92.22, 276.16,
 280.27, 284.23, 406.53
 layer 390.18
 membrane 374.1
 nucleus of thalamus 298.12,
 298.24, 300.18

- Reticulospinal tract 276.24
 Reticulum trabeculare 354.27
 Retina 358.19
 Retinaculum(-a)
 caudale 390.8
 cutis 390.5
 extensorum 92.22
 inferius 100.13
 superius 100.11
 flexorum 92.26, 100.12
 patellae
 laterale 68.18
 mediale 68.17
 peroneorum (fibularium)
 inferius 100.15
 superius 100.14
 unguis 394.8
 Retinal blood vessels 360.6
 Retro-olivary
 area 278.26
 sulcus 27.25
 Retroauricular lymph nodes 256.4
 Retrocecal
 lymph nodes 264.6
 recess 180.6
 Retroduodenal
 arteries 218.18
 recess 178.34
 Retrohyoid bursa 102.4
 Retrolentiform part of internal capsule 318.26
 Retromandibular vein 236.18
 Retropertitoneal space 176.20
 Retropharyngeal
 lymph nodes 256.23a, 258.13
 space 118.36
 Retroposterolateral nucleus 274.22
 Retropubic space 176.16
 Retropyloric nodes 262.21
 Rhinal sulcus 310.19
 Rhinencephalon 310.26a, 312.1
 Rhombencephalon 278.16
 Rhomboid fossa 286.20
 Rhomboidal nucleus 298.19
 Ribs 6.2
 angle of 6.16
 bony part 6.7
 cervical 6.22
 false 6.4
 first 6.17a
 floating 6.5
 head of 6.8
 joints 58.11
 neck of 6.11
 crest 6.12
 second 6.20a
 shaft (body) of 6.13
 true 6.3
 Right 396.7
 atrial veins 232.24
 atrioventricular
 opening 188.2
 valve 188.3
- Right
 atrium 186.14
 of heart 184.26
 auricle 186.22
 brachiocephalic veins 232.28
 branch
 hepatic artery proper 218.4
 portal vein of liver 248.2
 bronchomediastinal trunk 254.12
 colic
 artery 220.10
 flexure 124.27
 lymph nodes 264.10
 vein 248.27
 coronary
 artery 192.7
 vein 232.20b
 duct of caudate lobe 132.15
 fibrous
 ring 186.6
 trigone 186.5
 gastric
 artery 218.3
 vein 248.18
 gastro-omental
 artery 218.19
 vein 248.22
 hepatic
 artery 218.4
 duct 132.9
 veins 246.25
 horn of uterus 168.9
 inferior lobar bronchus 146.9
 jugular trunk 254.14
 lamina, larynx 138.16
 lobe
 of liver 130.18
 of prostate 162.16
 lumbar
 lymph nodes 262.7
 trunk 254.10
 lung 148.7
 lower lobe 150.9
 middle lobe 150.6
 upper lobe 150.2
 lymphatic duct 254.16
 main bronchus 144.30
 margin
 heart 184.15
 uterus 168.10
 marginal
 branch (right coronary
 artery) 192.10
 vein 232.20a
 middle lobar bronchus 146.6
 ovarian vein 246.34
 posterolateral branch of right
 coronary
 artery 192.15
 pulmonary
 artery 190.14
 veins 230.3
 inferior 230.17
 superior 230.4
- Right
 semilunar cusp
 of aortic valve 190.3
 of pulmonary valve 188.12
 subclavian trunk 254.13
 superior
 intercostal vein 246.2
 lobar bronchus 146.2
 suprarenal vein 246.32
 testicular vein 246.33
 thoracic duct 254.16
 triangular ligament 178.23
 ventricle of heart 184.21, 188.1
- Rima
 glottidis 144.4
 oris 108.4
 palpebrarum 366.8
 pudendi 170.29
 vestibuli 142.28
- Ring
 apophysis (epiphysis) 2.3b
 finger 400.47
- Rivus lacrimalis 368.15
 Roof of tympanic cavity 14.2
 Root
 canal 112.3
 filaments 334.4
 of lung 148.21
 of nail 392.27
 of nose 134.19
 of penis 162.28
 pulp 112.7
 of tongue 112.30
 of tooth 110.21
 apex 110.22
- Rosenmüller's recess 118.7
 Rostral 396.23
 Rostralis 396.23
 Rostrum 312.10
 sphenoidale 10.14
- Round
 ligament
 of liver 130.4, 248.13
 of uterus 168.32
 window 380.2
 crest 380.4
 fossula 380.3
- Rubrospinal tract 276.29, 294.10
 Rugae vaginales 170.12
 columns of 170.13
- S**
- Sac, lacrimal, fossa for 20.25, 32.22b
 Sacculus
 macula 372.5
 nerve 330.14
 Sacculiones coli 124.33
 Saccule 372.2
 Sacculus(-i) 372.2
 alveolares 152.4
 laryngis 144.2
 Saccus
 conjunctivalis 368.5

- Saccus
endolymphaticus 370.8
lacrimalis 368.21
- Sacral
canal 4.34
cornu (horn) 4.33
crest
intermediate 4.31
lateral 4.32
median 4.29
flexure 126.14
foramina
anterior 4.27
posterior 4.30
ganglia 352.23
hiatus 4.35
lymph nodes 266.4
nerves 342.7
parasympathetic nuclei
276.15
plexus 344.8
region 400.10
segment of spinal cord 274.9
splanchnic nerves 352.24
tuberosity 4.23
vein(-s)
lateral 250.5
median 248.38
venous plexus 250.6
- Sacrococcygeal
joint 56.21
ligament
deep dorsal 56.23
lateral 56.25
superficial dorsal 56.22
ventral 56.24
- Sacrococcygeus muscle
dorsal (posterior) 88.4
ventral (anterior) 88.3
- Sacroiliac
joint 66.11
ligaments
dorsal 66.14
interosseous 66.13
ventral 66.12
- Sacropelvic surface, ilium 42.29
- Sacrospinous ligament 66.8
- Sacrotransverse ligament 66.6
- Sacrum 4.16
ala 4.19
apex 4.36
base 4.17
dorsal surface 4.28
lateral mass 4.21
promontory 4.18
- Saddle joint 404.31
- Sagittal 396.6
border, parietal bone 16.33
sinus
inferior 238.16
superior 238.14
groove for 8.31, 16.26a,
18.16, 28.26
suture 54.3
- Sagittalis 396.6
- Salivary
glands
major 110.1
minor 108.31
nucleus
inferior 282.21
superior 286.5
- Salpingopalatine fold 116.8
- Salpingopharyngeal fold 118.4
- Saphenous
branch of descending genicular
artery 226.1b
nerve 344.4
opening 100.3
vein
accessory 252.8
greater 252.7
small 252.15
- Scala
tympani 372.12
vestibuli 372.11
- Scalene muscle, anterior,
tubercle 6.18
- Scalp hairs 392.3
- Scaphoid 40.4
fossa 12.6, 386.18
eminence 388.8
tubercle 40.5
- Scapula 34.3
neck 34.23
spine 34.7
- Scapular
artery
circumflex 212.22
dorsal 210.24, 210.24a
ligament
inferior transverse 60.15
superior transverse 60.14
line 396.55
nerve, dorsal 336.20
notch 34.16
region 400.11
vein
anterior circumflex 244.13a
circumflex 244.13a
dorsal 244.11
posterior circumflex 244.13a
- Scapus pili 392.13
- Schindylesis 404.18
- Sciatic
artery 222.25
nerve 344.17
notch
greater 44.6
lesser 44.7
- Sciatic foramen
greater 66.9
lesser 66.10
- Sclera 354.24
- Scleral
sulcus 354.25
veins 244.3
- Scrotal
nerves
anterior 342.19
- Scrotal
nerves
posterior 346.20
veins
anterior 252.6
posterior 250.21
- Scrotum 166.1
raphe 166.2
septum 166.3
- Sebaceous glands (of Zeis) 368.7,
394.17
- Second rib 6.20a
- Secondary
center of ossification 404.10
fissure 288.30
spinal lamina 378.4
tympanic membrane 380.6
visceral substance 276.8
- Sectiones
cerebellares 290.9
epithalamici 296.10
hypothalamici 302.13
medullae
oblongatae 280.9
spinalis 274.11
mesencephalici 292.21
metathalamici 298.11
pontis 284.7
telencephalici 314.19a, 316.1
thalami ventralis 300.14
thalamici 298.11
- Segmental
artery
anterior 218.7
medial 218.11
posterior 218.8, 220.25
superior 220.20
anterior 220.21
bronchial branches 148.1
bronchus(-i) 146.1
anterior 146.5, 146.18
basal 146.13, 146.25
apical 146.3
apicoposterior 146.17
lateral 146.7
basal 146.14, 146.26
medial 146.8
basal 146.12, 146.24
posterior 146.4
basal 146.15
subapical 146.11, 146.23
superior 146.10, 146.22
inferior 220.23
anterior 220.22
medullary artery 216.10e
- Segmentum(-a)
anterior
inferius (kidney) 154.19
(liver) 130.19
superius (kidney) 154.18
(upper lobe of left lung) 150.18
(upper lobe of right lung)
150.5
apicale (upper lobe of right
lung) 150.3

- Segmentum(-a)
 apicosterius (upper lobe of left lung) 150.17
 basale
 anterior
 (lower lobe of left lung) 150.25
 (lower lobe of right lung) 150.13
 laterale
 (lower lobe of left lung) 150.26
 (lower lobe of right lung) 150.14
 mediale
 (lower lobe of left lung) 150.24
 (lower lobe of right lung) 150.12
 posterius
 (lower lobe of left lung) 150.27
 (lower lobe of right lung) 150.15
 bronchopulmonalia 150.1
 cervicalia 274.6
 coccygea 274.10
 inferius (kidney) 154.20
 laterale
 (liver) 130.24
 (middle lobe of right lung) 150.7
 lingulare
 inferius (upper lobe of left lung) 150.20
 superius (upper lobe of left lung) 150.19
 lumbaria 274.8
 mediale
 (liver) 130.22
 (middle lobe of right lung) 150.8
 medullae spinalis 274.5
 posterius
 (kidney) 154.21
 (liver) 130.20
 (upper lobe of right lung) 150.4
 renalia 154.16
 sacralia 274.9
 subapicale
 (lower lobe of left lung) 150.23
 (lower lobe of right lung) 150.11
 superius
 (kidney) 154.17
 (lower lobe of left lung) 150.22
 (lower lobe of right lung) 150.10
 thoracica 274.7
 Sella turcica 10.5
 Sellar joint 404.31
- Semicanalis
 musculus tensoris tympani 12.29
 tubae auditoriae (auditivae) 12.30
- Semicircular canals
 anterior 376.7
 lateral 376.9
 osseous 376.6
 posterior 376.8
 duct 370.11
 anterior 370.12
 basal membrane 370.16
 epithelium 370.17
 lateral 370.14
 posterior 370.13
 proper membrane 370.15
- Semilunar cusp
 of aortic valve
 left 190.5
 posterior 190.3
 right 190.4
 lunules 188.15, 190.6
 nodules 188.14, 190.6
 of pulmonary valve
 anterior 188.11
 left 188.13
 right 188.12
 folds 116.14
 of colon 124.32
 of conjunctive 366.25
 ganglion 320.17
 lobule
 inferior 288.35
 superior 288.33
- Seminal vesicle 160.20
- Seminiferous tubules
 convoluted 158.29
 straight 158.30
- Sense organs 354.1
- Sensory ganglia 407.13, 407.14
 of cranial nerves 407.15
 nerve 408.10
 root 334.6
 facial nerve 328.19
 nasociliary nerve 320.12
 pterygopalatine ganglion 322.16c
 trigeminal nerve 320.16
- Septal cusp 188.6
 interventricular branches
 left coronary artery 192.20
 right coronary artery 192.13
 papillary muscle 188.18
- Septomarginal fasciculus 278.10
 trabecula 188.19
- Septula testis 158.26
- Septum(-a)
 atrioventriculare 184.25
 cervicale intermedium 272.10
- Septum(-a)
 corporum cavernosorum 172.11
 femorale 100.2
 glandis 164.3
 interalveolaria 24.11, 26.29
 interatriale 184.28
 intermusculare
 brachii
 laterale 92.19
 mediale 92.18
 cruris
 anterior 100.9
 posterior 100.10
 femoris
 laterale 98.15
 mediale 98.16
 interradicularia 24.12, 26.30
 intersinuale
 frontale 18.30
 sphenoidale 10.16
 interventriculare 184.22
 lingualis 114.16
 medianum posterius 272.21
 musculotubal canal 12.31
 nasale 136.4
 osseum 32.2, 136.6
 orbitale 364.19
 pectiniforme 164.13
 pellucidum (lucidum) 312.27
 cavity 312.28
 lamina 312.29
 penis 164.13
 precommissurale 312.30
 rectovaginale 174.25
 rectovesicale 174.24
 scroti (scrotalis) 166.3
- Seromucous gland 406.9
- Serous gland 406.8
 membrane 122.3
 pericardium 184.4
- Sesamoid bones
 fingers 40.32
 toes 52.32
 cartilage 140.27
- Shaft
 of clavicle 34.29
 of femur 46.12
 of fibula 48.20
 of metatarsal bone 52.19
 of penis 162.29
 of rib 6.13
 of tibia 48.1
- Sheath
 of extensor carpi radialis brevis 102.26
 fibrous
 of digits of foot 100.22
 of fingers 92.27
 of styloid process 16.9
 synovial
 of fingers 92.30
 of toes 100.19a, 100.20
 see also Tendon

Short

- bone 402.42
 - central artery 204.4
 - ciliary nerves 320.10
 - gastric
 - arteries 218.34
 - veins 248.31
 - gyrus of insula 308.27
 - head
 - of biceps brachii 88.15
 - of biceps femoris 96.4
 - nasopalatine nerve 322.20c
 - posterior ciliary arteries 202.6
- Shoulder
- blade 34.3
 - girdle 34.2
 - joints 60.12
 - joint 60.29
- Shrapnell's membrane 380.22
- Sigmoid
- arteries 220.14
 - colon 124.31
 - lymph nodes 264.12
 - mesocolon 178.8
 - sinus 238.13
 - groove for 8.33, 12.19, 16.26
 - veins 248.35
- Simple
- joint 404.23
 - membranous crus 370.27
 - osseous crus 376.16
- Sinister 396.8
- Sinoatrial (SA) node 186.8
- Sinuatrial node branch, left coronary artery 192.26
- Sinus(-us)
- anales 126.26
 - anteriores 138.6
 - aortae 192.6
 - caroticus 194.8, 200.12
 - cavernosus 238.21
 - coronarius 232.15
 - durae matris 238.8
 - epididymidis 162.6
 - ethmoidales 138.5
 - frontalis 18.28, 138.4
 - apertura 18.29
 - septum 18.30
 - intercavernosi 238.22
 - lactiferi 394.26
 - marginalis 238.10a
 - maxillaris 22.24, 138.2
 - medii 138.7
 - obliquus pericardii 184.9
 - occipitalis 238.11
 - groove for 8.33a
 - paranasales 138.1
 - petrosus
 - inferior 238.18
 - groove for 8.7, 14.18
 - superior 238.20
 - groove for 14.10
 - posterior(-es) 138.8, 380.15
 - prostaticus 164.28
 - rectus 238.17

Sinus(-us)

- renalis 154.7
 - sagittalis
 - inferior 238.16
 - superior 238.14
 - groove for 8.31, 16.26a, 18.16, 28.26
 - sigmoideus 238.13
 - groove for 8.33, 12.19, 16.26
 - sphenoidalis 10.15, 138.3
 - aperture 10.17
 - septum 1.16
 - sphenoparietalis 238.23
 - splenica (lienalis) 268.17
 - tarsi 50.30
 - transversus 238.9
 - groove for 8.32
 - pericardii 184.8
 - trunci pulmonalis 190.12
 - tympani 380.1
 - unguis 392.24
 - urogenitalis primitivus 172.34
 - venarum cavarum 186.18
 - venosus 406.30
 - sclerae 244.2a, 354.30
- Sinusoid 406.41
- Skeletal
- muscle 405.15
 - system 402.30
- Skeleton
- appendiculare 402.40
 - axiale 402.39
- Skin 390.1
- sulci 390.3
- Skull 28.20
- joints 56.8
 - synovial 60.1
 - sutures 54.1
- Small
- cardiac vein 232.21
 - intestine 122.20
 - saphenous vein 252.15
- Smallest cardiac veins 232.23
- Soft palate 108.17, 116.4
- Sole 402.20
- Soleal line of tibia 48.5
- Solitary lymphatic follicles (nodules) 122.32, 126.12
- Somatic nerve fibers 407.8
- Spatium(-a)
- anguli iridocornealis 358.14
 - epidurale (peridurale) 268.33
 - episclerale 364.22
 - extraperitoneale 176.19a
 - intercostale 6.40
 - interossea
 - metacarpi 64.15
 - metatarsi 17, 72
 - intervaginale(-ia) 354.14, 364.22
 - lateropharyngeum 118.37
 - perichoroideale 356.15
 - perilymphaticum 372.10
 - perinei
 - profundum 176.2
 - superficiale 176.8

Spatium(-a)

- peripharyngeum 118.35
 - praevesicale 176.16
 - retroperitoneale 176.20
 - retropharyngeum 118.36
 - retropubicum 176.16
 - subarachnoideum 270.2, 270.14
 - subdurale 268.30
 - zonularia 362.26
- Spermatic
- cord 160.25
 - fascia, internal 160.30
- Spheno-occipital synchondrosis 56.2
- Sphenoethmoidal
- recess 32.8, 136.19
 - suture 54.7
 - synchondrosis 56.7
- Sphenofrontal suture 54.6
- Sphenoid bone 10.1
- angular spine 10.38
 - body 10.2
 - greater wing 10.23
 - lesser wing 10.19
 - pterygoid process 12.1
- Sphenoidal
- angle 16.37
 - border, temporal bone 16.13
 - concha 10.18
 - crest 10.13
 - fontanelle 32.30
 - part of middle cerebral artery 204.19
 - process 24.26
 - rostrum 10.14
 - sinus 10.15, 138.3
 - aperture 10.17
 - septum 10.16
- Sphenomandibular ligament 60.8
- Sphenomaxillary suture 54.24
- Sphenopalatine
- artery 200.8
 - foramen 32.11
 - notch 24.19
- Sphenoparietal
- sinus 238.23
 - suture 54.9
- Sphenopetrosal
- fissure 30.19
 - synchondrosis 56.3
- Sphenosquamosal suture 54.8
- Sphenovomerine suture 54.22
- Sphenozygomatic suture 54.23
- Spherical recess of vestibule 374.22
- Spheroidal joint 404.26
- Sphincter muscle 405.11
- of bile duct 134.13
 - of pancreatic duct 128.18
- Spina(-ae)
- helicis 386.13
 - iliaca
 - anterior
 - inferior 42.21
 - superior 42.20

- Spina(-ae)
 iliaca
 posterior
 inferior 42.23
 superior 42.22
 ischiadica (ischialis) 44.5
 mentalis 26.21
 nasalis 18.19
 anterior 22.12
 posterior 24.31
 ossis sphenoidalis 10.38
 palatinae 24.6
 scapulae 34.7
 suprameatica 16.19
 trochlearis 18.23
 tympanica
 major 16.5
 minor 16.6
- Spinal
 arachnoid 270.13
 artery
 anterior 206.11
 posterior 206.16
 branch(-es)
 abdominal aorta 216.24
 ascending cervical artery
 210.21
 iliolumbar artery 222.9
 lateral sacral arteries 222.13
 posterior intercostal arteries
 212.8, 216.10, 216.18
 (posterior intercostal veins)
 246.16
 vertebral artery 206.5
 cord 272.13
 funiculi 274.1
 sections 274.11
 segments 274.5
 veins 246.20
 dura mater 268.31
 ganglion 334.7, 407.14
 lamina
 bony 378.1
 secondary 378.4
 lemniscus 284.24, 294.15,
 300.24
 nerve(-s) 334.3, 407.23
 groove for 2.22
 plexus 407.24
 trunk 334.8
 nucleus of trigeminal nerve
 280.26, 284.26
 pia mater 272.8
 roots of vagus nerve 332.33
 tract of trigeminal nerve
 280.26, 284.25
 veins
 anterior 246.20a
 posterior 246.20b
- Spino-olivary tract 278.6, 282.2
- Spinocerebellar tract
 anterior 278.3
 posterior 278.4
- Spinoreticular tract 278.7
- Spinotectal tract 278.1, 284.22
- Spinothalamic tract 278.2
 anterior 276.25
- Spinous process 2.11
- Spiral
 canal
 of cochlea 376.21
 of modiolus 376.25
 crest 372.21
 fold 134.11
 ganglion 330.16
 of cochlea 374.9
 ligament 372.21
 membrane 372.18
 organ (of Corti) 372.19
 prominence 374.6
 sulcus
 external 372.29
 internal 372.28
 tract, foraminous 378.11
 vein of modiolus 374.15
 vessel 374.2
- Splanchnic
 ganglion, thoracic 352.17
 nerves
 greater 352.16
 lesser 352.18
 lowest 352.20
 lumbar 352.21
 pelvic 352.34
 sacral 352.24
- Splanchnology (splanchnologia)
 405.35
- Spleen 268.1
 hilum 268.12
- Splen 268.1
 accessorius 268.2
- Splenic
 artery 218.25
 branches of splenic artery
 218.35, 268.18
 lymph nodes 262.25
 plexus 348.19
 pulp 268.16
 recess 176.34
 sinus 268.17
 vein 248.29
- Splenium 312.7
- Splenorenal ligament 178.19
- Spongy
 bone 402.36
 part of urethra 164.30
- Squama
 frontalis 18.2
 occipitalis 8.10
- Squamosomastoid suture 54.13
- Squamotympanic fissure 14.33
- Squamous
 border
 parietal bone 16.32
 sphenoid 10.31
 part of temporal bone 16.10
 suture 54.10, 404.16
- Stapedial
 branch 196.26
 fold 384.12
 membrane 382.28
- Stapes 382.1, 382.2
 head 382.3
- Staticae 372.3
- Statoconia 372.6
- Statoconial membrane 372.7
- Stellate
 ganglion 352.8
 venules 156.14
- Sternal
 angle 6.27
 articular surface (clavicle) 34.27
 branches of internal thoracic
 artery 210.6
 line 396.48
 membrane 58.23
 part of diaphragm 84.28
 synchondroses 6.28
- Sternoclavicular
 joint 60.22
 ligament
 anterior 60.24
 posterior 60.25
- Sternocleidomastoid
 branch
 occipital artery 196.18
 superior thyroid artery
 194.12
 muscle 80.26
 region 398.28
 vein 236.3
- Sternocostal
 joint 58.20
 ligament
 intra-articular 58.21
 radiate 58.22
 part of pectoralis major 84.5
 surface (heart) 184.12
 synchondrosis of first rib 26a
- Sternopericardiac ligaments
 184.3
- Sternum 6.23
 body 6.31
- Stomach 120.15
- Straight
 arterioles 156.8
 part of musclicriothy-
 roideus 142.13
 segments of renal tubules
 154.24
 seminiferous tubules 158.30
 sinus 238.17
 venules 156.13
- Stratum(-a)
 basale 390.14
 circulare 405.46
 (colon) 126.7
 (rectum) 126.19
 (small intestine) 122.25
 (stomach) 122.7
 (tympanic membrane)
 380.32
 colliculi superioris (grisea/
 alba) 294.22
 corneum 390.10
 unguis 394.6

- Stratum(-a)
 cutaneum (tympanic membrane) 380.29
 cylindricum 390.14
 fibrosum 404.39
 (tendon sheath) 405.19
 ganglionare
 nervi optici 358.25
 retinae 358.24
 germinativum unguis 394.7
 granuloseum 166.23, 290.16, 390.12
 longitudinale 405.46
 (colon) 126.2
 (rectum) 126.18
 (small intestine) 122.24
 (stomach) 122.6
 lucidum 390.11
 moleculare (plexiforme), (cerebellum) 290.14
 mucosum (tympanic membrane) 380.33
 neurium piriformium 290.15
 neuroepitheliale (retina) 358.23
 papillare 390.16
 radiatum (tympanic membrane) 380.31
 reticulare 390.18
 spinosum 390.13
 synoviale 404.40
 (tendon sheath) 405.20
- Stria(-ae)
 diagonalis (Broca) 312.3
 laminae
 granularis
 externa, cerebral cortex 316.11
 interna, cerebral cortex 316.12
 molecularis (plexiformis), cerebral cortex 316.10
 pyramidalis interna (ganglionaris), cerebral cortex 316.13
 longitudinalis
 lateralis 312.17
 medialis 312.16
 malleolaris 380.27
 medullaris(-es) 286.30
 thalamica 296.24
 olfactoriae
 lateralis 310.30
 medialis 310.30
 terminalis 314.7
 fibers of 304.18
 vascularis 374.8
- Stroma 182.8, 406.3
 ganglii (ganglionicum) 407.12
 iridis 258.12
 ovarii 166.15
 vitreum 362.9
- Stylohyoid
 branch of facial nerve 328.10
 ligament 60.11
- Styloid
 process
 head of fibula 48.18
 metacarpal bone 40.22
 temporal bone 14.26
 sheath 16.9
 ulna 38.14
 prominence 378.21
- Stylomandibular ligament 60.9
- Stylo mastoid
 artery 196.23
 foramen 14.27
 vein 236.31
- Subacromial bursa 102.8
- Subaortic common iliac lymph nodes 264.19
- Subapical
 segment
 of lower lobe of left lung 150.23
 of lower lobe of right lung 150.11
 segmental bronchus 146.11, 146.23
- Subarachnoid
 cisterns 270.4
 space 270.2, 270.14
- Subarcuate fossa 14.14
- Subcallosal area 312.4
- Subclavian
 artery 206.1
 groove for 6.19
 groove 34.30
 plexus 352.11
 triangle 398.31
 trunk, right/left 254.13
 vein 244.9
 groove for 6.20
- Subcommissural organ 296.19
- Subcostal
 artery 216.16
 muscles 84.20
 nerve 340.26
 plane 398.2
 vein 246.12
- Subcutaneous
 abdominal veins 234.16
 bursa 405.31
 infrapatellar 104.21
 of laryngeal prominence 102.3
 of lateral malleolus 106.7
 of medial malleolus 106.8
 of olecranon 102.15
 prepatellar 104.17
 of tibial tuberosity 104.23
 trochanteric 104.5
 calcaneal bursa 106.17
 part of external anal sphincter 174.15
 tissue 390.19
- Subdeltoid bursa 102.9
- Subdural space 268.30
- Subendocardial rami 186.12a
- Subfascial
 bursa 405.33
 prepatellar bursa 104.18
- Subformal organ 296.18
- Subhepatic recess 180.10
- Subiculum promontorii 378.27
- Sublenticular part of internal capsule 318.21
- Sublingual
 artery 196.3
 ducts
 major 110.3
 minor 110.4
 fold 108.27
 fovea 26.24
 ganglion 328.29, 352.33
 gland 110.2
 nerve 326.5
 papilla 108.26
 vein 234.31
- Submandibular
 duct 110.6
 fovea 26.25
 ganglion 326.8, 328.26, 352.32
 gland 110.5
 lymph nodes 256.16
 triangle 398.24
- Submental
 artery 196.10
 lymph nodes 256.15
 triangle 398.27
 vein 236.17
- Submucosa 118.16
- Submucosal plexus 350.6
- Submuscular bursa 405.32
- Suboccipital
 nerve 334.18
 part of vertebral artery 206.7
 venous plexus 234.12
- Subparietal sulcus 310.6
- Subphrenic recess 180.9
- Subpopliteal recess 106.2
- Subpubic angle 44.23
- Subpyloric nodes 262.20
- Subscapular
 artery 212.20
 branches of axillary artery 212.10
 fossa 34.5
 lymph nodes 258.19
 nerves 340.11
 vein 244.13a
- Subserosal plexus 350.4
- Substantia(-ae)
 adamantina 112.10
 alba 274.14, 276.17, 406.52
 compacta 402.35
 corticalis 402.34
 eburnea 112.9
 gelatinosa 276.7, 406.54
 centralis 274.15
 grisea 274.13, 406.51
 centralis 292.11
 intermedia centralis 276.12
 intermedia lateralis 276.13

Substantia(-ae)
 lentis 362.11
 muscularis (prostate) 162.22
 nigra 292.7
 perforata
 anterior 312.2
 interpeduncularis 290.33
 propria 356.9
 sclerae 354.32
 reticularis 280.27, 292.22,
 406.53
 spongiosa 402.36
 trabecularis 402.36
 visceralis secundaria 276.8
 Subtalar joint 70.13
 Subtendinous
 bursa 405.34
 of infraspinatus muscle
 102.11
 of latissimus dorsi muscle
 102.14
 of obturator internus muscle
 104.11
 of sartorius muscle 104.24
 of subscapularis muscle
 102.12
 of teres major muscle 102.13
 of tibialis anterior 106.16
 of trapezius 102.6
 of triceps brachii 102.17
 iliac bursa 104.15
 prepatellar bursa 104.19
 Subthalamic
 fasciculus 306.6
 nucleus 300.17
 Sudoriferous glands 394.11
 Sulcomarginal fasciculus 276.21
 Sulcus(-i)
 ampullaris 370.22
 anterolateralis 272.22, 278.21
 antehiclis transversus 388.4
 arteriae
 meningeae mediae 16.26b
 occipitalis 12.20
 subclaviae 6.19
 temporalis mediae 16.15
 vertebralis 4.9
 arteriales 30.8
 auricularis posterior 386.28
 basilaris 284.4
 bicipitalis
 lateralis 400.27
 medialis 400.28
 bulbo-pontines 284.3
 calcanei 50.29
 calcarinus 310.12
 caroticus 10.11
 carpi 40.15
 centralis 306.16
 insulae 308.30
 cerebrales 306.5
 cinguli (cingulatus) 310.5
 circularis insulae 308.31
 collateralis 310.18
 coronarius 184.20

Sulcus(-i)
 corporis callosi 310.2
 costae 6.17
 cruris helices 388.5
 cutis 390.3
 ethmoidalis 20.27
 frontalis
 inferior 306.29
 superior 306.27
 gingivalis 108.25
 glutealis 402.3
 habenuale (habenularis)
 296.5
 hamuli pterygoidei 12.11
 hippocampi (hippocampalis)
 310.14
 hypothalamicus 298.2
 infraorbitalis 22.6
 interlobares 306.21
 intermedius posterior 272.24
 intertubercularis 36.8
 interventricularis
 anterior 184.18
 posterior 184.19
 intraparietalis 308.5
 lacrimalis 20.23, 22.18, 32.22a
 lateralis 306.17
 limitans 286.25
 lunatus 308.13
 malleolaris 48.11, 48.30a
 matricis unguis 392.23
 medianus 286.22
 linguae 114.10
 posterior 272.20, 280.8
 musculi subclavii 34.30
 mylohyoideus 28.9
 nervus(-i)
 petrosi
 majoris 12.6
 minoris 12.7
 radialis 36.15
 spinalis 2.22
 ulnaris 36.29
 obturatorius 44.17
 occipitalis transversus 308.12
 occipitotemporalis 310.21
 oculomotorius 290.31
 olfactorius 136.10, 310.24
 orbitales 310.26
 palatinus(-i) 24.7
 major 22.23, 24.20
 palatovaginalis 12.8
 paracolici 180.8
 parieto-occipitalis 310.10
 popliteus 46.25a
 postcentralis 308.2
 posterolateralis 272.23, 280.1
 precentralis 306.24
 prechiasmaticus 10.4
 promontorii 378.26
 pterygopalatinus 22.23, 24.20
 pulmonalis thoracis 6.38
 retro-olivaris 278.25
 rhinalis 310.19
 sclerae 354.25

Sulcus(-i)
 sinus
 occipitalis 8.33a
 petrosi
 inferioris 8.7, 14.18
 superioris 14.10
 sagittalis superioris 8.31,
 16.26a, 18.16, 28.26
 sigmoidei 8.33, 12.19, 16.26
 transversus 8.32
 spiralis
 externus 372.29
 internus 372.28
 subparietalis 310.6
 supraacetabularis 42.12
 tali 50.13
 temporalis(-es)
 inferior 308.23
 superior 308.21
 transversus 308.17
 tendinis musculi
 flexoris hallucis longi 50.18,
 50.28
 peronei (fibularis) longi 52.4,
 52.13
 terminalis 186.16
 linguae 114.11
 tubae auditoriae (auditivae)
 10.39
 tympanicus 16.7
 venae
 caevae 128.30
 subclaviae 6.20
 venosi 30.7
 vomeris 20.30
 vomerovaginalis 12.9
 Supercilia 392.4
 Superciliary arch 18.5
 Supercilium 366.1
 Superficial 396.31
 brachial artery 212.26
 branch
 lateral plantar nerve 346.13
 medial
 circumflex femoral artery
 226.3a
 plantar artery 228.20
 radial nerve 340.8
 superior gluteal artery
 222.20
 transverse cervical artery
 210.23
 ulnar nerve 338.22
 cerebral veins 240.10
 circumflex iliac
 artery 224.31
 vein 252.3
 dorsal
 sacrococcygeal ligament
 56.22
 veins of clitoris 252.5
 veins of penis 252.5
 epigastric
 artery 224.30
 vein 252.4

- Superficial
 fascia 405.26a
 of penis 164.20
 head of flexor pollicis brevis 92.3
 inguinal
 lymph nodes 266.14
 ring 86.14
 lamina of levator tendon 364.15
 layer
 of cervical fascia 82.22
 temporal fascia 80.21
 lymph nodes 256.18, 258.2, 258.27
 lymphatic vessel 254.7
 middle cerebral vein 240.18
 palmar
 arch 214.27
 branch, radial artery 214.4
 venous arch 244.30
 parotid lymph nodes 256.5
 part
 of external anal sphincter 174.16
 of parotid gland 110.8
 perineal
 fascia 176.12
 space 176.8
 peroneal (fibular) nerve 344.21
 plantar arch 228.26a
 popliteal lymph nodes 266.19
 temporal
 artery 198.1
 rami 324.30
 veins 236.19
 transverse
 metacarpal ligament 92.23
 metatarsal ligament 100.19
 vein 406.48
 Superficialis 396.31
 Superior 396.19
 aberrant ductules 160.8
 alveolar nerve 324.2
 anastomotic vein 240.19
 angle (scapula) 34.19
 anterior segmental artery 220.21
 aperture 88.23
 articular
 facet 4.3
 process 2.14, 4.20
 surface, tibia 46.28
 auricular ligament 388.12
 basal vein 230.22, 232.9
 border petrous temporal 14.9
 branch(-es)
 to inferior lobe of right pulmonary artery 190.23
 inferior right pulmonary vein 230.17
 left inferior pulmonary vein 232.5
 superior gluteal artery 222.22
 transverse cervical nerve 336.2
 Superior
 bulb of jugular vein 234.22
 bursa of biceps femoris 104.16
 cerebellar
 artery 206.23
 peduncle 290.26, 292.19
 decussation 294.8
 cerebral veins 240.11
 cervical
 cardiac
 branches of vagus nerve 332.9
 nerve 352.4
 ganglion 350.27
 choroid vein 242.3
 clunial (gluteal) branches 342.5
 colliculus 292.15
 brachium 292.17, 294.23, 300.28
 commissure 294.24
 gray and white layers 294.22
 costal fovea 2.25
 costotransverse ligament 58.16
 deep lymph nodes 258.3
 dental
 arch 112.18
 branches of infraorbital nerve 324.7
 plexus 324.6
 duodenal
 flexure 124.7
 fold 178.28
 recess 178.29
 end of testis 158.17
 epigastric
 artery 210.12
 veins 234.15
 extensor retinaculum 100.11
 fascia
 of pelvic diaphragm 174.26
 of urogenital diaphragm 176.5
 fornix of conjunctiva 368.3
 fovea 286.27
 frontal
 gyrus 306.26
 sulcus 306.27
 ganglion 330.18, 332.2
 gingival branches of infraorbital nerve 324.8
 gluteal
 artery 222.19
 lymph nodes 266.2
 nerve 342.5, 344.12
 veins 250.2
 horn
 calciform margin 100.5
 thyroid cartilage 138.22
 hypogastric plexus 350.9
 hypophysial artery 200.25
 ileocecal recess 180.2
 labial
 artery 196.13
 branches of infraorbital nerve 324.12
 vein 236.12
 Superior
 laryngeal
 artery 194.13
 nerve 332.10
 vein 236.4
 lateral brachial cutaneous nerve 340.15
 ligament
 of epididymis 162.4
 of incus 382.26
 of malleus 382.24
 lingular
 bronchus 146.19
 segment of upper lobe of left lung 150.18
 longitudinal
 fasciculus 316.16
 muscle of tongue 114.23
 lymph nodes 264.3
 macular arteriole/venule 360.12
 margin
 adrenal gland 182.33
 cerebral hemisphere 306.10
 scapula 34.15
 mediastinum 152.25
 medullary velum 288.2
 mesenteric
 artery 220.1
 ganglion 348.14
 plexus 348.28
 vein 248.20
 nasal
 arteriole/venule of retina 360.10
 concha 20.14, 136.11
 meatus 32.4, 136.20
 nuchal line 8.26
 oblique muscle 364.10
 olivary nucleus 286.7
 ophthalmic vein 242.25
 orbital fissure 10.22, 32.23
 palpebral
 arch 202.18
 veins 236.9
 pancreatic lymph nodes 262.23
 pancreaticoduodenal lymph nodes 262.27
 parathyroid gland 182.11
 parietal lobule 308.4
 part
 of duodenum 124.2
 of left superior pulmonary vein 232.2
 of masseter muscle 80.13
 peroneal (fibular) retinaculum 100.14
 petrosal
 sinus 238.20
 groove for 14.10
 pharyngeal constrictor muscle 118.22
 phrenic
 arteries 216.7
 lymph nodes 260.6
 veins 246.9

- Superior
 pubic ligament 66.16
 ramus
 oculomotor nerve 320.6
 of pubis 44.13
 recess of tympanic membrane 384.9
 rectal
 artery 220.15
 lymph nodes 264.13
 plexus 350.2
 vein 248.36
 rectus muscle 364.4
 right pulmonary veins 230.3, 230.4
 sagittal sinus 238.14
 groove for 8.31, 16.26a, 18.16, 28.26
 salivary (salivatory) nucleus 286.5
 segment
 of kidney 154.17
 of lower lobe of left lung 150.22
 of lower lobe of right lung 150.10
 segmental
 artery 220.20
 bronchus 146.10, 146.22
 semicircular
 canal 376.7
 duct 370.12
 semilunar lobule 288.33
 suprarenal arteries 216.21
 surface of talus 50.8
 synovial membrane 60.6
 tarsal
 muscle 366.22
 plate 366.16
 temporal
 arteriole/venule of retina 360.8
 gyrus 308.19
 line 16.28
 sulcus 308.21
 thalamostriate vein 242.4
 thoracic
 aperture 6.36
 artery 212.11
 thyroid
 artery 194.10
 notch 138.17
 tubercle 138.19
 vein 236.1
 tracheobronchial lymph nodes 260.14
 transverse scapular ligament 60.14
 tympanic artery 198.19
 ulnar collateral artery 212.32
 vein(-s)
 of cerebellum 242.22
 of vermis 242.19
 vena cava 232.27
 opening 186.23
- Superior
 vesical arteries 222.29
 vestibular
 area 378.12
 nucleus 286.12
 wall 32.17
 Superolateral
 lymph nodes 266.16
 surface of cerebral hemisphere 306.15
 Superomedial lymph nodes 266.15
 Supinator crest 38.31
 Supra-acetabular sulcus 42.12
 Supra-orbital
 vein 236.8
 Suprachoroid lamina 356.14
 Supraclavicular
 lymph nodes 258.11
 nerves 336.4
 intermediate 336.6
 lateral (posterior) 336.7
 medial 336.5
 part of brachial plexus 336.19
 triangle 398.31
 Supracondylar
 line
 lateral 46.20b
 medial 46.20a
 process 36.18
 ridge
 lateral 36.20
 medial 36.17
 Supracostal branch of posterior
 intercostal
 arteries 216.13
 Supracristal plane 398.4
 Supraduodenal artery 218.14
 Supraglenoid tubercle 34.22
 Suprahyoid
 branch of lingual artery 196.2
 triangle 398.27
 Supramarginal gyrus 308.8
 Supramastoid crest 16.17
 Suprameatal
 pit 16.18
 spine 16.19
 Supraoptic
 commisure
 dorsal 304.12
 ventral 304.13
 fibers 304.21
 nucleus 302.18
 Supraopticohypophysial tract 304.23
 Supraorbital
 artery 202.13
 border/margin
 frontal bone 18.7
 orbit 32.15
 nerve 320.24
 notch/foramen 18.8
 Suprapatellar bursa 104.20
 Suprapleural membrane 152.9
 Suprapyloric node 262.19
- Suprarenal
 arteries
 inferior 220.18
 middle 220.16
 superior 216.21
 gland 182.29
 accessory 182.39
 impression 130.13
 plexus 348.22
 vein
 left 246.29
 right 246.32
 Suprascapular
 artery 212.1
 nerve 336.23
 vein 238.6
 Supraspinal
 ligaments 56.17
 recess 298.7
 Supraspinous fossa 34.8
 Suprasternal bones 6.34
 Supratonsillar fossa 116.16
 Supratragic tubercle 386.29
 Supratrochlear
 artery 202.20
 lymph nodes 258.26
 nerve 320.27
 veins 236.7
 Supravaginal part of cervix 168.16
 Supraventricular crest 188.7
 Supravesical fossa 180.14
 Supreme
 intercostal, vein 234.19
 nuchal line 8.25
 Sura 402.15
 Sural
 arteries 226.17
 nerve 346.5
 veins 252.13a
 Suspensory
 ligament
 of breast 394.31
 of ovary 180.28
 of penis (clitoris) 86.25
 of vermiform appendix 178.9
 muscle of duodenum 124.10
 Sustentaculum tali 50.27
 Sutura(-ae) 404.14
 coronalis 54.2
 craii (craniales) 54.1
 ethmoidolacrimalis 54.21
 ethmoidomaxillaris 54.20
 frontalis 18.6a, 54.11
 frontoethmoidalis 54.15
 frontolacrimalis 54.17
 frontomaxillaris 54.16
 frontonasalis 54.14
 frontozygomata 54.18
 incisiva 24.5
 intermaxillaris 54.30
 internasalis 54.26
 lacrimoconchalis 54.29
 lacrimomaxillaris 54.28
 lamdoidea 54.4

- Sutura(-ae)
 metopica 18.17a, 54.11
 nasomaxillaris 54.27
 occipitomastoidea 54.5
 palatina
 mediana 54.33
 transversa 54.34
 palatoethmoidalis 54.32
 palatomaxillaris 54.31
 parietomastoidea 54.12
 plana 404.17
 sagittalis 54.3
 serrata 404.15
 sphenoeethmoidalis 54.7
 sphenofrontalis 54.6
 sphenomaxillaris 54.24
 sphenoparietalis 54.9
 sphenosquamosa 54.8
 sphenomeriana 54.22
 sphenozygomatica 54.23
 squamosa 54.10, 404.16
 squamosomastoidea 54.13
 temporozygomatica 54.25
 zygomaticomaxillaris 22.13, 54.19
- Sutural bones 30.9
- Suture 404.14
 dentate 404.15
 flat 404.17
- Sweat glands 394.10
 duct 394.13
 eccrine 394.11
 merocrine 394.11
 pore 394.14
- Sympathetic
 branch to submandibular ganglion 328.27
 ganglion 407.19
 root
 internal carotid plexus 320.11
 pterygopalatine ganglion 322.16b
 system 350.21
 trunk 350.22
 ganglia 350.23
- Symphyseal surface (pubis) 44.11
- Symphysis 404.21
 intervertebral 56.9
 mandibulae (medialis) 26.14
 menti 26.14
 pubica 66.15
- Synchondrosis(-es) 404.21
 cranii (craniales) 56.1
 intraoccipitalis 56.4a
 anterior 56.6
 posterior 56.5
 manubriosternalis 6.29
 petro-occipitalis 56.4
 sphenoeethmoidalis 56.7
 sphenoeoccipitalis 52.2
 sphenopetrosa 56.3
 sternales 6.28
 sternocostalis costae primae 58.26a
 xiphisternalis 6.30
- Syndesmosis 404.13
 radioulnaris 62.9
 tibiofibularis 68.23
 tympanostapedialis 382.21
- Synovia 404.43
- Synovial
 bursa(-ae) 100.19a, 405.30
 of lower limb 104.4a
 of tensor veli palatini 102.2
 of trochlea 364.12
 of upper limb 102.5a
 fold 404.41
 infrapatellar 68.10
 joints 404.22
 layer, tendon sheath 405.20
 membrane 404.40
 inferior 60.7
 superior 60.6
 sheath(-s) 405.18
 of fingers 92.30
 of tendon 405.20a
 of toes 100.19a, 100.20
 villi 404.42
- Systema
 alimentarium 108.1
 conducens cordis 186.7a
 lymphaticum 254.1
 nervosum 268.21
 centrale 272.12, 406.50
 periphericum 320.1, 407.1
 respiratorium 134.17
 skeletale 402.30
 urogenitale 154.1
- Systema nervorum autonomicum 348.1
- T**
- Tactile
 corpuscles 390.24
 elevations 390.6
 menisci 390.26
- Taenia(-ae)
 choroidea 314.10
 coli 126.3
 fornix 312.24
 libera 126.6
 mesocolica 126.4
 omentalis 126.5
 thalami 298.9
 ventriculi quarti 288.7
- Tail
 of caudate nucleus 316.25
 of epididymis 160.4
 of helix 386.14
 of pancreas 128.13
- Talocalcaneal ligament
 interosseus 70.20
 lateral 70.14
 medial 70.15
 posterior 70.15a
- Talocalcaneonavicular joint 70.12
- Talocrural
 joint 70.1
- Talocrural
 region
 anterior 402.16
 posterior 402.16
- Talofibular ligament
 anterior 70.7
 posterior 70.8
- Talonavicular ligament 70.24
- Talus 50.3
 body 50.6
 facet
 anterior 52.1
 middle 52.2
 posterior 52.3
 head 50.4
 lateral process 50.11
 neck 50.5
 posterior process 50.17
 sulcus 50.13
- Tangential fibers 316.9
- Tapetum 312.14
- Tarsal
 arteries
 dorsal 228.5
 lateral 228.2
 medial 228.3
 bones 50.2
 glands 366.21
 joint, transverse 70.16
 plate
 inferior 366.17
 superior 366.16
- Tarsometatarsal
 joints 72.9
 ligaments
 dorsal 72.10
 plantar 72.11
- Tarsus 50.1, 402.23
 inferior 366.17
 superior 366.16
- Taste
 bud 388.27
 pore 388.28
- Tectal lamina 292.13, 294.18
- Tectobulbar tract 294.11
- Tectorial membrane 58.8, 372.26
- Tectospinal tract 276.32, 280.22, 284.22, 294.12
- Tectum mesencephalicum 292.12, 294.17
- Teeth 110.12
- Tegmen
 tympani 14.2
 ventriculi quarti 288.1
- Tegmental
 nuclei 294.2
 tract, central 294.26
 wall 378.17
- Tegmentum
 decussationes 294.7
 mesencephalicum 292.10
 pontis 284.17
- Tela
 choroidea
 ventriculi

- Tela
 choroidea
 ventriculi
 quarti 272.2, 288.5
 tertii 272.4, 298.8
 subcutanea 390.19
 submucosa 405.44
 (bronchus) 148.3
 (colon) 126.8
 (esophagus) 120.11
 (pharynx) 118.16
 (small intestine) 122.26
 (stomach) 122.10
 (urinary bladder) 158.8
 subserosa 122.4, 406.1
 (gallbladder) 134.6
 (liver) 130.31
 (perimetrium) 168.27
 (peritoneum) 176.25
 (urinary bladder) 158.2
 (uterine tube) 168.2
- Telencephalon 306.1
 sections 314.19a, 316.1
- Temporal
 arteriole/venule of retina
 inferior 360.9
 superior 360.8
 artery
 anterior 204.26
 deep 198.25
 middle 198.6, 204.27
 groove for 16.15
 posterior 198.25a, 204.28
 superficial 198.1
 bone 12.14
 petrous part 12.15
 anterior surface 14.1
 apex 12.25
 inferior surface 14.23
 posterior
 border 14.17
 surface 14.11
 superior border 12.9
 squamous part 16.10
 tympanic part 16.1
 zygomatic process 16.16
 branches of facial nerve 328.13
 crest 28.10a
 fascia 80.21
 fossa 30.11
 gyrus(-i)
 inferior 308.24
 middle 308.22
 superior 308.19
 transverse 308.18
 line
 of frontal bone 18.12
 inferior 16.29
 superior 16.28
 lobe 308.15
 nerves, deep 324.16
 operculum 308.20
 pole 308.16
 process 26.5
 rami, superficial 324.30
- Temporal
 region 398.13
 sulcus(-i)
 inferior 308.23
 superior 308.21
 transverse 308.17
 surface 10.25, 16.14, 18.10, 26.3
 veins
 deep 236.25
 middle 236.20
 superficial 236.19
- Temporomandibular
 joint 60.2
 ligament 60.4
- Temporopontine fibers 318.25
- Temporozygomatic suture 54.25
- Tendinous
 arch 405.28
 of levator ani muscle 174.11
 of pelvic fascia 174.27
 of soleus muscle 96.18
 intersections 86.3, 405.27
- Tendo 405.17
 calcaneus 96.19
 conjunctivus 86.21
 cricoesophageus 120.8
 infundibuli 186.6a
 intermedius 405.27a
- Tendon 405.17
 of lateral rectus at greater
 wing 364.18
 sheath 405.18
 of abductor pollicis longus
 102.20
 of extensor
 carpi radialis brevis 102.21
 carpi radialis longus 102.21
 carpi ulnaris 102.25
 digiti minimi 102.24
 digitorum 102.23
 digitorum longus 106.11
 hallucis longus 106.10
 indicus 102.23
 pollicis brevis 102.20
 pollicis longus 102.22
 of flexor
 carpi radialis 104.1
 digitorum longus 106.12
 hallucis longus 106.14
 pollicis longus 104.3
 for flexors
 in region of fingers 104.4
 of the toes 106.20
 of peroneus longus 106.19
 of superior oblique muscle
 102.1, 364.12
 of tibialis
 anterior 106.9
 posterior 106.13
- Tenia(-ae)
 choroidea 314.10
 of fornix 312.24
 of fourth ventricle 288.7
 of thalamus 298.9
- Tenon's capsule 364.21
- Tensor tympani muscle, semi-
 canal 12.29
- Tentorial
 branch of ophthalmic nerve
 320.20
 notch 268.28
- Tentorium cerebelli 268.25
- Terminal
 crest 186.17
 ganglion 352.29
 groove 186.16
 line 44.26
 nerve 352.27
 corpuscles 390.21
 notch 388.2
 part of middle cerebral artery
 204.29
 phalanx 40.27
 portion of posterior cerebral
 artery 208.1
 secretory part of sweat gland
 394.12
 ventricle 272.18
- Termini generales 396.1
- Testicular
 artery 222.1
 plexus 348.26
 vein
 left 246.30
 right 246.33
- Testis 158.16
 descent of 162.7
 lobules 158.27
 septa 158.26
- Textus nervosus 408.17
- Thalamic
 branch(-es)
 posterior cerebral artery
 206.28
 posterior communicating
 artery 208.21
 fasciculus(-i) 300.21, 302.5
 peduncle, inferior 302.8
 radiations
 anterior 302.1, 318.9
 central 302.2
 posterior 302.3, 318.27
 tract 300.21
- Thalamolentiform part of inter-
 nal capsule 318.14
- Thalamoparietal fibers 318.19
- Thalamostriate veins
 inferior 240.26
 superior 242.4
- Thalamus
 anterior nuclei 298.13
 dorsal 296.20
 medial nuclei 298.21
 median nuclei 198.17
 paratenial nucleus 298.20a
 reticular nucleus 298.12,
 298.24, 300.18
 sections 298.11
 tenia 298.9
 ventralis(subthalamus) 296.29

- Theca(-ae)
 externa 166.21
 folliculi 166.20
 interna 166.22
- Thenar eminence 400.40
- Thigh
 bone 46.2
 region 402.4
 anterior 402.5
 posterior 402.7
- Third occipital nerve 334.20
- Thoracic
 aorta 216.2
 aortic plexus 348.4
 artery
 internal 210.1
 lateral 212.18
 superior 212.11
 bones 6.1
 cardiac branches
 thoracic ganglia 352.15
 vagus nerve 332.20
 cavity 6.35a, 152.6
 column 276.14
 duct 254.17
 arch 254.18
 right 254.16
 fascia 84.22
 ganglia 352.14
 inlet 6.36
 muscles 84.1
 nerves 340.16
 long 336.21
 outlet 6.37
 part
 of esophagus 120.4
 of thoracic duct 254.20
 of trachea 144.19
 pulmonary
 branches 352.15a
 sulcus 6.38
 segment of spinal cord 274.7
 skeleton 6.35
 splanchnic ganglion 352.17
 vein(-s)
 internal 234.14
 lateral 244.14
 vertebrae 2.24
- Thoracoacromial
 artery 212.12
 vein 244.12, 244.21
- Thoracodorsal
 artery 212.21
 nerve 340.12
 vein 244.13a
- Thoracoepigastric veins 244.15
- Thoracolumbar fascia 76.20
- Thorax 6.1
 joints 56.8, 58.9
- Thumb 400.44
 carpometacarpal joint 64.10
- Thymic
 branches (internal thoracic
 artery) 210.3
 lobules 182.26
- Thymic
 veins 234.1
- Thymus 182.23
 cortex 182.27
 medulla 182.28
 right/left lobe 182.24
- Thyroarytenoid muscle 142.20
- Thyrocervical trunk 210.13
- Thyroepiglottic
 ligament 142.7
 muscle 142.19
 part of thyroarytenoid muscle
 142.20a
- Thyroglossal duct 114.13
- Thyrohyoid
 branch of ansa cervicalis 334.26
 ligament, lateral 138.27
 membrane 138.25
 median 138.26
- Thyroid
 artery
 inferior 210.14
 superior 194.10
 cartilage 138.14
 articular surface for 140.5
 foramen 138.24
 gland 182.2
 accessory 182.6
 isthmus 182.4
 lymph nodes 256.21
 notch
 inferior 138.18
 superior 138.17
 tubercle
 inferior 138.20
 superior 138.19
 veins
 inferior 232.30
 middle 236.2
 superior 236.1
- Tibia 46.27
 shaft 48.1
- Tibial 396.40
 artery
 anterior 226.22
 posterior 228.8
 collateral ligament 68.13
 margin of foot 402.22
 nerve 346.1
 node
 anterior 266.21
 posterior 266.22
 tuberosity 48.2
 veins
 anterior 252.16
 posterior 252.21
- Tibialis 396.40
- Tibiocalcaneal part of medial
 (deltoid) ligament 70.4
- Tibiobifibular
 joint 68.20, 68.23
 ligament
 anterior 68.25
 posterior 68.26
 syndesmosis 68.23
- Tibionavicular part of medial
 (deltoid) ligament 70.3
- Tibiotalar part of medial (del-
 toid) ligament
 anterior 70.5
 posterior 70.6
- Toes 52.23, 402.25
 big toe 402.26
 little toe 402.28
- Tongue 112.28
 apex 112.37
 body 112.29
 frenulum 114.2
 median groove 114.10
 mucous membrane 114.1
 musculature 114.18
 root 112.30
- Tonsilla(-ae)
 cerebelli 288.38
 lingualis 114.14
 palatina 116.9
 pharyngealis 116.27
 tubaria 118.6
- Tonsillar
 branch(-es)
 ascending palatine artery
 196.9
 glossopharyngeal nerve
 330.29
 lesser palatine nerves
 322.24a
 posterior inferior cerebellar
 artery 206.14
 crypts 116.11, 116.29
 fossa 116.15
 pits 116.10, 116.28
- Toruli tactiles 390.6
- Torus
 levatorius 118.5
 mandibularis 26.23
 palatinus 30.27
 tubarius 118.3
- Trabecula(-ae)
 carnae 186.1, 190.1a
 corporis spongiosi 164.15
 corporum cavernosorum
 164.14
 septomarginalis 188.19
 splenicæ (lienales) 268.15
- Trabecular
 bone 402.36
 meshwork 354.27
- Trachea 144.17
 bifurcation 144.24
- Tracheal
 branches
 inferior thyroid artery
 210.19
 internal thoracic artery
 210.4a
 vagus nerve 332.16
 cartilages 144.20
 glands 144.27
 muscle 144.21
 veins 234.6

- Tracheobronchial lymph nodes
260.13
inferior 260.16
superior 260.14
- Tractus
bulboreticulospinalis
276.30
corticonuclearis 318.12
corticospinalis (pyramidalis)
anterior 276.22
lateralis 276.28
dentatothalamicus 302.4
dorsolateralis 278.5
frontopontinus 318.10
habenulointerpeduncularis
296.12
hypothalamicus 304.10
hypothalamohypophysialis
304.20
iliotibialis 98.14
laterale 74.10a
mediale 76.1
mesencephalicus nervi tri-
geminalis 284.29, 292.26
olfactorius 310.28
olivocerebellaris 282.3
olivocochlearis 286.8
olivospinalis 276.33, 282.1
opticus 296.33
paraventriculohypophysialis
304.24
pontoreticulospinalis 276.31
reticulospinalis 276.24
rubrospinalis 276.29,
294.10
solitarius 282.9
spinalis nervi trigeminalis
280.25, 284.25
spino-olivaris 278.6, 282.2
spinocerebellaris
anterior 278.3
posterior 278.4
spinoreticularis 278.7
spinotectalis 278.1
spinothalamicus 278.2
anterior 276.25
spiralis foraminosus 378.11
supraopticohypophysialis
304.23
tectobulbaris 294.11
tectospinalis 276.32, 280.22,
284.22, 294.12
tegmentalis centralis 294.26
thalamici 300.21
trigeminothalamicus 284.28
uvealis 356.12
vestibulospinalis 276.23
- Tragus(-i) 386.23, 392.7
- Transpyloric plane 398.3
- Transversalis 396.9
fascia 86.28
- Transverse 396.9, 396.28
arytenoid muscle 142.22
branch of lateral circumflex
femoral artery 226.11
- Transverse
cervical
artery 210.22
nerve 336.1
veins 238.7
colli nerve 336.1
colon 124.28
costal fovea 2.27
crest 378.8
diameter (pelvis) 44.31
ductules of epophoron
170.19
facial
artery 198.3
vein 236.21
fasciculi 92.25, 100.18
fissure of cerebrum 306.8
head
of adductor hallucis 98.5
of adductor pollicis 92.8
ligament
of axis 58.7
of knee 68.6
lines 4.25
mesocolon 178.5
muscle of tongue 114.25
occipital sulcus 308.12
palatine
folds 108.29
suture 54.34
part
of nasal muscle 78.14
of portal vein of liver 248.6
perineal ligament 176.7
pontine fibers 284.14
process 2.12
rectal folds 126.23
ridge, tooth 110.17
sinus 238.9
groove for 8.32
of pericardium 184.8
sulcus of anthelix 388.4
tarsal (midtarsal) joint 70.16
temporal
gyri 308.18
sulci 308.17
vesical fold 180.20
- Transversus 396.28
- Trapezium 40.9
tubercle 40.10
- Trapezoid 40.11
body 286.14
anterior nucleus 286.15
posterior nucleus 286.16
ligament 60.20
line 34.34
- Triangular
fold 116.13
fossa 386.16
eminence 388.9
fovea 140.18
ligament
left 178.24
right 178.23
muscle 405.7
- Triangular
part of inferior frontal gyrus
306.33
ridge, tooth 110.18
- Tricuspid valve, right 188.3
- Trigeminal
ganglion 320.17
impression 12.8
lemniscus 284.28, 294.16, 300.25
nerve 320.15
mesencephalic
nucleus 284.30
tract 284.29, 292.26
motor nucleus 286.1
pontine nucleus 284.27
sensory root 320.16
spinal
nucleus 280.26, 284.26
tract 280.26, 284.25
tubercle 280.3
- Trigeminothalamic tract 284.28
- Trigonum
caroticum 398.25
cervicalis
anterior 398.23
posterior 398.30
claviopectoralis 398.36
collaterale 314.15
femorale 98.23, 402.6
fibrosum dextrum/sinistrum
186.5
habenulae (habenulare) 296.6
inguinale 180.17
lemnisci 292.18
lumbale 86.27
lumbare 400.14
muscularis 398.26
nervi
hypoglossi 286.31
vagi 286.33
olfactorium 310.29
omoclaviculare 398.31
omotracheale 398.26
pontocerebellare 284.6
submandibulare 398.24
submentale 398.27
vesicae 158.10
- Triquetrum 40.7
- Trochanter
major 46.6
minor 46.8
tertius 46.9
- Trochanteric
bursa(-ae)
of gluteus maximus 104.6
of gluteus medius 104.7
of gluteus minimus 104.8
fossa 46.7
- Trochlea 364.11
humeri 36.24
muscularis 405.29
peronealis (fibularis) 52.5
of phalanx 40.31
synovial bursa 364.12
tali (talare) 50.7

Trochlear

- fovea 18.24
- nerve 320.13
 - decussation 294.25, 320.14
 - nucleus 292.30
 - notch 38.22
 - spine 18.23

Trochoidal joint 404.30

True ribs 6.3

Truncus(-i) 186.11, 312.8

- brachial plexus 336.13
- brachiocephalicus 194.4
- bronchomediastinalis dexter/ sinister 254.12
- coeliacus 216.28
- costocervicalis 212.3
- encephali 278.15
- inferior 336.16
- intestinales 254.11
- jugularis dexter/sinister 254.14
- linguofacialis 196.6
- lumbaris dexter/sinister 254.10
- lumbosacralis 344.7
- lymphatici 254.9
- medius 336.15
- nervi
 - accessorii 332.34
 - spinalis 334.8
 - pulmonalis 190.11
 - subclavialis dexter/sinister 254.13
 - superior 336.14
 - sympatheticus 350.22
 - thyrocervicalis 120.13
 - vagalis
 - anterior 332.24
 - posterior 332.25

Trunks 312.8

- brachial plexus 336.13
- upper 336.14

Tuba

- auditoria (auditiva) 384.13
- uterina 166.29

Tubal

- branch(-es)
 - ovarian artery 222.4a
 - tympanic plexus 330.23
 - uterine artery 224.5
- extremity 166.12
- tonsil 118.6

Tuber(-a)

- calcanei 50.23
- cinereum 296.37
- frontale 18.4
- ischiadicum (ischiale) 44.4
- maxillare 22.17
- omentale 128.12, 130.7
- parietale 16.30
- of vermis 288.28

Tuberal nuclei 302.23

Tuberculum(-a)

- adductorium 46.23
- anterior 2.19
- atlantis 4.7
- thalamicum 296.22

Tuberculum(-a)

- articulare 16.22
- auriculare 386.26
- calcanei 50.26
- caroticum 2.21
- conoideum 34.33
- corniculatum 140.29, 142.9
- costae 6.14
- cuneatum 280.5
- cuneiforme 142.2
- dentis 110.16
- dorsale 38.15
- epiglotticum 142.5
- gracile 280.7
- iliacum 42.17
- infraglenoidale 34.21
- intercondylare
 - laterale 46.36
 - mediale 46.35
- intervenosum 186.25
- jugulare 8.18
- laterale (talus) 50.20
- lip 108.8
- majus (humerus) 36.6
- marginale 26.7
- mediale (talus) 50.19
- mentale 26.16
- minus (humerus) 36.7
- musculi scaleni anterioris 6.18
- obturatorium
 - anterior 44.18
 - posterior 44.19
- ossis
 - scaphoidei 40.5
 - trapezii 40.11
- pharyngeum 8.8
- posterior 2.20, 4.10
- pubicum 44.10
- quadratum 46.10a
- sellae 10.6
- supraglenoidale 34.22
- supratragicum 386.29
- thyroideum
 - inferius 138.20
 - superior 138.19
- trigeminale 280.3

Tuberositas(-tes)

- deltoides 36.21
- glutealis 46.17
- iliaca 42.31
- ligamenti coracoclavicularis 34.31a
- masseterica 28.4
- musculi serrati anterioris 6.21
- ossis
 - cuboidei 52.14
 - metatarsalis
 - primi (I) 52.21
 - quinti (V) 52.22
 - navicularis 52.8
- phalangis distalis 40.28, 52.28
- pronatoria 38.11a
- pterygoidea 28.5
- radii 38.7
- sacralis 4.23

Tuberositas(-tes)

- tibiae 48.2
- ulnae 38.21

Tubulus(-i)

- renalis(-es) 154.22
- contorti 154.23
- recti 154.24
- seminiferi
 - contorti 158.29
 - recti 158.30

Tunica(-ae)

- adventitia 120.6, 405.39
 - (ductus deferens) 160.16
 - (seminal vesicle) 160.21
 - (ureter) 156.22
- albuginea 158.24, 405.37
- corporis spongiosi 164.12
- corporum cavernosum 164.11
 - (ovary) 166.14
- conjunctiva 366.24
- bulbaris 368.1
- palpebralis 368.2
- externa 406.31
- fibrosa 130.31, 405.38
- bulbi 354.23
 - (spleen) 268.14
- funiculi spermatici 160.26
- interna bulbi 358.18
- intima 406.32
- media 406.33
- mucosa 405.40
 - (auditory tube) 384.24
 - (bronchus) 148.4
 - cavittatis tympanicae 384.4
 - (colon) 126.9
 - (ductus deferens) 160.18
 - (endometrium) 168.29
 - (esophagus) 120.12
 - (gallbladder) 134.8
 - (larynx) 144.14
 - (larynx) 114.1
 - nasi 136.14
 - oris 108.19
 - (pharynx) 118.17
 - (seminal vesicle) 160.23
 - (small intestine) 122.27
 - (stomach) 122.11
 - (trachea) 144.26
 - (ureter) 156.24
 - (urethra) 172.17
 - (urinary bladder) 158.9
 - (uterine tube) 168.4
 - (vagina) 170.11
- muscularis 120.7, 405.45
 - (bronchus) 148.2
 - (colon) 126.1
 - dartos 166.4
 - (ductus deferens) 160.17
 - (gallbladder) 134.7
 - (myometrium) 168.28
 - pharyngis 118.19
 - (rectum) 126.17
 - (seminal vesicle) 160.22
 - (small intestine) 122.23

Tunica(-ae)
 muscularis
 (stomach) 122.5
 (ureter) 156.23
 (urethra) 172.15
 (urinary bladder) 158.3
 (uterine tube) 168.3
 (vagina) 170.10
 serosa 122.3, 122.21, 405.48
 (gallbladder) 134.5
 (liver) 130.29
 (perimetrium) 168.26
 (peritoneum) 176.24
 (spleen) 268.13
 (urinary bladder) 158.1
 (uterine tube) 168.1
 spongiosa
 (urethra) 172.16
 (vagina) 170.16a
 subserosa 122.22
 vaginalis
 communis 160.30
 testis 158.23, 162.1
 vasculosa bulbi 356.12
 Turkish saddle 10.5
 Tympanic
 aperture of canaliculus of
 chorda tympani 380.16
 artery
 anterior 198.11
 inferior 194.20
 posterior 196.24
 superior 198.19
 canaliculus 14.28
 cavity 14.30, 378.16
 mucous membrane 384.4
 roof 14.2
 cells 380.18
 enlargement 330.21
 ganglion 330.21
 groove 16.7
 lip of limb of osseous spiral
 lamina 372.25
 membrane 380.21
 recess 284.7a
 anterior 384.8
 posterior 384.10
 superior 384.9
 secondary 380.6
 umbo 380.28
 nerve 330.20
 notch 16.8, 386.3a
 ostium of auditory tube
 384.14
 part of temporal bone 16.1
 plexus 330.22
 tubal branch 330.23
 ring 16.2
 sinus 380.1
 spine
 greater 16.5
 lesser 16.6
 veins 236.30
 wall of cochlear duct 372.18
 Tympanomastoid fissure 14.34

Tympanostapedial syndesmosis
 382.21

U

Ulna 38.18
 body 38.24
 head 38.32
 Ulnar 396.38
 artery 214.14
 branches of medial ante-
 brachial cutaneous
 nerve 338.7
 collateral ligament 62.5
 carpal 62.22
 head
 of extensor carpi ulnaris
 90.20
 of flexor carpi ulnaris 90.5
 of pronator teres 88.28
 nerve 338.17
 groove for 36.29
 notch 38.16
 recurrent artery 214.15
 tuberosity 38.21
 veins 244.18
 Ulnaris 396.38
 Ulnocarpal ligament, palmar
 62.20
 Umbilical
 artery 222.26
 cord 172.30
 fold
 lateral 180.18
 medial 180.15
 median 180.13
 ligament, medial 222.30
 part of portal vein of liver
 248.8
 region 400.5
 ring 86.23
 vein, left 248.12
 Umbo, membranæ tympani
 380.28
 Uncal process 2.17
 Uncinate
 fasciculus 316.18
 process 20.16, 128.3
 Uncus 2.17, 310.16
 corporis 2.17
 Unguis 392.20
 Unipennate muscle 405.8
 Upper 396.19
 anterior segment of kidney
 154.18
 arm 400.20
 branch to lower lobe of left
 pulmonary artery 190.37
 eyelid 366.3
 lingular branch, left pulmo-
 nary artery 190.35
 lip 108.6
 lobe of lung 148.23
 left lung 150.16
 right lung 150.2

Upper
 margin, spleen 268.10
 omental recess 176.32
 pelvic aperture 44.27
 pole of kidney 154.10
 trunk 336.14
 Urachus 156.31
 Ureter 156.19
 abdominal part 156.20
 pelvic part 156.21
 Ureteric
 branches
 artery of ductus deferens
 222.28
 ovarian artery 222.4
 testicular artery 222.2
 plexus 348.25
 Urethra
 feminina 172.13
 masculina 164.23
 membranous part 164.29
 navicular fossa 164.31
 spongy part 164.30
 Urethral
 artery 224.13
 carina of vagina 170.16
 crest 164.25, 172.21
 glands 164.35, 172.18
 lacunæ 164.34, 172.19
 surface of penis 162.32
 Urinary
 bladder 156.25
 apex 156.26
 body 156.27
 cervix (neck) 156.29
 fundus 156.28
 trigone 158.10
 uvula 158.14
 organs 154.2
 Uriniferous tubule (nephron)
 154.22
 convoluted 154.23
 Urogenital
 diaphragm 176.1
 inferior fascia 176.6
 superior fascia 176.5
 peritoneum 180.22
 region 400.17
 sinus, primitive 172.34
 system 154.1
 Uteric branches of renal artery
 220.26
 Uterine
 artery 224.2
 extremity 166.13
 glands 168.30
 part of placenta 172.28
 tube 166.29
 abdominal opening 166.30
 ampulla 166.34
 fimbriae 166.32
 infundibulum 166.31
 isthmus 166.35
 uterine opening 166.37
 uterine part 166.36

Uterine
veins 250.13
venous plexus 250.14
Uterovaginal plexus 350.16
Uterus 168.6
body 168.7
broad ligament 180.24
cavity 168.12
fundus 168.8
right/left horn 168.9
Utricle (utrículus) 370.10
Utricular
macula 372.4
nerve 330.9
Utriculoampullar nerve 330.8
Utriculosaccular duct 370.9
Utriculos prostaticus 164.27
Uveal
part of trabecular meshwork
254.29
tract 356.12
Uvula
palatina 116.5
vermis 288.30
vesicae 158.14

V

Vagal trunk
anterior 332.24
posterior 332.25
Vagina(-ae) 170.1
anterior wall 170.6
bulbi 364.21
carotica 82.25
communis musculum flex-
orum 104.2
externa (nervus opticus) 354.12
fibrosae
digitorum manus 92.27
tendinum digitorum pedis
100.22
interna (nervus opticus) 354.13
musculi
extensoris carpi radialis
brevis 102.26
recti abdominis 86.4
orifice 172.1
posterior wall 170.7
synovialis(-es) 100.19a
digitorum manus 92.30
tendinum 405.20a
digitorum pedis 100.20
tendinum(-is) 405.18
digitorum
manus 104.4
pedis 106.20
intertubercularis 88.14
musculi
abductoris longi 102.20
extensoris
brevis pollicis 102.20
carpi ulnaris 102.25
digiti minimi 102.24
digitorum 102.23

Vagina(-ae)
tendinum(-is)
musculi
extensoris
digitorum pedis longi
106.11
hallucis longi 106.10
indicis 102.23
pollicis longi 102.22
extensorum carpi
radialis 102.21
flexoris
carpi radialis 104.1
digitorum pedis longi
106.12
hallucis longi 106.14
pollicis longi 104.3
obliqui superioris 102.1,
364.12
peronei (fibularis) longi
plantaris 106.19
peroneorum (fibularium)
communis 106.15
tibialis
anterioris 106.9
posterioris 106.13
vestibule 170.32
fossa 170.33
Vaginal
artery 224.6
branches
middle rectal artery 224.7a
uterine artery 224.3
nerves 350.17
part of cervix 168.17
process 12.7, 16.9
of peritoneum 168.33, 180.23
venous plexus 250.15
Vagus nerve 332.1
dorsal nucleus 282.7
trigone 286.33
Vallate papillae 114.7
Vallecula 288.14
epiglottica 118.9
Vallum unguis 392.25
Valva 406.34
aorta 190.2
atrioventricularis
dextra 188.3
sinistra 188.26
ileocaecalis (ilealis) 124.19
mitralis 188.26
tricuspidalis 188.3
trunci pulmonalis 188.10
Valve 406.34
of veins 406.36
Valvula(-ae)
anales 126.27
Eustachii 186.26
foraminis ovalis 188.22
fossa navicularis 164.32
lymphatica 406.35
semilunaris
anterior 188.11
dextra 188.12, 190.4

Valvula(-ae)
semilunaris
posterior 190.3
sinistra 188.13, 190.5
sinus coronarii 186.27
Thebesii 186.27
venae caeve, inferioris 186.26
venosa 406.36
Vas(-a)
afferens 156.5
anastomoticum 406.37
auris internae 374.10
capillare 406.38
collaterale 406.39
efferens 156.6
lymphatica (lymphaticum)
254.2, 254.5, 406.30
afferens 254.24
efferens 254.25
profundum 254.8
superficialis 254.7
lymphocapillare 254.3
prominens 374.7
recta 156.8
sanguinae retinae 360.6
sinusoideum 406.41
spirale 374.2
vasorum 406.42
Vascular
cecal fold 180.3
lacuna 98.22
lamina 356.16
plexus 406.24, 408.13a
tunic of eyeball 356.12
Vater-Pacini corpuscles 390.23
Vein(-s) 230.1, 406.43
of brain stem 242.13
of bulb of penis 250.22
of bulb of vestibule 250.22
of caudate nucleus 242.9
of cochlear aqueduct 234.23,
374.19
of Galen 242.1
of lateral recess of fourth ven-
tricle 242.17
of medulla oblongata 242.16
of olfactory gyrus 240.27
of pterygoid canal 236.26
of uncus 240.17
of vertebral column 246.16a
of vestibular aqueduct
374.18
Velum
medullare
inferius 288.4
superius 288.2
palatinum 108.17, 116.4
Vena(-ae) 230.1, 406.43
adrenalis
dextra 246.32
sinistra 246.29
anastomotica
inferior 240.20
superior 240.19
angularis 236.6

- Vena(-ae)
 anterior(-es)
 cerebri 240.23
 septi pellucidi 242.5
 appendicularis 248.26
 aqueductus
 cochleae 234.23, 374.19
 vestibuli 374.18
 arcuatae 156.11
 articulares 236.29
 atriales
 dextrae 232.24
 sinistrae 232.24
 atrioventriculares 232.26
 auricularis(-es)
 anteriores 236.27
 posterior 238.3
 axillaris 244.13
 azygos 246.1
 basalis 240.22
 communis 230.21, 232.8
 inferior 230.26, 232.13
 superior 230.22, 232.9
 basilica 244.23
 basivertebrales 249.19
 brachiales 244.17
 brachiocephalicae (dextra/sin-
 istra) 232.28
 bronchiales 234.5, 246.6
 bulbi penis/vestibuli 250.22
 canalis pterygoidei 236.26
 capsulares 246.28a
 cardiaca
 minimae 232.23
 parva 232.21
 cava
 inferior 246.21
 foramen 84.32
 opening 186.24
 valve 186.26
 left, fold of 232.19
 superior 232.27
 opening 186.24
 cavernosae 164.19
 centralis(-es) 132.5, 182.36
 retinae 244.4
 cephalica 244.20
 accessoria 244.22
 cerebelli 242.18
 cerebri 240.9
 cervicalis profunda 234.13
 choroidea
 inferior 240.29
 superior 242.3
 ciliares 244.1
 anteriores 244.2
 circumflexa(-ae)
 anterior humeralis 244.13a
 iliaca
 profunda 250.25
 superficialis 252.3
 laterales femorales 252.11
 mediales femorales 252.10
 posterior humeralis 244.13a
 scapulae 244.13a
- Vena(-ae)
 colica
 dextra 248.27
 media 248.28
 sinistra 248.34
 columnae vertebrales 246.16a
 comitans 406.44
 nervi hypoglossi 234.30
 conjunctivales 244.7
 cordis 232.14
 coronaria
 dextra 232.20b
 sinistra 232.16a
 cutanea 406.45
 cystica 248.15
 digitales
 dorsales pedis 252.19
 palmares 244.31
 plantares 252.26
 diploica(-ae) 238.24
 frontalis 238.25
 occipitalis 238.28
 temporalis
 anterior 238.26
 posterior 238.27
 directae laterales 242.10
 dorsalis(-es)
 corporis callosi 242.12
 linguae 234.29
 profunda
 clitoridis 250.12
 penis 250.11
 superficiales
 clitoridis 252.5
 penis 252.5
 emissaria(-ae) 240.1, 406.46
 condylaris 240.4
 mastoidea 240.3
 occipitalis 240.5
 parietalis 240.2
 epigastrica(-ae)
 inferior 250.24
 superficialis 252.4
 superiores 234.15
 episclerales 244.5
 ethmoidales 242.27
 facialis 236.5
 femoralis 252.1
 fibulares 252.22
 frontalis(-es) 236.7, 240.13
 gastrica(-ae)
 brevis 248.31
 dextra 248.18
 sinistra 248.17
 gastro-omentalis (epiploica)
 dextra 248.22
 sinistra 248.32
 geniculares 252.14
 gluteales
 inferiores 250.3
 superiores 250.2
 gyri olfactorii 240.27
 hemiazygos 246.3
 accessoria 246.4
 oesophageales 246.5
- Vena(-ae)
 hepaticae 246.24
 dextrae 246.25
 intermediae 246.26
 sinistrae 246.27
 hypogastrica 250.1
 ileales 248.21a
 ileocolica 248.25
 iliaca
 communis 248.37
 externa 250.23
 interna 250.1
 iliolumbalis 248.39
 inferior(-es)
 cerebelli 242.22
 cerebri 240.16
 vermis 242.20
 insulares 240.25
 intercapitulares 244.29, 252.26a
 intercostalis(-es)
 anteriores 234.18
 posterior 246.13
 superior
 dextra 246.2
 sinistra 234.20
 suprema 234.19
 interlobares 156.10
 interlobulares 132.4, 156.12
 internae cerebri 242.2
 interosseae
 anteriores 244.19a
 posteriores 244.19b
 interventricularis anterior
 232.16
 intervertebralis 246.15
 jejunales 248.21
 jugularis
 anterior 238.4
 externa 238.1
 interna 234.21
 labialis(-es)
 anteriores 252.6
 inferiores 236.13
 posteriores 250.21
 superior 236.12
 labyrinthales 238.19
 labyrinthinae 374.15
 lacrimalis 242.28
 laryngea
 inferior 232.31
 superior 236.4
 lateralis atrii ventriculi later-
 alis 242.8
 lingualis 234.28
 lumbalis(-es) 246.11, 246.23
 ascendens 246.10
 magna cerebri 242.1
 marginalis
 dextra 232.20a
 lateralis 252.26b
 medialis 252.26c
 maxillares 236.22
 media
 profunda cerebri 240.24
 superficialis cerebri 240.18

Vena(-ae)

medialis atrii ventriculi lateralis 242.7
 mediana
 antebrachii 244.25
 basilica 244.27
 cephalica 244.26
 cubiti 244.24
 mediastinales 234.4, 246.8
 medullae
 oblongatae 242.16
 spinalis 246.20
 membri superioris 244.8a
 meningae 234.27
 mediae 236.24
 mesenterica
 inferior 248.33
 superior 248.20
 metacarpales
 dorsales 244.33
 palmares 244.34
 metatarsales
 dorsales 252.20
 plantares 252.25
 musculophrenicae 234.17
 nasales externae 236.10
 nasofrontalis 242.26
 nuclei caudati 242.9
 obliqua atrii sinistri 232.18
 obturatoria(-ae) 250.4
 accessoria 250.24a
 occipitalis(-es) 234.9, 238.2, 240.15
 oesophageales 234.7
 ophthalmica
 inferior 244.8
 superior 242.25
 orbitae 242.24a
 ovarica
 dextra 246.34
 sinistra 246.31
 palatina externa 236.16
 palpebrales 244.6
 inferiores 236.11
 superiores 236.9
 pancreaticae 248.23, 248.30
 pancreaticoduodenales 248.24
 paraumbilicales 248.16
 parietales 240.14
 parotideae 237.28
 pectorales 244.10
 pedunculares 240.30
 perforantes 252.12, 252.27
 pericardiacae 234.2
 pericardiophrenicae 234.3
 pericardiales 246.7
 petrosa 242.24
 pharyngeales 234.26
 phrenicae
 inferiores 246.22
 superiores 246.9
 pontis 242.15
 pontomesencephalica anterior 242.14
 poplitea 252.13

Vena(-ae)

portae hepatis 248.1
 portales hypophysiales 240.8a
 posterior(-es)
 corporis callosi 242.11
 septi pellucidi 242.6
 praecentralis cerebelli 242.23
 praefrontales 240.12
 praepylorica 248.19
 profunda(-ae) 406.47
 cerebri 240.21
 clitoridis 250.18
 faciei (facialis) 236.14
 femoris 252.9
 linguae 234.32
 membri
 inferioris 252.0b
 superioris 244.16b
 penis 250.17
 pudenda(-ae)
 externae 252.2
 interna 250.16
 pulmonalis(-es) 230.2
 dextra 230.3
 inferior 230.17
 superior 230.4
 sinistra
 inferior 232.4
 superior 230.27, 230.28
 radiales 244.19
 recessus lateralis ventriculi quarti 242.17
 rectalis(-es)
 inferiores 250.20
 mediae 250.19
 superior 248.36
 renales 156.9, 246.28
 retromandibularis 236.18
 sacralis(-es)
 laterales 250.5
 mediana 248.38
 saphena
 accessoria 252.8
 magna 252.7
 parva 252.15
 scapularis dorsalis 244.11
 sclerales 244.3
 scrotales
 anteriores 252.6
 posteriores 250.21
 sigmoideae 248.35
 spinales
 anteriores 246.20a
 posteriores 246.20b
 spiralis modioli 374.16
 splenica 248.29
 sternocleidomastoidea 236.3
 stylostomatoidea 236.31
 subclavia(-ae) 244.9
 sulcus 6.20
 subcostales 246.12
 subcutaneae abdominis 234.16
 sublingualis 234.31
 submentalialis 236.17

Vena(-ae)

subscapularis 244.13a
 superficiales 406.48
 cerebri 240.10
 membri
 inferioris 252.0a
 superioris 244.16a
 superior(-es)
 cerebelli 242.21
 cerebri 240.11
 vermis 242.19
 supraorbitalis 236.8
 suprarenalis
 dextra 246.32
 sinistra 246.29
 suprascapularis 238.6
 supratrochleares 236.7
 surales 252.13a
 temporalis(-es)
 media 236.20
 profundae 236.25
 superficiales 236.19
 testicularis
 dextra 246.33
 sinistra 246.30
 thalamostriata(-ae)
 inferiores 240.26
 superior 242.4
 thoracica(-ae)
 interna 234.14
 lateralis 244.14
 thoracoacromialis 244.12, 244.21
 thoracodorsalis 244.13a
 thoracoepigastricae 244.15
 thymicae 234.1
 thyroidea(-e)
 inferiores 232.29
 mediae 236.2
 superior 236.1
 tibiales
 anteriores 252.16
 posteriores 252.21
 tracheales 234.6
 transversa(-ae)
 cervicis 238.7
 faciei (facialis) 236.21
 trunci encephali 242.13
 tympanicae 236.30
 ulnares 244.18
 umbilicalis
 sinistra 248.12
 unci 240.17
 uterinae 250.13
 ventricularis(-es) 232.25
 inferior 240.28
 ventriculi
 dextri, anterior 232.22
 sinistri, posterior 232.17
 vertebralis 234.8
 accessoria 234.11
 anterior 234.10
 vesicales 250.8
 vestibulares 374.17
 vorticosae 242.29

- Venous**
 grooves 30.7
 plexus 406.25
 anterior
 external vertebral 246.17
 internal vertebral 246.18
 of foramen ovale 240.7
 of hypoglossal canal 240.6
 of internal carotid 240.8
 posterior
 external vertebral 246.17
 internal vertebral 246.18
 prostatic 250.10
 rectal 250.7
 sacral 250.6
 uterine 250.14
 vaginal 250.15
 vesical 250.9
- Venter**
 anterior (musculi digastricus) 82.8
 frontalis (musculi occipitofrontalis) 78.8
 inferior (musculi omohyoideus) 82.17
 (muscle) 405.4
 occipitalis (musculi occipitofrontalis) 78.9
 posterior (musculi digastricus) 82.9
 superior (musculi omohyoideus) 82.16
- Ventral** 396.15
 branch
 great auricular nerve 334.30
 spinal nerve 334.9, 334.21
 region of hypothalamus 302.16
 root 334.5
 sacrococcygeal ligament 56.24
 sacrococcygeus muscle 88.3
 sacroiliac ligaments 66.12
 side of fingers 400.49
 supraoptic commissure 394.13
 thalamus (subthalamus) 296.29
 sections 300.14
- Ventralis** 396.15
- Ventricle**
 left 184.21, 188.24
 right 184.21, 188.1
 third 298.1
- Ventricular**
 fold 142.29
 veins 232.25
 inferior 240.28
- Ventriculus(-i)** 120.15
 cordis 184.21
 laryngis 144.1
 lateralis 314.1
 quartus 286.19
 sinister 188.24
 terminalis 272.18
 tertius 298.1
- Ventromedial hypothalamic nucleus** 304.1
- Venula(-ae)** 406.49
 macularis
 inferior 360.13
 superior 360.12
 medialis retinae 360.14
 nasalis retinae
 inferior 360.11
 superior 360.10
 rectae 156.13
 stellatae 156.14
 temporalis retinae
 inferior 360.9
 superior 360.8
- Venule** 406.49
- Vermiform appendix** 124.22
 suspensory ligament 178.9
- Vermis**
 cerebelli 288.16
 folium 288.27
 pyramid 288.29
 tuber 288.28
- Vertebra(-ae)** 2.1a
 body 2.3
 cervicales 2.16
 coccygeal 4.37
 lumbales (lumbares) 2.28
 prominens (C7) 2.23
 sacrales 4.16
 thoracicae 2.24
- Vertebral**
 arch 2.4
 artery 206.2
 sulcus 4.9
 canal 2.2
 column 2.1
 joints 56.8
 foramen 2.10
 ganglion 352.6
 nerve 352.12
 notch
 inferior 2.9
 superior 2.8
 part
 of lung 148.12
 of vertebral artery 206.4
 plexus 352.12
 region 400.9
 vein 234.8
 accessory 234.11
 anterior 234.10
- Vertex** 28.30
 corneae 346.4
- Vertical** 396.2
 muscle of tongue 114.26
- Verticalis** 396.2
- Vesica**
 biliaris (fellea) 134.1
 urinaria 156.25
- Vesical**
 arteries
 inferior 224.1
 superior 222.29
 fold, transverse 180.20
 plexus 350.18
 surface of uterus 168.13
- Vesical**
 veins 250.8
 venous plexus 250.9
- Vesicouterine pouch** 180.32
- Vesicula seminalis** 160.20
- Vesicular**
 lymph nodes, lateral 266.9
 ovarian follicles 166.19
- Vestibular**
 area 286.26
 branches of labyrinthine artery 374.12
 cecum 372.17
 fold 142.29
 ganglion 330.5
 inferior part 330.12
 upper part 330.7
 glands
 greater 172.3
 lesser 172.2
 labyrinth 370.6
 ligament 144.11
 lip of limb of osseous spiral lamina 372.24
 membrane 374.3
 nerve 330.2, 330.4
 nuclei 282.12, 286.9
 inferior 282.13
 lateral 282.15, 286.11
 medial 282.14, 286.10
 superior 286.12
 veins 374.17
 wall
 of cochlear duct 374.3
- Vestibule** 374.21
 aqueduct 14.15
 external opening 14.16
 crest 374.24
 elliptical recess 374.23
 of larynx 142.27
 of mouth 108.3
 of nose 136.8
 pyramid 374.25
 spherical recess 374.22
 of vagina 170.32
 bulb 170.34
 fossa 170.33
- Vestibulocochlear**
 nerve 330.1
 organ 370.1
- Vestibulospinal tract** 276.23
- Vestibulum(-a)** 384.21
 bursae omentalis 176.31
 crest 374.24
 elliptical recess 374.23
 laryngis 142.27
 nasi (nasale) 136.8
 oris 108.3
 pyramid 374.25
 spherical recess 374.22
 vaginae 170.32
- Vestigial ductus deferens** 170.22
- Vestigium processus vaginalis** 160.31

Vibrissae 392.8
 Vidian canal 12.12
 Villi
 intestinales 122.30
 synoviales 404.42
 Villous folds 122.15
 Vinculum(-a)
 breve 92.33
 longum 92.32
 tendinum 92.31, 100.21
 Visceral
 ganglia 407.16
 layer 184.6
 of tunica vaginalis testis 162.3
 nerve fibers 407.9
 nodes 262.13
 of pelvis 266.5
 pelvic fascia 174.21
 peritoneum 176.26
 pleura 152.14
 plexus 348.2, 408.13
 surface
 of liver 130.1
 of spleen 268.4
 Viscerocranium 8.1a
 Vitreous
 body 362.4
 chamber of eye 362.3
 humor 362.9a
 membrane 362.8
 Vocal
 fold 144.5
 ligament 144.13
 process 140.14
 Volar 396.42
 Volaris 396.42
 Vomer 20.28
 ala 20.29
 choanal crest 20.30a
 cuneiform part 20.30b

Vomeronasal
 cartilage 134.32
 organ 136.7
 Vomerorostral canal 30.30
 Vomerovaginal
 canal 30.29
 groove 12.9
 Vortex cordis 186.2
 Vortices pilorum 392.18
 Vorticose veins 242.29

W

White
 commissure
 anterior 276.18
 posterior 276.18a
 communicating ramus 334.11b
 laminae 290.12
 matter 274.14, 276.17, 406.52
 ramus communicans 407.20
 Wing
 of ilium 41.13
 of sphenoid
 greater 10.23
 lesser 10.19
 Wisdom tooth 112.24
 Wolffian duct 172.32
 Wormian bones 30.9
 Wrist 40.1, 400.34

X

Xiphisternal synchondrosis 6.30
 Xiphoid process 6.32

Y

Yellow
 bone marrow 404.4
 ligaments 56.13

Z

Zona
 incerta 300.19
 orbicularis 66.22
 Zonula ciliaris 362.24
 Zonular
 fibers 362.25
 spaces 362.26
 Zygapophysial joints 56.14
 Zygapophysis
 inferior 2.15
 superior 2.14
 Zygomatic
 arch 30.12
 bone 26.1
 border, sphenoid 10.28
 branches of facial nerve 328.14
 nerve 322.25
 process
 frontal bone 18.13
 maxilla 22.29
 temporal bone 16.16
 region 398.21
 Zygomatico-orbital
 artery 198.5
 foramen 26.8
 Zygomaticofacial
 branch of zygomatic nerve 322.27
 foramen 26.9
 Zygomaticomaxillary suture 22.13, 54.19
 Zygomaticotemporal
 branch of zygomatic nerve 322.26
 foramen 26.10

Erratum

Feneis/Dauber,
Pocket Atlas of Human
Anatomy, 4th ed.
ISBN 3-13-511204-7 (GTV)
ISBN 0-86577-928-7 (TNY)

Page 228,
right-hand column should
read as follows:

- 15 **Lateral malleolar branches.** Rami malleolares laterales. Branches to the lateral malleolus, frequently from the communicating branch. A
- 16 **Calcanean branches.** Rami calcanei. They pass mainly to the lateral side of the calcaneus. A
- 17 **Calcanean network.** Rete calcaneum. Arterial network on posterior aspect of the calcaneus. A
- 17a **Nutrient artery of fibula.** A. nutiens (nutricia) fibulae. A
- 18 **Medial plantar artery.** A. plantaris medialis. Generally the weaker medial terminal branch of the posterior tibial artery; it supplies the abductor hallucis and flexor digitorum brevis muscles. C
- 19 **Deep branch.** Ramus profundus. It usually joins the plantar arch. C
- 20 **Superficial branch.** Ramus superficialis. It takes a superficial course on the abductor hallucis as far as the big toe. C
- 21 **Lateral plantar artery.** A. plantaris lateralis. Larger lateral terminal branch of the posterior tibial artery. It takes a curved course anterolaterally as it passes between the flexor digitorum brevis and quadratus plantae. C
- 22 **Deep plantar arch.** Arcus plantaris profundus. Distal convex continuation of the lateral plantar artery between the interossei and the oblique head of the adductor hallucis. C
- 23 **Plantar metatarsal arteries.** Aa. metatarsales plantares. Four arterial trunks emanating from the plantar arch below the spaces between the metatarsal bones. C
- 24 **Perforating branches.** Rami perforantes. Usually two such branches arise from each plantar metatarsal artery and pass between the metatarsal bones to the dorsum of the foot. C
- 25 **Common plantar digital arteries.** Aa. digitales plantares communes. Arterial stems extending from the distal perforating branch to the division into the proper plantar digital arteries. C
- 26 **Proper plantar digital arteries.** Aa. digitales plantares propriae. Arteries coursing along the plantar medial and lateral sides of the toes. C
- 26a **Superficial plantar arch.** [Arcus plantaris superficialis]. Occasional superficial connection between the medial and lateral plantar arteries.